# TRANSIENT FUNCTIONAL CROSSBITE AND LIP BITING CAUSED BY ERUPTION OF THE FIRST PERMANENT MOLAR: A CASE REPORT

Aline dos Santos **Letieri**[1], Paula Moraes **Lima**[1], Thiago Isidro **Vieira**[1], Lucianne Cople **Maia**[1*]

[1] Department of Paediatric Dentistry and Orthodontics, School of Dentistry, Universidade Federal do Rio de Janeiro, Rio de Janeiro, RJ, Brazil.

**Palavras-chave:** Erupção Dentária. Odontopediatria. Oclusão Dentária Traumática.

**Resumo**

**Introdução**: A erupção dentária é um fenômeno fisiológico que costuma causar alterações locais. **Objetivo**: Relatar um caso incomum de mordida cruzada transitória e mordedura de lábio causadas pela erupção do primeiro molar permanente. **Relato do caso**: Uma garota de 5 anos buscou tratamento odontológico com a queixa principal de dor em região posterior inferior. No exame clínico, foram observados edema, acúmulo de biofilme, ulceração local e inflamação por trauma do tecido devido à erupção do primeiro molar permanente inferior esquerdo. Além disso, foram observadas mordida cruzada unilateral funcional e mordedura de lábio. Foi prescrita clorexidina a 0,12% e pomada analgésica/antiinflamatória (Triancinolona Acetonida) tópica por 10 e 7 dias, respectivamente, associada à higiene local na área afetada. No acompanhamento de 1 mês, observou-se a resolução da inflamação local, bem como a correção espontânea da mordida cruzada e da mordedura do lábio. **Conclusão**: Uma vez que os desvios oclusais funcionais podem ser causados pela erupção dentária, é importante que os profissionais saibam diagnosticar e tratar corretamente esta condição.

**Keywords:** Tooth Eruption. Pediatric Dentistry. Dental Occlusion, Traumatic.

**ABSTRACT**

**Introduction**: Tooth eruption is a physiological phenomenon that typically causes local changes. **Objective**: The aim of this paper is to report an unusual functional crossbite and lip biting caused by eruption of the first permanent molar. **Case report**: A 5-year-old female sought dental treatment with the chief complaint of pain in the posterior region. At the clinical examination, swelling, accumulation of biofilm, local ulceration and severe traumatic tissue inflammation due to eruption of the first permanent lower left molar were observed. Furthermore, functional unilateral crossbite and lip biting were observed. Local hygiene associated with chlorhexidine 0.12% and topical analgesic/anti-inflammatory ointment (Triamcinolone Acetonide) were prescribed for 10 and 7 days, respectively. At 1-month follow up, resolution of local inflammation was observed as well as spontaneous correction of the crossbite and lip biting. **Conclusion**: Since functional occlusal deviations can be caused by tooth eruption, it is important that dentists are able to diagnose and treat this condition.

## INTRODUCTION

Tooth eruption is the displacement of the tooth from its initial site of development to its functional position in the dental arch.[1] There are different theories to explain this phenomenon, which include genetic, physical, hormonal, molecular and cellular control, the multifactorial concept being the most accepted.[1,2]

It is quite common that most children present systemic and local signs and symptoms associated with the period of tooth eruption, especially in primary dentition.[3,4] The most common alterations observed during this period are gingival irritation, irritability and drooling. It normally causes stress and a great deal of anxiety among parents due to the intense discomfort presented by children,[4] leading to a high demand for dental care, especially with pediatric dentists.[5]

It can also occur during permanent molar eruption, as this period is characterized by inflammation of the local tissues that generates pain and discomfort in patients, including other changes.[5] Thus, the aim of this report is to present a case of an unusual functional crossbite caused by the eruption of the lower first permanent molar.

Submitted: November 21, 2017
Modification: March 02, 2018
Accepted: March 16, 2018

*** Correspondence to:**
Professor Lucianne Cople Maia
Disciplina de Odontopediatria da Faculdade de Odontologia - UFRJ
Caixa Postal: 68066 – Cidade Universitária - CCS
CEP: 21941-971 - Rio de Janeiro – RJ – Brazil
E-mail: rorefa@terra.com.br
Fax/phone: +5521 39382101

## CASE REPORT

A 5-year-old female presented at the Department of Paediatric Dentistry and Orthodontics of Universidade Federal do Rio de Janeiro with a chief complaint of pain at the distal region of the second primary left lower molar. The patient's medical history was not relevant, but the patient had difficulty eating and brushing her teeth.

Clinical examination showed caries-free mixed dentition and unsatisfactory oral hygiene status. It was observed that the alveolar mucosa in the distal region of the second primary left lower molar presented with swelling, excessive accumulation of biofilm, local ulceration and severe traumatic tissue inflammation, associated with the eruption of the lower first left permanent molar (Figures 1a and 1b). In addition, it was observed that the ulcers were caused by direct occlusal contact of the first permanent left upper molar, already erupted, with this swollen soft tissue (Figure 1c).

A functional deviation from her normal occlusion was verified, as indicated by the occlusal closure in a different position of maximal habitual intercuspation to promote pain relief over this traumatized region. The presence of a functional unilateral posterior crossbite on the right side (Figure 1c) and parafunctional habit of lower lip biting (Figure 1d), leading to labial ulceration (Figure 1e) were observed.

The oral condition of the patient was explained to the mother and she was given instructions for improving oral hygiene, especially in the affected area, with an extra soft toothbrush. Mouthwash with 0.12% chlorhexidine was prescribed for 10 days and local use of analgesic and anti-inflammatory ointment (Triamcinolone Acetonide) only in the affected region for 7 days, to improve the ulcerations. Furthermore, the proposed treatment was to wait for the complete healing of the region and then verify whether the patient returned to her habitual occlusion. Despite her young age, the patient presented with cooperative behavior throughout the appointment.

At 1-month follow up, resolution of the inflammatory process, a significant improvement in her oral hygiene and a return to occlusion on maximal habitual intercuspation with spontaneous resolution of the crossbite and lip biting were verified. At the 6-month follow-up visit, maintenance of oral health, satisfactory oral hygiene and no occlusal alterations beyond the total eruption of the first permanent left lower molar were observed (Figure 1f).

In addition, the maintenance of a satisfactory occlusion relation on the posterior left region was observed (Figure 2).

## DISCUSSION

Different local symptoms are related to tooth eruption. Among the most commonly observed are excessive

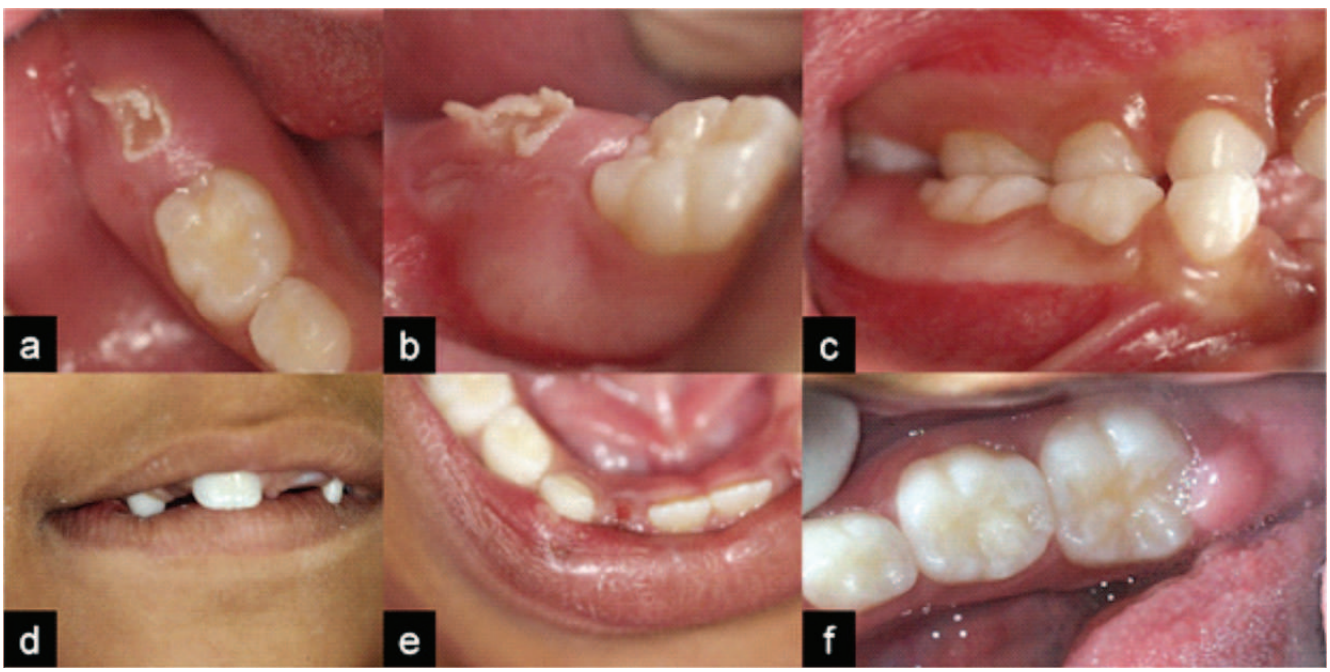


***Figure 1:*** *(a) Occlusal and (b) vestibular view of the hyperplasic inflammatory tissue in the distal region of the second primary left lower molar. (c) Posterior functional crossbite and direct occlusal contact of the first permanent left upper molar in lower soft tissue. (d) Lower lip biting. (e) Lower lip ulceration. (f) Six-month follow-up evaluation showing the complete remission of the lesion.*



***Figure 2**: Lateral view showing a satisfactory occlusion in the left posterior region at the six-month follow-up appointment.*

drooling, inflammation of the gingiva overlying the tooth, gum irritation, increased biting and pain.[3-5] The theory of the role of the periodontal ligament in determining tooth eruption stipulates that this process occurs by the release of mediators and activation of cells directly involved in the inflammatory process.[2,7] It is also known that the incidence of physical forces influences the mitotic activity and collagen production by cells of the periodontal ligament, acting as a local adaptive response to repair damages.[7]

The teeth movement through alveolar bone that occurs during normal tooth eruption also causes biological responses such as osteoclastogenesis and the osteogenesis process, starting molecular and cellular events that leads to local inflammatory changes.[8] The occurrence of such local modifications may explain the excessive tissue inflammation and local pain that were observed in the present report.

This case also presented an unusual occlusal deviation and lip biting associated with severe gingival inflammation due to the eruption of the first permanent left lower molar. There are no reports of tooth eruption as a causal factor of functional occlusal changes. However, it is known that posterior crossbites that result from a functional shift of the mandible should be treated as soon as clinically feasible after they are found.[6,9-11]

Tooth eruption is a period that requires special attention from dentists. It is extremely important to understand the mechanisms involved and all possible associated alterations in order to provide the most appropriate patient care.[2,12] Treatment should enable the control of pain and discomfort, which are the main complaints from patients during this period.[3-5] However, treatment can also be simple and achieved using a minimally invasive approach. Moreover, in the present case, the resolution of the inflammatory process was sufficient to remove the etiological factors and solve the transitory functional alterations.

It can be concluded that conservative management of a functional crossbite and lip biting due to eruption of a first permanent molar is shown to be an excellent treatment option.

## REFERENCES

1. Wang XP. Tooth eruption without roots. J Dent Res. 2013 Mar 92;3:212-14.
2. Craddock HL, Youngson CC. Eruptive tooth movement - the current state of knowledge. Br Dent J. 2004 Oct 197;7:385-91.
3. Kiran K, Swati T, Kamala K, Jaiswal D. Prevalence of systemic and local disturbances in infants during primary teeth eruption: a clinical study. Eur J Paediat Dent. 2011; 12(4):249-52.
4. Massignan C, Cardoso M, Porporatti AL, Aydinoz S, Canto DL, Mezzomo LAM, et. al. Signs and Symptoms of Primary Tooth Eruption: A Meta-analysis. Pediatrics. 2016;137(3):e20153501.
5. Memarpour M, Soltanimehr E, Eskandarian T. Signs and symptoms associated with primary tooth eruption: a clinical trial of nonpharmacological remedies. BMC Oral Health. 2015 Jul 15:88-96.
6. Binder RE. Correction of posterior crossbites: diagnosis and treatment. Pediatr Dent. 2004 May-Jun 26;3:266-72.
7. Huang L, Liu B, Cha JY, Yuan G, Kelly M, Singh G, et. al. Mechanoresponsive Properties of the Periodontal Ligament. J Dent Res. 2016, 95(4):467–475.
8. Wise GE, King GJ. Mechanisms of Tooth Eruption and Orthodontic Tooth Movement. J Dent Res. 2008, 87(5):414-434.
9. Andrade AS, Gameiro GH, DeRossi M, Gavião MBD. Posterior Crossbite and Functional Changes - A Systematic Review. Angle Orthod. 2009, 79(2);380-86.
10 Kecik D, Kocadereli I, Saatcic I. Evaluation of the treatment changes of functional posterior crossbite in the mixed dentition. Am J Orthod Dentofacial Orthop. 2007, 131(2):202-15.
11. Sonnesen L, Bakke M. Bite force in children with unilateral crossbite before and after orthodontic treatment. A prospective longitudinal study. Eur J Orthod. 2007, 29:310–313.
12. Almonaitiene R, Balciuniene I, Tutkuviene J. Factors influencing permanent teeth eruption. Part one – general factors. Stomatologija. 2010, 12(3):67-72.