AESTHETIC RECOVERY OF THE SMILE USING A SIMPLE AND EFFECTIVE APPLICATION OF PREPOLYMERIZED COMPOSITE VENEERS

Cínthia Marques **Sperduto**[1], Jeane Batista dos Santos **Cavalcante**[1], Núbia Gomes de **Santana**[1], João Victor Frazão **Câmara**[1*], Isabel Ferreira **Barbosa**[1], Gisele Damiana da Silveira **Pereira**[1]

[1]Department of Dental Clinic, Federal University of Rio de Janeiro, Rio de Janeiro, RJ, Brazil

Palavras- chaves: Estética. Falha de Restauração Dentária. Estética Dentária.

RESUMO

Introdução: As facetas pré-fabricadas de resina composta são laminados pré-polimerizados de compósito que surgiram no mercado para simplificar o procedimento restaurador, reduzindo o tempo de trabalho. São facetas extremamente finas, fabricadas em diversos tamanhos, com as quais é possível realizar restaurações com alto padrão estético em dentes anteriores através de uma técnica minimamente invasiva. **Objetivo:** Esse trabalho teve como objetivo demonstrar o uso de facetas pré-fabricadas de resina na reanatomização e recuperação da estética dentária de um paciente jovem com histórico de fratura e escurecimento dos dentes anteriores, após cirurgia estética periodontal. **Relato de caso:** Paciente compareceu à clínica com queixa do sorriso e ao exame clínico, observou-se dente 11 com fratura cervical, dente 21 com alteração de cor e infiltração por cárie e dente 22 com inclinação da face distal para palatina. Como tratamento, foi optado pela utilização das facetas pré-fabricadas de resina composta. **Conclusão:** Os resultados estéticos deste caso foram altamente satisfatórios, principalmente quando comparados ao tempo clínico, custo e trabalho laboratorial de facetas de cerâmica, mostrando a qualidade e as vantagens desse material.

Keywords: Aesthetics. Dental Restoration Failure. Dental Aesthetics.

ABSTRACT

Introduction: The prefabricated composite resin veneers are prepolymerized laminates of composite that appeared in the market to simplify the restorative procedure, reducing working time. They are extremely thin veneers fabricated in several sizes, which allows performing restorations with high aesthetic standard in anterior teeth using a minimally invasive technique. **Objectives:** This study aimed to show the use of prefabricated resin veneers in the re-anatomization and recovery of dental aesthetics of a young patient with history of fracture and darkening of anterior teeth after aesthetic periodontal surgery. **Case report:** The patient attended the clinic with a smile complaint and the clinical examination showed tooth 11 with cervical fracture, tooth 21 with color change and caries infiltration, and tooth 22 with inclination of the distal surface toward the palatal region. As treatment, was opted for the use of prefabricated composite resin veneers. **Conclusion:** The aesthetic results of this case were highly satisfactory, especially when compared with clinical time, cost, and the laboratory work of ceramic veneers, showing the quality and advantages of this material.

Submitted: May 21, 2019
Modification: September 19,02019
Accepted: September 20, 2019

***Correspondence to:**
João Victor Frazão Câmara
Address: Alameda Doutor Octávio Pinheiro Brisolla, 6-65, Jardim Brasil, Bauru - São Paulo, Brazil. Zip code 17012-059.
Telephone number: +55 (21) 98384-4255
E-mail: jvfrazao92@hotmail.com

INTRODUCTION

Over the last years, aesthetics in Dentistry has been a determinant factor for the development of new materials and techniques.[1,2] Several factors may interfere with the aesthetics of the smile, including dental trauma, which causes changes in tooth shape and potential darkening. This clinical situation may cause discomfort to the patient and brings the challenge of conservative aesthetic solution to dental professionals.[3]

Restorative procedures with minimal dental preparation that employ adhesives. The adhesive system promotes a high degree of physical and chemical adhesion at the tooth/restoration interface, reduction of polymerization contraction and marginal microleakage. Therefore, the prefabricated composite resin veneers are used in cases presenting deficient restorations and/or shape changes, allowing an aesthetic recontouring. They are extremely thin and fabricated in several sizes, which allows performing restorations with high aesthetic standard in anterior teeth and minimally invasive restorations, preserving the dental structure.[4]

Thus, this study aimed to show the clinical use of prefabricated resin veneers in the aesthetic dental recovery of a young adult patient.

CASE REPORT

Male patient, D B S, 24 years old, attended the Integrated Clinic of the School of Dentistry of the Federal University of Rio de Janeiro, RJ, Brazil, complaining of the appearance of his anterior teeth. After anamnesis, clinical examination, radiographic analysis, and initial photographs, the treatment was designed.

The clinical examination showed a deficient restoration of element 21, with overcontouring, disharmonious color, and caries infiltration; small cervical fracture in element 11, restored with excess composite resin; element 22 with inclination of the distal surface toward the palatal region; absence of proportion between the cervico-incisal size of upper central and lateral incisors and inadequate gingival contour; and presence of bacterial plaque and dental calculus, especially in the lingual aspect of lower incisors (Figure 1A).

Initially, instructions were provided on oral hygiene and adequacy of the oral environment, which included supragingival scaling with periodontal curettes (Hu-Friedy Mfg.Co, LLC3232 N. Rockwell St.Chicago) and prophylaxis with Robinson brush (Microdont Micro Usinagem de Precisão Ltda, SP, Brazil) and prophylactic paste (Herjos 90G Tutti Frutti – RJ- Brazil).

Next, gingivectomy was performed from element 12 to element 22 to improve the gingival contour, considering that central incisors presented small cervico-incisal size relative to lateral incisors and canines. The surgical technique selected was external bevel gingivectomy (16,17), with the purpose of recontouring the lining tissues. The periodontal pocket depth was assessed with a millimeter bur (Hu-Friedy Produtos para Saúde Ltda - Rio de Janeiro - RJ - Brazil) followed by an external bevel and intrasulcular incision with a scalpel blade (Maxicor - Paraná - Brazil). The incised area was removed with a Gracey periodontal curette (Golgran 2013 Desenvolvimento N2 Mídia - SP - Brazil) and the tooth surface exposed was subjected to scaling and flattening (Figure 1B). There was no suture or placement of surgical cement, therefore allowing a second-intention healing.

After two weeks, the composite resin restoration of element 21 was removed, considering the presence of overcontouring and caries infiltration. After removing the caries and the restoration, little remaining tooth structure was verified (Figure 1C). The post was made of fiberglass composite and epoxy resin, featuring high mechanical strength, double taper, radiopacity and aesthetics. In anterior teeth, the indication is determined for 50% loss of structure coronary. For stabilization of the coronary reconstruction, the post occupied two thirds of the length of the dental remnant. Proper endodontic treatment allowed the absolute isolation of the element, preparation of the conduit by removing the gutta-percha with a 0.5 Largo bur (Microdont Micro Usinagem de Precisão Ltda - SP - Brazil) for cementing a prefabricated 0.5 White Post fiberglass post (FGM Produtos Odontológicos – SC – Brazil) previously performed cleaning with alcohol and silanized with Prosil (FGM Produtos Odontológicos - SC – Brazil). After 60s and with a short air blast, excess silane is removed. The post was cemented with RelyX U 200 self-adhesive resin cement (3M Brasil - SP - Brazil) (Figure 1D). The excess fiberglass post was cut with a #4 spherical diamond bur (Microdont Micro Usinagem de Precisão - SP - Brazil) and the final restoration was performed with an Opallis composite resin (FGM Produtos Odontológicos - SC – Brazil) translucent in the palatal region (Figure 1E), opaque in the incisal region, and A3 and D3 in the buccal region by the stratification method (Figure 1F), with posterior finishing and polishing.

The same session included the selection of the prefabricated aesthetic veneers (Brilliant NG Componeer - Coltene) of incisal resin by size and translucency, whereas size L opaque bleach was chosen. Next, elements 11, 12, 21, and 22 were prepared with a light bevel on the buccal aspect with a 4138 bur (Microdont Micro Usinagem de Precisão - SP - Brazil) to reduce the convexity until fitting the veneers



***Figure 1**: (A) Initial photograph; (B) Periodontal surgery of gingival recontouring of elements 12 to 22; (C) Removal of the deficient restoration of element 21; (D) Cementation of prefabricated 0.5 White Post fiberglass post (FGM, Brazil); (E) Performance of adhesive system and application of a thin layer of Opallis translucent composite resin (FGM, Brazil) per palatal region; (F) Final restoration with Opallis A3 and D3 composite resin (FGM, Brazil) by the stratification method; (G) Preparation of elements 11, 12, 21, and 22 with light bevel on the buccal aspect with a 4138 bur (Microdont, Brazil); and (H) Preparation of veneers with 37% phosphoric acid etching.*

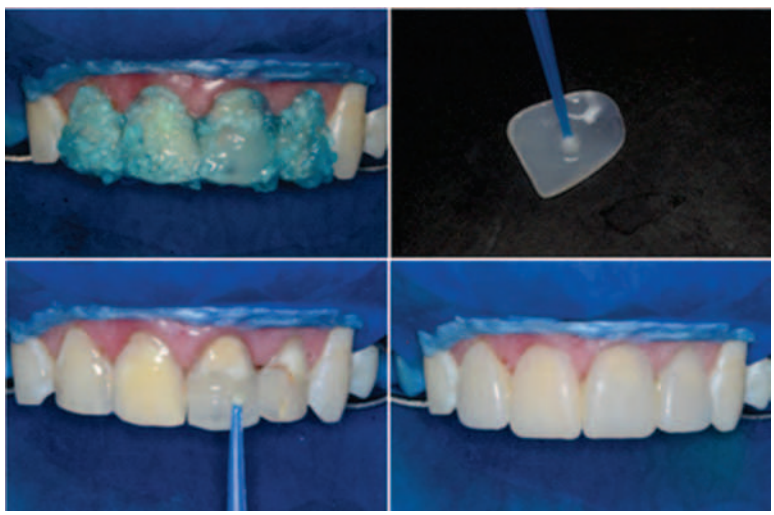

***Figure 2**: (A) 37% phosphoric acid etching with Condac 37 - Dentscare (FGM, Brazil); (B) Preparation of veneers with active application of Adper Single Bond II adhesive (3M, Brazil); (C) Active application of conventional adhesive of two steps (3M, Brazil) and light curing and (D) Thin layer of Opallis composite resin applied on the buccal aspect of teeth, followed by the positioning of veneers with mild pressure and light curing.*



***Figure 3**: Final photograph.*

(Figure 1G). The teeth and veneers were etched with 37% phosphoric acid (Condac FGM Produtos Odontológicos - SC – Brazil) (Figures 1H and 2A). Washing was performed with water blast for 20 s and, after removal, the tooth surface was briefly air dried. A conventional adhesive system (One Coat Bond SL – Coltene) of two steps with water base that does not change the physical conditions of the veneers was used. It was applied with a microbrush (Figure 2B) followed by light curing for 20 s, according to the manufacturer's instructions. Brilliant NG resin color scale was used (Brilliant NG Componeer - Coltene) for color selection of resin for cementation of facets. A thin layer of Opallis flow composite resin (high mechanical strength and low viscosity) (FGM Produtos Odontológicos - SC – Brazil) was placed on the buccal aspect of teeth and the veneer was pressed over this resin and later light cured for 40 s with Bluephase G2 (Ivoclar/Vivadent - Liechtenstein) on all surfaces (Figure 2C). The excess resin was removed with a composite resin spatula. Each tooth was individually prepared and cemented to control the removal of excess cementing material. The palatal surfaces of teeth were filled with composite resin and the canine guide was set for tooth 13 in the incisal region by placing Opallis A3 composite resin (FGM Produtos Odontológicos - SC – Brazil) and later finishing and polishing (Figures 2D and Figure 3).

DISCUSSION

The unbalance of smile harmony is seen as a determinant factor for facial harmony. Several factors may produce problems that affect oral aesthetics, including dental traumas, caries, frequent consumption of pigmented foods, tooth malpositioning, among others.[5,6,7]

In order to reach excellent functional and aesthetic results, considering the gingival level and smile line were not satisfactory in the present report, a multidisciplinary approach is required to re-establish harmony between tooth structure and the gingiva. Therefore, gingivectomy is required to extend the length of clinical crowns of anterior teeth and to a harmonious gingival contour.[8]

Ceramic laminates have been considered the gold standard for restoring anterior teeth, but a less invasive preparation is needed.[9] They show excellent properties such as biocompatibility and aesthetics. However, their mechanical limitations such as fragility, low fracture toughness, low stress, and the flexural strength and wear caused on antagonist teeth have been described as potential disadvantages.[10]

The use of prefabricated composite resin veneers has been the aesthetic solution mostly used to elongate anterior teeth, correct malpositioning, close diastemas, and mask discolorations in devitalized teeth, also restoring fractured teeth, extensive caries lesions, congenital malformations, and fluorosis.[11,12,13,14]

These veneers present the advantage of a low elasticity modulus and a higher ability to absorb functional loads when compared to porcelain veneers,[15,16] and they are more viable economically. As for ceramic veneers, they favor the preservation of structure and allow easy color selection.[17] Such technique provides shorter clinical time and lower cost also when compared to direct composite resin veneers.

This model of veneers is available in small, medium, large, and extra-large sizes, and the veneer closest to the size of the tooth in question is selected. Some adjustments may be required by wearing the piece.[17] Marginal and

superficial discoloration problems have been reported over time. Another disadvantage is the difficulty for selecting the correct opacifying resin when masking the unwanted color of the dental element is required.[18] As a solution, thin layer of opaque resin, dispersed with the aid of non-adhesive microbush to evaluate naturalness compared to tooth color.

The composite veneers are formed with thin layers that are polymerized under controlled light, heat, and pressure, providing greater durability and aesthetics. The probability of failure of restorations of composite resin veneers was not significantly different from the ceramic restorations.[18] Perdigão *et al.* reported that prefabricated veneers resulted in a mechanical strength statistically similar to IPS E.max Press (Ivoclar, Vivadent, Schaan, Liechtenstein), but further studies assessing the survival of this type of material are required.[19]

As related by Dietschi *et al.*, prefabricated veneers present reduction of polymerization shrinkage, superior mechanical properties compared to direct resin, decreasing gap, postoperative hypersensitivity and microleakage. Besides that, direct composite resin restorations present some limitations such as the difficulties of color match and surface polishing. However, further *in vivo* studies are needed to assess the potentiality of prefabricated veneers.

CONCLUSION

In this case report, the clinical use of prefabricated resin veneers in the aesthetic dental was considered success because is a technique that preserves the dental structure, fast and low cost.

REFERENCES

1. Korkut B, Yanýkoglu F, Günday M. Direct composite laminate veneers: Three case reports. J Dent Res Dent Clin Dent Prospects. 2013;7(2):105–111.

2. Abu Arqoub SH, Al-Khateeb SN. Perception of facial profile attractiveness of different antero-posterior and vertical proportions. Eur J Orthod. 2011; 33(1):103-11.

3.Kumar A, Kumar V, Singh J, Hooda A, Dutta S: Drug-induced discoloration of teeth: An updated review. Clin Pediatr. 2012; 51(2):181–185.

4.Nguyen JF, Migonney V, Ruse ND, Sadoun M. Resin composite blocks via high-pressure high-temperature polymerization. Dent Mater. 2012; 28(5):529-534.

5.Al-Zarea BK. Satisfaction with appearance and the desired treatment to improve aesthetics. Int J Dent. 2013; 2013:1-7.

6.Anchieta RB, Rocha EP, Watanabe MU, de Almeida EO, Freitas-Junior AC, Martini AP, Barioni SR. Recovering the function and esthetics of fractured teeth using several restorative cosmetic approaches. Three clinical cases. Dent Traumatol. 2011;28:166–172.

7.DiAngelis AJ, Andreasen JO, Ebeleseder KA, Kenny DJ, Trope M, Sigurdsson A, Andersson L, Bourguignon C, Flores MT, Hicks ML, Lenzi AR, Malmgren B, Moule AJ, Pohl Y, Tsukiboshi M . International Association of Dental Traumatology guidelines for the management of traumatic dental injuries: 1. Fractures and luxations of permanent teeth. Dent Traumatol. 2012; 28:2–12.

8.Pinto RC, Chambrone L, Colombini BL, Ishikiriama SK, Britto IM, Romito G. A. Minimally invasive esthetic therapy: a case report describing the advantages of a multidisciplinary approach. Quintessence Int. 2013; 44(5):385-391.

9.Kamal V, Mahesh GE, Parag D. Esthetic smile designing with porcelain laminates – a case report. Journal of Pierre Fauchard Academy. 2014; 28:100-103.

10.Gomes G, Perdigao J. Prefabricated composite resin veneers – A clinical review. J Esthet Restor Dent. 2014; 26(5):302-313.

11.Dietschi D, Devigus A. Pre-fabricated composite veneers: Historical perspectives, indications and clinical application. Eur J Esthet Dent. 2011; 6:178–87.

12.Du Toit J, Patel N. Montalli V, Jain S. Aesthetic treatment of severely fluorosed teeth with prefabricated composite veneers: a case report. IntDentistry South Africa. 2012;2(6):44-50.

13.Bhatt A, Gupta V. Componeer- A case study. Update Dental College Journal. 2016; 6(1):40-42.

14.Migliau G, Besharat LK, Sofan AAA, Sofan EAA, Romeo U. Endo-restorative treatment of a severely discolored upper incisor: resolution of the “aesthetic” problem through Componeer veneering System. Ann Stomatol. 2016;12(3-4):113-8.

15.Gargari M, Ceruso FM, Pujia A, Prete V. Restoration of anterior teeth using an indirect composite technique. Oral Implantol. 2014;6(4):99-102.

16.D‘Sousa DSJ, Kumar M. Esthetics and biocompatibility of composite dental laminates. Med J Armed Forces India. 2010;66(3):239-43.

17.Magne P, Stanley K, Schlichting LH. Modeling of ultrathin occlusal veneers. Dent Mater. 2012;28(7):777-82.

18.Gurtu A, Bansal R, Chowdhary P, Mehrotra N, Mohan S, Mehrotra A, Kishore A. Componeer: An emerging esthetic solution. J Dent Sci Oral Rehab. 2016;7(3):146-148.

19.Perdigão J, Sezinando A, Muñoz MA, et al. Prefabricated veneers—bond strengths and ultramorphological analyses. J Adhes Dent. 2014;16(2):137–46.