OROFACIAL FINDINGS AND DENTAL CARE MANAGEMENT IN A PATIENT WITH ROBINOW SYNDROME

Marina Fernandes **Sena**,[1] Paôla Caroline da Silva **Mira**,[1] Thais Tedeschi dos **Santos**,[1] Carolina Paes **Torres,**[1] Francisco Wanderley Garcia **Paula-Silva**,[1]* Fábio Lourenço **Romano**,[1] Sandra Maria Garcia da **Silveira**,[1] Karina. Mayra de Queiroz **Brito**,[1] Alexandra Mussolino de **Queiroz**,[1]

[1]Department of Children's Clinic, School of Pediatric Dentistry of Ribeirão Preto-USP, Ribeirão Preto, SP, Brazil.

Palavras-chave: Síndrome de Robinow. Crianças com Deficiência. Atendimento Odontológico.

RESUMO

Introdução: A síndrome de Robinow é uma doença genética rara caracterizada por baixa estatura, dismorfismos faciais e anomalias orodentais, genitália subdesenvolvida e falhas no desenvolvimento esquelético. **Relato de Caso:** Uma paciente de 6 anos com Síndrome de Robinow foi encaminhada ao Centro de Formação de Recursos Humanos Especializado no Atendimento Odontológicode Pacientes com Necessidades Especiais (Ribeirão Preto, São Paulo, Brasil).Na investigação da história médica e ao exame clínico foram observados baixa estatura, dismorfismo facial e genitália hipoplásica. Os achados orofaciais mostraram retrognatismo, hemangioma de linha média de aproximadamente 1 cm de largura com bordas voltadas para cima, língua bífida, anquiloglossia, hipertrofia gengival geral, mordida profunda e apinhamento dentário leve. A anormalidade cardíaca e o atraso no desenvolvimento neuromotor demandaram cuidados individualizados. O tratamento odontológico consistiu em procedimentos preventivos e restauradores para adequar a condição de saúde bucal da paciente. Além disso, foi realizada avaliação ortodôntica e planejamento do tratamento. A paciente está em acompanhamento há seis anos. **Conclusão**: Anomalias orofaciais e outras alterações encontradas no presente caso contribuíram para complementar os achados orofaciais na literatura e auxiliar no diagnóstico da síndrome. Neste caso, um plano de tratamento integral e equipe multiprofissional foram essenciais para resgatar a saúde bucal e propiciar melhor qualidade de vida à paciente.

Keywords: Robinow Syndrome. Disabled Children. Dental Care.

ABSTRACT

Introduction: Robinow syndrome is a rare genetic disorder of skeletal development. It is characterized by short stature, facial dysmorphisms and orodental anomalies, underdeveloped genitalia, mesomelic brachymelia. **Case Report**: A 6 year old girl with Robinow Syndrome was referred in the Center for Formation of Human Resources Specialized in Dental Care to Special Needs Patients (Ribeirão Preto, São Paulo, Brazil) for evaluation. Medical history investigation and clinical examination were observed in short stature, facial dimorphism and hypoplastic genitalia. Orofacial findings showed retrognathism, a mid-line hemangioma approximately 1 cm wide with upturned borders, bifid tongue, ankyloglossia, general gingival hypertrophy, deep bite and mild tooth crowding. Cardiac abnormality and neuromotor developmental delay consisted of systemic manifestations present which demanded individualized dental care. The dental treatment consisted of preventive and restoratives procedures to adequate the oral health condition of the patient and orthodontic treatmentwas planned. The patient has been in follow-up for six years. **Conclusion**: Orofacial anomalies and other alterations found in the present case contributed to complement the orofacial findings described in the literature and to assist in diagnosis of the syndrome. In this case, amultiprofessional team and integral treatment were essential to rescue oral health and improvelife quality of the patient.

Submitted: July 2, 2019
Modification: September 16, 2019
Accepted: September 17, 2019

***Correspondence to:**
Francisco Wanderley Garcia Paula-Silva
Address: Faculdade de Odontologia de Ribeirão Preto da Universidade de São Paulo. Avenida do Café, s/n. Ribeirão Preto. SP. Brazil. Zip code: 14040-904.
Telephone number: 55 (16) 3315-3995.
E-mail: franciscogarcia@forp.usp.br

INTRODUCTION

Robinow syndrome (RS) was first described in 1969 by Robinowet al.(1969).[1] Epidemiological data indicate occurrence in approximately 1:500,000 births with no gender predilection.[2] Researchers have identified two types of RS, which are distinguished by their patterns of inheritance and the severity of their signs and symptoms: autosomal dominant (OMIM #180700)[3] and autosomal recessive (OMIM #268310).[4] The diagnosis of RS is based mainly on the observation of typical clinical features like short stature, facial dysmorphisms and hypoplastic genitalia.[5]

Patients with RS present several craniofacial and orodental alterations such as frontal bossing, bulging or wide forehead, midfacial hypoplasia, hypertelorism, gingival hypertrophy, micrognathia, retrognathia, missing teeth, bilobed tongue tip. [6,7-10] The signs of both types of RS are similar, but tend to be more severe in the autosomal recessive form, including a more evident dwarfism and typical vertebral and rib segmentation anomalies, such as hemivertebrae with fused ribs leading to kyphoscoliosis. [11-15] Craniofacial findings are more significant in the recessive form whereas orodental features are more common in the dominant form.[16]

The prognosis of RS is unfavorable, especially for the patients with heart problems.[7] The treatment includes surgeries for treating hernias, vertebral anomalies and scoliosis, orthodontic procedures for correction of dental malocclusions, face reconstruction, psychotherapy and even growth hormone therapy in some cases.[17]

This report presents the case of a pediatric patient diagnosed with RS. The clinical features are described, with emphasis on the orodental findings and dental treatment performed in an outpatient dental service.

CASE REPORT

A 6-year-old female child was referred for general dental treatment at the Center for Formation of Human Resources Specialized in Dental Care to Special Needs Patients, School of Dentistry of Ribeirão Preto, University of São Paulo, Brazil.

During the clinical interview, the mother revealed uneventful pregnancy, with normal ultrasound scans and results to laboratory tests within normal ranges. Between the third and fourth months the mother used procaine benzylpenicillin, dimenhydrinate and *sodium* dipyrone. She smoked one pack of cigarettes per day and was under continuous use of ranitidine hydrochloride. The child was born at term by cesarean delivery weighing 2,860 g and measuring 44 cm, with 34 cm cephalic perimeter and 5/9 Apgar score. The parents were healthy and non-consanguineous, and both were 30-year-old at the time of conception. There was no similar case in the family.

According to the medical history, the child had delayed neuromotor development, at 6 months, the child underwent surgical closure of the patent ductus arteriosus. The child had normal karyotype of 46 XX, and showed underdeveloped genitalia, focus of left parietal demyelination and discrete signs of cerebellum atrophy and moderate bilateral hearing loss.

Thus, general clinical examination revealed mesomelic shortening of the upper limbs, with small hands, strong ligament laxity, muscular hypotonia, brachycephaly, bilateral clinodactyly of the fifth fingers, and transversal palmar crease on the right hand (Figure 1A, 1B, 1C).

The craniofacial and orodental characteristics revealed very dispersed hair, low-set ears, frontal bossing, shallow eyebrows, “fetal face”, square nose tip, wide nose bottom, erased philtrum, thin lips, triangle-shaped mouth, retrognathism, a mid-line hemangioma approximately 1 cm wide with upturned borders, bifid tongue, ankyloglossia, general gingival hypertrophy, deep bite and mild tooth crowding (Figure 1B, 1D, 1E, 1F).

Initial radiographic examinations revealed early tooth losses due to the extensive carious lesions (Figure 2A). A panoramic radiograph showed the presence of all permanent teeth, supernumerary tooth in the region of the tooth 17 and the upper and lower third molar undergoing coronary formation (Figure 2B). Also, in the oral examination, the patient presented inflammation gingival and accumulation of biofilm in the upper and lower dental arch.

A two-phase treatment was planned for this case. In the first phase, preventive measures were applied.[18] The second phase was surgical and restorative. Teeth 64, 71, 74 and 81 were not restorable and were extracted. Teeth 16, 26, 62, 63, 75 and 85 were restored.

Due to the patient’s heart problems, a prophylactic antibiotic regimen was prescribed prior to the dental procedures, with 50 mg of Amoxilin per kg body weight taken 1 hour before the procedure. [19]

There was moderate mental retardation associated with uncooperative behavior. After a few modulating sessions employing the basic behavior guidance, [20] physical restraint measures were used after parental consent by signing the consent form.

After completion of the dental treatment, the patient was referred to orthodontic treatment, which it is in initial phase. The diagnosis and treatment orthodontic plan were performed after the clinical examination and documentation orthodontic analysis. By analyzing facial features, the patient

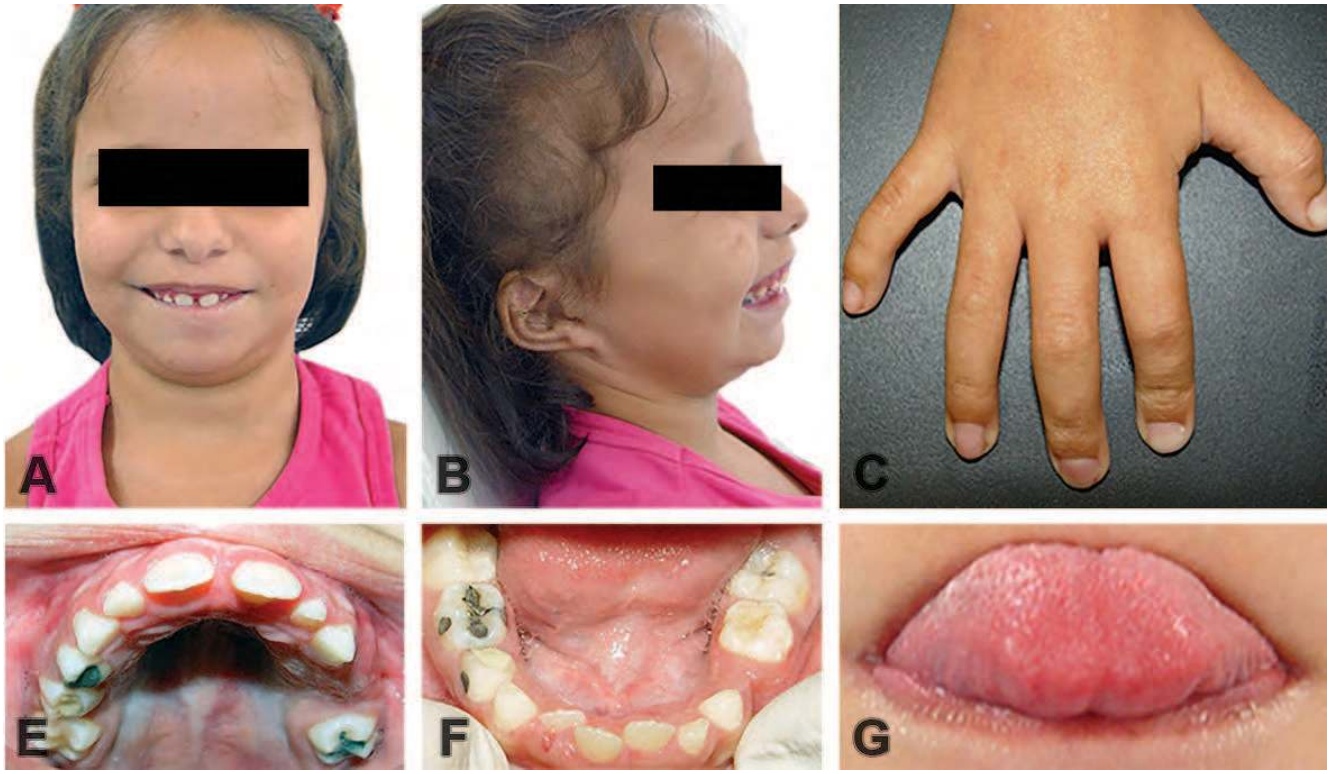

***Figure 1**: Patient at 6-year-old during treatment. (A) Frontal view of the patient. (B) Lateral view of the patient where it can be observed low-set ears, frontal bossing, and retrognathism. (C) Bilateral clinodactyly of the fifth fingers. (D) Intra-oral view where it can be observed high palate. (E) Presence of mild tooth crowding. (F) Presence of mild ankyloglossia.*

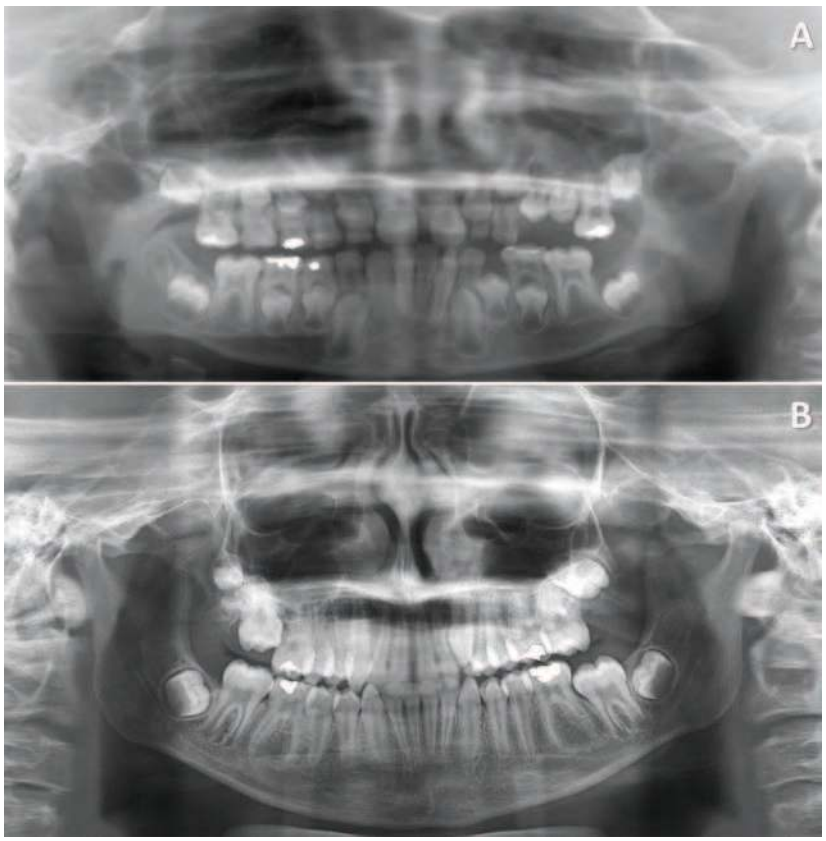

***Figure 2**: (A) Patient at 7-year-old, initial radiographic examination. (B) Patient at 11-year-old, actual radiographic examination.*

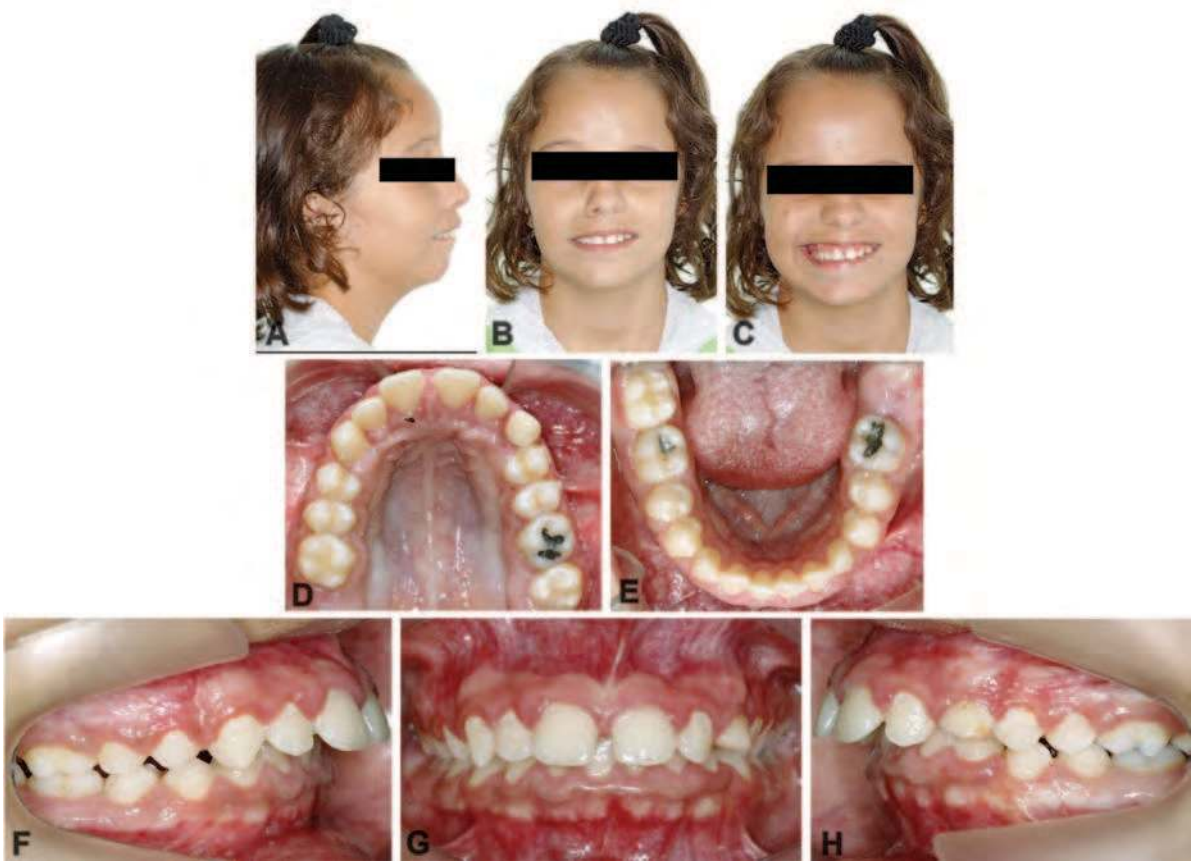

***Figure 3**: Patient at 11-year-old. (A) Lateral view of the patient with the presence of lower third increased, convex profile, nasolabial acute angle, decreased chin-neck line, absence of lip seal. (B) Frontal view of the patient which it can be observed facial assymmetric. (C) Frontal view of the patient which it can be observed facial asymmetric while smiling. (D) Maxillary arch. (E) Mandibular arch. (F), (G) and (H) Malocclusion Class II, Angle division 1 deep overbite, overjet of 7 mm, coincident upper midline and lower midline 1 mm deviated to the left, gingival hypertrophy.*

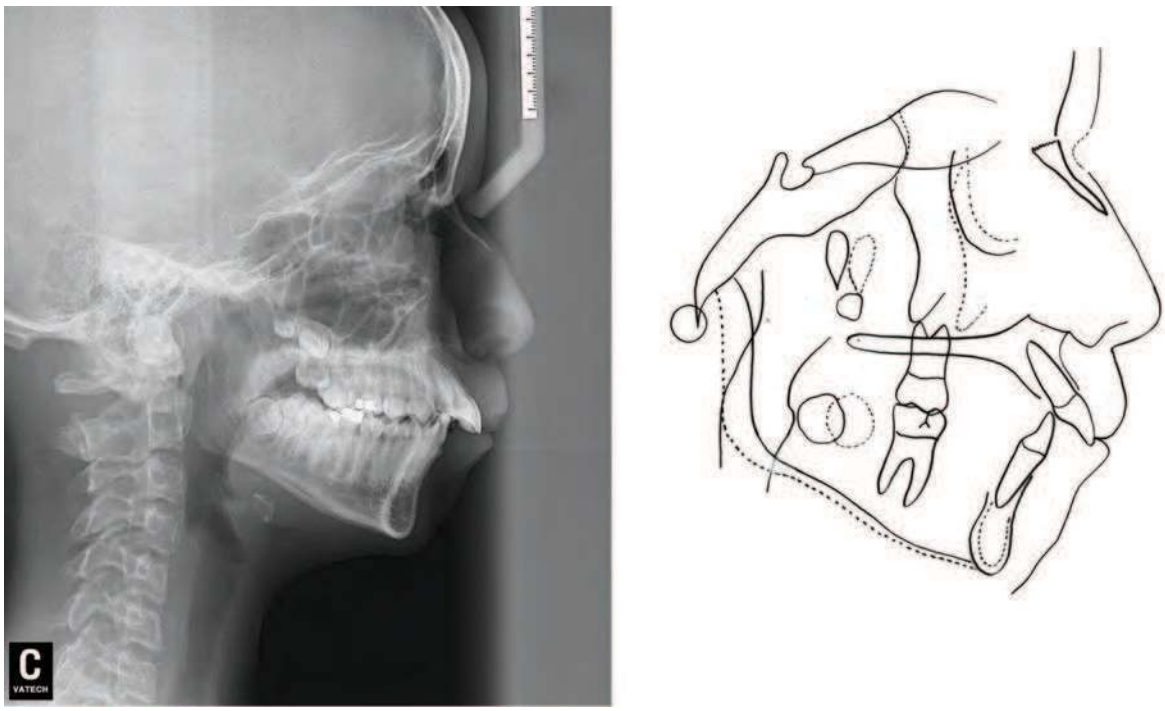

***Figure 4**: Patient at 11-year-old. (A) Lateral teleradiographic examination. (B) Cephalometric analysis.*

***Table 1**: Craniofacial and orodental manifestations: bibliographic survey*

Craniofacial	Orodental
Frontal bossing[2, 8, 18, 28, 29, 33]	Triangular mouth (bottom corners face downward)[16, 28, 29, 33]
Bulging or wide forehead [16, 17, 28, 33]	Broad mout[8]
Hemangioma[8, 16]	High palate [8, 10, 11, 28, 29]
Flat facial profile with large head (macrocephaly not necessarily associated with hydrocephaly)[16, 28]	Long/short philtrum (tented upper lip, inverted "V" philtrum)[2, 8, 11, 16, 17, 25]
Midfacial hypoplasia [9, 10, 28, 29]	Dental abnormalities, misaligned teeth (crowded, missing teeth) [2, 9, 10, 11, 17, 18, 28, 29, 33]
Hypertelorism [2, 8, 16, 17, 25, 28, 29, 33]	Gingival hypertrophy [8-11, 16, 17, 28]
Wide palpebral fissures[7]	Abnormal uvula (heart shaped) [7, 9, 28]
Downslanting palpebral fissures[7, 29]	Absent uvula[16]
Lower lid deficiency (pseudoexophthalmos)[7]	Cleft lip/palate (non midline) [2, 8, 16, 33]
Ear abnormality, small and lower set [8, 17, 29]	Bifid tongue (bilobed tongue tip)[10, 16,18, 28, 29]
Right pre-auricular pit[16]	Ankyloglossia[9, 10, 16, 28, 29]
Micrognathia [8-10, 29]	Microdontia[8]
Retrognathia [11, 18]	Crowded tooth buds[8]
Prominent eyes with bilateral proptosis [2, 8, 11, 16, 18, 28, 29, 33]	Delayed tooth eruption and exfoliation[10, 16, 18, 28, 29]
Epicanthal folds [2, 11]	Short roots primary molars[16]
Flat-saddle nose[8]	Trapezoid maxillary arch[16]
Upturned nose with depressed nasal bridge[11, 16, 18, 28, 29, 33]	Narrow and thick-floored pulp chambers[16]
Short nose [2, 18, 25, 28]	Down-slanted mouth corners[2, 11]
Broad nasal bridge[16, 18, 25]	Thin upper lip [11]
Anteverted nares [17, 18, 25, 28, 29]	Supernumerary teeth[11]
Macrocephaly [11, 20, 28, 29]	
Posteriorly rotated ears [2, 18, 25]	

presented lower third increased, convex profile, nasolabial acute angle, decreased chin-neck line, absence of lip seal and facial asymmetric (Figure 3A, 3B, 3C).

At that time, the patient was in the mixed dentition (Figure 3D and 3E) and dental pattern revealsed malocclusion Class II, Angle division 1, deep overbite, overjet of 7 mm, coincident upper midline and lower midline 1 mm deviated to the left (Figure 3F, 3G, 3H).

In cephalometric analysis (Figure 4) in the horizontal plane was possible to verify that the maxilla (SNA = 82 °) was well positioned and mandible (SNB = 73 °) retruded in relation to the anterior cranial base, showing an skeletal malocclusion class II (ANB = 8º). In the vertical plane the patient had a predominance of mesofacial vertical growth and morphological type (SNGoGn = 41 °, NSGn = 70 °, Facial axis = 89 °). The upper and lower incisors were protruded (1-NA = 7mm, 1-NB = 6mm) and axial inclination increased (1.NA = 32 °, 1.NB = 26 °).

The patient was referred to extraction of the supernumerary tooth after complete eruption and root formation of the permanent maxillary right second molar. Orthodontic treatment was performed in two phases. In the first phase, Kloehn headgear was adapted with a parietal traction (high) of 500 gf in each side. The use of the appliance was recommended for 12 hours/day to redirect the maxillary growth and to allow an anterior mandibular growth. The time to use this appliance was of approximately 12 months.

FOLLOW-UP

During puberty, parents were informed about the importance of collaboration for the success of orthodontic treatment, especially during the period of growth. Unfortunately, the parents reported that they could not collaborate and that orthodontic treatment should be interrupted without the corrective phase.

The patient still remains in follow-up, as the child was considered a high-caries-risk patient after completion of the restorative phase. Additionally, supervision of oral homecare

by the parents was strongly recommended and gingival hypertrophy was not surgically treated because alteration was not severe.

DISCUSSION

RS features can be identified at birth and by ultrasound examination, starting at 19 weeks of gestation.[9] The patient of this case was diagnosed with the recessive form of RS, based on her postnatal characteristics. [10-12, 20-22] Although parental consanguinity has an important role in RS etiology,[7] the patient in this case was born to a non-consanguineous couple.

Congenital heart problems are a common finding in individuals with RS, accounting to 16% of the cases reported in the literature and 5 to 10% of the children with RS die prematurely due to heart problems. [1,6,23-25] The patients with RS requires reduction of anxiety (usually evoked by dental treatment) as well as maintenance of adequate oral conditions without infectious foci and administration of prophylactic antibiotics prior to dental procedures for prevention of bacterial endocarditis[14] and supervision of oral homecare for parents.

The patient presented mental retardation, even though normal intelligence is reported in most cases. [8-10, 13, 26-28] The neuropsychomotor condition of the patient was an important issue during the dental treatment because she presented unpredictable oscillations of mood, poor understanding of instructions and resistive behavior that are common to individuals with mental retardation.

After a few modulating sessions using resources of behavior management, the patient became more cooperative with dental staff, allowing the treatment without need of sedation or general anesthesia, thus eliminating the risks inherent to general anesthesia procedures and hospital infection, which are increased in patients with cardiovascular problems. In addition, the anatomic characteristics of patients with RS make intubation very difficult. [29,30]

Patients with RS present several craniofacial and orodental alterations.[12-15] In this case the syndrome was characterized by the findings that are consistent with other reports in the literature (Table 1).

Besides the orodental examination, this case report evaluated the cephalometric profile of the patient which yet there not report in the literature to Robinow syndrome. The detection of occlusal alterations is important to execute the planning of orthodontic treatment in earlier phase because the improvement in facial appearance in syndromic children is gradually reduced with growth.[31] Further studies are needed to describe the differences in frequency and severity of craniofacial and orodental features and between dominant and recessive forms to be used as clinical pattern in the characterization of the forms of Robinow Syndrome.[16,32] In this way, it is very important that the dentists describe in detail the craniofacial and orodental findings and to assist in diagnosis in this syndrome, because the facial features are more pronounced in younger subjects than adults.[16] The dental treatment requires that the dentist to be familiar with RS features, as well the performance of integral treatment and multiprofessional team is essential to promote a better life quality to these patients.

Orofacial anomalies and other alterations presented in this case contributed to the orofacial findings described in the literature for diagnosis of Robinow syndrome. In this case, a multiprofessional team and integral treatment were essential to rescue oral health and improve life quality of the patient.

REFERENCES

1. Robinow M, Silverman FN, Smith HD. A newly recognised dwarfing syndrome. Am J Dis Child 1969;117: 645–51.
2. Hosalkar HS, Gerardi J, Shaw BA. Robinow syndrome. J Postgrad Med 2002; 48: 50-1.
3. OMIM #180700 [n.d.] Robinow syndrome, autosomal dominant [Internet], Online Mendelian Inheritance in Man. Available from: <http://omim.org/entry/180700> [Accessed July 18 2012].
4. OMIM #268310 [n.d.] Robinow syndrome, autosomal recessive [Internet], Online Mendelian inheritance in man. Available from: <http://omim.org/entry/268310> [Accessed July 18 2012].
5. Robinow M. The Robinow (fetal face) syndrome: a continuing puzzle. Clin Dysmorphol 1993; 2:189-98.
6. Robinow, M. Robinow syndrome. In: Buyse ML (eds): Birth defects encyclopedia. Massachusetts: Blackwell Scientific Publications; 1990; 1499-1500.
7. Patton MA, Afzal AR. Robinow syndrome. J Med Genet 2002;39:305–310.
8. Al Kaissi A, Bieganski T, Baranska D, Chehida FB, Gharbi H, Ghachem MB, Hendaoui L et al. Robinow syndrome: report of two cases and review of the literature. Australas Radiol 2007; 51:83-86.
9. Grothe R, Anderson-Cermin C, Beiraghi S. Autosomal Recessive Robinow Syndrome: A Case Report. J Dent Child 2008; 75: 48-54.
10. Cerqueira DF, Souza IPR. Orofacial manifestations of Robinow's Syndrome: a case report in pediatric patient. Oral Surg Oral Med Oral Pathol Oral Radiol Endod 2008; 105:353-7.
11. Mazzeu JF, Pardono E, Vianna-Morgante AM, Richieri-Costa A, Ae Kim C, Brunoni D et al. Clinical characterization of autosomal dominant and recessive variants of Robinow syndrome. Am J Med Genet A 2007; 143: 320-325.
12. Castells S, Chakurkar A, Qazi Q, Bastian W. Robinow syndrome with growth hormone deficiency: treatment with growth hormone. J Pediatr Endocrinol Metab 1999; 12:565-71.

13. American Academy of Pediatric Dentistry. Guideline on caries-risk asse ssment and management for infants, children, and adolescents. Pediatr Dent 2010-2011; 31(6): 179-86.
14. Wilson W, Taubert KA, Gewitz M, Lockhart PB, Baddour LM, Levison M et al. Prevention of infective endocarditis: guidelines from the American Heart Association: a guideline from the American Heart Association Rheumatic Fever, Endocarditis, and Kawasaki Disease Committee, Council on Cardiovascular Disease in the Young, and the Council on Clinical Cardiology, Council on Cardiovascular Surgery and Anesthesia, and the Quality of Care and Outcomes Research Interdisciplinary Working Group. Circulation 2007; 116: 1736-1754.
15. American Academy of Pediatric Dentistry. Guideline on Management of Dental Patients with Special Health Care Needs Pediatr Dent 2016-2017; 38(6): 107-1.
16. Kantaputra PN, Gorlin RJ, Ukarapol N et al. Robinow (Fetal Face) Syndrome: Report of a boy with Dominant Type and an Infant With Recessive Type. Am J Med Genet 1999; 84:1-7.
17. Suresh SS. Robinow Syndrome. Indian J Orthop. 2010; 42:474-6.
18. Roifman M, Brunner H, Lohr J, et al. Autosomal Dominant Robinow Syndrome. 2015 Jan 8 [Updated 2018 Aug 9]. In: Adam MP, Ardinger HH, Pagon RA, et al., editors. GeneReviews® [Internet]. Seattle (WA): University of Washington, Seattle; 1993-2019.
19. Atalay S, Ege B, Imamoðlu A, Suskan E, Ocal B, Gümüþ H. Congenital heart disease and Robinow syndrome. Clin Dysmorphol 1993; 3: 208-210.
20. Sabry MA, Ismail EA, al-Naggar RL, al-Torki NA, Farah S, al-Awadi SA, Obenbergerova D et al. Unusual traits associated with Robinow syndrome. J Med Genet 1997; 34:736–740.
21. Al-Ata J, Paquet JAM, Teebi AS. Congenital Heart Disease in Robinow Syndrome. Am J Med Genet 1998; 77:332-333.
22. Wang LY, Hsu CH, Shih SL, Lin SP. Robinow syndrome: report of one case. Chung Hua Min Kuo Hsiao Erh Ko I Hsueh Hui Tsa Chih 1997; 38: 235-238.
23. Castro S, Peraza E, Barraza A, Zapata M. Prenatal diagnosis of Robinow syndrome: a case report. J. Clin. Ultrasound 2014; 42:297-300.
24. Mishra S, Agarwalla SK, Pradhan S. Robinow Syndrome: A Rare Diagnosis. J Clin Diagn Res. 2015; 9: SD04–SD05.
25. Nagasaki K, Nishimura G, Kikuchi T, Nyuzuki H, Sasaki S, Ogawa Y el al. Nonsense mutations in FZD2 cause autosomal-dominant omodysplasia: Robinow syndrome-like phenotypes. Am J Med Genet. 2018;176A:739–742.
26. Lirk P, Rieder J, Schuerholz A, Keller C. Anaesthetic implications of Robinow syndrome. Paediatr Anaesth 2003; 13: 725-7.
27. Sleesman JB, Tobias JD. Anaesthetic implications of the child with Robinow syndrome. Paediatr Anaesth 2003; 13:629–632.
28. Basman A, Akay G, Peker I, Güngör K, Akarslan Z, Özcan S, el al. Dental management and orofacial manifestations of a patient with Robinow Syndrome. J Istanbul Univ Fac Dent 2017; 51(2):43-48.
29. Jain PS, Gupte TS, Jetpurwala AM, Dedhia SP. Robinow syndrome and fusion of primary teeth. Contemp Clin Dent 2017; 8:479-81.
30. Beiraghi S, Leon-Salazar V, Larson BE, John MT, Cunningham ML, Petryk A, Lohr JL. Craniofacial and intraoral phenotype of Robinow syndrome forms. Clin Genet 2011; 80: 15-24.
31. Gürsoy S, Hukki J, Hurmerinta K. Five year follow-up of mandibular distraction osteogenesis on the dentofacial structures of syndromic children. Orthod Craniofac Res 2008; 11: 57-64.
32. Afzal AR, Rajab A, Fenske CD, Oldridge M, Elanko N, Ternes-Pereira E, Tüysüz B et al. Recessive Robinow syndrome, allelic to dominant brachydactyly type B, is caused by mutation of ROR2. Nat Genet 2000; 25:419-22.
33. Kargi E, Acun C, Tomaç N, Savranlar A, Dursun A, Babuccu O. Midline cleft of the lower lip associated with Robinow syndrome. Scand J Plast Reconstr Surg Hand Surg 2004; 38:361-4.