THE DENTIST AS A CHILD ABUSE INFORMER: A CASE REPORT

Ana Lúcia **Vollú**[1], Marta Lua P.W. **Almeida**[2], Maria de Fátima C. **Vasconcelos**[2], Cláudia M. **Gomes**[2], Roberto Braga de C. **Vianna**[1], Fernanda **Barja-Fidalgo**[1,3], Andréa **Fonseca-Gonçalves**[1*]

[1] Departamento de Odontopediatria e Ortodontia, Faculdade de Odontologia, Universidade Federal do Rio de Janeiro.
[2] Departamento de Pós-Graduação, Faculdade de Odontologia, Universidade Veiga de Almeida (UVA).
[3] Departamento de Odontologia Preventiva e Comunitária, Faculdade de Odontologia, Universidade do Estado do Rio de Janeiro.

Palavras-chave: Maus-tratos Infantis. Violência Doméstica. Odontopediatria.

RESUMO

Introdução: A violência doméstica contra as crianças interfere no seu desenvolvimento psicológico, levando a sequelas que se manifestam e persistem até a idade adulta. A evidência física da violência doméstica é facilmente observada no complexo orofacial e, eventualmente, é detectada pelos dentistas. **Relato do Caso**: Relatamos o caso de uma vítima de maus-tratos, de 9 anos de idade, que foi diagnosticada durante o tratamento odontológico. Um odontopediatra, durante as consultas de rotina, após identificar injúrias físicas (hematoma na órbita esquerda e queimaduras na mão esquerda e lábios), suspeitou tratar-se de maus tratos, levando o caso às autoridades responsáveis. A custódia da criança foi concedida à avó por uma decisão judicial, o que permitiu a recuperação da saúde e qualidade de vida. **Conclusão**: Os profissionais devem conduzir adequadamente os casos de abuso, a fim de proteger as crianças de ocorrências futuras.

Keywords: Child Abuse. Domestic Violence. Pediatric Dentistry.

ABSTRACT

Introducition: Domestic violence against children interferes in their psychological development, leading to sequels that manifest and persist up to adulthood. Physical evidence of domestic violence is easily observed in the orofacial complex and eventually becomes detected by dentists. **Case Report**: We report the case of a 9-year-old victim of maltreatment who was diagnosed during dental treatment. The existence of physical injuries (a hematoma in the left orbit and burns on the left hand and in the lips) aroused the attention of the pediatric dentistry, whose brought the case to the responsible authorities. Custody of the child was granted to the grandmother by a court decision, which enabled the recovery of health and quality of life. **Conclusion**: Professionals must properly conduct cases through complaints in order to protect children from future occurrences.

INTRODUCTION

Child maltreatment is recognized internationally as a serious public health, human rights, legal, and social problem. It is linked to other forms of violence including intimate partner violence, community violence involving young people, and suicide.[1] As stated by the World Health Organization (WHO), five subtypes can be distinguished: physical abuse; sexual abuse; neglect and negligent treatment; emotional abuse; and exploitation.[2] All types are potentially harmful to one's health, development, and dignity.[3] The prevalence of children physical abuse in Brazil is 18%, while it ranges from 12% in Europe to 26% in Easter Mediterranean region.[4] The anatomic region most affected in domestic violence against children involving physical manifestations is the face,[5] with an estimated prevalence rate of 58-85%.[6,7] Thus, it is an important region of the orofacial complex in dentistry,[7] which is examined regularly in the clinical routine. Unintentionally, dentists may face clinical signs of domestic violence on a daily basis. However, many dentists complain about the lack of training to interpret suspicious cases and report them to the authorities. Consequently, children maltreatment expands as an underreported social problem.[8] Brazilian laws determine the notification of cases of child abuse by health professionals [9]

Submitted: January 13, 2018
Modification: March 22, 2018
Accepted: March 26, 2018

*** Correspondence to:**
Professor Andréa Fonseca-Gonçalves
Rua Rodolpho Paulo Rocco 325, Cidade Universitária, Rio de Janeiro
Tel.: 55(21) 3938-2098 - e-mail: andrea.gantonio@odonto.ufrj.br

On the basis of this information and through the report of a case of child maltreatment, the aim of this paper is to provide elements that may assist dentists, especially pediatric dentists, in the diagnosis and management of child abuse cases.

CASE REPORT

A 9-year-old female leukoderma child sought the pediatric dentistry clinic of a private university in the city of Rio de Janeiro for treatment. In the anamnesis, the patient was reported to have lived with her father, stepmother, and three brothers. The mother, alcohol dependent, abandoned the child when she was a baby. The intraoral examination revealed five caries lesions in dentin of deciduous molars.

The patient always attended dental treatments with her paternal aunt, and her parents never appeared at the clinical appointments. She was a shy, withdrawn child with a sad, shy look and did not interact with the dental team. In the fourth appointment, the following lesions were observed: a hematoma in the left orbit (Figure 1) and burns on the left hand (Figure 2) and in the lips (Figure 3).



***Figure 1**: Hematoma in the left orbit.*



***Figure 2**: Burning with laceration of the epithelium in the left hand.*



***Figure 3**: Burning in the lips with loss of epithelium.*

When asked about how these injuries happened, the child reported that she had fallen off the school ladder. After a few minutes, she said that her brother kicked her eye. Not convinced with the answer, the dentist asked the pediatric dentist (coordinator of the clinic) to talk with the child. Using behavior guidance techniques[10] the coordinator achieved interaction with the child. Therefore, she felt confident and willing to report that one day, her stepmother had beaten and burned her with a hot spoon while the father was aware and conniving with the situation.

Notification of the case

After the victim's report, her aunt was questioned by the dentist if she was aware of the observed physical lesions. She was aware of the lesions but not knowledgeable about what happened. The coordinator explained the mistreatment and requested the presence of a social worker at the university, who advised the aunt to seek the Guardianship Council immediately and make a complaint.

Getting there, the Council sent the aunt to the police station for the Department of Protection of Children and Adolescents (DPCA) to record the occurrence. According to the present Brazilian legislation, the child was referred for corpus delicti exam in an appropriate institution. Them the case was referred directly to the Public Ministry, which requested the testimony of the dentist, school bus driver, and teacher. The dentist presented to authorities, the images made during the consultation as well as the dental documentation produced during the dental care of the patient. According to the school bus driver, she had observed marks on child's body, constant delays in reaching the bus, and consecutive absences to school. The teacher did not testify, but the school board sent a letter about the child, which included a drop in school performance and lack of concentration in class but made no mention of the aggressions.

In an informal report, the teacher warned the child's aunt that she had already seen marks on the child's body. Thus, the father had been called to the school, where he denied any type of aggression. The judge decided to take the necessary measures to transfer child's custody to the paternal grandmother. It has been emphasized that the testimony of the pediatric dentist was essential for the final decision.

When the child returned for dental treatment, it was possible to observe her behavioral changes. She was more expressive and was talkative, happy, and quite participative.

DISCUSSION

Craniofacial, head, face, and neck injuries occur in more than half of the cases of child abuse. Oral injuries are

usually caused by instruments such as eating utensils or bottles during forced feedings, hands, and fingers and also by scalding liquids or caustic substances.[7]

The abuse may result in contusions, burns, or lacerations of the different oral soft tissues, as well as lesions in hard tissues (fractures or displacements of teeth or bones).[7] The lips were the most common site for inflicted oral injuries, followed by the oral mucosa, teeth, gingivae, and tongue.[11] In the present case, there were burn signs in the lips caused by a hot spoon, besides a hematoma in the orbital region.

A careful and thorough intraoral and perioral examination is necessary in all cases of suspected abuse.[7] In addition, the child should be fully evaluated because the presence of lesions in other parts of the body may confirm the maltreatment. Moreover, in cases of physical abuse, it is common to find other indicators besides bodily injury. These include insensitivity to pain during clinical appointments, social isolation, low self-esteem, dejection, shyness, guilt, inattention, and incomprehension.[12] In the present case, there were bodily injuries in the child's hand, which led the professional to suspect even more of the maltreatment, and the child was shy and dejected.

Child abuse results from a complex interaction among the child, caregiver, and environmental factors. Although child physical abuse affects children of all ages, ethnicities, and sociodemographic backgrounds, particular factors in life history can increase maltreatment vulnerability.[13] In this case, we recognized some risk factors such as being an unwanted baby, the mother's abandonment; and consumption of alcohol or drugs by the mother during her pregnancy.[1,14]

In general, girls are more susceptible to sexual abuse[1] and boys are at greater risk of harsh physical punishment.[1,14] Furthermore, children with health problems and those living in families with concomitant intimate-partner violence are at greater risk.[14] In this case, the victim was a girl and only reported physical abuse. We didn't have any information about sexual abuse or concomitant violence.

Some characteristics and attitudes of the aggressor can help identify victims of abuse. Among them are the fact that persons different from the parents or guardians take the victim to the clinic, which may constitute self-incriminating behavior on the part of the agressor.[15] It's known that children are several times more likely to be victims of extreme abuse and homicide in the hands of step parents than genetic parents,[16] and one parent is usually the abuser while the other parent assumes a passive position, allowing the abuse to continue.[17] It is in accordance with the case reported since the parents never attended appointments with the child and the stepmother was the abuser while the father was conniving.

On the basis of the researched literature,[12,18,19] we compiled some indicators to help in child maltreatment identification (Figure 4). Facing the evidence, the professional in this case suspected mistreatment. Thus, using behavior guidance techniques that reduced the child's anxiety, as a "reassuring touch"[20] simultaneously with a paused voice, the professional could interact with the child and allow her to feel comfortable to tell the truth.

The procedures to be adopted by dentists in mistreatment cases are (1) documenting in detail (recording and photographs) the lesions and/or signs observed; (2) notifying the competent local authorities; and (3) being available to testify when requested. In the present case, the violence was reported by the child herself, and the aunt, who was responsible for her care during the appointments, signed the dental chart, recognizing the information provided by the dentist. The aunt was then advised by the social worker to make a formal complaint to the competent local authorities. A study[21] found that reporting a suspicion of child maltreatment is a clinical and ethical dilemma for dentists since there are contradicting professional roles, difficulties confirming suspicions of maltreatment, and perceived shortcomings in the child-protection system.[21] Besides that, a systematic review[8] that investigated the perception, knowledge, and attitude of dentists toward the detection and management of domestic violence against children cases concluded that more attention must be given to forensic education in dentistry. Usually, many dentists complain about the lack of training for detect suspicious cases and reporting them to the authorities.[22,23] Proper training is necessary to support dentists on the detection and management of pediatric patients under domestic violence.[8] In the present case, the dentist conducted the case correctly, doing her duty; that is, in specific countries such as the United States and Brazil, dentists are required by law to report suspicious cases of domestic violence against children observed in the dental practice.[8] In Brazil, the criminal code define maltreatment as the exposure to danger of life or health of a person subordinated to the causative agent, since it is under his authority, custody or surveillance for the purpose of education, teaching, treatment or custody. The obligation of the dentist to report a case of maltreatment is determined both by the Statute of the Child and the Adolescent[9] as by the Ethic Dentistry Code.[24]

It is important for health care providers to be aware that physical or sexual abuse may result in oral or dental injuries or conditions. Pediatric dentists are more likely to attend a victim of abuse; thus, they must be aware about their important role in making a trust link between the child and themselves to obtain the child's report of the

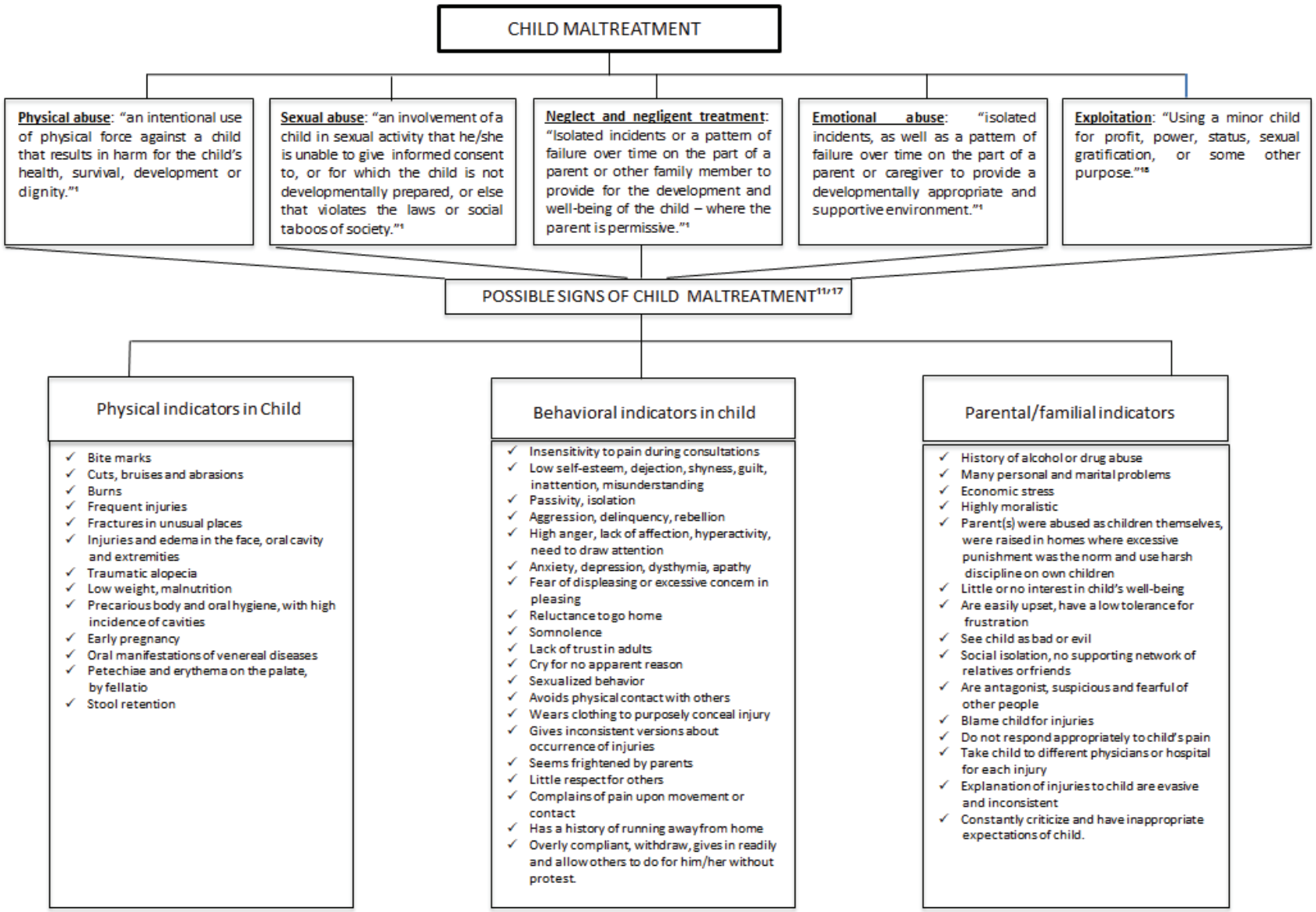

***Figure 4**: Child maltreatment definitions and possible signs.*

maltreatment and notifying the case to the authorities. Therefore, professionals protect children by breaking the cycle of violence, giving them the opportunity for better lives.

ACKNOWLEDGEMENT:

We thank the support provided by Capes and FAPERJ.

REFERENCES

1. Preventing child maltreatment: a guide to taking action and generating evidence, Md.: World Health Organization and International Society for Prevention of Child Abuse and Neglect; 2006. WHO Library Cataloguing-in-Publication Data.

2. Child maltreatment. World Health Organization. Avaiable at: "http://www.who.int/topics/child_abuse/en/" Accessed: 2017-02-08. (Archived by WebCite® at : "http://www.webcitation.org/6o8cERPEB")

3. Violence and Injury Prevention-Child Maltreatment. World Health Organization. Avaiable at: "http://www.who.int/violence_injury_prevention/violence/child/en/". Accessed: 2017-02-08. (Archived by WebCite® at "http://www.webcitation.org/6o8ckb85a")

4. Violence Info. World Health Organization. Avaiable at :http://apps.who.int/violence-info/child-maltreatment.Acessed :2018-03-01.

5. Kenney JP, McDowell JD, Spencer DE. Abuse and violence. In: Senn DR, Weems RA, eds. Manual of Forensic Odontology. 5th ed. Boca Raton: CRC Press; 2013: 356-374.

6. Herschaft EE, Alder ME, Ord DK, Rawson RD, Smith EE.Manual of Forensic Odontology. 4th ed. Lubbock: American Society of Forensic Odontology; 2006:210-243.

7.American Academy of Pediatric Dentistry. Guideline on Oral and Dental Aspects of Child Abuse and Neglect. Available at: "http://www.aapd.org/publications/".Accessed: 2017-04-27 (Archived by WebCite®at:http://www.aapd.org/media/Policies_Guidelines/G_Childabuse1.pdf

8. Rodrigues JLSA, Lima APB, Nagata JY, Rigo L, Cericato GO, Franco A,a, et al. Domestic violence against children detected and managed in the routine of dentistry - A systematic review. J Forensic Leg Med 2016; 43: 34-41.

9.Brasil. Lei n. 8.069, de 13 de julho de 1990. Dispõe sobre o Estatuto da Criança e do Adolescente, e dá outras providências. Disponível em https://www.planalto.gov.br/ccivil_03/leis/l8069.htm.

13. Flaherty EG, Stirling J Jr, The Committee on Child Abuse and Neglect.The pediatrician's hole in child maltreatment prevent. Pediatrics 2010;126(4):833-841.

14. Reichenheim ME, de Souza ER, Moraes CL, de Mello Jorge MHP, da Silva CMFP, Minayo MCS. Violence and injuries in Brazil: the effect, progress made, and challenges ahead. www.thelancet.com Published online May 9, 2011 DOI:10.1016/S0140-6736(11)60053-6.

15. Holmes-Johnson E, Geboy M, Getka EJ. Behavioral Considerations. Dent Clin North Ame 1986; 30(3): 391-398.

16. Daly M, Wilson M. Evolutionary social psychology and family homicide. Science 1988; 242(4878):519–524.

17. Gallo L G. Child abuse: who is involved? N Y State Dent J 1983; 49: 77-78.

18. Study on Child Abuse, Md.: Ministry of Woman and Child Development Government of India; 2007. Printed by Kriti, New Delhi.

19. Child exploitation. Avaiable at : "https://legaldictionary.net/childexploitation/" . Accessed: 2017-02-24. (Archived by WebCite® at : "http://www.webcitation.org/6oWNUwxR1")

20.Greenbaum PE, Lumley MA, Turner C, Melamed BG. Dentist's reassuring touch: effects on children's behavior. Pediatr Dent 1993;15(1):20-24.

21.Kvist T, Wickström A, Miglis I, Dahllöof G. The dilemma of reporting suspicions of child maltreatment in pediatric dentistry. Eur J Oral Sci 2014; 122: 332–338.

22. Sonbol HN, Abu-Ghazaleh S, Rajab LD, et al. Knowledge, educational experiences and attitudes towards child abuse amongst Jordanian dentists. Eur J Dent Educ. 2012;16: 158-165.

23. Laud A, Gizani S, Maragkou S. Child protection training, experience, and personal views of dentists in the prefecture of Attica. Int J Paediatr Dent. 2012; 23: 64-71.

10. American Academy of Pediatric Dentistry. Guideline on Behavior Guidance for the Pediatric Dental Patient. Available at: "http://www.aapd.org/publications/". Accessed: 2017-04-27. (Archived by WebCite® at: http://www.webcitation.org/6q2Tgost2).

11. O'Neill JA Jr, Meacham WF, Griffin JP, Sawyers JL. Pat¬terns of injury in the battered child syndrome. J Trauma 1973;13:332-9.

12. Vieira ELR, Katz CRT, Colares V. Indicators of child and adolescent maltreatment in pediatric dentistry practice.Odontologia Clin-Cientif 2008;7:113-118.