WITHOUT MINI-PLATES, MINI-IMPLANTS AND SURGERY: TREATMENT OF SEVERE ANTERIOR OPEN BITE IN AN ADULT PATIENT - A CASE REPORT

Leonard Euler **Nascimento**[1,2*]

[1]Orthodontics Specialization Course, School of Dentistry, Universidade Federal do Piauí (UFPI), Teresina-PI, Brazil.
[2]School of Dentistry, Universidade do Estado do Piauí – FACOE (UESPI), Parnaíba-PI, Brazil.

Palavras-chave: Mordida Aberta. Adulto. Step-bends. Elásticos. Dispositivo de Ancoragem Temporário. Cirurgia.

RESUMO

Introdução: Atualmente, existe uma tendência de tratar a mordida aberta com mini-implantes, miniplacas, cirurgias ortognáticas e levantes de mordida, quando estes protocolos nem sempre são indicados e a sua aplicação pode ser desnecessária e excessiva. **Objetivo**: Este relato de caso descreve o tratamento de uma mordida aberta anterior grave em paciente adulto com "step bends" e elásticos verticais. **Relato do caso**: A paciente tinha 29 anos e 8 meses de idade e relatou ter baixa autoestima; portanto ela queria fechar sua mordida aberta não tratada. Ao exame, um perfil convexo, padrão de crescimento vertical, desvio da linha média dental e exposição da língua podiam ser vistos ao sorrir. A relação sagital dental e esquelética era de Classe II. O *overjet* de +5 mm e o *overbite* anterior de -5,5 mm. A mordida aberta esquelética grave envolveu os primeiros molares até os dentes anteriores e foi tratada apenas com "step bends" e elásticos verticais por pouco mais de 2 anos. **Resultados**: Melhoria facial significativa, exposição dos incisivos superiores ao sorriso estético, sobremordida e *overjet* adequados foram observadas. As linhas médias dentárias superior e inferior adequadas à linha sagital. Foi observada rotação da mandíbula no sentido anti-horário. A mordida aberta esquelética grave foi tratada. **Conclusão**: A má oclusão grave da mordida aberta esquelética tratada com "step bends" e elásticos verticais em pacientes adultos demonstrou correção eficiente, previsível e estável da mordida aberta.

Keywords: Open Bite. Adult. Step-bends. Elastics. Temporary Anchorage Dispositive.

ABSTRACT

Introduction: Currently, there is a tendency to treat open bite with mini-implants, miniplates, and orthognathic surgeries and build ups when these protocols are not always indicated and to be apply them unnecessarily and excessively. **Objectives**: This case report describes treatment of a severe anterior open bite in an adult patient with step bends and vertical elastics. **Case report**: The female patient was 29 years and 8 months old and reported that she had low self-esteem; therefore, she wanted to have her untreated open bite closed. By examination, a convex profile, vertical growth pattern, dental midline deviation, and tongue exposure could be seen upon smiling. The dental and skeletal sagittal relationship was Class II. The overjet was +5 mm and the anterior overbite was -5.5 mm. The severe skeletal open bite involved the first molars to the anterior teeth, and it was treated only with step bends and vertical elastics over 2 years. **Results**: Significant facial improvement, maxillary incisor exposure upon aesthetic smiling, and adequate overbite and overjet were observed. The upper and lower dental midlines fit to the sagittal line. A counterclockwise rotation of the mandible was observed. The severe skeletal open bite was treated. **Conclusions**: Severe skeletal open bite malocclusion treated with step bends and vertical elastics in adult patient demonstrated efficient, predictable and stable open bite correction.

Submitted: January 26, 2020
Modification: March 14, 2020
Accepted: May 14, 2020

***Correspondence to:**
Leonard Euler Nascimento
Address: Rua Senador Candido Ferraz, 1770, Apto 1802 – Jockey - Teresina-PI, Brazil
ZIP CODE: 64049-250
Telephone Number: +55 (86) 999767714
Fax: +55 (86) 32143757
E-mail: leonardeuler@hotmail.com

INTRODUCTION

Severe anterior open bite (AOB) is still a challenging malocclusion to be treated by the orthodontist. The incidence is higher in females (64.9%). The AOB etiology is resulted of genetic and environmental factors or both as well.[1,2] However, the OAB in adults is more difficult because of complicated problems and oftentimes when the surgical correction is requested.[1-3]

The miniplates and miniscrews are also variations used nowadays to correct AOB as others.[4] Due to the their high success rates to treat AOB,[5] resistance is coming up from the orthodontists/buccal-facial surgeons to treat using conventional protocols without surgeries and temporary anchorage dispositive (TAD).[6,7] Disadvantages attributed to the miniplates are the applicability of a specialized surgery, higher medical costs and probably biological damages.

After identifying the etiological agent and defining the diagnosis and case planning, the use of mini-screws, miniplates and any surgery aproach[4-7] can be disregarded to continue the treatment of an AOB. This case report aimed to show a severe adult AOB treatment performed without extractions and no use of TADs, only with the use of elastics and steps bended in the orthodontic stainless steel archwires.

CASE REPORT

Diagnosis and Etiology

A 29-year and 8-month-old female patient scheduled an appointment with an orthodontic private clinic. Her chief complaints were as follows: "I feel myself with low self-esteem because I use orthodontic appliances for more than three years with another professional, but my AOB is the same as when I started treatment; therefore, I'd like to close it". Orthodontic brackets without archwires and tongue interposition could be seen while she was talking.

Given that a new treatment would have to be started and the unfinished one would have to be terminated, the author asked for the previous initial radiographs, casts and photographs; however, the patient said that none were prescribed, and as a result, they were unavailable. Therefore, the author prescribed only new registers as when the patient arrived at the office and adopted these registers as the new references starting from that moment (Figures 1A-O; 2 A-D). In this way, the need for a second set of radiographs, casts and photographs just after the removal of the previous appliance removal was avoided, preventing additional costs and radiation administration to the patient.

By examination, there were fillings in the molars. Maxillary dental midline deviation of 1.0 mm from the left in relation to the midfacial plane, lip incompetence at rest, and tongue interposition were noticed (Figure 1A-O). The dental sagittal relationship was Class II on the right (Figures 1D-I). The patient had a convex profile (S-Lsup +4, S-Linf +4) and projecting incisors (1-NA 7 mm, IMPA 98, 1-NB 9). The third molars were absent according to X-ray assessment (Figure 2). The incisors showed mild root absorption with a large periodontal ligament. The 5° ANB was characteristic of a Class II skeletal discrepancy. The GoGn-SN, Y Axis and FMA angles, 38°, 66°, and 32°, respectively, indicated an increased lower anterior face height (vertical growth pattern) associated with an AOB. The skeletal open bite involved the anterior (-5.5 mm) and posterior teeth up to the first molars. The overjet was +5 mm. Symptoms were not reported at the temporomandibular joint, which was shown to have normal function and structure. The patient was diagnosed with dental and skeletal Class II, severe open-bite malocclusion, mild lower face height increased, dental midline deviation and tongue exposure upon smiling.

Treatment Objectives

The orthodontic treatment objectives were to treat the AOB, correct the upper dental midline deviation, and achieve a Class I canine and molar relationship. Further objectives included an ideal overbite and overjet, improvement of facial aesthetics, and a new swallow pattern.

Treatment Alternatives

Three treatment alternatives were considered: (1) surgical correction treatment,[5,8] (2) posterior teeth intrusion + TADs + anterior teeth extrusion with elastics,[10] and (3) step-down bends in the upper arches + anterior teeth extrusion with elastics.[11] The patient strongly rebutted orthognathic surgery and the use of TADs.[9] After clear explanation and discussion about the treatment alternatives and limitations with the patient, the third option was chosen.

Treatment Progress

First, it was made clearer to the patient that she would be required to completely restart treatment. Therefore, new orthodontics radiographs, casts and photographs were made preserving the same appliance she had in her mouth. Once the new registers received, the entire appliance she had was removed, and a new one was placed, with 0.022" x 0.028" edgewise bracket slots. Along with the orthodontic treatment, the patient agreed to orofacial myofunctional therapy with a speech therapist. The archwires were changed approximately every 25-30 days or when a changed was deemed necessary. The 0.014", 0.016", and 0.018" CrNi leveling and alignment archwires had mesial Omegas adjacent to the accessories welded in the molar bands. Both 0.016" x 0.022" and 0.019" x 0.25" CrNi archwires were used in the

finalization period. The treatment was conducted as follows:

a) First four months: A 0.014" archwire were set in the both arches. Mild step-down bends into upper orthodontic archwire, starting at the interproximal contact point of the posterior molars and bending until the mesial surface of the lateral incisors. Each time the 0.014" archwires were changed during these first four months, all the original bends were increased. The elastics prescribed in this report case (São Paulo, Morelli, Brazil) had to be changed every two days. Square elastics (5/16" light, 80 gf, only at night), began to be used after the third month of treatment. At the end of these first four months, the severe AOB had decreased by + 2,0 mm.

b) Five to eight months: A 0.016" archwire was set in both arches. Bends were made in the same proportion as those in the last 0.014" archwire. Class II and square elastics (5/16" light, 80 gf, only at night, 12 h/day), began to be used, as shown in Figure 3 A-E. After the 8th months of treatment, the AOB decreased by + 1.5 mm, showing a – 2.0 mm overbite. The overjet was + 4.0 mm.

c) Nine to twelve months: 0.016"/0.018" wires were set in the upper/lower arches, respectively. Periapical X-rays were made at this phase (Figure 3 F-G). The elastics remained unchanged in terms of size and duration of use (Figure 3 H,I). The AOB had decreased by an additional + 3.0 mm, and a positive overbite of 1.0 mm was achieved. The overjet was 3 mm.

d) 13 to 16 months: 0.018"/0.016 x 0.022" wires were set in the upper/lower arches, respectively, and bends were applied where necessary. Class II (5/16" medium, 100 gf, 24 h/day) and square elastics (5/16" medium, 100 gf, only at night) were used, and changed every two days. The AOB had decreased by an additional + 1.5 mm. An overjet of 2.5 mm and a Class I molar and canine relationship were established. The anterior upper teeth brackets were repositioned to avoid step down bends in the next archwires.

e) 17 to 20 months: 0.018"/0.016 x 0.022" wires were set in the upper/lower arches, respectively. Class II elastic elastics began to be used only on the right side at night (5/16" medium, 100 gf), and 3/16" triangle elastics (5/16" medium, 100 gf, 24 h/day) were installed with their apex bared at the upper canine hooks and the base of the first and second bicuspids, which were changed every two days. The premature occlusal contacts were removed with occlusal adjustment.[12] Individual bends were made as necessary. The AOB decreased by an additional + 1,0 mm, resulting in a total AOB reduction of 9,0 mm and representing a change from an initial overbite of -5,5 mm to a final overbite of +3,5 mm, which was finally considered an overcorrection of the AOB (Figure 3 A-I). In the vertical relationship, it is considered normal for the upper anterior teeth to overlap the lower teeth by 2 to 3 mm; moreover, this is considered to increase the vertical overbite.[13] In this case, the overcorrection was purposeful due to the high epidemiological prevalence of recurrence.[13]

f) 21 to 24 months (end of treatment): In this finalization period, 0.016" x 0.022" and 0.019" x 0.026" CrNi upper and lower archwires, respectively, were set. The Class II and triangular vertical elastics were gradually removed. In the first of the last four months, the elastics were used only at night and were changed every night. In the second of the last four months, the elastics were worn only every other night, and in the remaining two months, no more elastics were used through the end of the treatment. During the last four months of treatment, the overbite and overjet were maintained, and neither tongue interposition nor the atypical swallowing were observed.

After 24 months of orthodontic treatment, the appliance was removed, and the central upper incisors received aesthetic procedures. The wrap-around retainer (in the maxilla) was used 24 h/day in the first 8 months, half a day (at night) for an additional 3 months and every other night in the last month of use. A lower retainer in the six anterior teeth (3-3) were set for undetermined ending time (Figures 4K,M; 4A). The patient was urged to maintain her orofacial myofunctional therapy with the speech therapist for additional 12 months. The treatment progress performed is summarized in Table 1.

Treatment Results

Significant facial improvements can be seen in Figure 4. The profile is symmetrical in terms of the new position of the upper and lower lips; maxillary incisor exposure upon aesthetic smiling, adequate overbite (+3.5 mm) and overjet (+ 2.5 mm), and Class I functional relationships can be observed, and the upper and lower dental midlines fit to the sagittal line. Root absorption and periodontal conditions did not suffer greater damage than that observed at the beginning. Mandibular projection was observed, and the convexity and vertical relationship had decreased due to a counterclockwise movement of the mandible (Figure 5, Table 2).

The overlaps confirmed that the cephalometric changes were an extrusion of the upper and lower incisors and an intrusion of the upper molars (Figure 5 E, F). Symptoms were not reported at the temporomandibular joint. Conventional orthodontics provided physiological and aesthetic results and met the most urgent needs of the patient. In a posttreatment follow-up of 12 months, no significate relapses were verified. Despite these limitations, the amount of vertical and facial improvements was considerable, and the patient's chief complaints were satisfied.

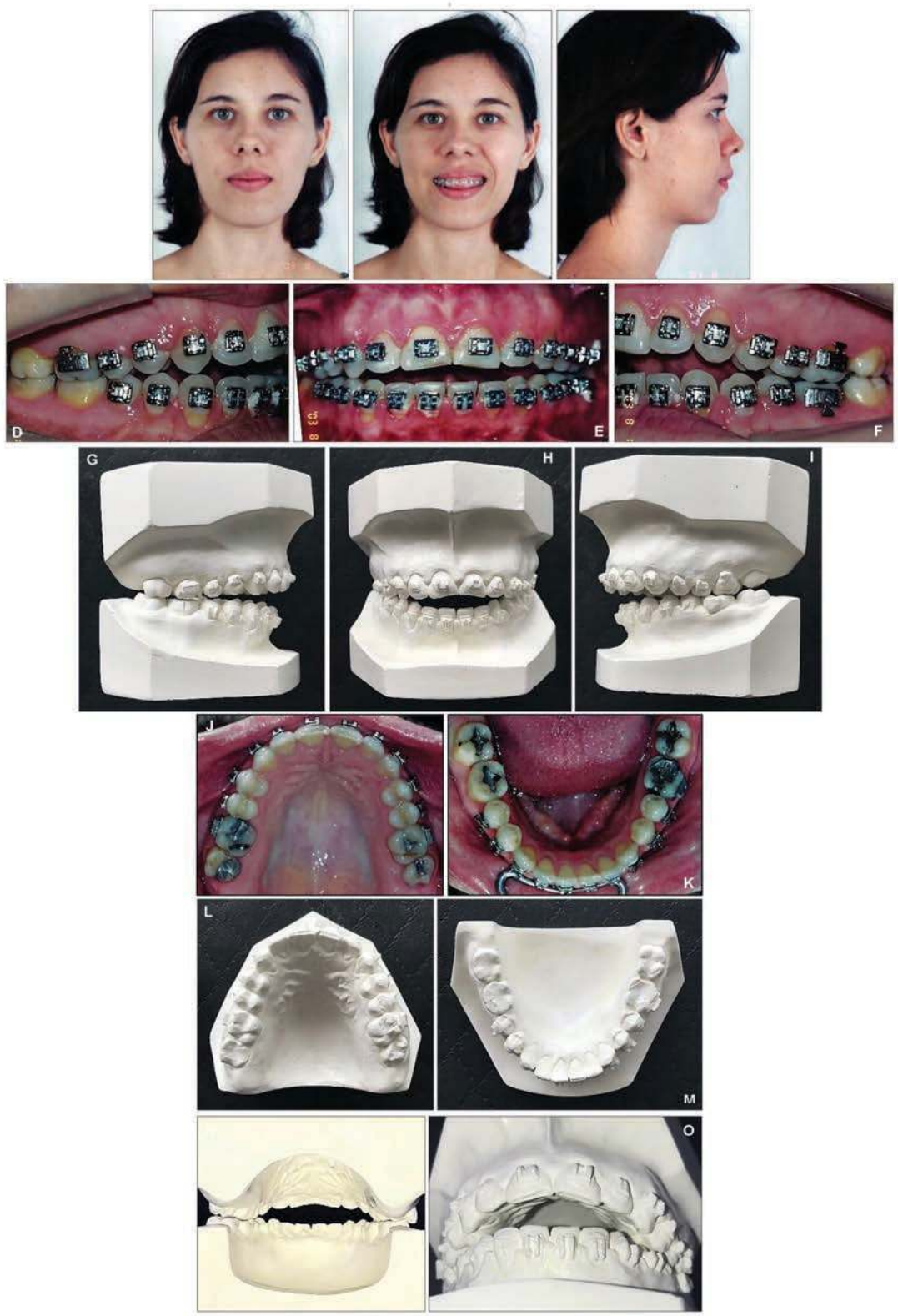

***Figure 1**: Photos when patient presented to the office. Extra-orals (A-C); intra-orals: (D-M); details of posterior (N) and anterior-inferior (O) occlusion, showing the severe open bite from the first molars including the anterior region of the arches.*

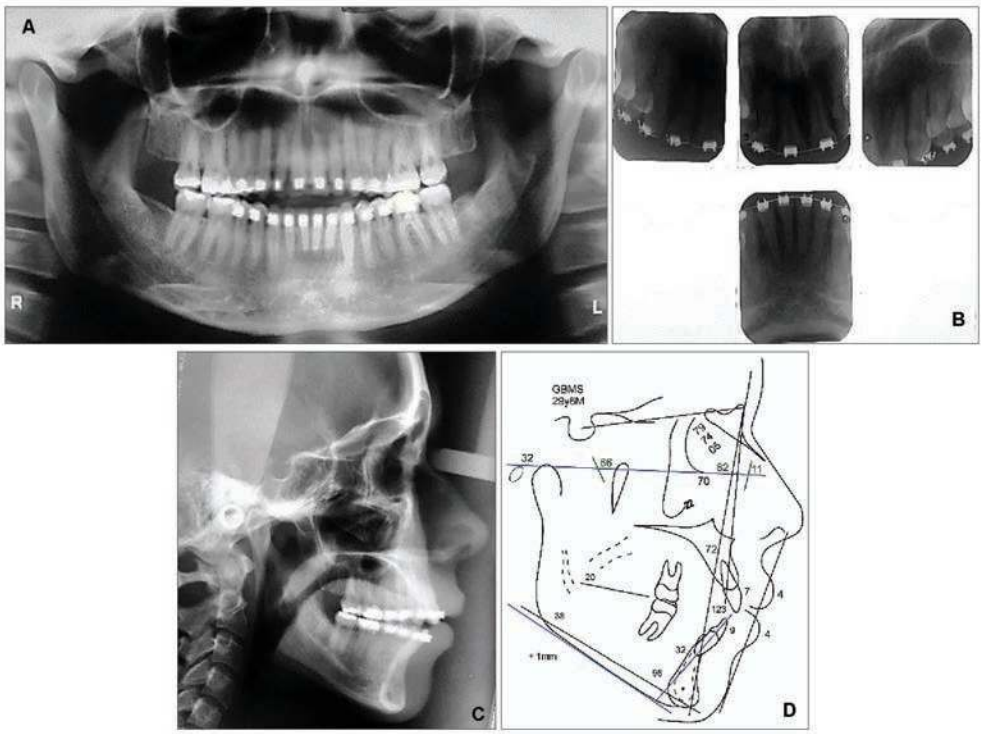

Figure 2: Initial X-rays (A-C). Periapical X-rays brought by the patient, with orthodontic wires (B). Initial cephalometric tracing (D).



Figure 3: *Intermaxillary elastics (5/16"). Square and Class II verticals: closed mouth (A-C); opened mouth (D, E). X-rays (F, G). After overjet and overbite establishment: open mouth (H), closed mouth (I).*



Figure 4: *Final photos. Extra-orals (A-C); intra-orals (D-M); details of posterior (N) and anterior-inferior occlusion, showing the severe open bite correction (O).*

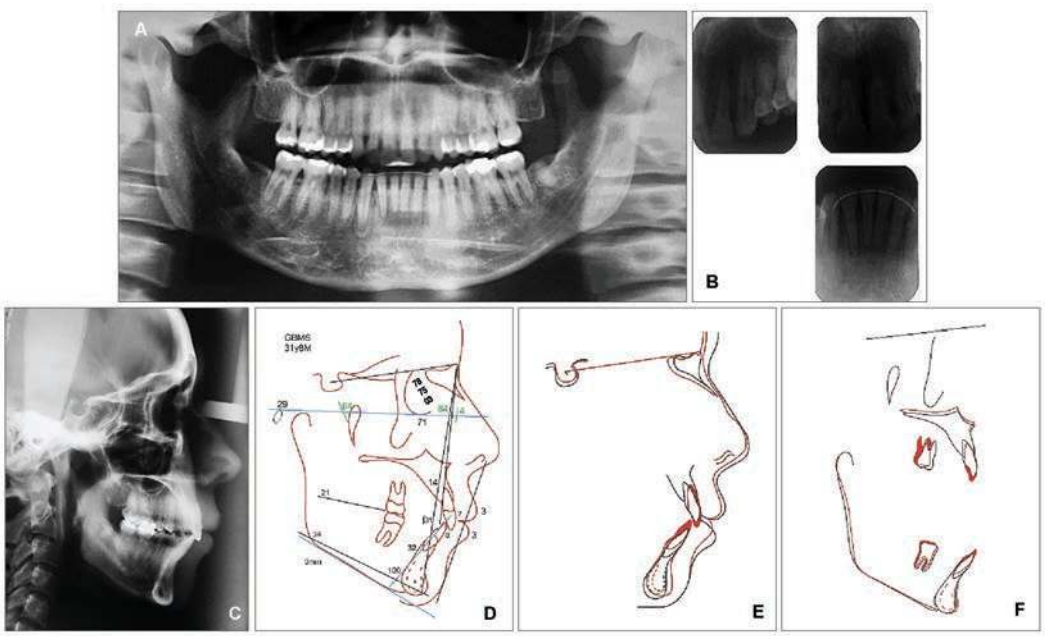

***Figure 5**: X-rays: panoramic (A); periapical (B) and final cephalometric (C). Final cephalometric tracing (D). Overlaps: N recorded (E), best-fit of maxilla and internal contour of mentonian symphysis (F).*

Table 1: *Summarized conducts performed in the- treatment of a severe anterior open bite, dental and skeletal class II sagittal relationship, in adult patient, with vertical elastics and step bends without the use of temporary anchoring devices nor surgery.*

Months	**1-4**	**5-8**	**9-12**	**13-16**	**17-20**	**21-24**
Speech Therapy Orofacial myofunctional therapy with a speech therapist along the treatment.						
Archwires size						
Upper	0.014"	0.016"	0.016"	0.018"	0.018"	0.016" x 0.022"
Lower	0.014"	0.016"	0.018"	0.016" x 0.022"	0.016" x 0.022"	0.019" x 0.025"
Archwires Bends						
Upper	Vertical step-down bends: Starting at the posterior teeth until the mesial of lateral incisors. Mild increased by each archwire changes			1st, 2nd order bends where necessary to a/n		1st, 2nd, 3rd finalization bends
Lower	———	1st, 2nd order bends where necessary to a/n		Added 3rd orders bends with ideals torches.		
The elastics prescriptions						
Beginning	3th	5th	9th	13th	17th	21th
Changes	Every two days					Cl. II and Triangle elastics gradually removed
Direction	Square	Class II and Square		Cl. II / Square	Cl. II	Triangle
24 h/day	——	——		Yes / ——	——	Yes
at night 12 h/day	Yes	Yes		—— / Yes	Yes right side	——
Magnitude	80 gf			100 gf		
Size	5/16" light			5/16" medium	5/16" medium	3/16"
Initial Overbite = - 5.5 mm						
Overbite decreased	+2.0mm	+1.5mm	+3.0mm	+1.5 mm	+1.0 mm	Final overbite
Overbite achieved	-3.5mm	-2.0mm	+1.0mm	+2.5 mm	+3.5 mm	+3.5 mm
Initial Overjet = + 5.0 mm						
Overjet decreased	-0.5mm	-0.5mm	-1.0mm	-0.5 mm	——	Final overjet
Overjet achieved	+4.5mm	+4.0mm	+3.0mm	+2.5 mm	+2.5 mm	+2.5 mm
Retainers						
Maxilla	Wraparound					
Use	24 h/day in the first 8 months, half a day (at night) for an additional 3 months and every other night in the last month of use					
Mandible	A lingual fixed set in the lower anterior six teeth (3 – 3)					
Use	No ending time determined					
Speech Therapy	Additional orofacial myofunctional therapy with a speech therapist for one year					

Table 2: *Values of the cephalometric tracings: initial (T0) and final (T1).*

	Analysis Type	NORMA	T0 29y 8m	T1 31y 8m	Diferences between T0-T1
Steiner	SNA	82	79	78	-1
	SNB	80	74	75	+1
	ANB	2	5	3	-2
	1.NA°	22	22	14	-8
	1-NA (mm)	4	7	7	none
	1.NB°	25	32	32	none
	1-NB (mm)	4	9	8	-1
	1:1	131	123	131	+8
	Ocl.SN	14	20	21	+1
	GoGn.SN	32	38	34	-4
	S-Ls (mm)	0	4	3	-1
	S-Li (mm)	0	4	3	-1
	Pog-NB (mm)	---	2	2	none
Downs	Å Facial	87.9	82	84	+2
	Å Convexity	0	11	4	-7
	Å Y Axis	59.4	66	64	-2
Tweed	FMA	25	32	29	-3
	FMIA	68	50	51	+1
	IMPA	87	98	100	+2

DISCUSSION

Currently, there is a great tendency of treatment plans for AOB, whether anterior, posterior, skeletal, or dental, to be bold, involving TADs and orthognathic surgery.[5,6,8-10] Such procedures can be unnecessary and computerized topographies and magnetic resonances as well.[14] This was avoided in the treatment described in this report.

a) Mechanical extrusion vs the impact to the root apex by molar intrusion

The choice to extrude the anterior teeth instead of intrude the molars was made due to a report in the literature[15] that indicated that the intrusion of molars causes approximately four times more root resorption than incisor extrusion. The rounding root apexes observed in the incisors can be attributed to the lingual interposition in addition to the use of vertical elastics.[15]

b) Vertical elastics/TADs vs counterclockwise rotation

The outcomes of this case report showed anterior teeth extrusion, a counterclockwise rotation of the mandible, positive vertical overbite and dental midline deviation correction, in addition to improvements to the patient's facial profile and the maintenance of passive lip sealing (Figures 4 and 5D-F). These results are predictable, efficient, and have good stability for open bite correction, even with the absence of TADs.[16,17]

The elastics are disposable, their activation is increased by jaw movement, and they have predictable mechanics, if used correctly;[16] however, the TADs requires more caution regarding inflammation in the adjacent soft tissues, bone density,[9] root injuries, mobility, fractures due to excessive force of the operator and possible reinstallation.[18]

c) Strength and time of elastics

In the literature,[19] similar to the observations in this case report, the use of the same elastics for a period between 1 and 2 days can maintain the remaining strength, and the triangular elastics contributed to the maintenance of the AOB correction, even in the face of potential side effects. When tip backs and Omega stops are used adjacent molar accessories with the most rigid wires, extrusion and mesioinclination are minimized, which avoids tilting the occlusal plane downward.[19] The use of intermaxillary elastics can promote signs and symptoms of temporomandibular disorder.[20] In this clinical case, these symptoms were not observed.

At the one-year follow-up after appliance removal, a mild relapse was detected, but since the treatment produced an overcorrection of the anterior open bite, the final aesthetic results and functional movement were not affect. Besides, the literature says that relapses can also occur also with the use of TADs[6,8] In addition, the patient continued to practice with the previous tongue therapy.

CONCLUSIONS

In this case report, a severe skeletal open bite malocclusion in an adult patient was treated only with step bends and vertical elastics, which demonstrated an efficient, predictable and stable open bite correction.

REFERENCES

1. Subtelny JD, Sakuda M. Open-bite: diagnosis and treatment. Am J Orthod. 1964;50:337–358.

2. Proffit WR, Ackerman JL. Diagnosis and treatment planning in orthodontics. In: Graber TM, Vanarsdall RL, eds. Orthodontics. Current Principles and Techniques. 2nd ed. St Louis, Mo: Mosby Year Book Inc; 1994: 1–95.

3. Oliveira JA, Bloomquist DS. The stability of the use of bilateral sagittal split osteotomy in the closure of anterior open bite. Int J Adult Orthodon Orthognath Surg. 1997;12:101–108.

4. Hart TR, Cousley RR, Fishman LS, Tallents RH. Dentoskeletal changes following mini-implant molar intrusion in anterior open bite patients. Angle Orthod. 2015;85:941–948.

5. Janson G, Valarelli F. Open-Bite Malocclusion: Treatment and Stability. Ames, IA: John Wiley & Sons, Inc; 2014. p. 133–312

6. Scheffler NR, Proffit WR, Phillips C. Outcomes and stability in patients with anterior open bite and long anterior face height treated with temporary anchorage devices and a maxillary intrusion splint. Am J Orthod Dentofacial Orthop. 2014;146:594–602

7. Alsafadi AS, Alabdullah MM, Saltaji H, Abdo A, Youssef M. Effect of molar intrusion with temporary anchorage devices in patients with anterior open bite: a systematic review. Prog Orthod. 2016;17:9.

8. Kahnberg KE, Widmark G. Surgical treatment of the open bite deformity. Surgical correction of combined mandibular prognathism and open bite by oblique sliding osteotomy of the mandibular rami. Int J Oral Maxillofac Surg. 1988;17:45–48.

9. Baek MS, Choi YJ, Yu HS, Lee KJ, Kwak J, Park YC. Longterm stability of anterior open-bite treatment by intrusion of maxillary posterior teeth. Am J Orthod Dentofacial Orthop. 2010;138:396.e1–396.e9.

10. Deguchi T, Kurosaka H, Oikawa H, Kuroda S, Takahashi I, Yamashiro T, et al. Comparison of orthodontic treatment outcomes in adults with skeletal open bite between conventional edgewise treatment and implantanchored orthodontics. Am J Orthod Dentofacial Orthop.2011;139:S60–S68.

11. Janson G, Crepaldi MV, de Freitas KM, de Freitas R, Janson W. Evaluation of anterior open-bite treatment with occlusal adjustment. Am J Orthod Dentofacial Orthop. 2008;134:10.e1–10.e9

12. Silva MBG, Sant'Anna EF. The evolution of cephalometric diagnosis in Orthodontics. Dental Press J Orthod. 2013 May-June;18(3):63-71

13. Ruellas AC, Yatabe MS, Souki BQ, Benavides E, Nguyen T, Luiz RR, et al. 3D Mandibular superimposition: comparison of regions of reference for voxel-based registration. PLoS One. 2016;11:e0157625

14. Abdelkarim AA. Appropriate use of ionizing radiation in orthodontic practice and research Am J Orthod Dentofacial Orthop 2015;147:166-8

15. Southard TE, Marshall SD, Bonner LL. Orthodontics in the Vertical Dimension: A Case-Based Review. John Wiley & Sons, 2015: 272.

16. Sugawara J, Baik UB, Umemori M, Takahashi I, Nagasaka H, Kawamura H, et al. Treatment and posttreatment dentoalveolar changes following intrusion of mandibular molars with application of a skeletal anchorage system (SAS) for open bite correction. Int J Adult Orthodon Orthognath Surg. 2002;17:243–253.

17. Cruz-Escalante MA, Aliaga-Del Castillo A, Soldevilla L, Janson G, Yatabe M, Zuazola RV. Extreme skeletal open bite correction with vertical elastics. Angle Orthod. 2017;87:911–923.

18. Loriato LB, Machado AW, Pacheco W. Considerações clínicas e biomecânicas de elásticos em Ortodontia. R Clin Ortodon Dental Press. 2006;5:44-57.