REPLANTATION OF AVULSED TOOTH: A STEP-BY-STEP REPORT

Michelle Jenné **Allegretto**[1], Larissa Soares Lima da **Silva**[1], Jéssica Muniz **Loureiro**[1], Lucas Alves **Jural**[2], Marcela Baraúna **Magno**[1,3], Patricia de Andrade **Risso**[3], Lucianne Cople **Maia**[1*]

[1]Department of Pediatric Dentistry and Orthodontics, School of Dentistry, Universidade Federal do Rio de Janeiro, Rio de Janeiro, Brazil.
[2]Ungraduated student, School of Dentistry, Universidade Federal do Rio de Janeiro, Rio de Janeiro, Brazil.
[3] Department of Dental Clinic, School of Dentistry, Universidade Federal do Rio de Janeiro, Rio de Janeiro, Brazil

Palavras-chave: Avulsão Dentária. Injuria Dental. Relatos de Caso.

RESUMO

Introdução: A avulsão é uma injuria grave que causa sérios danos aos tecidos de suporte do doente e é caracterizada pelo completo deslocamento do elemento dentário de dentro do alvéolo. O reimplante é, na maioria das situações, o tratamento de escolha para o dente permanente avulsionado e uma conduta correta é necessária para um bom prognostico nestes casos. Estudos prévios mostram que o conhecimento de dentistas sobre o manejo de um dente que sofreu avulsão é deficiente e destacam a importância da educação continuada, com a intenção de aumentar o nível de conhecimento de dentistas clínicos frente a urgências envolvendo dentes avulsionados. **Objetivo**: este relato tem como objetivo apresentar uma sequência clínica passo-a-passo envolvendo o reimplante de um dente permanente maduro que sofreu avulsão, seguindo o guia CARE. **Relato do caso**: O dente 21, armazenado em leite, foi reimplantado 2 horas após a avulsão e estabilizado com contenção flexível. As etapas clínicas foram realizadas conforme as recomendações da Associação Internacional de Traumatismos Dentários. O tratamento endodôntico foi iniciado cinco dias após o reimplante, com trocas periódicas de medicação intracanal. Atualmente o paciente encontra-se em acompanhamento, sem sinais ou sintomas negativos relacionados a avulsão. **Conclusão**: O reimplante dental após avulsão deve ser realizado após minucioso diagnóstico e condições de armazenamento do dente, com protocolo clínico embasado nas evidências científicas das associações de traumatismos dentoalveolares.

Keywords: Tooth avulsion. Tooth Injuries. Case Reports.

ABSTRACT

Introduction: Avulsion is a serious injury that causes damage to dental and supportive tissues, and is characterized by complete displacement of a tooth from its socket. In most situations, replantation is the treatment of choice for permanent tooth avulsion, and appropriate management is critical for a good prognosis in these cases. Previous studies have shown that the level of knowledge of dentists regarding the management of an avulsed tooth is deficient and have underscored the importance of continuing dental education to further the knowledge of general dentists in the urgency management of permanent avulsed teeth. **Objective**: This report aims to present a step-by-step clinical sequence involving the reimplantation of a mature permanent tooth that suffered avulsion, following the CARE guide. **Case report**: Tooth 21, stored in milk, was reimplanted 2 hours after avulsion and stabilized with flexible containment. The clinical steps were carried out according to the recommendations of the International Association of Dental Traumatology. Endodontic treatment was started five days after reimplantation, with periodic changes of intracanal medication. The patient is currently under follow-up, with no negative signs or symptoms related to avulsion. **Conclusion**: Dental reimplantation after avulsion should be performed after a thorough systemic and oral diagnosis and tooth storage conditions, with a clinical protocol based on scientific evidence of associations of dentoalveolar trauma.

Submitted: July, 2020
Modification: August 19, 2021
Accepted: February 4, 2021

***Correspondence to:**
Dr. Lucianne Cople Maia
Address: Rua Rodolpho Paulo Rocco, 325 - Cidade Universitária, Rio de Janeiro - RJ, Brazil - CEP: 21941-913.
Telephone/Fax: +55 21 3938-2098
E-mail: rorefa@terra.com.br

INTRODUCTION

Traumatic dental injuries in primary and permanent dentitions commonly occur in children and adolescents,[1] and can range from a simple concussion to substantial damage involving structures surrounding the tooth.[2,3] Avulsion can be defined as the complete detachment of the tooth from its socket, and is the most complicated and serious type of all permanent dental injuries. Its prevalence can range from 0.7% to 31.9%, with the highest incidence occurring in the maxillary central incisor.[4,5]

In most situations, replantation is the treatment of choice for the avulsion of a permanent tooth. The immediate and most appropriate management of an avulsed tooth occurs at the accident site, together with other first-aid procedures, and the dentist's knowledge regarding tooth replantation is critical for a good prognosis in these cases. Any and every attempt must be made to preserve a tooth, whether rhizogenesis is incomplete or complete.[2] The prognosis of permanent teeth with incomplete rhizogenesis is more or less favorable depending on how well the pulp can be repaired, and on continued root development. However, in regard to the replantation of teeth with complete rhizogenesis, even in the case of those with a less favorable late prognosis, the fundamental concern is to maintain the needed contour, width and height of the alveolar bone, and to restore the function and aesthetics of the tooth, even should the procedures represent but a temporary solution in anticipation of a more definitive future treatment.[2]

Many studies have shown that there is an urgent need to improve the knowledge of both general dentists and dental professions in general for treating urgency cases of tooth avulsion and overall traumatic dental injuries.[8,9] Bearing this in mind, the present study aims to give step-by-step directions for replanting an avulsed mature permanent tooth, according to the International Association of Dental Traumatology (IADT)[2] and CARE guideline.[10]

CASE REPORT

General concerns when receiving the patient

Some overall concerns involved in receiving a patient with dental avulsion call for asking the patient questions that must be answered before treatment can be decided on. Knowing where, how and when the trauma occurred, and also the storage medium of the avulsed tooth until its destination are of fundamental importance. Other related information of vital importance to treatment and prognosis include neurological symptoms, presence of systemic diseases, allergies, and having healthcare coverage for tetanus vaccine application.

Clinical Examination and Diagnosis

A thirteen-year-old adolescent was referred from a public oral health center to the Dental Trauma Surveillance and Monitoring Center - Department of Pediatric Dentistry Universidade Federal do Rio de Janeiro (DTSMC-UFRJ), Brazil, with an avulsed right maxillary permanent central incisor (#11) suffered two hours prior to admission. The traumatic injury occurred at school during recreational sports, and the tooth fell to the ground. There were no episodes of loss of consciousness or vomiting after the trauma. The adolescent's teacher placed the avulsed tooth in a container with milk (Figure 1A), and took the child and tooth to a public oral health center, which immediately referred the patient to the DTSMC-UFRJ.

During anamnesis, the mother reported that the adolescent had no general health problems or allergies that could contraindicate tooth replantation. In addition, healthcare coverage for tetanus vaccine application was confirmed. Extraoral examinations revealed no skin injuries. During intraoral clinical examination, the left permanent maxillary central incisor[11] and the right permanent lateral maxillary incisor (#12) presented with slight mobility, with bleeding from the gingival crevice, but without displacement, and were diagnosed as having subluxation (Figure 1B). Radiographic examinations showed the complete displacement of tooth #11 and a completely empty socket (Figure 1 C). No suggestive abnormalities could be seen in teeth #21 or #12. The alveolus was evaluated, and no alveolar fracture was detected.

Replantation procedure

The topical and local anesthesia administered consisted of 20% benzocaine and 2% lidocaine with epinephrine 1:100.000 (Alphacaine – DFL) (for a total average of one and a half tubes, 2.7 ml) (Figure 2 A and B).

First, the tooth was removed from the milk-filled storage container, and the crown and root surface were irrigated clean with a jet of saline. This step enabled diagnosis of a closed root canal apex, and an uncomplicated crown fracture in the avulsed tooth.

Then, the tooth was manipulated from the crown, and slowly replanted with slight digital pressure. No force was used (Figure 2 C).

A flexible splint was installed involving the maxillary canines and incisors, as follows (Figure 2 D,E,F,G):

1.Acid etching (Scotchbond Etchant - 3M ESPE) and

application of an adhesive system (Scotchbond multi-purpose - 3M ESPE), following the manufacturer's recommendations;

2.A thin layer of composite resin (Z250 3M ESPE) was placed over all the teeth to be splinted and polymerized;

3. A nylon thread was positioned over the thin layer of composite resin, and another layer of composite resin was placed over the thread to hold it in place, after which the resin was polymerized. As this procedure was being performed tooth by tooth, the replanted tooth (#11) was held in place with digital pressure. The splint was kept away from the gingiva to avoid gingival inflammation (Figure 2G). Occlusal contact was checked.

The dosing schedule was 500mg amoxicillin every 8 hours, for 7 days, and chlorhexidine (0.12%) mouth rinse twice a day for 1 week, as local antimicrobial therapy.

The patient was instructed, in the presence of the caregiver, to avoid engaging in contact sports, to eat a soft diet, and to brush with a soft-bristled brush. Furthermore, both were advised of the importance of complying with required follow-up visits. It is believed that homecare helps in the healing process following an injury, in compliance with the sequential treatment regimen, and also aids in possible future outcomes. The splint was removed 30 days after replantation.

Endodontic Therapy and Restorative Procedure

Endodontic therapy was initiated five days after tooth replantation. The root canal was prepared chemically and mechanically with irrigation using 2.5% sodium hypochlorite. Calcium hydroxide mixed with saline solution was introduced as an intracanal medicament, and the access cavity was sealed with temporary restoration material. The calcium hydroxide solution was refreshed periodically, every 15 days, during 45 days. At each intracanal medicament change during clinical visits, the temporary restoration material was removed, the root canal was cleaned with saline solution, and irrigated with 2.5% sodium hypochlorite, a fresh calcium hydroxide paste was prepared, and the root canal was filled with the medication (Figure 3B).

Root canal obturation was performed when the clinical symptoms of mobility, sensitivity to percussion and swelling of surrounding tissues had ceased, and radiographic sings of external resorption had stopped (Figure 3). In the present case, the tooth was filled 50 days after replantation.

The access cavity and crown fracture restoration was performed using the incremental technique with freehand sculpting and composite resin (A2B and A2E – Z350 – 3M ESPE) after acid etching (Scotchbond multi-purpose - 3M ESPE), and also using conditioning with an adhesive system (Prime&Bond 2.1 - Dentsply) (Figure 3F).

Follow-up

After five days, onset of the external inflammatory root resorption could be observed in the apical third of the root (Figure 3A). This resorption stopped after the root canal medication was refreshed, and did not progress during 3 months of follow-up after replantation (Figure 3B, C, D and Figure 4B). At this time, the restoration was satisfactory both functionally and esthetically (Figure 4A). The patient is scheduled to be monitored periodically at the University's DTSMC-UFRJ dental trauma center for five years.



***Figure 1**: A) tooth storage medium (milk); B) frontal view during clinical and C) radiographic examinations.*

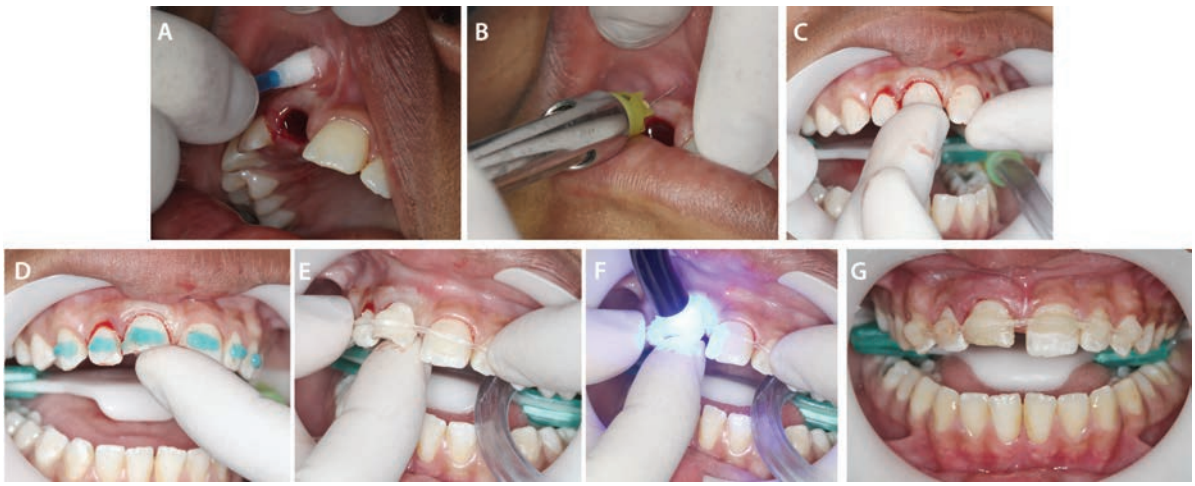

***Figure 2**: Replantation steps: Topical A) and local B) anesthesia; replantation of the tooth in the socket C); etching acid D); nylon thread was positioned after application of adhesive system and adaptation of composite resin, E); resin polymerization F); and final semi-rigid splint image G).*

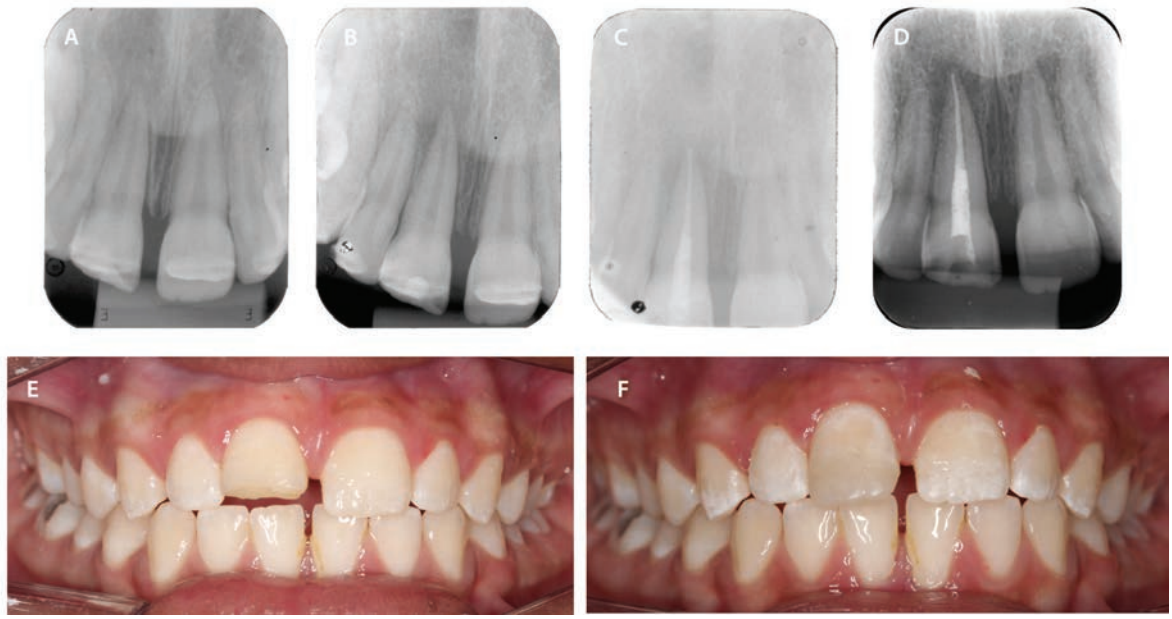

***Figure 3**: Endodontic and restorative steps: periapical radiograph taken 5 days after replantation A); periapical radiograph taken 30 days after replantation (with calcium hydroxide in root canal) B) periapical radiographic 1 month after replantation C); periapical radiographic 2 months after replantation D); image after splint removal and before restoration E); and after composite resin restoration F).*



***Figure 4**: Clinical A) and radiographic B) views after 3 months of replantation.*

DISCUSSION

Previous studies have highlighted the importance of continuing dental education to further the knowledge of general dentists in the urgency management of avulsed permanent teeth.[8,9,12] The present manuscript made a step-by-step report of the immediate procedures to deal with an avulsed tooth indicated for replantation, following IADT recommendations.

Extraoral time and storage medium influence tooth avulsion treatment choice. Fifteen minutes is the ideal extraoral time for replantation.[2] The authors of this manuscript opted to replant the tooth, despite two hours of extraoral time, because it was stored in a physiological medium. Milk and herbal medicines have been reported as good alternatives to Hank's balanced salt solution.[11] It is worthwhile remembering that the main objective in cases of late replantation is to maintain the contour, width and height of the alveolar bone temporarily for future treatment.[2] In addition, there are also individual situations when replantation is not indicated, like periodontal disease and severe medical conditions.[2] The patient of the present case did not present any condition that would contraindicate tooth replantation.

A flexible splint has been found to promote periodontal healing of the reimplanted tooth better, because it allows slight tooth movement.[13] Thus, it was indicated in the present case, and installed to immobilize the reimplanted tooth, by fixing it to the tooth with composite resin. This splint can be made with steel wire up to 0.016 inches (0.4 mm) in diameter, or with a fishing line (0.13 - 0.25mm - nylon wire).[2]

Controlling the infection during periodontal healing after replantation is fundamental, because of the risk of inflammation during long-term healing periods, considering that inflammation creates an environment favorable to root resorption.[14] For this reason, the IADT recommends systemic antibiotic therapy associated to endodontic treatment for patients undergoing replantation procedures.[2] The endodontic treatment requires closing the apex ideally as of two weeks after replantation, to prevent infection of the periodontal ligament through the root canal.[2] In the present case, amoxicillin was prescribed, and the endodontic treatment was initiated 5 days before replantation.

Calcium hydroxide has been considered the gold standard of intracanal medication, because of its strong alkalizing effects, stemming from the generation of hydroxyl ions, which ensure antibacterial power with broad-spectrum activity.[15] Hydroxyl ions can diffuse through root dentine and penetrate deeper into the biofilm,[16] thus reducing the viable bacteria in half.[17] Calcium hydroxide was used as an intracanal medication for up to one month, with two changes in the medication solution, in the present study. Used together with systemic antibiotic therapy, this medication was found to be effective in stopping external root resorption, diagnosed 5 days after replantation.

Comparing the updates in the guidelines presented by IADT, some changes could be observed, like endodontic treatment in cases of avulsion of mature permanent teeth. This treatment used to be recommended between 7 and 10 days after replantation in 2012, whereas the period indicated currently is up to two weeks after replantation. In addition, although an antibiotic prescription is still questioned, systemic antibiotics are still prescribed to reduce possible inflammatory root resorption, and prevent periodontal infection. Amoxicillin and penicillin are indicated as the medications of first-choice.[2]

There are many outcomes associated with tooth avulsion, including pain and excessive mobility, as well as inflammatory, infection-related or ankyloses-related replacement root resorption, and even tooth loss resulting from contraindication of replantation, or sequels. Periodic clinical and radiographic monitoring is important for all types of traumatic dental injuries, to diagnose and treat any of these outcomes, as quickly as possible. Additionally, it is important to underscore that clinicians must evaluate the avulsed tooth as well as its adjacent neighbors and antagonists at each return visit, since other teeth may have also suffered secondary trauma.[2]

CONCLUSION

In this case report, the authors describe the IADT recommendations for tooth replantation. These procedures should be made known to general dentists to improve their knowledge regarding avulsed teeth, and ensure correct procedural behavior in their immediate handling of an avulsion in the event of urgencies.

REFERENCES

1. Azami-Aghdash S, Ebadifard Azar F, Pournaghi Azar F, Rezapour A, Moradi-Joo M, Moosavi A, et al. Prevalence, etiology, and types of dental trauma in children and adolescents: Systematic review and meta-analysis. Med J Islam Repub Iran. 2015;29: 234.
2. Fouad AF, Abbott PV, Tsilingaridis G, Cohenca N, Lauridsen E, Bourguignon C, O'Connell A, Flores MT, Day PF, Hicks L, Andreasen JO, Cehreli ZC, Harlamb S, Kahler B, Oginni A, Semper M, Levin L. International Association of Dental Traumatology guidelines for the management of traumatic dental injuries: 2. Avulsion of permanent teeth. Dent Traumatol. 2020 Aug;36(4):331-342. .
3. Diangelis AJ, Andreasen JO, Ebeleseder KA, Kenny DJ, Trope M, Sigurdsson A, et al. Guidelines for the management of traumatic dental injuries: 1. Fractures and luxations of permanent teeth. Pediatr Dent. 2017;39: 401-11.

4. Stewart C, Kinirons M, Delaney P. Clinical audit of children with permanent tooth injuries treated at a dental hospital in ireland. Eur Arch Paediatr Dent. 2011;12: 41-5.
5. Eslamipour F, Iranmanesh P, Borzabadi-Farahani A. Cross-sectional study of dental trauma and associated factors among 9- to 14-year-old schoolchildren in isfahan, iran. Oral Health Prev Dent. 2016;14: 451-7.
6. Soares AJ, Souza GA, Pereira AC, Vargas-Neto J, Zaia AA, Silva EJ. Frequency of root resorption following trauma to permanent teeth. J Oral Sci. 2015;57: 73-8.
7. Stewart SM, Mackie IC. Establishment and evaluation of a trauma clinic based in a primary care setting. Int J Paediatr Dent. 2004;14: 409-16.
8. Al-Shamiri HM, AlShalawi FE, AlJumah TM, AlHarthi MM, AlAli EM, AlHarthi HM. Knowledge, attitude and practice of hepatitis b virus infection among dental students and interns in saudi arabia. J Clin Exp Dent. 2018;10: e54-e60.
9. Cohenca N, Forrest JL, Rotstein I. Knowledge of oral health professionals of treatment of avulsed teeth. Dent Traumatol. 2006;22: 296-301.
10. Gagnier JJ, Kienle G, Altman DG, Moher D, Sox H, Riley D. The care guidelines: Consensus-based clinical case report guideline development. Journal of Clinical Epidemiology. 2014;67: 46-51.
11. Fagundes NCF, Bittencourt LO, Magno MB, Marques MM, Maia LC, Lima RR. Efficacy of hank's balanced salt solution compared to other solutions in the preservation of the periodontal ligament. A systematic review and meta-analysis. PLoS One. 2018;13: e0200467.
12. Menezes MC, Carvalho RG, Accorsi-Mendonca T, De-Deus G, Moreira EJ, Silva EJ. Knowledge of dentists on the management of tooth avulsion injuries in rio de janeiro, brazil. Oral Health Prev Dent. 2015;13: 457-60.
13. Veras SRA, Bem JSP, de Almeida ECB, Lins C. Dental splints: Types and time of immobilization post tooth avulsion. J Istanb Univ Fac Dent. 2017;51: S69-S75.
14. Consolaro A. The four mechanisms of dental resorption initiation. Dental Press J Orthod. 2013;18: 7-9.
15. Siqueira JF, Jr., Lopes HP. Mechanisms of antimicrobial activity of calcium hydroxide: A critical review. Int Endod J. 1999;32: 361-9.
16. Lin S, Tsesis I, Zukerman O, Weiss EI, Fuss Z. Effect of electrophoretically activated calcium hydroxide on bacterial viability in dentinal tubules—in vitro. Dent Traumatol. 2005;21: 42-5.
17. Chai WL, Hamimah H, Cheng SC, Sallam AA, Abdullah M. Susceptibility of enterococcus faecalis biofilm to antibiotics and calcium hydroxide. J Oral Sci. 2007;49: 161-6.