ALAGILLE SYNDROME: FACIAL CHARACTERISTICS, RARE ORAL MANIFESTATIONS, AND MANAGEMENT OF THE CASE

Camila **Nassur**[1], Adílis **Alexandria**[1,2*], Sabrina Loren de Almeida **Salazar**[1], Luciana **Pomarico**[1], Gloria Fernanda Barbosa de Araújo **Castro**[1]

[1] Department of Pediatric Denstry and Orthodontics, Universidade Federal do Rio de Janeiro, Rio de Janeiro, Rio de Janeiro, Brazil.
[2] Department of Preventive and Community Dentistry, Universidade do Estado do Rio de Janeiro, Rio de Janeiro, Rio de Janeiro, Brazil.

Palavras-chave: Síndrome de Alagille. Hiperplasia Gengival. Fibroma Ossificante Periférico.

RESUMO

Introdução: A síndrome de Alagille (AGS) é uma doença autossômica dominante com expressividade variável que podem afetar o fígado, coração, rins, vasos sanguíneos, olhos, rosto e esqueleto. **Objetivo**: Descrever um caso de um paciente pediátrico com síndrome de Alagille. **Relato do caso**: A história familiar era negativa até mesmo para as manifestações mais leves de AGS. Clinicamente, o paciente apresentava face triangular, hipertelorismo, filtro curto e face média plana. O exame intraoral revelou ausência dos incisivos laterais superiores permanentes, hipoplasia de esmalte e aspecto esverdeado em alguns dentes, hiperplasia gengival, retenção de dois incisivos inferiores decíduos, presença de um dente supranumerário, e um nódulo de tecido mole pediculado na face lingual do primeiro molar inferior permanente esquerdo. **Resultados**: O tratamento odontológico exigiu a extração dos dentes decíduos retidos e do dente supranumerário, biópsia excisional e exame histopatológico da lesão além da aplicação de fluoreto tópico. Também foi realizada instrução dietética e de higiene oral. **Conclusão**: Atualmente, o paciente faz visitas de acompanhamento frequentes para monitorar o desenvolvimento dentário.

Keywords: Alagille Syndrome. Gingival Fibromatosis. Ossifying Fibroma.

ABSTRACT

Introduction: Alagille syndrome (AGS) is an autosomal dominant disease with variable expressiveness that can affect the liver, heart, kidneys, blood vessels, eyes, face and skeleton. **Objective**: To describe a case of a pediatric patient with Alagille syndrome. **Case report**: The family history was negative for even the mildest manifestations of AGS. Clinically, the patient had a triangular face, hypertelorism, short philtrum and flat midface. Intraoral examination revealed the absence of the permanent upper lateral incisors, enamel hypoplasia and a greenish color in some teeth, gingival hyperplasia, retention of two primary lower incisors, presence of a supernumerary tooth, and a pediculated nodule of soft tissue on the lingual aspect of the left permanent mandibular first molar. **Results**: The dental treatment required the extraction of the retained primary teeth and the supernumerary tooth, excisional biopsy and histopathological examination of the lesion were performed and also application of topical fluoride. Also dietary and oral hygiene instructions were given. **Conclusion**: Currently, the patient makes frequent follow-up visits to monitor the dental development.

Submitted: February 23, 2020
Modification: July 26, 2021
Accepted: August 05, 2021

***Correspondence to**:
Adílis Kalina Alexandria
Address: Departamento de Odontologia Preventiva e Comunitária, Faculdade de Odontologia, 2º andar, Pavilhão Mario Franco Barroso, Universidade do Estado do Rio de Janeiro. Rio de Janeiro - RJ, Brazil.
E-mail: adilis.alexandria@gmail.com.br

INTRODUCTION

Alagille Syndrome (AGS), also known as arteriohepatic dysplasia, is an autosomal dominant developmental disorder.[1] AGS was first reported by Alagille *et al.*[2] and is characterized by paucity of intrahepatic bile ducts, in association with five main clinical abnormalities: low birth weight, growth retardation, vertebral anomalies, cardiovascular and hepatic complications.[1,3,4]

The severity of the disorder can vary within the same family, with symptoms ranging from so mild that they go unnoticed to severe heart and/or liver disease requiring transplantation. The symptoms are usually observed in the first 2 years of life. Some patients can die before the age of five due to the cardiovascular and hepatic complications.[3,4]

Facial and oral findings are important considerations in the management and planning of dental treatment for patients with AGS. The aim of this article is to present a case of Alagille Syndrome in a pediatric patient, describing the facial and rare dental abnormalities.

CASE REPORT

A 13-year-old female, leucoderma, and diagnosed with the Alagille Syndrome was referred by her pediatric doctor to the Pediatric Dentistry Department of a public university in Rio de Janeiro, Brazil, for a dental appointment.

The medical history revealed that she was jaundiced at birth and 4 months after she underwent laparotomy, intraoperative cholangiogram and a liver biopsy. The result of the biopsy revealed paucity of the interlobular bile ducts. An echocardiogram also showed the presence of peripheral pulmonary artery stenosis. The patient also presented hepatosplenomegaly but without ascites and edema. Further evaluation demonstrated pulmonary artery stenosis, bilateral posterior embryotoxon, and vertebral abnormalities. A diagnosis of AGS was made. The family history was negative for even the mildest manifestations of AGS. When she was 5 years old, she underwent an orthotopic liver transplantation. She has been placed on cyclosporine, prednisolone and multivitamins.

Extraoral examination revealed a triangular face, consisting of a prominent forehead, deep-set eyes, hypertelorism, long, straight nose with flattened tip, short philtrum, flat midface and a triangular chin (Figure 1A).

Intraoral examination revealed the absence of the permanent upper lateral incisors, presence of enamel hypoplasia and a greenish color in some teeth, with the stain varying in degree and extension. The teeth showed a thin line of green pigmentation in the cervical third (Figure 1B and 1C). Gingival hyperplasia was also observed at the anterior teeth. Further examination revealed a localized pedunculated nodule (2 x 1,5 cm) on the lingual aspect of the left permanent mandibular first molar (Figure 1C). Good oral hygiene was reported, no caries were found, but an anterior cross bite was observed. Other oral manifestations such as prolonged retention of two primary lower incisors and the presence of one supernumerary tooth in the same region were also observed.

The radiography examination confirmed the agenesis of the upper lateral incisors, presence of the retained primary incisors and the supernumerary tooth (Figure 2).

The proposed treatment included the extraction of the retained primary teeth and the supernumerary tooth, as well as a fluoride application (varnish) on the teeth with hypoplasia. Also dietary and oral hygiene instructions were given to the parents. Excisional biopsy and histopathological examination of the lesion were performed. The differential diagnosis was established with pyogenic granuloma, traumatic fibroma, and peripheral giant cell granuloma. The family was informed about the likely benign nature of the lesion. Histopathological analysis revealed a peripheral ossifying fibroma. Follow-up visits were scheduled to allow the continuous monitoring of dental development. The patient was referred for orthodontic treatment.



***Figure 1**: A) Extraoral clinical photograph: triangular face, prominent forehead, deep-set eyes, hypertelorism, long, straight nose with flattened tip, short philtrum, flat midface and a triangular chin; B) Intrabucal clinical photograph: Gingival enlargements firm, pale red, and resilient, with a lobulated surface and C) Intrabucal clinical photograph: Pedunculated nodule on the lingual aspect of the left permanent mandibular first molar.*

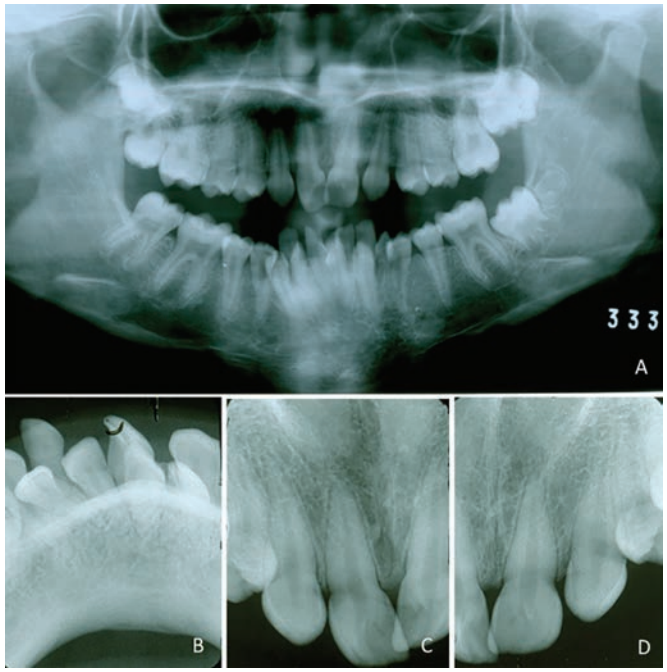

***Figure 2**: A) Panoramic radiograph, B) Periapical radiographs showing presence of retained primary incisors and a supernumerary tooth, and periapical radiographs confirmed the agenesis of the upper right C) and left D) lateral incisors.*

DISCUSSION

Alagille Syndrome is inherited in an autosomal dominant manner and genetic studies have revealed that mutations in the Jagged 1 (JAG1) gene, encoding a ligand for the Notch receptor, are responsible for this syndrome.[1,5]

Subjects commonly present chronic cholestasis, cardiac, skeletal abnormalities, ocular abnormalities, and characteristic facial features[3]. Patients with AGS present the characteristic facial features that include a prominent forehead, hypertelorism with deep-set eyes, pointed chin, or a straight nose with a bulbous tip.[4,5] These findings coincide with our case report. Also, the oral findings reported teeth with a grayish intrinsic discoloration with focal areas of white and yellow patches and enamel hypoplasia, gingival inflammation, talon cusps, oral xanthomas and severe hypodontia.[4-7]

The presence of the prolonged retention of primary incisors, a supernumerary tooth and absence of the permanent upper lateral incisors had not been previously described in the literature in AGS patients. Ho *et al*.[8] reported the case of a three-year-old patient with severe hypodontia in primary dentition. Chatterjee and Mason[6] report alterations in teeth form, but no number abnormality. Clinical problems associated with prolonged retention of deciduous teeth have also included the possibility of malocclusion, a shift in the normal midline of the patient's dentition, difficulty in maintaining dental hygiene and crowding.

The intrinsic pigmentation and enamel hypoplasia presented in this case are probably associated to hyperbilirubinemia, which must have occurred during enamel and dentin formation, resulting in dental pigmentation, due to accumulation of intrinsic staining by bilirubin oxidation.[9] The diagnosis of bilirubin pigmentation is usually based on a clinical history of jaundice combined with green tooth discoloration and less often enamel hypoplasia.[7]

Patients who have undergone organ transplant surgery are at increased risk for serious infection and require lifelong immunosuppressive therapy.[10,11] The side effects of these drugs include an increased susceptibility to infections.[11] Organ transplant recipients may be taking one or more medications that affect dental treatment. It is very important that dentists are aware of the side effects of these medications, which range from xerostomia and gingival hyperplasia to orthostatic hypotension and hyperglycemia. Cyclosporine A has been the primary tool used to prevent rejection of organ transplants and its clinical use is often complicated due to adverse effects including nephrotoxicity, hepatotoxicity, neurotoxicity, hypertension and gingival overgrowth.[12,13] The gingival fibrous hyperplasia associated with cyclosporine A therapy are described in this case, the patient took the cyclosporine for 9 years.

Some immunosuppressive agents can interact with other commonly prescribed drugs, so, the decision to premedicate for invasive dental procedures and selection of the appropriate regimen should be made upon in

consultation with the patient's physician.[11] In this case, according to her doctor, it was necessary to use medicine before the dental procedures.

It is important to make a basic therapeutic approach to reduce the risk for recurrence of gingival overgrowth; it is essential to improve oral hygiene and the execution of procedures to control periodontal disease. If the patient uses drugs that induce the gingival growth, it is important to evaluate the possibility of replacing them with other medications.[11] In more critical cases, surgical removal must be performed to reestablish the anatomy and physiology of the gingival tissue with better control of the dental biofilm.

Peripheral ossifying fibroma (POF) is a lesion of the gingival tissues[14] representing up to 2% of all oral lesions that are biopsied.[15] Garcia *et al*. (2013)[15] underline the non-neoplastic nature of the POF. It is a condition of the inflammatory reaction associated with mineralization and derived from the periodontal ligament cells. The etiology and pathogenesis of POF remains unknown, but it has been observed in conditions associated with known genetic mutations, such as the nevoid basal cell carcinoma syndrome, multiple endocrine neoplasia type II, neurofibromatosis and the Gardner syndrome.[16]

The lesions of POF are most often found in the gingival, located anteriorly to the molars and on the maxilla.[17] In this study, the lesion was exophytic and pedunculated and was located beside the molars on the mandible. There is an association between Alagille Syndrome and multiple central giant cell granulomas of the mandible.[1,3-5] However, there is no evidence to support the association between Alagille Syndrome and FOP.

CONCLUSION

This case describes an uncommon oral manifestation and some important aspects concerning diagnosis and avoidance of complications associated with AGS. The diagnosis can be difficult in a family without AGS classical features, being a challenge to clinical treatment decisions. Confirming the need for the dentist to keep a specific approach to patients suffering from systemic diseases. Early professional advice and treatment, as well as periodical follow-ups, can improve the quality of the lives of these patients.

REFERENCES

1. Turnpenny PD, Ellard S. Alagille syndrome: pathogenesis, diagnosis and management. Eur J Hum Genet. 2012; 20: 251-257. doi: 10.1038/ejhg.2011.181.

2. Alagille D, Odièvre M, Gautier M, Dommergues JP. Hepatic ductular hypoplasia associated with characteristic facies, vertebral malformations, retarded physical, mental, and sexual development, and cardiac murmur. J Pediatr. 1975; 86:63-71. doi: 10.1016/s0022-3476(75)80706-2.

3. Rapp JB, Bellah RD, Maya C, Pawel BR, Anupindi SA. Giant hepatic regenerative nodules in Alagille syndrome. Pediatr Radiol. 2017; 47(2):197-204. doi: 10.1007/s00247-016-3728-2.

4. Jesina D. Alagille Syndrome: An Overview. Neonatal Netw. 2017; 36(6):343-347. doi: 10.1891/0730-0832.36.6.343. doi: 10.1891/0730-0832.36.6.343.

5. Benabed Y, Chaillou E, Denis MC, Simard G, Reynier P, Homedan C. Alagille syndrome: a case report. Ann Biol Clin. 2018; 76(6):675-680. doi: 10.1684/abc.2018.1399.

6. Chatterjee M, Mason C. Talon Cusps Presenting in a Child with Alagille´s Syndrome – A Case Report. J Clin Pediatr Dent. 2007; 32: 61-64. doi: 10.17796/jcpd.32.1.c041035j626wj573.

7. Lamba G, Nagpal DI, Korishettar R. Green Pigmentation of Teeth Caused by Neonatal Cholestatic Jaundice and Sepsis: A Case Report. Int J Clin Pediatr Dent. 2019;12(6):566-568. doi: 10.5005/jp-journals-10005-1696.

8. Ho NC, Lacbawan F, Francomano CA, Ho V. Severe hypodontia and oral xanthomas in Alagille syndrome. Am J Med Genet.2000; 93:250-2. doi: 10.1002/1096-8628(20000731)93:3<250::aid-ajmg18>3.0.co;2-a.

9. Rakauskaite A, Juodzbalys G, Pauza DH, Cicciù M. Green pigmentation in human teeth. A stereomicroscopic study. J Clin Pediatr Dent. 2014; 38(4):355-61. doi: 10.17796/jcpd.38.4.057t211602x447j8.

10. Helenius-Hietala J, Meurman JH, Höckerstedt K, Lindqvist C, Isoniemi H. Effect of the aetiology and severity of liver disease on oral health and dental treatment prior to transplantation. Transpl Int. 2012; 25(2):158-65. doi: 10.1111/j.1432-2277.2011.01381.x.

11. Hogan J, Pietrement C, Sellier-Leclerc AL, Louillet F, Salomon R, Macher MA, Berard E, Couchoud C. Infection-related hospitalizations after kidney transplantation in children: incidence, risk factors, and cost. Pediatr Nephrol. 2017; 32(12):2331-41. doi: 10.1007/s00467-017-3737-x.

12. Gandhi M, Rai E, Shirley A, Suda NK. Massive gingival bleed: a rare manifestation of cyclosporine toxicity. BMJ Case Rep. 2020; 13(12):e236828. doi: 10.1136/bcr-2020-236828.

13. Paul LC. Overview of side effects of immunosuppressive therapy. Transplant Proc. 2001; 33: 2089-2091. doi: 10.1016/s0041-1345(01)01959-5.

14. Carrera GI, Berini AL, Escoda CG. Clinicopathological features of peripheral ossifying fibroma in a series of 41 patients. Br J Oral Maxillofac Surg. 2019; 57(10):1081-1085. doi: 10.1016/j.bjoms.2019.09.020.

15. Garcia BG, Caldeira PC, Johann ACBJ, de Sousa SCOM, Caliari MV, Carmo MAV, et al. Cellular proliferation markers in peripheral and central fibromas: a comparative study. J Appl Oral Sci. 2013; 21:106-111. doi: 10.1590/1678-7757201302116

16. de Marcos JG, Rodriguez SA, Rodrigo JC, Poblet E. Peripheral

ossifying fibroma: a clinical and immunohistochemical study of four cases. J Oral Sci. 2010; 52: 95-99. doi: 10.2334/josnusd.52.95.

17. Lázare H, Peteiro A, Pérez Sayáns M, Gándara-Vila P, Caneiro J, García-García A, Antón I, Gándara-Rey JM, Suárez-Peñaranda JM. Clinicopathological features of peripheral ossifying fibroma in a series of 41 patients. Br J Oral Maxillofac Surg. 2019;57(10):1081-85. doi: 10.1016/j.bjoms.2019.09.020.