# DENTAL RADIOGRAPHIC ANATOMY ANALYSIS FOR IDENTIFICATION OF A CARBONIZED BODY: CASE REPORT

Millena Gonçalves de Souza **Gomes**[1*], Vanessa Moreira **Andrade**[2], Annie Seabra de **Medeiros**[2], Andreia Cristina Breda de **Souza**[2,3], Maria Augusta **Visconti**[1]

[1]Department of Oral Pathology and Diagnosis, Dental School of the Universidade Federal do Rio de Janeiro, Rio de Janeiro, Rio de Janeiro, Brazil.
[2]Forensic Odontology Service, Instituto de Medicina Legal Afrânio Peixoto, Rio de Janeiro, Rio de janeiro, Brazil.
[3]Department of Social and Preventive Dentistry, Dental School of the Universidade Federal do Rio de Janeiro, Rio de Janeiro, Rio de Janeiro, Brazil.

**Palavras-chave**: Identificação de Vítimas. Odontologia Legal. Cadáver. Radiografia.

**RESUMO**

**Introdução**: Os exames de imagem odontológicos fornecem um importante auxílio para os odontolegistas em casos de identificação cadavérica. Porém, em alguns casos, tal auxílio se torna essencial, como nos casos em que todas as coroas dentárias se encontram hígidas e quando ocorre perda da estrutura coronária, podendo ser devido à ação térmica. **Objetivo**: Relatar um caso em que odontolegistas identificaram um cadáver através de comparações radiográficas. **Relato do caso**: Em 2018, um cadáver carbonizado no interior de um veículo incinerado foi encaminhado para exame visando sua identificação. A análise comparativa utilizou diferentes tipos de exames bidimensionais: uma radiografia panorâmica *antemortem* e radiografias periapicais *postmortem*. Houve total concordância da anatomia dentária radiográfica, destacando-se a angulação das raízes, morfologia dos condutos radiculares, regiões de furca, ápices radiculares, forma das câmaras pulpares e regiões do trabeculado alveolar relativos a ambas as arcadas, além de uma cavidade localizada na face oclusal do primeiro molar inferior direito. **Conclusão**: A compatibilidade da anatomia dentária observada através das radiografias foi primordial para um resultado positivo do processo de identificação odontológica.

**Keywords**: Victims Identification. Forensic Dentistry. Cadaver. Radiography.

**ABSTRACT**

**Introduction**: Dentistry imaging is responsible for providing paramount support for forensic odontologists in cases of cadaveric identification. Nevertheless, in some cases, this assistance becomes essential, as in cases in which all the crowns have proven to be in perfect health standards, and when the dentist is able to identify loss of crown structural integrity, which can occur due to intense thermal action. **Objective**: To report a case in which forensic odontologists identified a cadaver through radiographic comparisons. **Case report**: In 2018, a carbonized bodyfound inside an incinerated vehicle was referred to an examination aiming its identification. The comparative analysis used different types of bidimensional images: *antemortem* panoramic radiograph and *postmortem* periapical radiographs. There was a total agreement of the dental radiographic anatomy, with emphasis on the root angulation, morphology of root canals, furcation regions, root apexes, the shape of pulp chambers and regions of alveolar trabecular related to both arches, as well as a cavity located in the occlusal surface of the lower right first molar. **Conclusion**: The compatibility of dental anatomy analyzed through the radiographs was fundamental for a positive result of the dentistry identification process.

Submitted: March 12, 2020
Modification: July 18, 2021
Accepted: July 30, 2021

***Correspondence to:**
Millena Gonçalves de Souza Gomes
Address: Rua Coronel Eurico de Souza Gomes Filho, número 515, apartamento 301. Rio de Janeiro – Rio de Janeiro, Brazil. Zip Code: 22620-320
Telephone number: +55 (21) 9 8788-0191.
E-mail: sgomesmillena@gmail.com

## INTRODUCTION

One of the objectives of forensic dentistry is the determination of human identity through the comparison and compatibility of *antemortem* (AM) and *postmortem* (PM)[1-4] records, by utilizing all documentation present in the patient dental documentation, including examinations related to dental treatments.[5] Therefore, dental identification is based on verifying the particularities of dental nature between the dental records relating to examination and/or treatments conducted whilst the patient was alive, and those particularities observed in the cadaver.[6-11]

In accordance with the INTERPOL guide for Disaster Victim Identification[12], dental analysis is considered a primary method of identification, being a reliable method to confirm the identity, together with friction ridge analysis and DNA analysis. The analysis of the dental arches by the forensic dentists fills the biological demands for an identification method to be considered valid (individuality, perpetuation and immutability), as well as the technical demands (practicability and classifiable).[13]

The *postmortem* radiographical exam was introduced into the forensic dentistry routine in 1898[14], ever since studies have been conducted showing and reiterating the importance of forensic dentists conducting intraoral radiographs. These must cover all dental support locations, including the edentulous areas, to achieve knowledge on unerupted teeth, extracted roots and anatomical structures.[5,6,9-11,16-19]

The specific techniques to be applied in each individual case will depend crucially on the quality and types of *antemortem* radiographs available to the forensic dentists.[15,16]

The objective of the present article was to report a case of human identification, beginning with the confrontation of the dental characteristics observed in an *antemortem* panoramic radiograph and those verified in *postmortem* periapical radiographs, laying the foundation of the essential aspects that involve the process of dental identification, as well as, highlighting its advantages and limitations.

## CASE REPORT

In August 2018, a carbonized corpse was found inside an incinerated vehicle, the body was then referred to the Legal Medical Institute Afrânio Peixoto in Rio de Janeiro – Brazil so that its cause of death could be determined, and a human identification examination could be conducted. On external examination, despite the severe carbonization, it was possible to state that the deceased was an adult male. Due to the intense carbonization, it was not possible to determine the cause of death with the necroscopic exam identifying that the upper and lower airways did not present any sign of soot.

The family members of a missing adult male went to the Forensic Dentistry Sector of the Legal Medical Institution, bringing the *antemortem* dental documentation, seeking a comparative analysis with the aforementioned corpse (Figure 1). The *antemortem* documentation was composed by panoramic radiography and five digitalized photos, both dated February 2017, being three intraoral photos (smiling, right lateral and left lateral - all conducted with teeth in occlusion) and two extraoral photos (smiling with teeth in occlusion and right lateral profile with pursed lips). The *antemortem* dental documentation also contained a declaration from the dentist hired by the man, dated August 2018, informing the beginning of the orthodontic treatment in February 2017, with the installation of a fixed orthodontic appliance in both arches, a dental cleaning and made the mentioned photos. In addition, the declaration also reported the patient return in April 2017 for installation of orthodontic bands, and after this date, the dentist had no more contact with the patient.

When analyzing the dental records provided by the family, it was possible to identify in the panoramic radiograph (Figure 2) the clinical situations described in Table 1 and the root configuration of the teeth that presented healthy roots in Table 2.

The team of forensic dentists on duty conducted ten periapical radiographs of the corpse using parallelism technique with positioners with a conventional device of periapical radiography. The jaws were placed on the sector's bench protected with a plastic film. Five images were of the maxilla (Figure 3) and five of the mandible (Figure 4), then overlaps and comparisons were made with the PowerPoint program between the *antemortem* panoramic radiograph and the *postmortem* periapical radiographs.

The clinical situations present in Table 3 were possible to be observed in the *postmortem* periapical radiographs.

Regarding the anatomical dental and alveolar characteristics, it was noted a total and complete agreement between the *antemortem* and *postmortem* images, highlighting the location, contour, and extension of the cavity on the occlusal face of tooth 46 (Figure 5), the root angulation, root canal morphology, furcation regions and root apexes (Figure 6), the shape of pulp chambers (Figure 7), and regions of alveolar trabecular (Figure 8) related to both arches.

Given the above, specific correspondences were verified between all the characteristics in the cadaveric examination with those obtained from the *antemortem* documentation, furthermore, no incompatibility or inconsistency was verified when the data was confronted. The results of this investigation allowed the dentists to conclude the identification as positive.

According to the American Board of Forensic Odontology guidelines,[20] the results of this investigation allowed the dentists to conclude the identification as positive, in other words, the *antemortem* and *postmortem* data match in sufficient detail to establish that they are from the same individual, with no unexplained discrepancy.

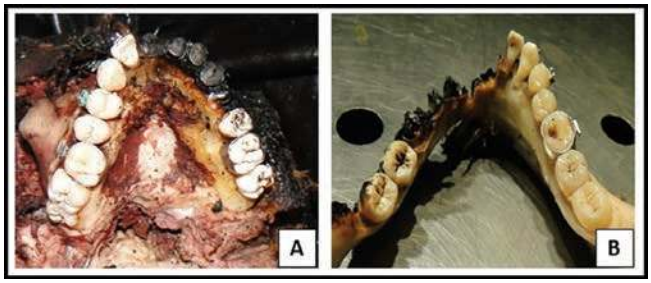


***Figure 1**: Top view photographs of the charred corpse. A) Maxilla; B) Mandible.*



***Figure 2**:* Antemortem *panoramic radiograph provided by the family.*

***Table 1**: Dental configuration extracted from* antemortem *panoramic radiography of upper and lower teeth.*

| Upper teeth | Note | Lower teeth | Note |
|---|---|---|---|
| 18 | Infraocclusion | 38 | H |
| 17 | H | 37 | H |
| 16 | H | 36 | H |
| 15 | H | 35 | H |
| 14 | H | 34 | H + BR |
| 13 | H | 33 | H + BR |
| 12 | H | 32 | H + BR |
| 11 | Caries (IM) | 31 | H + BR |
| 21 | MR (IM) | 41 | H |
| 22 | H | 42 | H + BR |
| 23 | H | 43 | H + BR |
| 24 | H | 44 | H + BR |
| 25 | H | 45 | H |
| 26 | H | 46 | Caries (O) |
| 27 | H | 47 | H |
| 28 | Infraocclusion | 48 | H |

*Note: H: Healthy; BR: Orthodontic bracket; MR: Mimetic restoration; IM: Incisal mesium; O:Occlusal.*

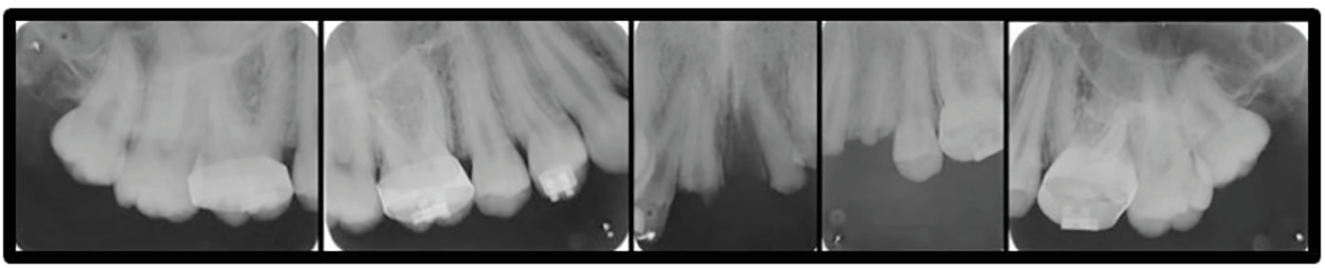

***Figure 3**: Postmortem periapical radiographs of the maxilla.*

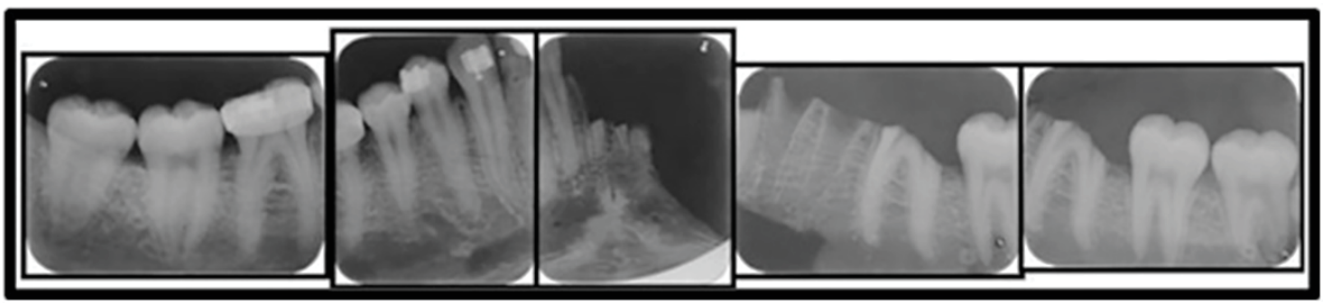

**Figure 4**: *Postmortem periapical radiographs of the mandible*

***Table 2**: Root configuration of teeth with intact roots.*

| Tooth | Root configuration |
|---|---|
| 18 | Fusion roots and distal tilt |
| 17 | Pulp narrowing and parallel and straight roots |
| 16 | Pulp narrowing and converging roots |
| 14 | Distal curvatures in the cervical third of its roots |
| 12 | Mesial curvatures in the middle and apical third of its roots |
| 11 | Distal curvatures of the apical thirds of its roots |
| 21 | Distal curvatures of the apical thirds of its roots |
| 22 | Mesial curvatures in the middle and apical third of its roots |
| 24 | Distal curvatures in the cervical third of its roots |
| 26 | Pulp narrowing and divergent roots |
| 27 | Pulp narrowing and parallel and straight roots |
| 28 | Fusion roots with distal inclination and root laceration |
| 38 | Converging roots and open apical end |
| 37 | Wide Pulp chamber and parallel and straight roots with pulp narrowing, mesial pulp horn higher than the distal |
| 36 | Relatively parallel roots, with apex slightly curved to distal |
| 45 | Mesial curvatures in the middle third of its roots |
| 46 | Pulp narrowing and relatively parallel roots |
| 47 | Wide Pulp chamber and converging roots |
| 48 | Fusion roots and exposed apical end |

***Table 3**: Odontogram filled out from* postmortem *periapical radiographs.*

| Upper teeth | Note | Lower teeth | Note |
|---|---|---|---|
| 18 | H | 38 | H |
| 17 | H | 37 | H |
| 16 | H + B + BR | 36 | TAF |
| 15 | H | 35 | PMA |
| 14 | H + BR | 34 | PMA |
| 13 | H | 33 | TAF |
| 12 | H | 32 | BSM |
| 11 | TAF | 31 | RR |
| 21 | TAF | 41 | RR |
| 22 | TAF | 42 | H + BR |
| 23 | TAF | 43 | H + BR |
| 24 | TAF | 44 | H + BR |
| 25 | H | 45 | H |
| 26 | H + B + BR | 46 | H + B + BR |
| 27 | H | 47 | H |
| 28 | H | 48 | H |

*Note: H: Healthy; B: Orthodontic band; BR: Orthodontic bracket; TAF: Thermal action fracture; PMA:* postmortem *avulsion; BSM: Bone segment missing due to thermal action; RR: Root remnant due to thermal action.*

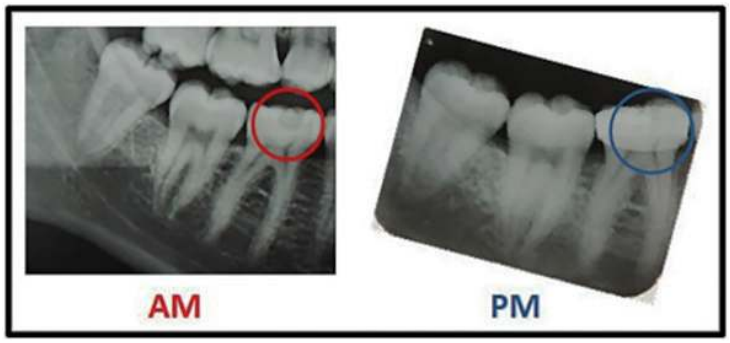


***Figure 5**: Comparison of the shape of the cavity in the tooth crown 46. AM: antemortem; PM: post mortem.*

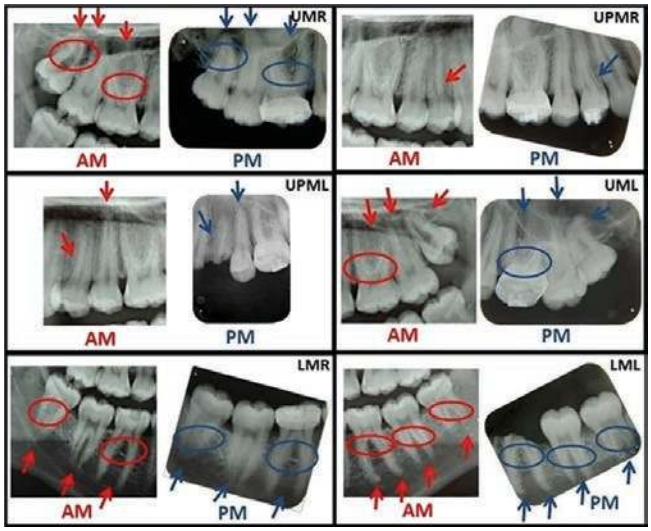


***Figure 6**: Comparison of the angulation of the roots, root canal, furcation regions and root apexes. UMR: região molar superior do lado direito; AM: antemortem; PM: post mortem; UPMR: região pré-molar superior do lado direito; UPML: região pré-molar superior do lado esquerdo; UML: região molar superior do lado esquerdo; LMR: região molar inferior do lado direito; LML: região molar inferior do lado esquerdo.*

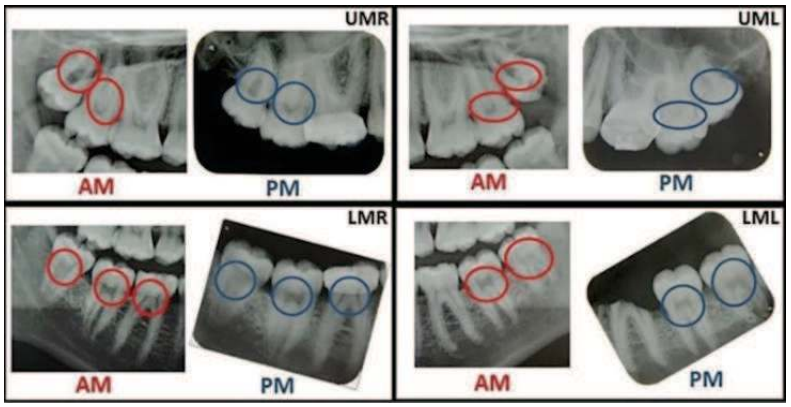


***Figure 7**: Comparison of the shape of the pulp chambers. UMR: região molar superior do lado direito; AM: antemortem; PM: post mortem; UML: região molar superior do lado esquerdo; LMR: região molar inferior do lado direito; LML: região molar inferior do lado esquerdo.*

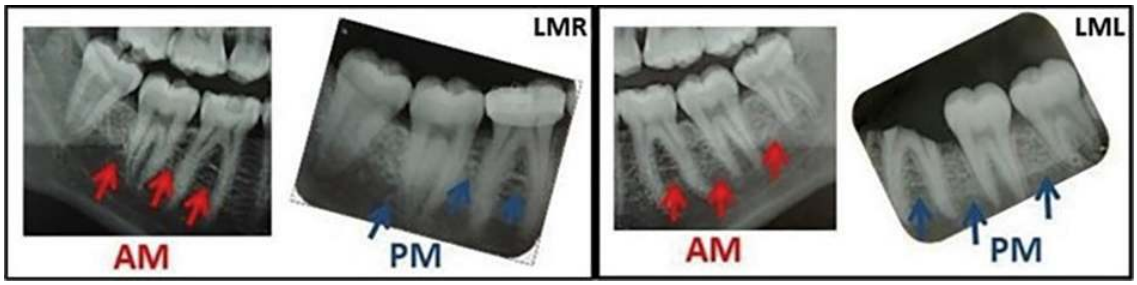


***Figure 8**: Comparison of regions of the alveolar trabeculate. AM: antemortem; PM: post mortem; LMR: região molar inferior do lado direito; LML: região molar inferior do lado esquerdo.*

## DISCUSSION

The carbonization condition of the corpse prevented the use of the most employed primary method of identification, the dactyloscopy or friction ridge analysis, due to dehydration on the regions of the digital, being impossible its analysis. With this, in carbonized cadavers the dental analysis is the preferred method of identification, having seen the teeth and restorative materials resistance in relation to the termal act.[4,5,17,19]

Combination of morphological, pathological, and therapeutic dental characteristics is employed to distinguish individuals, where the cumulative effects of these particularities, when positive, increases the practical importance for the result of identification.[6,14,18,21,22]

The comparison of the aforementioned dental characteristics, when recorded in written form in *antemortem* documents, might contain errors and a lack of details,[12] while comparing them based on *antemortem* radiographs provides objective and reliable data. Thus, as in this case report, several studies have cited positive comparisons between *antemortem* and *postmortem* dental radiographs, either by comparing the images in parallel or by overlapping.[4,5,7-9,11,15,17,19,21,22]

According to Scoralick *et al.*[19], considering the reality of forensic activity in Brazil, the comparison between radiographs is beneficial, as it is a low-cost and effective method.

In the present report, the comparative analysis was based on radiographic exams with distinct characteristics and objectives, with panoramic radiography being the source of *antemortem* information that allowed the adequate extraction of data of the forensic dentistry confrontation.

Characteristics such as tooth positioning, root, pulp and crown shape are unique for each individual,[19] and it is notorious that dental roots preserve morphological information for longer periods when compared to crowns,[11,16] highlighting the importance of radicular radiographic analysis for cases of cadaveric dental identification.

Attributable to the high temperature to which the cadaver was exposed, it resulted in the loss of teeth, either due to fracture at the cervical level, reduction to the root remnant, *postmortem* avulsion, or absence of a bone segment with the specific tooth, making human identification extremely difficult. However, the analysis of the root angulation and root apices of the teeth present, as well as the analysis of the bone trabeculate and the furcation region of the molars were indispensable to the establishment of the identification once the incinerated corpse did not possess all its intact teeth in the arch on account of the carbonization.

In addition to the thermal action, which can hinder dental identification due to loss of tooth structure, another challenge for forensic dentists is the expansion and popularization of prophylactic dental treatments, responsible for significantly diminishing the incidence of caries, making the process of dental identification burdensome,[21,23] as there is a consequent reduction in the need for restorative interventions. Therefore, dental identification is more laborious and must be done through morphological identifiers as was done in the present case report, being different from that presented in other articles[5,7,11,17-19] which compared *antemortem* and *postmortem* dental interventions. The difficulty in the identification process was highlighted by Forrest[16] who cited that in the absence of restorations or evidence of other dental treatment, anatomical features, including dental morphology, sinuses, and bone morphology, can be used, nevertheless, the level of work demanded is increased as it becomes a more straining process.[16]

Another point that can be highlighted is the fact that the *antemortem* documentation dated February 2017 and the cadaveric exam was performed in August 2018, having a time gap of more than a year. However, the compared characteristics for identification as the root angulation, morphology of root canals and shape of pulp chambers do not change as time went on. In a different manner, in the analysis of restorative treatments, a time gap can difficult

the identification process, due to the new dental treatments that could be conducted in this time interval.

In the present case, the predominance of healthy teeth and the quality and compatibility of the anatomical aspects present on the radiographs led the experts to the conclusion of identification as positive. As a limitation, it was not possible to compare the mandibular canal and maxillary sinus anatomy due to periapical radiographs do not cover these regions.

# CONCLUSION

In summary, this report demonstrated that aspects of the dental and alveolar root anatomical structure observed through *postmortem* radiographs were essential for the dental identification process, allowing an objective comparison with *antemortem* radiographs. In addition, different types of *antemortem* and *postmortem* dental images can be used for cadaveric identification through radiographic comparison.

## Acknowledgments

The authors would like to thank the director of the Legal Medical Institute Afrânio Peixoto for allowing the disclosure of this case.

## REFERENCES

1. Brown KA. Procedures for the collection of dental records for person identification. J Forensic Odontostomatol. 2007; 25(2):63-4.

2. Chiam SL, Page M, Higgins D, Taylor J. Validity of forensic odontology identification by comparison of conventional dental radiographs: a scoping review. Science & Justice. 2019;59: 93-101. doi: 10.1016/j.scijus.2018.08.008.

3. Manica S. A new website to aid the interpretation of antemortem dental records: www.internationaldentalcharts.org. J Forensic Odontostomatol. 2014; 32(2):1-7.

4. Musse JO, Marques JAM, Vilas Boas CDF, Sousa SRV, Oliveira RN. Importância pericial das radiografias panorâmicas e da análise odontológica para identificação humana: relato de caso. Rev Odontol UNESP. 2011;40(2): 108-111.

5. Caputo IGC, Reis JN, Silveira TCP, Guimarães MA, Silva RHA. Identification of a charred corpse through dental records. RSBO. 2011;8(3):345-51.

6. Angelakopoulos N, Franco A, Willems G, Fieuws S, Thevissen P. Clinically Detectable Dental Identifiers Observed in Intra-oral Photographs and Extra-oral Radiographs, Validated for Human Identification Purposes. J Forensic Sci. 2017;62(4):900-6. doi: 10.1111/1556-4029.13310.

7. Blakaj F, Bicaj T, Bicaj B. Dental Identification of a Decomposed Body. Med Arh. 2010;64(2):125-6.

8. Blau S, Hill A, Briggs CA, Cordner SM. Missing Persons-Missing Data: The Need to Collect Antemortem Dental Records of Missing Persons. J Forensic Sci. 2006;51(2):286-9. doi: 10.1111/j.1556-4029.2006.00051.x.

9. Campobasso CP, Dell'Erba AS, Belviso M, Di Vella G. Craniofacial Identification by Comparison of Antemortem and Postmortem Radiographs Two Case Reports Dealing with Burnt Bodies. Am J Forensic Med Pathol. 2007;28(2):182-6. doi: 10.1097/PAF.0b013e31806195cb.

10. Chen H, Jain AK. Dental Biometrics: Alignment and Matching of Dental Radiographs. IEEE Trans Pattern Anal Mach Intell. 2005;27(8):1319-26.

11. Silva RF, Franco A, Mendes SDSC, Picole FF, Nunes FG, Estrela C. Identifying murder victims with endodontic radiographs. J Forensic Dent Sci. 2016;8(3):167-70. doi:10.4103/0975-1475.195112

12. INTERPOL [Internet]. Disaster Victim Identification Guide [version 2018]. Available from: https://www.interpol.int/How-we-work/Forensics/Disaster-Victim-Identification-DVI

13. Vanrell, JP. Odontologia Legal e Antropologia Forense. 3ª ed. Editora Guanabra Koogan S.A. 2019.

14. Manigandan T, Sumathy C, Elumalai M, Sathasivasubramanian S, Kannan A. Forensic radiology in dentistry. J Pharm Bioallied Sci. 2015;7(1):S260-4. Doi: 10.4103/0975-7406.155944.

15. Emiliano GBG, Marinho FS, Oliveira RN. Potential contribution of periapical radiographic film image processing for forensic identification. RGO. 2016;64(4):484-9. doi: 10.1590/1981-86372016000300000193215.

16. Forrest AS. Collection and recording of radiological information for forensic purposes. Aust Dent J. 2012;57(1):24-32. doi: 10.1111/j.1834-7819.2011. 01658.x.

17. Hinchliffe J. Forensic odontology, part 1. Dental identification. Br Dent J. 2011;210(5):219-24. doi: 10.1038/sj.bdj.2011.146.

18. Nicopoulou-Karayianni K, Mitsea AG, Horner K. Dental Diagnostic Radiology in the Forensic Sciences: Two Case Presentations. J Forensic Odontostomatol. 2007;25(1):12-6.

19. Scoralick RA, Barbieri AA, Moraes ZM, Júnior LF, Júnior ED, Naressi CM. Identificação humana por meio do estudo de imagens radiográficas odontológicas: relato de caso. Rev Odontol UNESP. 2013;42(1):67-71.

20. American Board of Forensic Odontology (ABFO) [Internet]. Body Identification Information & Guidelines [revised 2017]. Available from: http://abfo.org/wp-content/uploads/2012/08/ABFO-Body-ID-Information-Guidelines-Feb-2017.pdf

21. Carvalho SPM, Silva RHA, Lopes-Junior C, Peres AS. A utilização de imagens na identificação humana em odontologia legal. Radiol Bras. 2009;42(2):125-30. doi: 10.1590/S0100-39842009000200012.

22. Johansen RJ, Bowers M. Positive Dental Identification Using Tooth Anatomy and Digital Superimposition. J Forensic Sci. 2013;58(2):534-6. doi: 10.1111/1556-4029.12040.

23. Gruber J, Kameyama MM. O papel da radiologia em odontologia legal. Pesqui Odontol Bras. 2001;15(3): 263-8.