ORAL MANIFESTATIONS AND CRANIOFACIAL CHARACTERISTICS OF HUTCHINSON-GILFORD PROGERIA SYNDROME: A CASE REPORT

Caroline Gomes **Bertoncelli**[1], Andréa Reis **Wendt**[1], Paulo Ricardo Gomes Fernandes dos **Santos**[1], Luciana Reichert da Silva **Assunção**[1], José Vitor Nogara Borges de **Menezes**[1], Fabian Calixto **Fraiz**[1*]

[1]Departament of Stomatology, Universidade Federal do Paraná, Curitiba, Paraná, Brazil.

Palavras-chave: Progéria. Síndrome de Hutchinson-Guilford. Manifestações Bucais. Criança. Relatos de Casos.

RESUMO

Introdução: A Progéria ou Síndrome de Hutchinson-Guilford (HGPS) é uma doença genética rara com um fenótipo característico de envelhecimento precoce em crianças pequenas, causado por uma mutação no gene LMNA e conseqüente acúmulo de progerina na célula. **Objetivo**: Descrever as manifestações orais da Síndrome de Hutchinson-Guilford. **Relato do Caso**: Este é um relato de caso de uma paciente de seis anos com Síndrome de Hutchinson-Guilford. O exame físico revelou atrofia da pele, lipodistrofia, rarefação dos cabelos, vasos sangüíneos proeminentes no couro cabeludo, desproporção craniofacial, cianose perioral e aumento das articulações dos joelhos. O exame intraoral revelou abertura bucal limitada, dentição mista com anatomia dentária normal e apinhamento ântero-inferior. A sequência e a cronologia de erupção estavam alteradas. O plano de tratamento incluiu profilaxia profissional, aplicação tópica de flúor, bem como orientação de higiene bucal e aconselhamento dietético. O acompanhamento do desenvolvimento da dentição e a intervenção odontológica precoce e oportuna colaboraram com a manutenção da saúde bucal da criança. **Conclusão**: Intervenções clínicas e educacionais precoces podem ajudar os pacientes com HGPS a manter um estado de saúde bucal adequado e melhorar sua qualidade de vida.

Keywords: Hutchinson–Gilford Progeria Syndrome. Progeria. Oral Manifestations. Child. Case Reports.

ABSTRACT

Introduction: Hutchinson-Guilford progeria syndrome (HGPS) is a rare genetic disease with a characteristic phenotype of premature aging in young children caused by a mutation in the LMNA gene and consequent accumulation of progerin in the cell. **Aim:** Describe oral manifestations of Hutchinson-Guilford progeria syndrome. **Case Report:** This is a case report of a six-year-old female patient with Hutchinson-Guilford Progeria syndrome. The physical examination revealed skin atrophy, lipodystrophy, hair rarefaction, prominent blood vessels of the scalp, craniofacial disproportion, perioral cyanosis and enlarged knee joints. The intraoral exam revealed limited mouth opening, mixed dentition with normal tooth anatomy and anteroinferior crowding. The eruption sequence and chronology were abnormal. The treatment plan included professional prophylaxis, the topical application of fluoride as well as both oral hygiene and dietary counselling. Monitoring the development of dentition and an early and timely dental intervention contributed to the maintenance of child's oral health**.** **Conclusion:** Early clinical and educational interventions can help patients with HGPS maintain adequate oral health status and improve their quality of life.

Submitted: May 18, 2020
Modification: July 26, 2021
Accepted: August 05, 2021

***Correspondence to:**
Fabian Calixto Fraiz
Departament of Stomatology
Universidade Federal do Paraná
Address: Avenida Lothário Meissner, 632.
Curitiba – PR, Brazil. Zip code: 80210-170
Telephone number: +55 (41) 3360-4021

INTRODUCTION

The first cases of Hutchinson-Guilford Progeria syndrome (HGPS; also known as progeria) were described by Jonathan Hutchinson in 1886 and independently by Hastings Guilford ten years later, giving rise to the name of the syndrome.[1,2] There are currently 30 progeroid syndromes described.[3] Classic HGPS (OMIM: #176670) is a rare sporadic autosomal dominant genetic disease[4-8] with a characteristic phenotype of premature aging in young children caused by a mutation in the LMNA gene and consequent accumulation of progerin in the cell.[6,7,9,10] The accumulation of this protein due to the repetition of cellular cycles causes toxicity, diminishing the life expectancy of the cell and causing premature tissue aging.[8]

According to a report from the Progeria Research Foundation published on March 31, 2019, 157 patients were diagnosed with this syndrome worldwide.[11] The mean life expectancy of affected individuals is 14 years of age and death generally occurs due to heart problems.[3,4]

Affected children are born with a stable health status and begin to present signs of the disease at about six to 12 months of age.[12,13]The most frequent manifestations are alopecia, hypotrichosis, lipodystrophy, exophthalmia, skin atrophy, thin nose, prominent blood vessels, stiff enlarged joints and short stature.[12,14,15] Mental development is not affected.[14] Few studies have offered a good description of the orofacial manifestations. The most common manifestations are: perioral cyanosis, craniofacial disproportion micrognathia, maxillary sinus atrophy, facial atrophy, delayed tooth eruption, tooth agenesis, dental malformations, dental crowding, narrow pulp chamber and frequent caries.[13,14]

Due to the low prevalence byof the syndrome, the Progeria Research Foundation has led an effort to unite all cases.[11] However, studies addressing oral problems in individuals with HGPS describe a considerable variety of characteristics, which hinders the identification of a pattern. Therefore, the aim of the present study was to contribute to the recognition of orofacial manifestations in this rare syndrome.

CASE REPORT

This case report describes oral manifestations in a six-year-old female patient with HGPS. The patient medical history revealed the parents were young at conception (mother: 21 years; father: 23 years) and the pregnancy occurred without complications. In the first year of the child's life, the occurrence of hair loss, prominent blood vessels on the scalp, low body weight and growth deficit led to the first suspicion of HGPS, which was confirmed when the child was two years of age through a genetic evaluation performed by the Progeria Research Foundation.[11] The patient was included in the foundation's study protocol of farnesyltransferase. At five years of age, the patient exhibited neuroatrophy of the knees, was sent for physical therapy and began taking imipramine (25 mg).

At six years and nine months of age, the patient began taking lonafarnib (SCH663366) (75 mg) provided by the foundation and exhibited skin atrophy, lipodystrophy, hair rarefaction, prominent blood vessels of the scalp, craniofacial disproportion, perioral cyanosis and enlarged knee joints. Electrocardiogram and echocardiogram results revealed normal findings. Concomitant to the use of lonafarnib, the patient made use of retinol with cholecalciferol and acetylsalicylic acid.

The patient began to visit the pediatric dental service of the *Universidade Federal do Paraná* in the city of Curitiba, Brazil, at the age of six years and nine months. At the time, the patient weighed 10.7 kg and was 98 centimeters in height (Figure 1A). Her diet was not considered cariogenic (little snacking between meals and low intake of sweets). She made regular use of a fluoridated toothpaste (1100 ppm F), but had difficulty using dental floss.

The intraoral exam revealed limited mouth opening, a mixed dentition with normal tooth anatomy and anteroinferior crowding (Figure 1B and 1C). The teeth were sound, but marginal gingivitis related to dental biofilm was found. The eruption sequence and chronology were not consistent with her age (six years); teeth 75 and 85 were still absent from the oral cavity. The panoramic radiograph revealed atrophy of the maxillary sinuses, small condyles, the formation of the germs of all permanent teeth, impacted teeth 75 and 85 and a lack of space for the proper eruption of teeth 31, 32 and 42 (Figure 1D).

The treatment plan included professional prophylaxis, the topical application of fluoride as well as both oral hygiene and dietary counselling. At the follow-up appointment when the child was eight years of age the mother reported that the use of dental floss was more frequent and an improvement in gingival health status was observed after oral hygiene counselling (Figure 2A and 2B). The panoramic radiograph showed an irregular root resorption pattern, although root development of the permanent successors was considered normal. The teeth 52, with delayed root resorption, and 54, with extensive resorption and considerable mobility, (Figure 2C) were extracted. The clinical examination revealed a developmental defect of enamel in teeth 11 (enamel hypoplasia) and 21 (demarcated opacity) (Figure 2A).

At nine years of age, the oral hygiene pattern had

worsened, with localized marginal gingivitis (Figure 3A). The other findings were the ectopic eruption of teeth 31 and 32 (Figure 3B), considerable mobility of teeth 63 and 64, the 24 erupting in vestibular direction (Figure 3C), and the presence of teeth 16 and 26 in the oral cavity. Non-cavitated caries were found on teeth 44 and 12 (Figure 3D). Panoramic radiography revealed an absence of space for proper eruption of all teeth (Figure 3E)

All teeth were normal in size, but with a lack of space for proper eruption. The cephalometric analysis revealed deficient jaw growth (SNA:78°; SNB:67°) with greater mandibular deficiency (ANB:11°). A tendency toward vertical growth (SNGoGN:54°) with a short face (AFAI:85 mm) was found (Table 1 and Figure 4).

***Table 1**: Cephalometric analysis of present case of Hutchinson-Guilford Progeria syndrome.*

SNA	78°
SNB	67°
ANB	11°
Co-A	110 mm
Co-Gn	118 mm
Mx-Md difference	8 mm
SNGoGN	54°
SNGN	65°
SNPo	35°
AFAI	85 mm
Naso-labial angle	112°

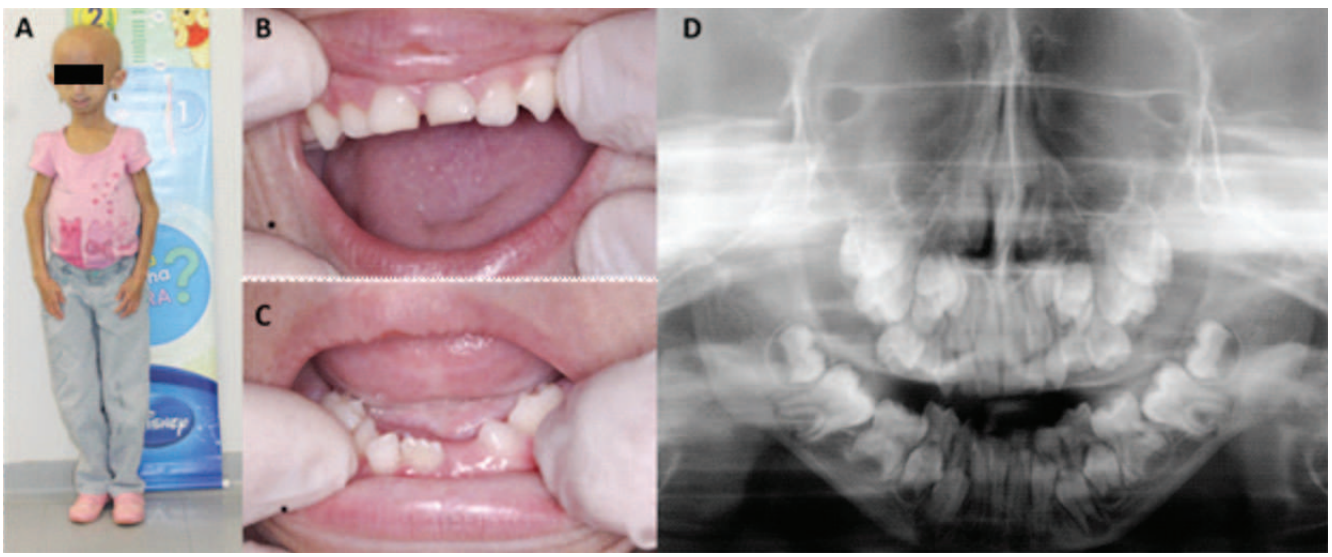

***Figure 1**: A) Aged clinical appearance and short stature at 6 years of age. B) Limited mouth opening. C) Dental crowding in anteroinferior region. D) Initial panoramic radiograph.*

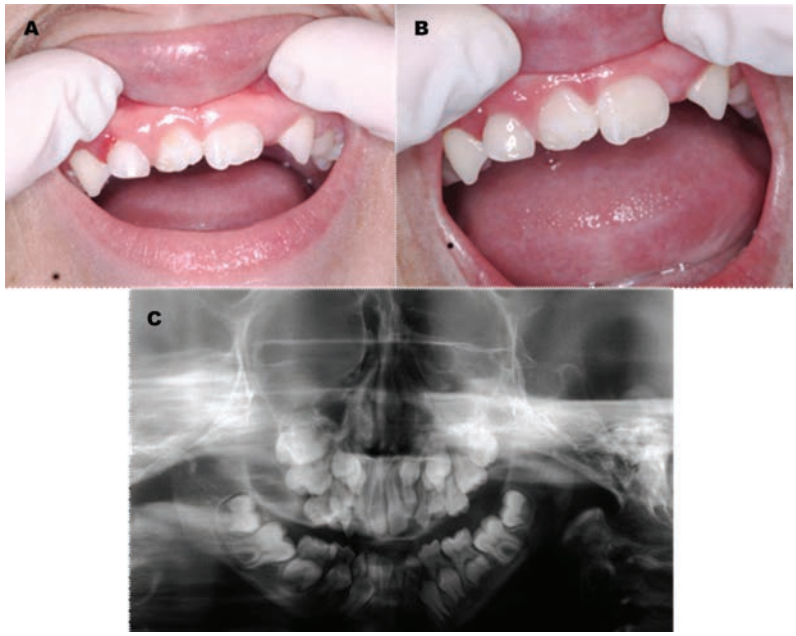

***Figure 2**: A) Intraoral examination at 8 years of age. B) Clinical evolution after oral hygiene counselling. C) New panoramic radiograph after 2 years, confirming presence of all germs of permanent successors.*

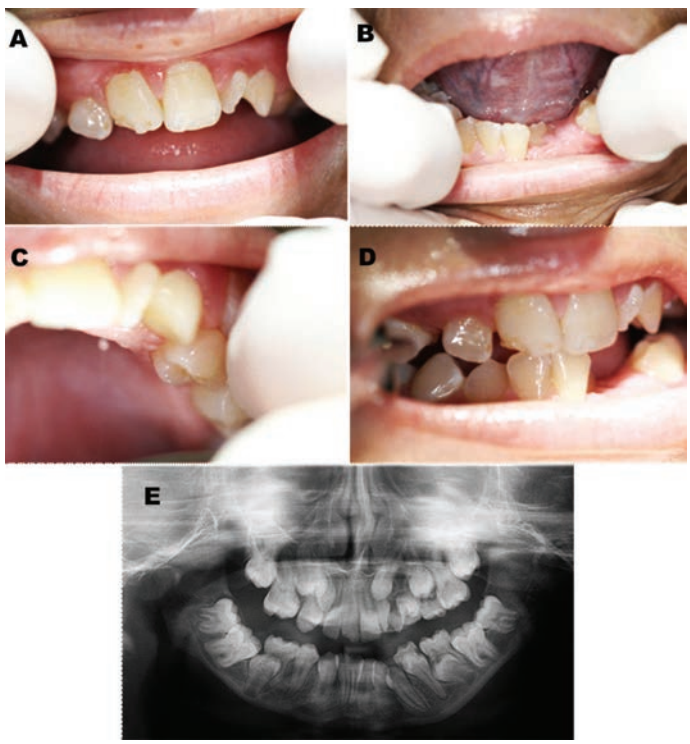

***Figure 3**. A) Marginal gingivitis on incisors. B) Absence of space for eruption of teeth 31 and 32. C) Tooth 24 erupting in vestibular direction. D) Active white spots on teeth 12 and 44. E) Absence of space for proper eruption of all teeth.*

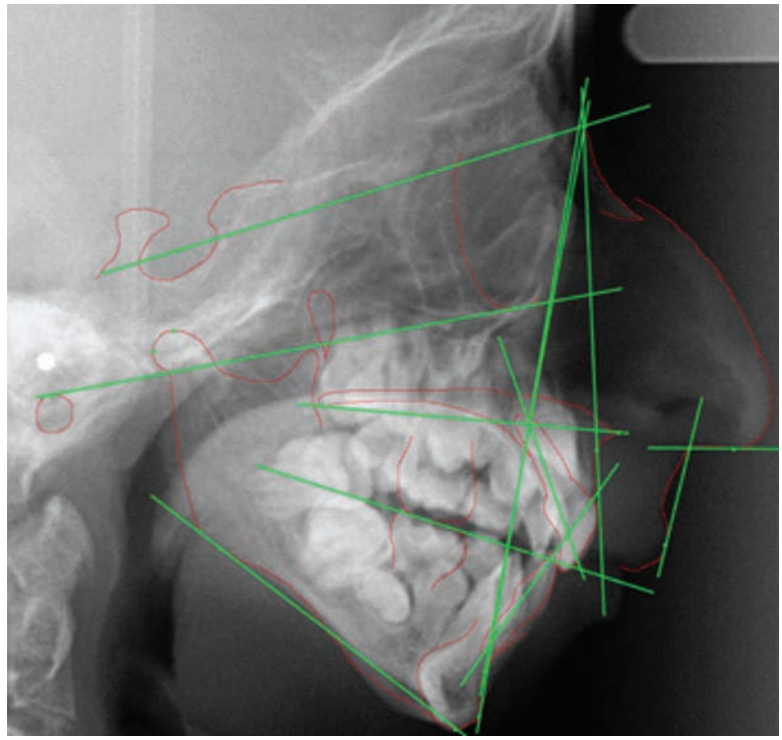

***Figure 4**: Cephalometric tracing indicating abnormally small vertical and sagittal dimensions.*

DISCUSSION

The considerable variation in oral findings associated with HGPS described in the literature is likely due to the low prevalence of this syndrome.[10,13,16] Moreover, the increase in life expectancy of affected individuals leads to new clinical situations determined by the lifecycle itself. The most relevant oral manifestations can be considered the result of incompatibility determined by deficient jaw growth and the normal morphological/anatomical development of the teeth.[17] This may lead to the need for extraction of some teeth.[18]

In the present case, the cephalometric analysis revealed micrognathia in both jaws, leading to a lack of space for the adequate eruption of the permanent teeth, which were normal in terms of both shape and size.

On the sagittal plane, the ANB angle was slightly increased (11°); the anterior height of the face (AFAI:85 mm) and the length of both the maxilla and mandible (Co-A:110 mm; Co-GN:118 mm) were abnormally small. As reported in other cases, a tendency toward vertical growth (SNGoGN: 54°) and an increase in the nasolabial angle (112°) due to deficient maxillary growth were also found.[19] Other authors also report discrepancies between normal tooth size in a face with atrophic growth.[17,20] In 2002, Batstone[18] reported a case in which the surgical removal of the permanent mandibular first molars and primary maxillary second molars was necessary due to recurring pericoronaritis.

According to Domingo,[20] hypodontia is another common condition in individuals with HGPS. The author reported a greater frequency of absent second premolars in comparison to the general population, which is in agreement with clinical findings of agenesis described in the literature.[10,17,19] Although hypodontia is a common condition in individuals with HGPS, especially the absence of second premolars,[10,17,19] this was not found in the present case.

Delays in the eruption chronology are also commonly reported in individuals with HGPS.[18,19] In the present case, the primary mandibular second molars had not yet erupted at six years of age, probably due to the mandibular growth deficiency.

The literature suggests that individuals with HGPS have a high incidence of dental caries and gingivitis.[13-17,19] In the present case, gingivitis was associated with a greater presence of biofilm and lower toothbrushing frequency at home. It was possible to maintain oral health throughout the entire follow-up period through simple preventive measures. This suggests that the increased prevalence of caries and gingivitis is more related to traditional etiological factors rather than oral characteristics inherent to the syndrome.

CONCLUSION

In conclusion, children with Hutchinson-Gilford Progeria Syndrome who receive preventive care and educational actions for the control of dental biofilm, access to fluoride and dietary control have the same chances of successfully avoiding the development of dental caries and gingivitis as children without this syndrome. However, dentists should be aware of the altered eruption pattern, dental crowding as well as the discrepancy between deficient orofacial development and normal tooth size and shape. These aspects may require an adequate, timely intervention to minimize the consequences of the lack of space in the oral cavity. Early clinical and educational interventions can help individuals with HGPS maintain an adequate oral health status, improving their quality of life.

REFERENCES

1. Hutchinson J. Congenital absence of hair and mammary glands with atrophic condition of the skin and its appendages. *Trans Med Chir Soc*. 1886;69:473-477.

2. Gilford H, Hutchinson J. On a Condition of Mixed Premature and Immature Development. *J R Soc Med*. 1896;MCT-80(1):17-45. Doi: 10.1177/095952879708000105.

3. Passarelli PC, Pasquantonio G, Manicone PF, et al. Orofacial signs and dental abnormalities in patients with Mulvihill-Smith syndrome. *Med (United States)*. 2018;97(18). doi: 10.1097/MD.0000000000010656.

4. Gordon LB, Shappell H, Massaro J, et al. Association of lonafarnib treatment vs no treatment with mortality rate in patients with Hutchinson-Gilford progeria syndrome. *JAMA - J Am Med Assoc*. 2018;319(16):1687-1695. doi: 10.1001/jama.2018.3264.

5. Kreienkamp R, Gonzalo S. Metabolic Dysfunction in Hutchinson-Gilford Progeria Syndrome. Cells. 2020 Feb 8;9(2):395. doi: 10.3390/cells9020395.

6. Ahmed MS, Ikram S, Bibi N, Mir A. Hutchinson–Gilford Progeria Syndrome: A Premature Aging Disease. Mol Neurobiol. 2018 May;55(5):4417-27. doi: 10.1007/s12035-017-0610-7.

7. QI YC, XIE XH. Hutchinson-Gilford Progeria Syndrome and its Relevance to Cardiovascular Diseases and Normal Aging. *Biomed Environ Sci*. 2013;26(5):382-389. doi: 10.3967/0895-3988.2013.05.007.

8. Hussain I, Patni N, Ueda M, et al. A novel generalized lipodystrophy-associated progeroid syndrome due to recurrent heterozygous LMNA p.T10I mutation. *J Clin Endocrinol Metab*. 2018;103(3):1005-1014. doi: 10.1210/jc.2017-02078.

9. Choi H, Kim TH, Jeong JK, Strandgren C, Eriksson M, Cho ES. Expression of the Hutchinson-Gilford Progeria Mutation Leads to Aberrant Dentin Formation. *Sci Rep*. 2018;8(1):15368. doi:.10.1038/s41598-018-33764-6.

10. Reichert C, Gölz L, Götz W, Wolf M, Deschner J, Jäger A, et al. Dental and craniofacial characteristics in a patient with Hutchinson–Gilford progeria syndrome. J Orofac Orthop. 2014 Jul;75(4):251-63. doi: 10.1007/s00056-014-0216-x.

11. Progeria Research Foudation [Internet]. Available from: https://www.progeriaresearch.org.

12. Hennekam RCM. Hutchinson-Gilford progeria syndrome: review of the phenotype *Am J Med Genet A*. 2006;140(23):2603-24. doi: 10.1002/ajmg.a.31346.

13. Nogueira AS, Nogueira CBP, Medeiros R, Beliláqua AC, Santos PSS, Rubira-Bullen IRF, et al. Hutchinson-Gilford Progeria Syndrome (HGPS): relevant aspects of a rare syndrome diagnosed in a Brazilian child. J Oral Diag. 2016;1(1):91-98. doi: 10.5935/2525-5711.20160009.

14. Alves DB, Silva JM, Menezes TO, Cavaleira RS, Tuji FM, Lopes MA, et al. Clinical and radiographic features of Hutchinson-Gilford progeria syndrome: A case report. World J Clin Cases. 2014 Mar 16;2(3):67-71. doi: 10.12998/wjcc.v2.i3.67.

15. Panigrahi RG, Panigrahi A, Vijayakumar P, Choudhury P, Bhuyan SK, Bhuyan R, et al. Hutchinson-Gilford Progeria Syndrome: A Rare Genetic Disorder. Case Rep Dent. 2013;2013:631378. doi: 10.1155/2013/631378.

16. Bassir SH, Chase I, Paster BJ, Gordon LB, Kleinman ME, Kieran MW, et al. Microbiome at sites of gingival recession in children with Hutchinson–Gilford progeria syndrome. J Periodontol. 2018 Jun;89(6):635-44. doi: 10.1002/JPER.17-0351.

17. Maloney WJ. Hutchinson-gilford progeria syndrome: Its presentation in F. Scott fitzgerald's short story' the curious case of benjamin button; And its oral manifestations. J Dent Res. 2009 Oct;88(10):873-876. doi: 10.1177/0022034509348765.

18. Batstone MD, Macleod AWG. Oral and maxillofacial surgical considerations for a case of Hutchinson-Gilford progeria. Int J Paediatr Dent. 2002 Nov;12(6):429-32. doi: 10.1046/j.1365-263x.2002.00401.x.

19. Hasty MF, Vann WF. Progeria in a pediatric dental patient: literature review and case report. Pediatr Dent. 1988 Dec;10(4):314-9.

20. Domingo DL, Trujillo MI, Council SE, et al. Hutchinson-Gilford progeria syndrome: Oral and craniofacial phenotypes. *Oral Dis*. 2009;15(3):187-195. doi: 10.1111/j.1601-0825.2009.01521.x.