TISSUE HEALING WITH POLYPROPYLENE MEMBRANE USED AS CONVENTIONAL GUIDED BONE REGENERATION AND EXPOSED TO THE ORAL CAVITY FOR POST-DENTAL EXTRACTION: A CASE REPORT

Thiago Henrique **Esch**[1], Davi da Silva **Barbirato**[2], Mariana Fampa **Fogacci**[2], Otto de Oliveira **Magro**[1], Maria Cynésia Medeiros de **Barros**[3]

[1] Professional Master Degree, Universidade Federal do Rio de Janeiro - UFRJ, Rio de Janeiro, RJ, Brazil
[2] Faculdades Integradas Aparício Carvalho – FIMCA, Porto Velho, RO, Brazil
[3]Department of Clinical Dentistry, Universidade Federal do Rio de Janeiro - UFRJ, Rio de Janeiro, RJ, Brazil

Palavras-chave: Cicatrização de Feridas. Regeneração Óssea Guiada. Bone-Heal®. Membrana de Polipropileno.

RESUMO

Introdução: A manutenção do rebordo alveolar após a extração dentária é muito importante para a instalação de um implante osseointegrável e para o resultado estético da reabilitação protética. A cirurgia regenerativa é frequentemente necessária para recuperar o volume perdido quando um dente é extraído. O coágulo sanguíneo que se forma é muito importante na cirurgia regenerativa porque permite que as células mesenquimais se diferenciem em células osteoprogenitoras, o que leva à regeneração óssea. **Objetivo:** Esse relato de caso compara o reparo ósseo após a extração dentária em um mesmo paciente através de três protocolos diferentes em preparação para posterior instalação de implante. **Relato de Caso:** Paciente de 50 anos, sexo feminino, necessitou de extração dentária dos elementos 14, 24 e 26 com posterior reabilitação. A primeira técnica utilizada foi a remoção dentária com sutura somente, a segunda utilizou a membrana de polipropileno BoneHeal de forma exposta após a extração, e a terceira técnica utilizou a membrana BoneHeal de subperiostealmente. Após alguns dias, a membrana subperiosteal expôs e não foi possível continuar em posição. No entanto, as duas regiões que a membrana foi utilizada, obtiveram um maior aumento no tecido mole. **Conclusão:** Em nosso estudo de caso, a membrana de polipropileno pareceu reparar tecido.

Keywords: Wound Healing. Guided Bone Regeneration. Bone-Heal®. Polypropylene Membrane.

ABSTRACT

Introduction: The maintenance of the alveolar ridge after tooth loss is very important for the installation of an osseointegrated dental implant and for the aesthetic result of the rehabilitation prosthesis. Regenerative surgery is often needed to recover the volume lost when a tooth is extracted. The blood clot that forms is very important in regenerative surgery because it allows the mesenchymal cells to differentiate into osteoprogenitor cells, which leads to bone regeneration. **Objective:** This case report compares the bone repair after dental extraction in the same patient via three different protocols and the healing in preparation for posterior implant placement. **Case Report:** A patient 50 year-old female required dental extraction of elements 15, 24 and 26 and prosthetic rehabilitation. The first technique used was tooth extraction and suture only, the second technique used exposedBoneHeal® polypropylene membrane after extraction, and the third technique usedBoneHeal membrane subperiosteally. After a few days, the subperiosteal membrane became exposed and it was not possible to keep it in position. However, the two regions in which the membrane was used obtained a greater increase in soft tissue. **Conclusion:** In our study case, the polypropylene membrane seemed to repair tissue.

Submitted: March 22, 2018
Modification: July 4, 2018
Accepted: July 5, 2018

***Correspondence to :**
Address: Praça Antônio Calado, 215. Apt: 807. Barra da Tijuca. Rio de Janeiro Brasil. CEP: 22793-084
Telephone number: +55(21) 3502-5490 /+55 (21) 98558-0319
E-mail: thiago.h.esch@hotmail.com ou cynesiaster@gmail.com

INTRODUCTION

After the removal of a dental element, the alveolar ridge atrophies and loses volume due to intense remodeling and loss of function of the alveolar bone.[1,2] Because of the scientific advances in the field of bone regeneration and in surgical techniques, bone regeneration surgeries in dentistry have been promising and successful.[3,5] Guided Bone Regeneration (GBR) surgery aims to provide bone volume for subsequent rehabilitation with osseointegrated dental implants, as well as to correct bone defects.

Fibroblasts and epithelial cells proliferate faster after tooth extraction, before the dental socket forms bone tissue. GBR aims to isolate and maintain the blood clot that forms in the socket under a membrane, thus avoiding unwanted cells from competing with bone cells in the site to be regenerated subperiosteally, preventing contamination from the unwanted cells, and oral exposure.[6,7]

The spaces that remain after membrane placement in regeneration procedures are filled by a hematoma with characteristics ideal for promoting bone regeneration. Polymorphonuclear cells, the first cells to reach the site, differentiate into macrophages, undifferentiated mesenchymal cells, and fibroblasts. Periosteal, endosteal, and medullary bone molecules form granulation tissue to the postoperative day.[8,9] Mesenchymal cells differentiate into osteoblasts that produce collagen fibers and osteomucin, which eventually give rise to the osteoid. This granulation tissue is gradually replaced by newly formed bone. After 2 weeks, the cellular activity of osteoblasts and osteoclasts replaces the necrotic bone by generating new bone.[10] This cellular activity produces alkaline phosphatase and provides calcium ions in the medium, which are used in the calcification process that forms the new tissue, giving rise to fibrillar bone between the 15th and 20th day of repair.[11] After formation of the fibrillar bone, the second phase of bone resorption and deposition occurs at the site with the formation of a new lamellar osteoid. The formation of the lamellar bone, with well-defined haversian and Volkman's canals, is complete within 120 days. Next, tissue remodeling and functional adaptation of the newly formed bone, which is equivalent to autogenous bone morphologically and histologically, is complete after 180 days.[11]

The region to be regenerated must remain isolated from soft tissue for a sufficient time, allowing the turnover of bone cells to occur. Nonresorbable membranes are considered the gold standard for GBR because they allow this isolation and maintain the stable framework necessary for the bone graft and blood clot[4]. In Brazil, a new polypropylene membrane has been used that improves bone regeneration after a dental extraction by isolating the blood clot formed in the site, not allowing soft tissue cells to migrate into the alveolus to be regenerated, and avoiding competition among cells. This polypropylene barrier is impermeable and nonresorbable and should be placed, intentionally exposed, in the buccal environment for 714 days, according to the manufacturer, using a flapless technique.[1214] This case report compares bone repair after exodontia in the same patient, in which no membrane and BoneHeal® were used at different sites. Three different surgical protocols were used for the bone repair: Protocol 1 was dental extraction and suture only. Protocol 2 was dental extraction and placement of BoneHeal membrane subperiosteally with primary closure of the flap. Protocol 3 was dental extraction and placement of BoneHeal membrane exposed in the oral cavity.

CASE REPORT

Our patient was a 50-year-old female with no systemic disease. Elements 15, 24, and 26 had extensive carious lesions, requiring dental extraction and prosthetic rehabilitation (Figures 1 and 2).



Figure 1: *Preoperative photograph showing teeth 15, 24, and 26 for dental extraction for extensive carious lesions.*

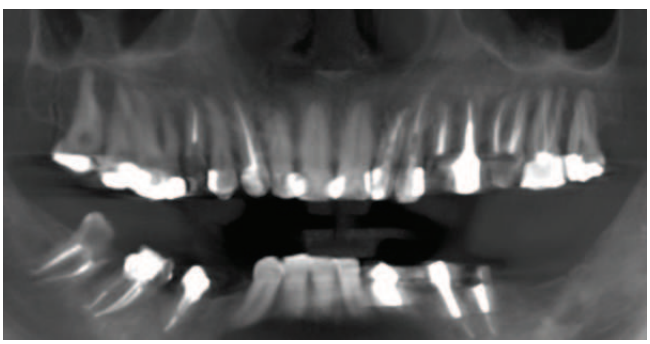

Figure 2: *Initial X-ray showing teeth 15, 24, and 26 in need of extraction.*

Element 15 was selected for Protocol 2: dental extraction and placement of a subperiosteal BoneHeal membrane (INP, São Paulo, Brazil) with greater viability of the flap division and passive closure of the surgical site. The membrane was removed after 4 months of healing because osteogenesis of the dental socket was complete between the third and fourth month post-exodontia. Bone maturation lasted approximately 6 months.[15] Element 24 was selected for Protocol 3: dental extraction with placement of exposed membrane, which was removed after 14 days along with the sutures. Element 26 was selected for Protocol 1: no membrane was used because it had a larger alveolus and interradicular septum than 24, which favored healing without the use of a membrane (Table 1). After the 4-month healing period, the three sites received osseointegrated dental implants.

***Table 1**: Surgery protocols*

Protocol 1	Dental extraction + suture	Element 26
Protocol 2	Dental extraction + subperiosteal BoneHeal	Element 15
Protocol 3	Dental extraction + exposed BoneHeal	Element 24

The surgical procedure started with two buccal relaxing incisions and an intrasulcular incision for element 15, with detachment of a posterior flap to execute the atraumatic dental extraction. After the extraction, the buccal division of the flap began with displacement of the flap to allow passive stabilization next to the palatal mucosa. After the flap was displaced, the membrane was inserted into the adjacent alveolus, between the cortical bone and the periosteum, allowing for the isolation of the clot. After insertion of the membrane with the help of the passive positioning of the flap, a horizontal mattress suture was placed to stabilize the membrane, followed by simple sutures to join the flap next to the palatal mucosa with sutures in the buccal relaxing incisions to close the surgical wound. Dental elements 24 and 26 were removed without major complications. After extraction, a buccal and palatal flap was detached in the region of 24 to allow insertion of the biomembrane between the cortical bone and the periosteum, followed by simple sutures for stabilization. An "X" suture was placed in element 26 for clot retention in the alveolus (Figure 3).

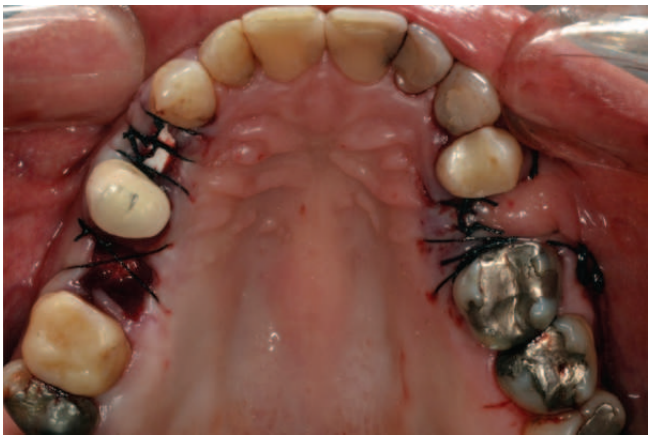

Figure 3: Immediate postoperative photo showing submerged membrane in element 15, exposed membrane in element 24, and only an "X" suture in element 26.

DISCUSSION

Because different surgical protocols were used, the healing stages presented were also different. By postoperative day 4, the subperiosteal membrane used in element 15 (Protocol 2) had become exposed. We chose to keep it in place because its border was not exposed, allowing it to continue as a barrier. At postoperative day 7, the patient returned for revision without the membrane in place. She reported that it fell out the day after the previous consultation when she used dental floss. Therefore, the membrane was in position for only 5 days. We chose not to remove the sutures to allow element 15 to complete 14 days of healing as previously planned. All sutures were removed after postoperative day 14. After removal of the sutures, the Protocol 3 membrane was removed with forceps and without the need for anesthesia. At 21 days of healing, the tissue volume of the Protocol 3 area looked better than that of the Protocol 1 area and was more reddish. The tissue color at the Protocol 1 site was normochromic, indicative of epithelial proliferation at the site. At 69 days, the gingival tissue of Protocol 1 was almost homogeneous. The vestibular and palatine borders in the Protocol 3 area were rosy and not very prominent, whereas in the Protocol 2 area, the vestibular flap was pink and practically in its normal position. During the healing process, it was observed that there was a greater increase in soft tissue in the areas where the membrane was used than in the area where it was not used. Figures 4 and 5 show this increase in soft tissue at elements 15 and 24 compared to that at 26 after 4 months of bone repair. At this time, the bone was evaluated (Figure 6) and the implants were installed at the three sites (STRONG SW implants, S.I.N. Implant System, São Paulo, Brazil, HE 4.1 x 3.75 x 10 mm) and all regions were sutured.



***Figure 4**: After 4 months of healing, the greatest increase in soft tissue occurred at 15 and 24 compared to that at 26.*

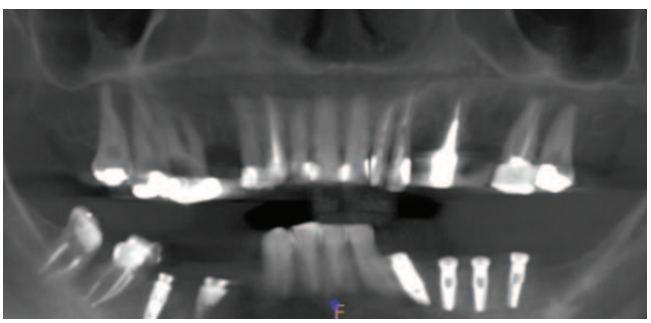

***Figure 5**: X-ray after 4 months of healing, before the placement of implants.*

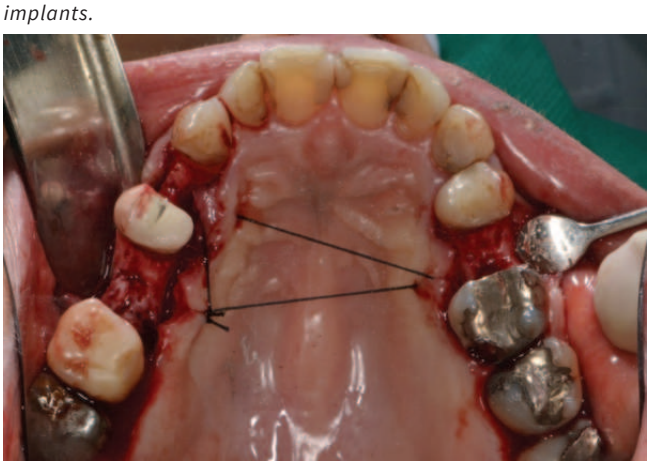

***Figure 6**: Bone overview at the three surgical sites after 4 months of healing.*

The sizes of the dental sockets in the premolar and molar regions were different. The molar area to be repaired was larger than that of the premolar area. However, in this case study, only the increase in soft tissue and the healing in the regions were evaluated for posterior implant installation.

In this case study, the subperiosteal polypropylene membrane provided better soft tissue repair. The retention and isolation of the clot, promoted by the membrane, prevented epithelial cells from migrating into the alveolus, allowing the mesenchymal cells to populate the formed granulation tissue more effectively. Because of the characteristic rigidity of polypropylene and its memory, its conventional use for performing GBR as described in the literature (i.e., submerged) was ineffective in this case because it became exposed in the first days of healing. The exposure of submerged polypropylene membrane used in GBR suggests that the biocompatibility of this barrier may not be satisfactory. Despite the occurrence of this exposure, bone and tissue repair were not impaired during the time the membrane was a barrier.

The technique proposed by the manufacturer of BoneHeal, in which the membrane should remain exposed in the oral cavity, is very simple to perform. It has a low risk of morbidity and does not require a second surgery for removal of the membrane. However, the benefits and the biological events involved in bone repair with this technique are not clear. Therefore, more qualitative and quantitative evaluation studies of the new bone formed using this technique need to be performed. Prospective longitudinal studies for assessing the behavior of hard and soft tissues would be highly relevant.

CONCLUSION

The subperiosteal polypropylene membrane used in our patient seems to have promoted tissue repair. Tissue repair still occurred when the submerged polypropylene membrane applied in GBR became exposed. Histological and tomographic examinations should be performed in future studies to identify the dynamics of bone reparation after these procedures.

REFERENCES

1. Botticelli, D., Berglundh, T., Lindhe, J. Hard-tissue alterations following immediate implant placement in extraction sites. J. Clin. Periodontol. 31:820–828, 2004.

2. Araújo, M.G., Lindhe, J. Dimensional ridge alterations following tooth extraction. An experimental study in the dog. J. Clin. Periodontol. 32:212–218, 2005.

3. Hämmerle, C.H., Jung, R.E., Feloutzis, A. A systematic review of the survival of implants in bone sites augmented with barrier membranes (guided bone regeneration) in partially edentulous patients. J. Clin. Periodontol. 29 Suppl. 3:226231; discussion 232233, 2002.

4. Jung, R.E., Sapata, V.M., Hämmerle, C.H.F., Wu, H., Hu, X.L., Lin, Y. Combined use of xenogeneic bone substitute material covered with a native bilayer collagen membrane for alveolar ridge preservation: A randomized controlled clinical trial. Clin. Oral Implants Res. 29(5):522–529, 2018.

5. Retzepi, M., Donos, N. Guided Bone Regeneration: biological

principle and therapeutic applications. Clin. Oral Implants Res. 21(6):567576, 2010.

6. Hardwick, R., Scantlebury, T.V., Sanchez, R., Whitley, N., Ambruster, J. Membrane design criteria for guided bone regeneration of the alveolar ridge. In: Buser, D., Dahlin, C., Schenk, R.K., eds. Guided bone regeneration in implant dentistry. Chicago: Quintessence, pp. 101–136, 1994.

7. Dahlin, C., Linde, A., Gottolow, J., Nyman, S. Healing of bone defects by guided tissue regeneration. Plast. Reconstr. Surg. 81:672676, 1988.

8. Harrison, J.W., Jurosky, K.A. Wound healing in the tissues of the periodontium following periradicular surgery. 2. The dissectional wound. J. Endod. 17(11):544552, 1991.

9. Harrison, J.W., Jurosky, K.A. Wound healing in the tissues of the periodontium following periradicular surgery. III. The osseous excisional wound. J Endod. 18(2):7681, 1992.

10. Schenk, R.K., Buser, D., Hardwick, W.R., Dahlin, C. Healing pattern of bone regeneration in membrane-protected defects: a histologic study in the canine mandible. Int. J. Oral Maxillofac. Implants 9:13–29, 1994.

11. Sepe, W.W., Bowers, G.M., Lawrence, J.J., Friedlaender, G.E., Koch, R.W. Clinical evaluation of freeze-dried bone allografts in periodontal osseous defects-part II. J. Periodontol. 49(1):914, 1978.

12.Petrilli, G., Filho, L.R.P., Salomão, M., Siqueira, J.T.T. Regeneração óssea guiada com barreira de Polipropileno e instalação de Implante Flap Less. Rev. Catarinense de Implantodontia 18:2023, 2018.

13.Salomão, M., Siqueira, J.T.T., Alvarez, F.K. Regeneração óssea guiada em defeitos extensos pós exodontias utilizando membrana exposta ao meio bucal. Rev. Implant News 7(6):753759, 2010.

14.Salomão, M., Siqueira, J.T.T. Uso de barreira exposta ao meio bucal para regeneração óssea guiada após a exodontia. Rev. Assoc. Paul. Cir. Dent. 64(3):1848, 2010.

15. Felice, P., Zucchelli, G., Cannizzaro, G., Barausse, C., Diazzi, M., Trullenque-Eriksson, A., Esposito, M. Immediate, immediate-delayed (6 weeks) and delayed (4 months) post-extractive single implants: 4-month post-loading data from randomized controlled trial. Eur. J. Oral Implantol. 9(3):233247, 2016.