THREE YEAR FOLLOW-UP AND MANAGEMENT OF A SEVERELY DISLOCATED TOOTH AFTER PRIMARY TRAUMA

Adílis Kalina **Alexandria** [1,2], João Alfredo **Farinhas** [2], Daniela Novaes **Soares** [1], Thais Pinto **Alves** [2], Laura Salignac Guimarães **Primo** [2]

[1] Universidade Salgado de Oliveira - UNIVERSO, Niterói, RJ, Brazil
[2] Department of Pediatric Dentistry and Orthodontics - Universidade Federal do Rio de Janeiro - UFRJ, Rio de Janeiro, RJ, Brazil

Palavras-chave: Traumatismos Dentários. Dente Decíduo. Dente Permanente.

RESUMO

Objetivo: Este relato de caso descreve o manejo e um acompanhamento de 3 anos de um dente anterior incluso e ectópico. **Relato de Caso:** O paciente, uma menina (9 anos de idade) foi encaminhada devido à falta de um incisivo central esquerdo superior permanente. Quando ela tinha 2 anos de idade, sofreu uma intrusão completa de seu incisivo central esquerdo superior decíduo, e o dente re-erupcionou após 4 semanas. O exame radiográfico revelou a impactação e deslocamento grave do incisivo central esquerdo superior permanente. O dente impactado foi cirurgicamente exposto e tracionado ortodonticamente para alinhamento ao longo de um período de 12 meses. **Resultados:** Após este período, o incisivo central apresentou saúde periapical e periodontal satisfatórias, oclusão adequada e bom resultado estético. Após três anos de acompanhamento, arredondamento apical e ausência de dano extensivo às estruturas dentárias ou teciduais foi observado. **Conclusão:** O manejo ortodôntico foi realizado com sucesso, com excelentes resultados funcionais e estéticos. O tratamento de um incisivo impactado é um desafio que deve ser cuidadosamente planejado. Um acompanhamento clínico e radiográfico por um grupo multiprofissional é de extrema importância.

Keywords: Tooth Injury. Primary Tooth. Permanent Tooth.

ABSTRACT

Objective: This case report describes the management and a 3-year follow-up of an unerupted and ectopic positioned anterior tooth. **Case Report:** The patient, a girl (9 years old) was referred due to the lack of a permanent maxillary left central incisor. When she was 2 years old suffered a complete intrusion of her primary maxillary left central incisor, and the tooth re-erupted after 4 weeks. Radiographic examination revealed the impaction and severe dislocation of the permanent maxillary left central incisor. The impacted tooth was surgically exposed and placed in orthodontic traction for alignment over a period of 12 months. **Results:** After this period the central incisor presented satisfactory periapical and periodontal health, adequate occlusion and a good esthetic outcome. After three years of follow-up, apically rounded and no extensive damage to tooth or tissues structures were observed **Conclusion:** The orthodontic management had been successfully performed with excellent functional and esthetic results. Treatment of an impacted incisor is a challenge, which should be carefully planned. A clinical and radiographic follow-up by a multi-professional group is of outmost importance.

Submitted: March 22, 2018
Modification: June 7, 2018
Accepted: June 8, 2018

***Correspondence to:**
Adílis Kalina Alexandria
Address: Faculdade de Odontologia, Universidade Federal do Rio de Janeiro, Cidade Universitária – CCS, CEP: 21941-971, Rio de Janeiro – RJ, Brazil.
Telephone number: 00 55 21 39382101,
E-mail: adilis.alexandria@gmail.com

INTRODUCTION

Traumatic injuries occur frequently in primary dentition with a prevalence of between 30-35.5%.[1] The prevalence of intrusive luxation is approximately 29%.[2-4] It is more common in primary dentition, mainly with 1-3 year-old children,[5] when the crowns of the permanent successors are being formed and the alveolar bone is more resilient.[6] Various problems to permanent teeth have been described as a consequence of intrusive luxation of primary teeth such discoloration of enamel, enamel hypoplasia, crown and root dilacerations, and eruption disturbances.[1,3] The magnitude of damage to developing germ is associated to the stage of germ development, intensity, severity, and direction of the impact. [6]

The determination of the relationship of an intruded primary tooth with the follicle of the succedaneous tooth influences in treatment, [1,7,8] If the tooth's apex is displaced labially, waits the spontaneous reeruption, however the extraction is indicated when the apex is displaced toward the permanent tooth germ. [7]

The lack of a maxillary central incisor causes important psychological, functional and aesthetic problems that could have an impact on the child and/or their parents. [9] This paper reports the management and a 3 year follow-up of severe dislocated unerupted anterior teeth as a consequence of intrusive luxation in the primary dentition.

CASE REPORT

A 9 year-old girl was referred to the Pediatric Dental Clinic at the Federal University of Rio de Janeiro, Brazil, for dental treatment due to the lack of the maxillary left central incisor. The mother reported that when the patient was 2 years old she suffered a complete intrusion of her primary maxillary left central incisor. The tooth re-erupted after 4 weeks and her mother did not report any sequelae on the deciduous tooth traumatized.

A clinical evaluation revealed that the patient was in mixed dentition, with lack of the permanent maxillary left central incisor in the arch. This tooth was in a horizontal position at the level of the labial sulcus, but intraosseous (Fig 1a). Lateral and orthopantographic radiographs revealed impaction of the permanent maxillary left central incisor, which was in an ectopic position (Fig 1b and 1c).

The treatment plan was: 1) Recovery of space in the region of the upper left central incisor: fixed brackets

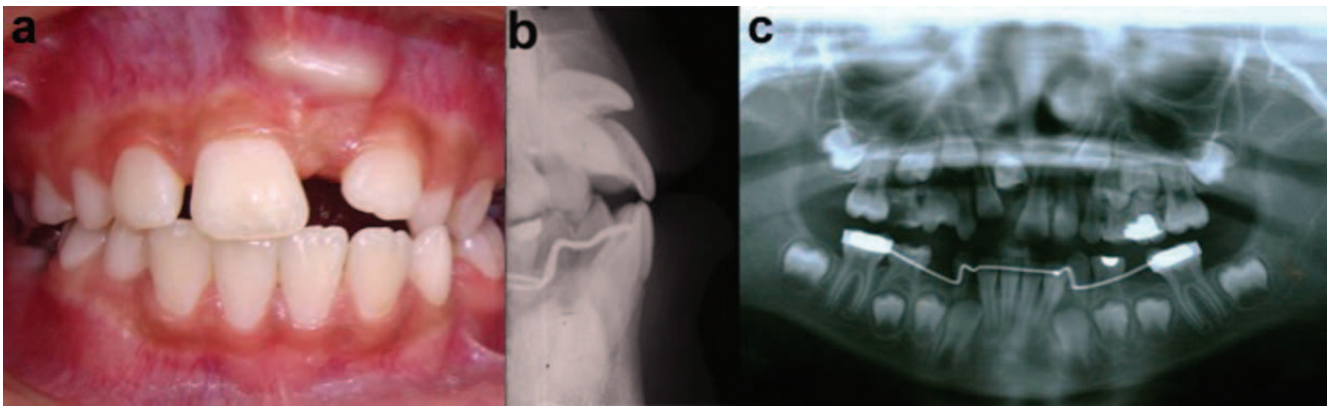

Figure 1: *a) Initial aspect of tooth in a horizontal position at the level of the labial sulcus and lack of space. b) Lateral radiograph: impaction of permanent maxillary left central incisor. c) Orthopantographic radiograph: impaction of permanent maxillary left central incisor (ectopic position).*

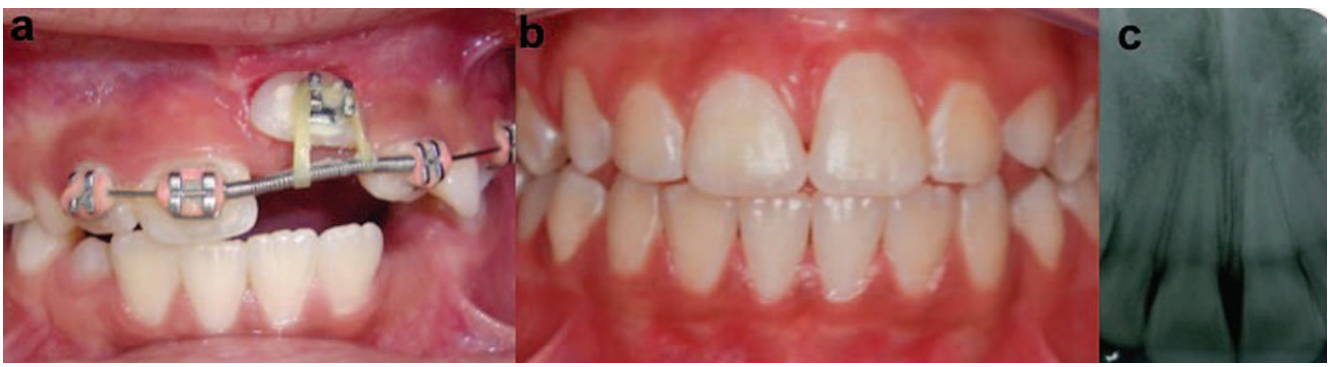

Figure 2: *a) Recover of the space in the region of the upper left central incisor (aspect after 6 months of treatment) and exposure and traction of the tooth. b) Final clinical and c) Radiographic aspect of the case, after 3 years of follow-up.*

(Edgewise Standard; Morelli, Sorocaba, SP, Brazil) was bonded with light-cure orthodontic composite (Transbond TM XT; 3M Unitek/ESPE, Monrovia, CA, USA) on the upper arch, an open spring was placed between the maxillary right central incisor and the maxillary left lateral incisor, the spring was changed weekly to increase the strength of the tooth spacing (Fig 2a). This stage lasted 6 months. 2). After recovering the space in the upper right central incisor region, a surgical exposure of the maxillary left central incisor was performed, and an orthodontic bracket was bonded (Edgewise Standard; Morelli, Sorocaba, SP, Brazil) with light-cure orthodontic composite (Transbond TM XT; 3M Unitek/ESPE, Monrovia, CA, USA). Chlorhexidine mouth rinse was recommended for a 14-day-period as also instructions on oral hygiene. 3) After surgical exposure, the traction and alignment of the tooth was initiated. The traction was made with sequential changes of elastomeric chains (Fig 2a); the alignment and leveling were performed with sequential stainless steel wires. The traction and correct alignment was completed in 12 months.

The child returned for follow-up visits every 6 months. Satisfactory periapical and periodontal health, after three years is shown in Fig 2b, associated with the absence of radicular shortening (Fig 2c) and adequate occlusion demonstrated the success of the case. There was a slight change in the gingival esthetics, and periodontal surgery (gingivoplasty of permanent maxillary left central incisor) was suggested, however the family was satisfied with the final appearance and preferred not to perform it.

DISCUSSION

The problems in permanent teeth are most frequently observed after intrusive injuries of primary teeth.[2-4,6,10] The close anatomical relationship between the primary incisor roots and the permanent successor tooth germs elucidates the effects of intrusive injuries on permanent teeth.[1,4,6] Because of potential sequelae, is important treat the primary teeth traumatized as to avoid any damage in permanent successors.[7,10] The IADT[7] guideline indicate spontaneous repositioning in case of tooth displaced toward or through the labial bone plate and extraction in case of displaced into the developing tooth germ. As the patient reported not receiving any type of treatment after dental trauma, the positioning of the deciduous tooth at the time of the intrusion is not known, the absence of appropriate evaluation and treatment may have contributed to the sequelae of impactation observed in the permanent tooth.

The permanent incisor structure and shape were not changed, but there was a shift in the direction of tooth eruption causing the dental impaction and severe ectopic position of the tooth. Thus, the sequel was limited to an alteration in the eruption pathway.

One of the consequences after traumatic injuries in primary dentition is dilacerations of the crown or root as a result of a developmental anomaly in which the axial inclination of the tooth between the crown and root has been modified.[9] In this case report, the initial aspect of the tooth suggested the appearance of a crown dilaceration, but the evolution of the case showed that it was a case of impaction and the ectopic position of the tooth. The conduct of an impacted ectopic anterior tooth is difficult due its position intraosseous and procedure involves surgical exposition with orthodontic treatment. Other authors [11,12] related the same technique used in this case report.

The impaction of the maxillary incisor is habitually diagnosed at the beginning of the mixed dentition phase, due to the lack of eruption of a tooth. The dental trauma and absence of teeth affects the quality of life of children and their parents, in terms of aesthetic, psychological and functional.[8] Depending on the degree of dental impaction and the position of the tooth, the prognosis may be difficult.[10] The position of ectopic teeth (labial or palatal position) may indicate the need for surgical exposure and orthodontic treatment.[13] A palatal positioned tooth usually arises without intervention.[10,13] It is believed that this impaired eruption is due to the cortical thickness of the palatine bone; as well as to the dense, thick and resistant palatine mucosa; crown and root inclination; and absence of space in the dental arch.[13]

Tooth movements in the arch commonly cause discrepancies of tooth gingival levels.[13] In this case report, it was necessary to regain space before starting the traction of the impacted tooth. Fixed orthodontic therapy was necessary to achieve proper leveling, alignment and angulation. Although, after fixed orthodontic treatment the gingival level of the maxillary left central incisor was different from the level of the neighboring teeth, the child and her family were satisfied with the final appearance and preferred not to perform a periodontal surgery. However, there was an adequate occlusion and an excellent esthetic outcome after the orthodontic treatment.

The patient is currently under revision, and after three years of follow-up, the orthodontic management was successfully performed with the correct alignment of the severely dislocated permanent central incisor. Excellent functional and esthetic results were obtained and the patient and her parents were satisfied with the results. The family preferred not submitted the patient to new procedures, such as gingivoplasty, because they were satisfied with the clinical

outcome. The patient had a low smile line, such that the small gingival defect was not aesthetically perceptible when smiling, which was probably the main factor that contributed to the decision.

CONCLUSION

Traumatic injuries in primary teeth must be treated not only for esthetical and functional reasons, but also because they might have affected the successors' developing germs. Regular follow-up, early treatment and correct clinical interventions after dental trauma may minimize or even prevent damage to the successor tooth. Parents need to be made aware of how important early treatment is.

REFERENCES

1. Andreasen JO. Luxation of permanent teeth due to trauma. A clinical and radiographic follow-up study of 189 injured teeth. Scandinavian journal of dental research 1970;78(3):273-86
2. Assuncao LR, Ferelle A, Iwakura ML, Nascimento LS, Cunha RF. Luxation injuries in primary teeth: a retrospective study in children assisted at an emergency service. Brazilian oral research 2010;25(2):150-6
3. Carvalho V, Jacomo DR, Campos V. Frequency of intrusive luxation in deciduous teeth and its effects. Dental Traumatology 2010;26(4):304-7
4. do Espírito Santo Jácomo DR, Campos V. Prevalence of sequelae in the permanent anterior teeth after trauma in their predecessors a longitudinal study of 8 years. Dental Traumatology 2009;25(3):300-4
5. Altay N, Gungor HC. A retrospective study of dento-alveolar injuries of children in Ankara, Turkey. Dental Traumatology 2001;17(5):201-4
6. Von Arx T. Developmental disturbances of permanent teeth following trauma to the primary dentition. Australian Dental Journal 1993;38(1):1-10
7. Malgren B, Andreasen JO, Flores ME, Robertson A, DiAngelis AJ, Andersson L, Cavalleri G, Coheca N, Day P, Hicks ML, Malmgren O, Moule AJ, Onetto J, Tsukiboshi M. International Association of Dental Traumatology guidelines for the management of traumatic dental injuries: 3. Injuries in the primary dentition. Dental Traumatology 2012;28: 174-182
8. Lenzi MM, Alexandria AK, Ferreira DMTP, Maia LC. Does trauma in the primary dentition cause sequelae in permanent successors? A systematic review. Dental Traumatology 2015;31:79-88
9. Azeredo LAA, Ronir RL, Leão ATT, Maia LC. Initial assessment of responsiveness of the P-CPQ (Brazilian Version) to describe the changes in quality of life after treatment for traumatic dental injury. Dental Traumatology 2012;28(4):256-62
10. Altun C, Cehreli ZC, Guven G, Acikel C. Traumatic intrusion of primary teeth and its effects on the permanent successors: a clinical follow-up study. Oral surgery, oral medicine, oral pathology, oral radiology, and endodontics 2009;107(4):493-8
11. Lin YTJ, Treatment of an impacted dilacerated maxillary central incisor. American Journal of Orthodontics and Dentofacial Orthopedics 1999;111(4):406-409.
12. Pavlidis D, Daratsianos N, Jager A. Treatment of an impacted dilacerated maxillary central incisor. American Journal of Orthodontics and Dentofacial Orthopedics 2011; 139(3):378-387
13. Bishara SE. Impacted maxitlary canines: A review. American Journal of Orthodontics and Dentofacial Orthopedics 1995;101(2):159-171.