PHOTOBIOMODULATION THERAPY FOR ORAL MUCOSITIS MANAGEMENT IN HEAD AND NECK CANCER PATIENTS UNDERGOING RADIOTHERAPY: CASE REPORTS

Thais Benedetti Haddad **Cappellanes**[1], Silvio **Boraks**[2], Beatriz **Tholt**[1], Juliano Abreu **Pacheco**[3], Maíra **Prado**[1*], Celso Silva **Queiroz**[1]

[1]School of Dentistry, Veiga de Almeida University, Rio de Janeiro, RJ, Brazil.
[2]Associação Paulista de cirurgiões-dentistas, São Paulo, SP, Brazil.
[3]Hospital do Câncer de Ribeirão Preto, Ribeirão Preto, SP, Brazil.

Palavras-chave: Câncer de Cabeça e Pescoço. Terapia de Luz de Baixa Intensidade. Mucosite. Fotobiomodulação. Relato de casos.

RESUMO

Introdução: A terapia com fotobiomodulação (FBM) tem sido recomendada para a prevenção da mucosite oral (MO). **Objetivo**: avaliar o uso de FBM para prevenir e controlar a gravidade das lesões da mucosite oral e a sensibilidade dolorosa em pacientes submetidos à radioterapia para tratamento de câncer de cabeça e pescoço (CCP). **Relato dos casos**: Oito pacientes com CCP atendidos para tratamento radioterápico, associado ou não à quimioterapia, foram acompanhados. Foi realizada avaliação clínica, incluindo anamnese meticulosa. Os pacientes foram acompanhados durante todo o período de tratamento radioterápico. Para o protocolo de profilaxia de MO, foi utilizado um equipamento laser de baixa potência, com comprimento de onda na faixa de 660nm, em modo de contato e 30 mW de emissão contínua com 4J/cm^2. Para o protocolo terapêutico, e para comprimento de onda na faixa de 660nm, em modo de contato e 30 mW de emissão contínua com 8J/cm^2 na área da lesão, até sua completa remissão. Todos os pacientes foram acompanhados clinicamente desde o início da terapia antineoplásica até a conclusão do tratamento médico ou remissão total da lesão oral, envolvendo o controle pós-radioterapia. Uma escala visual analógica (EVA) foi usada para medir a dor semanalmente. **Resultados:** Observou-se um desenvolvimento progressivo das lesões da 1ª à 5ª semana. A remissão da mucosite oral foi observada a partir da 7ª semana até o final do tratamento. Houve um aumento contínuo do processo doloroso, atingindo o nível máximo na 6ª semana, com declínio ocorrendo até a 7ª semana. **Conclusão:** A terapia de fotobiomodulação foi capaz de controlar a gravidade das lesões de MO e a sensibilidade dolorosa em pacientes submetidos à radioterapia para tratamento do câncer de cabeça e pescoço, evitando a interrupção da terapia oncológica.

Keywords: Head and Neck Cancer. Low Level Light Therapy. Mucositis. Photobiomodulation. Case Reports.

ABSTRACT

Introduction: Photobiomodulation therapy (PBM) has been recommended for the prevention of oral mucositis (OM). **Objective**: to evaluate the use of PBM to prevent and control the severity of oral mucositis lesions and painful sensitivity in patients undergoing radiotherapy for head and neck cancer (HNC) treatment. **Case reports**: Eight patients with HNC attended for radiotherapy treatment, either associated with chemotherapy, or not were followed up. Clinical evaluation was performed, including meticulous anamnesis. The patients were followed up throughout the entire period of radiotherapy treatment. For the protocol of prophylaxis of OM, low level laser equipment was used, with a wavelength in the range of 660nm, in a contact mode, 30 mW of continuous emission 4J/cm^2 three times per week and for the therapeutic protocol wavelength in the range of 660nm, in a contact mode, 30 mW of continuous emission 8 J/cm^2, in the respective areas compromised by oral mucositis, 3 times per week till the complete remission of the lesions. All the patients were clinically followed up from the beginning of the antineoplastic therapy up to the conclusion of the medical treatment or total remission of the oral lesion, involving post radiotherapy control. A visual analog scale (VAS) was used to measure pain every week. **Results**: A progressive development of the lesions was observed from the 1st to the 5th week. Remission of OM was observed from the 7th week up to the conclusion of treatment. There is a continuous increase in the pain process, attaining the maximum level in the 6th week, with decline occurring up to the 7th week. **Conclusion:** Photobiomodulation therapy was able to control the severity of OM lesions and painful sensitivity in patients undergoing radiotherapy for head and neck cancer treatment, avoiding the interruption of the cancer therapy.

Submitted: December 08, 2022
Modification: February 21, 2022
Accepted: March 14, 2022

***Correspondence to**:
Dr. Maíra Prado
Address: Praça da Bandeira, 149 - Tijuca, Rio de Janeiro, RJ, Brazil. Zip code: 20270-150
Telephone number: +55 (21) 97104-1717
E-mail: mairapr@hotmail.com

INTRODUCTION

Oral cancer is a highly prevalent disease, responsible for elevated mortality rates among individuals in the economically active age group. According to the World Health Organization (WHO) estimates, the number of cancer cases will reach 21 million persons in 2030.[1] Furthermore, according to the WHO, it is necessary to guarantee that people with cancer have access to safe and effective treatment, including pain relief and palliative care.[1]

Onco-hematological patients generally have oral manifestations as side- effects of Radiotherapy (RT) treatment and its intense immunosuppression caused by chemotherapy (CT). Among the most important oral complications of CT and RT, hyposalivation, osteoradionecrosis and oral mucositis may be cited. Oral Mucositis (OM) is a severe, common complication of oncological treatment, and its prevalence is directly related to the chemotherapy regime instituted and its mode of administration. In RT patients, OM is related to the dose of radiation used, area irradiated and time of treatment.[2] Over 40% of the patients will present OM when submitted to primary chemotherapy, and 100% of the patients submitted to RT of head and neck cancer therapy.[2-6]

The OM resulting from the effect of ionizing radiation is manifested as an intense inflammatory reaction of the mucosa that lines the oral cavity and oropharynx. Clinically presented as an erythema, single ulcer or multiple ulcers that may be confluent. The presence of ulcers is always related to intense pain and it also represents a risk factor for opportunist infections. Most of the clinical manifestation of OM occurs in the period between the fifth and seventh day after the beginning of the therapy with RT and CT, with greater involvement of the non-keratinized mucosa. Despite being a reversible phenomenon, depending on its degree of severity, OM may extensively compromise the patients' quality of life, and in some cases, may lead to interruption of the base pathology treatment.[7] In addition to pain, the patient may experience difficulties with the basic oral functions such as speech, swallowing, chewing, as well as difficulty to wear dental prostheses and performing oral hygiene, which may be aggravated by xerostomia or hyposalivation, clinical aspects that could compromise the adherence of patients to the treatment.[8] Therefore, the presence of severe OM may result in serious clinical complication, frequently involving the need for hospitalization, administration of enteral or parenteral nutrition and use of narcotic medication.[9]

Many researchers have studied OM induced by RT and CT, in an endeavor to establish effective protocols for its prevention and treatment. The use of antimicrobial, analgesic and anti-inflammatory agents, for topical or systemic use; parasympathomimetic agents, cell protectors, tissue growth factors, control of oral hygiene, cryotherapy, use of benzydamine mouth washes and Low Level Laser therapy or photobiomodulation (PBM), have been reported.[10,11] In 2019, the Multinational Association of Supportive Care in Cancer (MASCC/ISO) recommended the use of photobiomodulation for the prevention of OM in two cases: for patients having head and neck cancer and for patients before undergoing hematopoietic stem cell transplant.[12]

The aim of this study was to evaluate the use of photobiomodulation therapy to prevent and control the severity of OM lesions and painful sensitivity in patients undergoing radiotherapy for head and neck cancer treatment.

CASES REPORT

This study was approved by the Research Ethics Committee (Protocol Nº. 0251/07). Eight patients with HNC, who were attended at the Radiotherapy Sector of the "Instituto de Câncer Dr. Arnaldo Vieira de Carvalho", São Paulo – SP, for radiotherapy treatment, either associated with chemotherapy, or not were followed up.

Clinical evaluation was performed, by one experienced clinical dentist with 20 years of practice, including meticulous anamnesis and intraoral clinical exam. The patients were followed up throughout the entire period of radiotherapy treatment and were instructed about the importance of maintaining adequate oral hygiene, taking general care relative to body hydration and balanced diet, avoiding dry, hard and spicy foods.

OM was evaluated by means of clinical exam, with the scale recommended by the WHO.[3] The scale is based on the presence of erythema and ulcerations and the impact of these ulcerations on food intake.

Treatment protocol

After the 1st RT session, all the patients were instructed to use artificial saliva manipulated in a laboratory to control hyposalivation. Artificial saliva application was recommended three times a day, or more, according to individual needs.

Laser

For the prophylaxis protocol of OM, low level laser equipment of InGaAlP was used, with a wavelength in the range of 660nm, in a contact mode, 30 mW of continuous emission, fiber diameter/laser output of 2mm, pen tip: 0.03cm^2 Comercial Practical- Kondortech-Ind e Comércio LTDA-EPP-2011 (Registered M.S. ANVISA No.80022400015). The

applications were made during the entire Radiotherapy course three times a week, by one operator, with a prophylactic fluence established at 4.0 J/cm² witch is in the therapy window: energy density of 2-4 J/cm² shown to be mostly effective on improving cell growth[13] and recommended by Zecha *et al*.[14] and MASCC/ISOO.[4] Irradiations were applied as follows: superior and inferior internal lip mucosa (one point in each quadrant), labial commissure (one point each side), the floor of the mouth (one point in each side), lateral and ventral edge and posterior regions of the tongue (total of 10 points), left and right jugal mucosa (4 points each side) and smooth palate (one point on each side), in a contact mode, one punctual application per site of 1 cm². Macroscopic involved tumor site was excluded from PBM. According to de Pauli Paglioni et al.[6] in a systematic review of human clinical studies regarding prevention and treatment of toxicities associated with oncological treatment, although a great variation of the laser protocols has been reported, the majority of the clinical studies using 660nm wavelength and dose from 3,5 J/cm² with 24mW, 4J/cm² with 46mW, 6J/cm² with 25mW, 10J/cm² with 40mW, most studies showed no side effects and were well-tolerated.

For therapeutic treatment, the patients who developed OM, were treated with 8 J/cm² red laser, in the respective areas compromised by oral mucositis, 3 times per week, with intervals of 48 hours between the sessions.

All the patients were clinically followed up from the beginning of the antineoplastic therapy up to the conclusion of the medical treatment or until full remission of the oral lesion, involving post radiotherapy control.

Pain evaluation

For the patients with the condition of mucositis, a visual analog scale (VAS) was used to measure pain. The scale consists of visual identification of pain, in which the patient classifies the values of pain from zero to ten, as being compatible with painful symptoms as follows: **Light pain** (from 0 to 3); **Moderate pain** (from 4 to 6); **Intense pain** (from 7 to 10). The patient marked on the line of the scale the point that they feel represents their perception of their current state of pain.

Patient findings

The patient characteristics are described in Table 1. Among the 8 patients, six patients were submitted to RT and two were treated with RT associated with CT. The Rx dosage for this group was 50 to 70 Gy. Figure 1 illustrated clinical findings of patients 3, 5 and 7 and different degree of OM. The mucositis degree of all patients was shown in Table 2.

The degree of pain, according to VAS scale, is shown in Table 3. When an analysis was performed in terms of time, considering 8 weeks, the mucositis and pain scores, for the 8 patients evaluated, are shown in Tables 4 and 5.

An analyses period of time (8 weeks), relative to oral mucosa, a progressive development of the lesions was observed from the 1st to the 5th week. Remission of oral mucositis was observed from the 7th week up to the conclusion of treatment (Figure 2). When we analyzed the mean values of OM score, when prevention by means of PBM was instituted, we could note that in six of the 8 clinical cases, OM ranged from zero to two, according to the WHO scale.

The distribution of mean values of the pain score, throughout the period of time (Figure 3), show evidence of continuous increase in the pain process, attaining the maximum level in the 6th week, with decline occurring up to the 7th week. New exacerbation in pain process occurred, progressing up to 8th week. Related to the analgesia attained with PBM, previously described in other studies,[3,15] our data demonstrated that the degree of pain ranged from zero to four on the VAS scale. Only one patient (n.6) reported no pain and had no OM during the therapy, but it must be pointed out that individual different responses are expected. Patient 4 reported a pain score of 4 in VAS scale however, OM clinical detected was score 2. In one case (Figure 1C), there was a need for the use of a nasogastric tube during the fifth week of therapy, when OM score was up to 4 but there was not a delay in RT therapy because of that and regression of the OM lesions could be observed by the eighth week. In the present study, the patient included were between age group of 46 till 64 years old being only one female among 7 male patients. We found out that the difficulty of swallowing, dysgeusia and dry mouth sensation were important factors considered by them that directly affected their quality of life and this discomfort could be related to the pain scores reported by them and not only the severity of the clinical OM presented, in patient n. 3 case (Figure 1A), OM score 2 was detected during the second week of treatment while the patient reported highly discomfort and odinophagy. In patient 5 (Figure 1B), OM clinically detected was also score 2 but the patient reported intense pain (score 7-VAS scale), effective treatment must be targeted at the various factors involved in the pain experience such as difficulty of speaking, swallowing, and eating due to the mucositis pain.

***Table 1**: Patients Characteristics.*

Patient	Gender	Age	Tumor Location	Smoking status	Alcohol consumption	Therapy
1	male	51	Soft Palate	smoker	yes	Surgery + RT
2	male	62	Inferior lip	no	no	CT + RT
3	male	46	oropharynx	smoker	yes	Surgery + RT
4	female	51	oropharynx	no	unspecified	Surgery +RT
5	male	54	oropharynx	no	unspecified	Surgery +RT
6	male	58	larynx	smoker	unspecified	RT
7	male	57	oropharynx	smoker	unspecified	CT +RT
8	male	64	Inferior Lip/ mouth floor	smoker	yes	Surgery + RT



***Figure 1**: Clinical findings of patients 3 (A), 5 (B) and 7 (C).*

***Table 2**: Means and standard deviation of mucositis degree presented during the treatment.*

Patients	Mucositis
1	1.25±0.89
2	0.75± 0.71
3	1.67±0.82
4	0.38±0.52
5	1.63±1.41
6	0.00±0.00
7	2.29±1.80
8	1.13±0.64

***Table 3**: Means and standard deviation of degree of pain during the treatment.*

Patients	Pain
1	0.75±0.71
2	1.25±2.31
3	1.17±1.17
4	2.50±2.73
5	3.75±3.49
6	0.00±0.00
7	4.29±3.40
8	1.00±0.82

***Table 4**: Distribution of mean values (mean ± standard deviation) of mucositis scores considering time Intervals during treatment.*

	1st week	2nd week	3rd week	4th week	5th week	6th week	7th week	8th week
OM	0.0± 0.0	0.5 ± 0.7	0.8 ± 0.8	1.2 ± 1.0	1.8 ± 1.2	1.8 ± 1.3	2.0 ± 1.3	1.6 ± 0.9

***Table 5**: Distribution of mean values (mean ± standard deviation) of pain scores considering time Intervals observed.*

	1st week	2nd week	3rd week	4th week	5th week	6th week	7th week	8th week
Pain scores	0.00±0.00	0.37±0.74	1.00±1.30	1.50±2.13	2.85±3.38	4.42±2.87	3.33±3.14	4.00±2.16

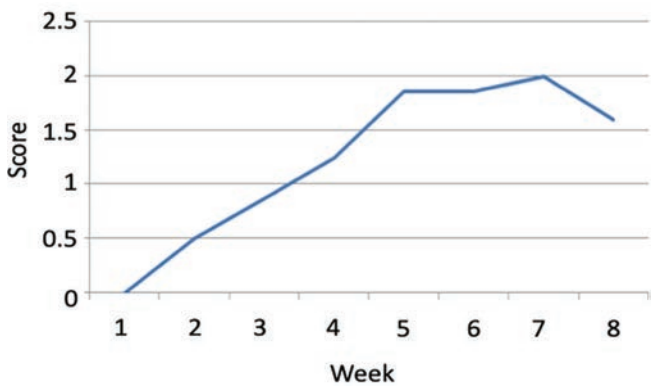

***Figure 2**: Distribution of mean values of mucositis scores per week.*

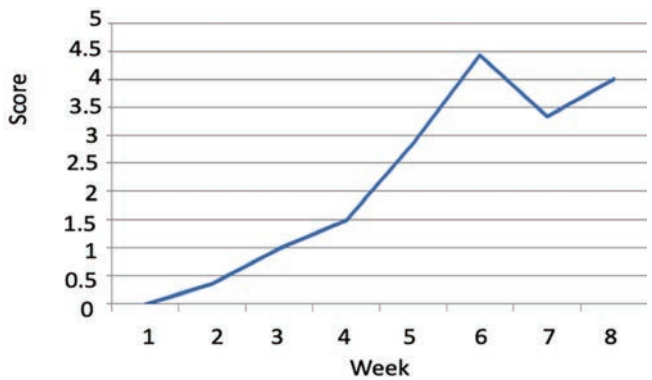

***Figure 3**: Distribution of mean values of pain scores per week*

DISCUSSION

Therapeutic management of oral mucositis resulting from radiotherapy have posed an enormous challenge to researchers and clinicians. RT increases the level of reactive oxygen species that may cause upregulation of transcription factors, such as NF-kB and STAT3. The increased level of transcription factors activates the production of inflammatory cytokines, such as matrix metalloproteinase, leading to tissue damage. The severe lesion of OM may cause interruption of the radiotherapy treatment, and negatively affect the prognosis of patients. Therefore, it is imperative to institute a satisfactory clinical protocol.[16]

In updates of the MASCC/ISOO mucositis guidelines, a new recommendation in favor of PBM was developed for preventing OM in patients both receiving hematopoietic stem cell transplantation conditioned with high dose chemotherapy and undergoing head and neck radiotherapy.[11] This recommendation was consistent with our clinical findings. The radiation-induced mucositis peaks are expected within 2 or 3 weeks in patients treated with cumulative dose in standard 200 centi-Gray (cGy) daily fractioned and these lesions usually heal within several weeks. In the present clinical study, we consider a good clinical result to have detected score two as the most severe score of OM in

6 of 8 patients. These 6 patients demonstrated that PBM markedly reduced severity and duration of OM and they could continue with the cancer therapy and solid diet. However, we cannot affirm that PBM prevented mucositis to occur.

The pathogenesis of OM is not fully understood, yet it is thought to involve direct and indirect mechanisms. Direct mucosal injury radiation and chemotherapy interfere with the average 5 to 14 day turnover time of the oral epithelium and induce apoptosis. Indirect stomatotoxic effects that result from the release of inflammatory constituents, loss of salivary constituents, and therapy induced neutropenia have been postulated to contribute to the development of OM. Due to that, the authors believe that an individualized and detailed follow-up is necessary for each patient. In Case 4, the authors believe that pain could be explained by the fact that coupled with the occurrence of oral candidiasis, this oropharyngeal tumor case must have presented a more severe OM that was unreachable to our PBM. We are able to infer that there was a pain control in most cases as none of them had the need to be submitted to narcotics nor hospitalization even when the OM score was 3 or 4.

In regard of mechanisms of action suggested for PBM, these are related to the action on Cytochrome c oxidase (CcO) in the respiratory chain of the mitochondria, facilitating the transportation of protons by the membrane, which elevates the gradient of protons, leading to the production of ATP (adenosine0 triphosphate), increase in cell proliferation and increase in the production of collagen fibers. PBM potentiates tissue regeneration by the action on different stages: in inflammation, [cell] proliferation and remodeling.[17-19] The use of the visible light spectrum, between 600 and 700nm, has been indicated for oral mucositis treatment due to its superficially action as it penetrates tissues, from 2 to 5mm deep.[7] It must be pointed out that studies conducted with light in the infrared range (wavelength ›700nm), or association of red and infrared light have also been claimed to attain positive results in the control of pain and inflammation.[20] Mobader et al.[19] published a clinical case report in which a diode laser, 980 nm wavelengh, with energy density of 4 J/cm^2 was applied on a daily basis, 5 times per week, in intra and extra-oral regions, for patients undergoing head and neck radiotherapy. The authors reported a regression of the OM lesions and verified that PBM can be considered a good approach for the treatment of dysgeusia and oral dryness, but the literature is still limited in this area.

Our results corroborate with of He et al.[3] who reported consistent findings of the reduction in severity and duration of the OM lesions. Patients undergoing cancer therapy also have heterogeneous chemo and radiotherapy regimes so the PBM protocol must be individualized. The first day of RT is claimed to be the starting point for the prophylactic PBM to be conducted and as soon as an OM lesion is clinically detected, a therapeutic protocol must be applied, respecting up-dated scientific recommendations for the therapeutic window protocols, according to the MASCC recommendations, the curative dose of 4J/cm^2 should be used, whereas a lack of consistent harmonization about PBM parameters is found in clinical trials. It should be pointed out that new technologies and equipment are launched by the industries and the need to update parameters and protocols is constant. The therapeutic protocol must be carried out till the complete remission of the lesion. So, we can conclude that in many clinical studies and case reports, a heterogeneity of treatment days is expected. In our study, after the remission of all lesions, we carried out a 30 day follow-up. In 2019, Martins et al.,[21] in a randomized clinical study, also working with PBM 5 times per week, concomitant with RT, stated that OM was the adverse effect most frequently found, and that its severity was intimately related to the number of sessions of head and neck cancer therapy.

Medicine and Dentistry are moving towards a Person-Centered-Care, a new understanding of the patient in a humanized manner. Each patient must be treated in a different manner; in the case of an oncological patient, it is an even greater challenge. Clinical evaluation associated to the follow-up of biomarkers has been shown to be a helpful instrument for monitoring the individual response.[21] One of the major limitation of the present study is that only eight clinical cases were reported. The small group of people and lack of a control group can also be pointed out as a limitation, since a randomized controlled trial would yield better evidence. Health professionals must understand that population is living longer and habits are changing day by day. There are also new therapies being developed for the treatment of cancer, minimizing its cytotoxic effects, with the goal at all times being to seek quality of life, and integral, multidisciplinary treatment. We understand that the more serious clinical outcomes of OM include impaired quality of life, increased cost and duration of hospital stay, increased incidence of secondary or systematic infections and infection-related mortality, and indirectly decreased survival rate due to possible treatment delays or dose reduction.[20]

According to Peng *et al*.[22], in a meta-analysis, comparing prophylactic treatments for OM, PBM associated to a standard oral care achieved the best effect in preventing severe OM for patients with head and neck cancers receiving radiotherapy, nevertheless, a lack of consistent harmonization about PBM protocols is found in clinical trials. Clinical trials have indicated PBM therapy at least 3 times per week, or even daily, with wavelenghs that range from: 633 to

685 nm in the red, or from 780 to 970 nm in infra-red. Despite our small sample, we agree with Peng et al.[22] that more individualized data from the patients are needed to minimize bias. Thus, the standard oral care must always be provided which is the basic care for OM and when associated to PBM, better clinical results are expected. The PBM implemented as a routine in the prevention and treatment of OM in the present study, administrated three times a week, showed desired therapeutic effect. This supportive treatment is used in a growing number of care centers. However, multicenter randomized controlled trials should be conducted in order to standardize parameters and define the best preventive/therapeutic protocol with long-term follow-ups.[20,22]

CONCLUSION

Photobiomodulation therapy was able to control the severity of OM lesions and painful sensitivity in patients undergoing radiotherapy for head and neck cancer treatment, avoiding the interruption of the cancer therapy.

REFERENCES

1. Nações Unidas Brasil. Available from: https://nacoesunidas.org/oms-cancer-mata-88-milhoes-de-pessoas-anualmente-no-mundo/
2. Jones JA, Avristscher EB, Cooksley CD, Michelet M, Bekele BN, Elting LS. Epidemiology of treatment-associated mucosal injury after treatment with newer regimes for lymphoma, breast, lung, or colorectal cancer. Support Care Cancer. 2006 Jun;14(6):505-15. doi: 10.1007/s00520-006-0055-4.
3. He M, Zhang B, Shen N, Wu N, Sun J. A systematic review and meta-analysis of the effect of low-level laser therapy (LLLT) on chemotherapy-induced oral mucositis in pediatric and young patients. Eur J Pediatr. 2018 Jan;177(1):7-17. doi: 10.1007/s00431-017-3043-4.
4. Elad S, Cheng KKF, Lalla RV, Yarom N, Hong C, Logan RM, Bowen J, Gibson R, Saunders DP, Zadik Y, Ariyawardana A, Correa ME, Ranna V, Bossi P; Mucositis Guidelines Leadership Group of the Multinational Association of Supportive Care in Cancer and International Society of Oral Oncology (MASCC/ISOO). MASCC/ISOO clinical practice guidelines for the management of mucositis secondary to cancer therapy. Cancer. 2020 Oct 1;126(19):4423-4431. doi: 10.1002/cncr.33100. Epub 2020 Jul 28. Erratum in: Cancer. 2021 Oct 1;127(19):3700. PMID: 32786044; PMCID: PMC7540329.
5. Rezk-Allah SS, Elshafi HMA, Farid RJ, Hassan MAE, Alsirafy SA. Effect of Low-Level Laser Therapy in Treatment of Chemotherapy Induced Oral Mucositis. J Lasers Med Sci. 25 de fevereiro de 2019;10(2):125–30.
6. de Pauli Paglioni M, Araújo ALD, Arboleda LPA, Palmier NR, Fonsêca JM, Gomes-Silva W, Madrid-Troconis CC, Silveira FM, Martins MD, Faria KM, Ribeiro ACP, Brandão TB, Lopes MA, Leme AFP, Migliorati CA, Santos-Silva AR. Tumor safety and side effects of photobiomodulation therapy used for prevention and management of cancer treatment toxicities. A systematic review. Oral Oncol. 2019 Jun;93:21-28. doi: 10.1016/j.oraloncology.2019.04.004. Epub 2019 Apr 10. PMID: 31109692.
7. Bensadoun R, Nair R, Pine B, Caillot E, Berger A, Jarde P. Laser parameters drawn from meta-analysis on the efficacy of LLLT in oral mucositis. Support Care Cancer 2012; 20(1):1-283. doi:10.1007/s00520-011-1202-0.
8. Rolston KVI. The burdens of cancer therapy: clinical and economic outcomes of chemoterapy-induced mucositis. Cancer 2004 Mar 15;100(6):1324-5. doi: 10.1002/cncr.20101.
9. Antunes HS, Herchenhorn D, Small IA, Araújo CM, Viégas CM, Cabral E, et al. Phase III trial of low-level laser therapy to prevent oral mucositis in head and neck cancer patients treated with concurrent chemoradiation. Radiother Oncol. 2013 Nov;109(2):297-302. doi: 10.1016/j.radonc.2013.08.010.
10. Zanin T, Zanin F, Carvalhosa AA, Castro PH, Pacheco MT, Zanin IC, et al. Use of 660-nm diode laser in the prevention and treatment of human oral mucositis induced by radiotherapy and chemotherapy. Photomed Laser Surg. 2010 Apr;28(2):233-7. doi: 10.1089/pho.2008.2242.
11. Lalla RV, Bowen J, Barasch A, Elting L, Epstein J, Keefe DM, et al. Mucositis Guidelines Leadership Group of the Multinational Association of Supportive Care in Cancer and International Society of Oral Oncology (MASCC/ISOO). MASCC/ISOO clinical practice guidelines for the management of mucositis secondary to cancer therapy. Cancer. 2014 May 15;120(10):1453-61. doi: 10.1002/cncr.28592. Epub 2014 Feb 25. Erratum in: Cancer. 2015 Apr 15;121(8):1339.
12. Zadik Y et al. Systematic review of photobiomodulation for the management of oral mucositis in cancer patients and clinical practice guidelines. Support Care Cancer. 2019 Oct;27(10):3969-3983. doi: 10.1007/s00520-019-04890-2.
13. Azevedo LH, de Paula Eduardo F, Moreira MS, de Paula Eduardo C, Marques MM. Influence of different power densities of LILT on cultured human fibroblast growth : a pilot study. Lasers Med Sci. 2006 Jul;21(2):86-9. doi: 10.1007/s10103-006-0379-9. Epub 2006 May 13. PMID: 16699912.
14.Zecha JA, Raber-Durlacher JE, Nair RG, Epstein JB, Elad S, Hamblin MR, et al. Low-level laser therapy/photobiomodulation in the management of side effects of chemoradiation therapy in head and neck cancer: part 2: proposed applications and treatment protocols. Support Care Cancer. 2016 Jun;24(6):2793-805. doi: 10.1007/s00520-016-3153-y. Epub 2016 Mar 17. PMID: 26984249; PMCID: PMC4846551.
15. Amadori F, Bardellini E, Conti G, Pedrini N, Schumacher RF, Majorana A. Low-level laser therapy for treatment of chemotherapy-induced oral mucositis in childhood: a randomized double-blind controlled study. Lasers Med Sci. 2016 Aug;31(6):1231-6. doi: 10.1007/s10103-016-1975-y.
16. Sonis ST. Oral mucositis. Anticancer Drugs. 2011 Aug;22(7):607-12. doi: 10.1097/CAD.0b013e3283462086.
17. Murphy BA, Gilbert J. Dysphagia in head and neck cancer patients treated with radiation: assessment, sequelae, and rehabilitation. Semin Radiat Oncol. 2009 Jan;19(1):35-42. doi: 10.1016/j.semradonc.2008.09.007.
18. Cooperstein E, Gilbert J, Epstein JB, Dietrich MS, Bond SM, Ridner SH, et al. Vanderbilt Head and Neck Symptom Survey version 2.0: report of the development and initial testing of a subscale for assessment of oral health. Head Neck. 2012 Jun;34(6):797-804. doi: 10.1002/hed.21816.
19. Mobadder ME, Farhat F, Mobadder WE, Nammour S. Photobiomodulation Therapy in the Treatment of Oral Mucositis, Dysgeusia and Oral Dryness as Side-Effects of Head

and Neck Radiotherapy in a Cancer Patient: A Case Report. Dent J (Basel). 2018 Nov 10;6(4):64. doi: 10.3390/dj6040064.
20. Kuhn A, Porto FA, Miraglia P, Brunetto AL. Low-level infrared laser therapy in chemotherapy-induced oral mucositis: a randomized placebo-controlled trial in children. J Pediatr Hematol Oncol. 2009 Jan;31(1):33-7. doi: 10.1097/MPH.0b013e318192cb8e. PMID: 19125084.
21. Martins AFL, Nogueira TE, Morais MO, Oton-Leite AF, Valadares MC, Batista AC, et al. Effect of photobiomodulation on the severity of oral mucositis and molecular changes in head and neck cancer patients undergoing radiotherapy: a study protocol for a cost-effectiveness randomized clinical trial. Trials. 2019 Feb 1;20(1):97. doi: 10.1186/s13063-019-3196-8. PMID: 30709370; PMCID: PMC6359861.
22. Peng H, Chen BB, Chen L, Chen YP, Liu X, Tang LL, et al. A network meta-analysis in comparing prophylactic treatments of radiotherapy-induced oral mucositis for patients with head and neck cancers receiving radiotherapy. Oral Oncol. 2017 Dec;75:89-94. doi: 10.1016/j.oraloncology.2017.11.001.