ESTHETIC REHABILITATION IN PRIMARY AND PERMANENT SUCCESSORS INCISORS IN A CHILD WITH CONOIDAL AND ABSENCE TEETH: A CASE REPORT

Roberta Costa **Jorge**[1,2], Patrícia Papoula Gorni dos **Reis**[1,2], Fernanda Barja-Fidalgo Silva de **Andrade**[1], Vera Mendes **Soviero**[1,2], Tatiana Kelly da Silva **Fidalgo**[1*]

[1]Department of Preventive and Community Dentistry, Universidade do Estado do Rio de Janeiro - UERJ, Rio de Janeiro, Brazil.
[2]Dental School, Faculty of Arthur Sá Earp Neto - UNIFASE, Petrópolis, Rio de Janeiro, Brazil.

Palavras-chave: Estética. Reabilitação Oral. Anormalidades Dentárias. Displasia Ectodérmica. Bullying.

RESUMO

Objetivo: Mostrar o tratamento estético realizado em incisivos decíduos e em seus sucessores permanentes em uma criança com anomalias dentárias congênitas (dentes conoides e ausentes), que associado a desproporção óssea do terço médio da face levaram a um diagnóstico suspeito de displasia ectodérmica. **Relato de caso**: Este relato foi redigido seguindo o *CARE Statement*. Menina de 6 anos de idade compareceu à Clínica de Odontopediatria com queixa de bullying devido à aparência de seus dentes. A reanatomização dos incisivos decíduos conoides foi feita com coroas de acetato pré-formadas e resina composta direta. Após 15 meses, os incisivos decíduos esfoliaram e os incisivos permanentes irromperam também com formato conoide. Para a reabilitação estética, foram realizadas restaurações diretas com resina composta pela técnica incremental guiada por matriz de silicone confeccionada a partir do enceramento diagnóstico. **Conclusão**: No seguimento, paciente e responsáveis relataram satisfação com a aparência do sorriso e aumento da autoestima. O caso continua em acompanhamento e o planejamento futuro incluirá ortodontia e prótese dentária.

Keywords: Esthetic. Oral Rehabilitation. Tooth Abnormalities. Ectodermal Dysplasia. Bullying.

ABSTRACT

Objective: To show the aesthetic treatment performed in deciduous incisors and in permanent successors in a child with congenital dental abnormalities (conoid and missing teeth), which associated with bone disproportion of the middle third of the face led to a suspicious diagnosis of ectodermal dysplasia. **Case report**: This report was written following the CARE Statement. A 6-year-old girl attended the Pediatric Dental Clinic complaining about bullying due to appearance her teeth. The reanatomization of the conoid-shaped deciduous incisors was done with direct composite resin using preformed acetate crowns. After 15 months, the deciduous incisors had exfoliated and the permanent incisors erupted also with a conoid shape. For aesthetic rehabilitation, direct composite restorations were performed using the incremental technique guided by a silicone matrix made based on the diagnostic wax-up. **Conclusion**: In the follow-up, the patient and guardians reported satisfaction with appearance of her smile and an increased self-esteem. The case remains under follow-up and future planning will include orthodontics and prosthodontics.

Submitted: December 28, 2021
Modification: January 07, 2022
Accepted: March 28, 2022

***Correspondece to**:
Tatiana Kelly da Silva Fidalgo
Address: Avenida Vinte e Oito de Setembro, 157, Vila Isabel, Faculdade de Odontologia, Universidade do Estado do Rio de Janeiro, Rio de Janeiro/RJ, Brazil. Zip code: 20551-030
Telephone number: +55 (21) 2868-8286
E-mail: tatianaksfidalgo@gmail.com

INTRODUCTION

Ectodermal dysplasia (OMIM 305100)[1] is a hereditary disease that causes abnormal embryonic development of two or more anatomic structures derived from ectoderm (hair, nails, teeth, and sweat glands). Clinical features are characterized by thin and sparse hair, including a reduced density of eyelash and eyebrow hair; periocular skin with fine wrinkles and hyperpigmentation, and frequent hypoplasia of the middle third of the face, saddle nose, protruding lips, auricular malformation with oblique implantation, protruding supracilliary regions. These patients present usually considerable missing teeth (anodontics, oligodontics or hypodontics) and affected teeth may also have conoid crowns.[2–4] For that reason, not rarely, dentists may be the first to suspect about the diagnosis.

The diagnosis of ectodermal dysplasia (ED) is based on observation of clinical manifestations and genetic testing. According to Wright et al.,[2] ED can be divided into two groups according to the phenotype that the individual presents: classic and mild. The classic form is characterized by the presence of three main signs, which become obvious in childhood, allowing for the early diagnosis of the condition: Hypohidrosis, Hypotrichosis and Hypodontia and other dental changes. The mild form of ED is characterized by less severe manifestation of some, or all of the main features mentioned in the classic form.

According to the World Health Organization (WHO), quality of life is perception of individuals of their own position in life in the context of the culture and value systems in which they live, and in relation to their goals, expectations, standards and concerns.[5] The Bullying is a negative and aggressive situation in which other exposes a person repeatedly. Due to its distinctive features, ectodermal dysplasia may affect patients' social relations and psychological well-being. Oral aspects may be associated with episodes of bullying and lack of social acceptance in school groups,[6] causing a negative impact on the quality of life.

This report aimed to show the aesthetic treatment with direct composite restorations in primary and in the successor permanent teeth in a child with ectodermal dysplasia, through a fast, accessible and low-cost alternative. The present case was described according to the CARE protocol.[7]

CASE REPORT

This case was reported following the Care Statement and in accordance with the Declaration of Helsinki.[8]

Medical and dental history

Female patient, 6 years old, black, with family history of a sibling with missing teeth and tooth abnormality, suggestive of ectodermal dysplasia attended for dental care at the Pediatric Dentistry Clinic of a Brazilian Public University, at the end of 2017. Her main complaint was dissatisfaction with her smile. She described her teeth as "claw teeth" and reported episodes of verbal bullying, being nicknamed "little shark" by classmates. Her parents mentioned that there were no alterations in family similar to that. The mother and the child signed the consent and authorization to start the dental treatment after understanding the clinical procedures suggested by the dental team.

Initial clinical and radiographic examinations

Extraoral clinical examination, showed normal hair on the eyebrow and head; reduced middle third of the face, malformed ears with oblique implantation and periocular skin with hyperpigmentation. Intraoral clinical examination showed a caries-free deciduous dentition, good oral hygiene; teeth 51, 61, 62, 72, 71, 81, 82 with abnormal shape and absence of tooth 52. In the radiography, it was observed that the permanent central incisors had also an abnormal shape (11 and 21) and that teeth 12, 22, 31, 41, 36 and 46 were missing (Figure 1).

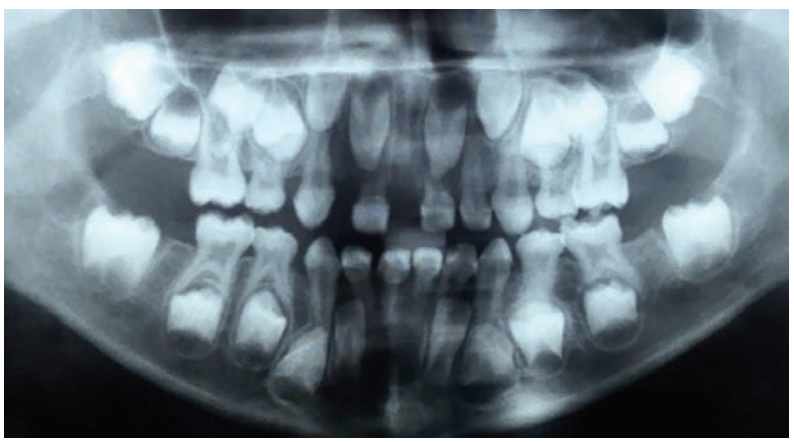

***Figure 1**: Panoramic radiographic of patient with at 6 years old and clinical.*



***Figure 2**: Esthetic treatment in the primary dentition with crowns. (a) Checking the fit of the crowns. (b) After the conditioning with 37% phosphoric acid and application of adhesive. (c) Removal of the crown acetate mold. (d, e) Frontal and lateral view immediately after removal excess with a diamond drill and polishing.*

Treatment performed in the primary teeth

The proposed treatment was the reanatomization of the seven abnormal teeth with direct composite resin restoration (Figure 2). Preformed acetate crowns (Crown Forms®, Dentsply) were used following the clinical protocol described below:

1. the preformed acetate crowns (Crown Forms®, Dentsply) were selected and had their anatomic crown height adjusted in a working plaster cast (Alginate Plastalgin type II® – Septodont – Brazil; DentMix Type IV Special Stone Plaster® - Asfer – Brazil);
2. prophylaxis of teeth was performed with pumice stone paste;
3. the cut preformed acetate crowns were tested in the mouth;
4. a hole was made with a drill in the incisal edge of the preformed acetate crowns for extravasation of the excess of composite resin;
5. the enamel surface was etched with 37% phosphoric acid for 30 seconds followed by rinsing and air-drying;
6. adhesive (Adper™ Single Bond 2, 3M ESPE - Brazil) was applied in the whole etched enamel surface and light cured for 20 seconds;
7. the preformed acetate crowns were filled with composite resin (Filtek Z350 XT™ – B2B, 3M ESPE - Brazil) and placed over the teeth; excess of resin in the gingival margin and in incisal edge was removed with a carver and the crown was light cured for 40 seconds, 20 seconds through the buccal and 20 seconds through the lingual surface (this step was done for each tooth at a time);
8. The preformed acetate crowns were removed, the remaining excess of resin was removed with a diamond burr (n. 3168, KG Sorensen – Brazil) and polishing was done (Kit Polimento de Resina, Microdont – Brazil).

Treatment performed in the permanent teeth

Fifteen months later, the deciduous incisors (51, 61, 72 and 82) had exfoliated and it was already possible to see the permanent central incisors (teeth 11 and 21) erupting in the mouth with a conoid shape. The teeth 32 and 42 erupted with a normal appearance. Again, the child reported a negative impact in socialization and self steem caused by the appearance of her teeth. Therefore, we planned a new aesthetic rehabilitation phase with direct composite resin restorations. The clinical sequence of this new treatment phase is described below, and the final results is shown in Figure 3:

1. the plaster working model was obtained (Alginate Plastalgin type II® – Septodont – Brazil; DentMix Type IV Special Stone Plaster® - Asfer – Brazil);
2. the diagnostic wax-up was done to obtain a proper contour of the central incisors improving the width/length proportion of the teeth (New Wax® - Technew - Brazil);

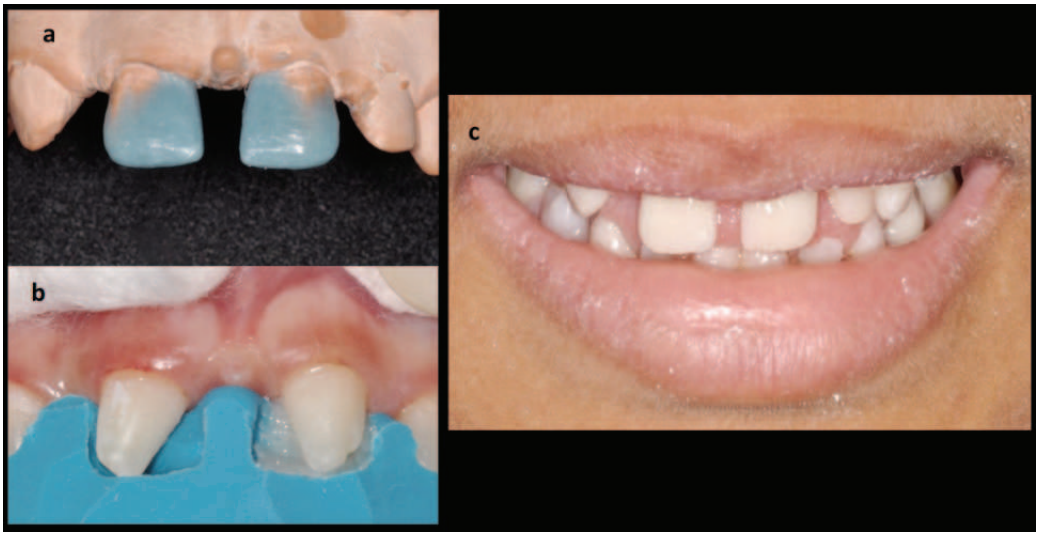

Figure 3: Esthetic treatment in the permanent dentition (teeth 11 and 21) with composite resin. (a) Progressive waxing of the plaster model and making of the mold silicone guide. (b) Checking the adaptation of the mold and making the palatine face with composite resin. (c) Frontal view immediately after removal excess with a diamond drill and polishing.

3. the silicone matrix was made from the diagnostic wax-up to be used as a guide for the direct composite restoration (Clonage®, Nova DFL - Brazil);
4. the enamel surface was etched with 37% phosphoric acid for 30 seconds followed by rinsing and drying;
5. adhesive (Adper™ Single Bond 2, 3M ESPE - Brazil) was applied in the whole etched enamel surface and light cured for 20 seconds;
6. with the silicone matrix in position, a first layer of composite resin (Filtek Z350 XT – A2E, 3M ESPE - Brazil) was applied within the matrix creating the palatal shape and the mesial/distal angles;
7. successive increments of composite resin were placed to complete the restoration (Filtek Z350 XT – A2E and A2B, 3M ESPE - Brazil);
8. the edges of the restoration were finishing was done with a fine diamond burr (n. 3195F, KG Sorensen – Brazil) and polishing with polishing discs (Soflex, 3M ESPE - Brazil) fitted with a low-speed pen.

Follow-up

The patient attended for follow up appointments 1 week, 4 months and 12 months after the treatment when the condition of the restorations and the patient's satisfaction were assessed.

DISCUSSION

In the first stage of treatment, represented by the reanatomization of the deciduous teeth (51, 61, 62, 72, 71, 81, 82), our objective was fulfilled once the aesthetic was established, the patient felt better with her smile and the treatment did not hinder the natural exfoliation of the deciduous teeth. The preformed acetate crowns are largely used in Pediatric Dentistry because they provide good esthetic results, are low cost and practical. The proper anatomic contour of the teeth is easily obtained with a single insertion of the composite resin. In the present case, the previous adjustment of the preformed acetate crowns in the working plaster cast reduced the chair time and certainly favored patient's collaboration during treatment. Appointment duration should not be extended beyond the patient's tolerance level, avoiding irritability and tiredness.[9] With the technique, it was possible to restore the seven deciduous incisors in a single appointment. In total, only three dental appointments were necessary: an initial appointment for impression; the main appointment when the restorations were done; and a final appointment for final polishing.

A limitation of the restoration through preformed acetate crowns is the impossibility of using the stratification technique for a better reproduction of the shades of the natural tooth. In primary teeth, it is not a major concern as the so-called "milk teeth" are whiter, more opaque and present less color nuances than permanent teeth. Hence, the esthetic result is good despite the use of only one color of composite resin. The same result should not be expected in permanent teeth that are polychromatic. For this reason, in the second phase of the treatment, after the eruption of the permanent teeth, we opted for another restorative alternative, the incremental technique. In order to have a more predictable result, a silicone personalized matrix was made based on the diagnostic wax-up. Besides guiding the reanatomization of the teeth in terms of size and shape, the silicone matrix also reduces chair time,[10] which is of particular importance when dealing with children.

Conventionally, anterior composite restorations require that a beveled wear is done on the enamel surface. In the present case, no tooth preparation was done. We decided to keep the integrity of the teeth. Only acid etching was done before applying the adhesive and the composite resin. In the future, if the patient is not completely satisfied with the appearance of the resin restorations, they can be replaced for prosthetic alternatives like ceramic crowns.[11]

Although the child was 6 years old, the ectodermal dysplasia had not been diagnosed until she came to the dental clinic with the complaint of abnormal shape of the deciduous teeth. Her facial appearance was not so characteristic of the syndrome, which is not surprising as most females present only mild or moderate signs of this genetic disorder.[12] Hence, the teeth abnormalities were the key finding that leaded to the suggestive diagnosis of ectodermal dysplasia. Nonetheless, the patient was referred to the genetic pediatric clinic for a confirmation of the diagnosis and genetic counseling to the family.

The clinical success of the treatment was verified by the patient's great satisfaction with the aesthetics of her teeth in both deciduous and permanent dentition. This change ended bullying. Dental malformations, besides affecting aesthetics and making children potential targets for aggressors,[13] usually require complex and usually costly dental treatment. The techniques presented in this case are easily performed in children because they are simple and relatively fast. Moreover, they are conservative alternatives, as they do not require tooth preparation or local anesthesia. More invasive treatment, such ceramic crowns combined to implants to replace missing teeth, can be postponed until orofacial growth is complete.

In conclusion, direct composite restorations done with preformed acetate crowns and silicone matrix technique were effective in improving the aesthetic appearance of conoid-shaped deciduous teeth and permanent teeth, respectively. Both techniques are simple, easy to handle, and relatively low cost. The child and her mother were satisfied with the aesthetic result, which had a positive impact in the social relations and well-being of the child.

REFERENCES

1. OMIM - Online Mendelian Inheritance in Man. ECTODERMAL DYSPLASIA 1, HYPOHIDROTIC, X-LINKED; XHED [Internet]. 2019. Available from: https://www.omim.org/entry/305100.
2. Wright JT, Fete M, Schneider H, Zinser M, Koster MI, Clarke AJ, et al. Ectodermal dysplasias: Classification and organization by phenotype, genotype and molecular pathway. American Journal of Medical Genetics, Part A. 2019;179(3):442–7. doi: https://doi.org/10.1002/ajmg.a.61045.
3. Masse J, Pérusse R. Ectodermal dysplasia. Archives of Disease in Childhood. 1994;71:1–2.
4. Itin PH. Etiology and pathogenesis of ectodermal dysplasias. American Journal of Medical Genetics, Part A. 2014;164(10):2472–7. doi: http://dx.doi.org/10.1002/ajmg.a.36550.
5. Group. The WHOQOL. The World Health Organization Quality of Life Assessment (WHOQOL): Position paper from the World Health Organization. Social Science & Medicine. 1995;41(10):1403–9.
6. Al-Omari IK, Al-Bitar ZB, Sonbol HN, Al-Ahmad HT, Cunningham SJ, Al-Omiri M. Impact of bullying due to dentofacial features on oral health-related quality of life. American Journal of Orthodontics and Dentofacial Orthopedics. 2014;146(6):734–9. doi: http://dx.doi.org/10.1016/j.ajodo.2014.08.011.
7. Riley DS, Barber MS, Kienle GS, Aronson JK, von Schoen-Angerer T, Tugwell P, et al. CARE guidelines for case reports: explanation and elaboration document. Journal of Clinical Epidemiology. 2017;89:218–35. doi: http://dx.doi.org/10.1016/j.jclinepi.2017.04.026.
8. World Medical Association. World Medical Association Declaration of Helsinki: ethical principles for medical research involving human subjects. JAMA. 2013 Nov 27;310(20):2191-4. doi: http://dx.doi.org/10.1001/jama.2013.281053.
9. Stigers JI. Nonpharmacologic Management of Children's Behaviors. In: McDonald R, Avery D, editors. McDonald and Avery's Dentistry for the Child and Adolescent,. Tenth Edit. 2016. p. 286–302.
10. Audrey L, Valadas R, Assef M, Lotif L, Martins E, Neto R, et al. Aplicação da técnica da muralha de silicona em paciente pediátrico: relato de caso clínico. Arquivo Brasileiro de Odontologia. 2017;12(1):24–7.
11. Ferreira C, Ferreira R, Fernandes ML, Branco K, Arantes R, Leão L. Displasia Ectodérmica: relato de caso. Arquivos em Odontologia. 2012;48(1):47–52. doi: http://dx.doi.org/10.7308/aodontol/2012.48.11.07.
12. Aquino SN, Paranaíba LMR, Swerts MSO, Martelli DRB, Barros LM de, Martelli Junior H. Orofacial features of hypohidrotic ectodermal dysplasia. Head and Neck Pathology. 2012;6:460–6.
13. Scheffel DLS, Jeremias F, Fragelli CMB, dos Santos-Pinto LAM, Hebling J, De Oliveira OB. Esthetic dental anomalies as motive for bullying in schoolchildren. European Journal of Dentistry. 2014;8(1):124–8. doi: http://dx.doi.org/10.4103/1305-7456.126266.