MULTIDISCIPLINAR AESTHETIC DENTAL REHABILITATION USING PREFABRICATED COMPOSITE RESIN VENEERS AFTER ORTHODONTIC TREATMENT

Cláudia Callegaro de **Menezes**[1*], Nathara Máximo Moreira **Cardoso**[1], Lincoln Moreira **Mendes**[1], Hana **Fried**[1], Gisele Damiana Da Silveira **Pereira**[1]

[1] Department of Clinical Dentistry, Universidade Federal do Estado do Rio de Janeiro, Rio de Janeiro, RJ, Brazil.

Palavras-chave: Estética Dentária. Diastema. Ortodontia. Gengivectomia.

RESUMO

Introdução: A odontologia cosmética apresenta-se como um dos fatores primordiais no planejamento odontológico, influenciando as pessoas em obter restaurações imperceptíveis e dentes cada vez mais claros. Muitas são as alterações que podem ocasionar problemas estéticos, dentre elas, as discrepâncias entre o tamanho dos dentes e do arco, causando diastemas anteriores múltiplos. Em algumas situações, o tratamento ortodôntico não é suficiente para atender as exigências e expectativas estéticas do paciente que podem necessitar de procedimentos restauradores e periodontais adicionais. As facetas pré-fabricadas de resina composta, são facetas pré polimerizadas de compósito, que surgiram no mercado para simplificar o procedimento restaurador, reduzindo o tempo de trabalho. **Objetivo**: Este artigo teve por objetivo apresentar um caso clínico no qual facetas pré-fabricadas de resina composta foram utilizadas para o tratamento de diastemas para uma reabilitação oral após o tratamento ortodôntico e cirurgia periodontal de forma a alcançar excelência estética. Ele também visa discutir indicações, vantagens e limitações da técnica. **Relato do caso**: O plano de tratamento foi dividido em duas fases. No primeiro, foi realizado um tratamento ortodôntico para alinhar e nivelar os dentes. Isto foi seguido pela cirurgia periodontal, para corrigir a margem gengival. A segunda fase foi a cimentação de facetas compostas diretas, a fim de obter um resultado estético agradável. **Conclusão**: A associação entre os tratamentos foi bem sucedida e provou ser minimamente invasivo, com um mínimo de abrasão dental e preservação das estruturas anatômicas, resultando em melhoria da saúde e satisfação do paciente.

Keywords: Aesthetic Dentistry. Diastema. Orthodontics. Gingivectomy.

ABSTRACT

Introduction: Cosmetic dentistry is one of the primary factors in dental planning, influencing people to obtain imperceptible restorations and increasingly clear teeth. Several disorders, such as discrepancies between the teeth size and the arch size, which cause multiple anterior diastemas, can generate aesthetic issues. In some situations, orthodontic treatment is not sufficient to meet the patient's aesthetic expectations, which may require additional restorative and periodontal procedures. The prefabricated facets of composite resin are prepolymerized composite facets that have appeared on the market to simplify the restorative procedure, reducing working time. **Objective**: This paper aims to present a clinical case in which prefabricated composite resin veneers were used to treat diastemas for oral rehabilitation after orthodontic treatment and periodontal surgery in order to achieve aesthetic excellence. It also aimed to discuss indications, advantages, and limitations of the technique. **Case report**: The treatment plan was divided into two phases. In the first one, an orthodontic treatment was performed to aligned and leveled the teeth. This was followed by the periodontal surgery, to correct the gingival margin. The second phase was the cementation of costumized direct composite veneers, in order to achieve an esthetical pleasing result. **Conclusion**: The association of treatments was successful and proved to be a minimally invasive, with minimum dental abrasion and preservation of anatomic structures, resulting improved patient health and satisfaction.

Submitted: March 22, 2018
Modification: April 13, 2018
Accepted: April 14, 2018

Correspondence to:
Cláudia Callegaro de Menezes
Address: Rua Álvaro Ramos, 185/305. Botafogo. Rio de Janeiro- RJ, Brazil.
Telephone Number: +55 21 99153-2396
E-mail: cacamenezes@hotmail.com

INTRODUCTION

An ideal smile is associated with buccal health, facial harmony, and synergy between form and function. One of the biggest issues in daily clinical practice is the discrepancy between the dimensions of teeth and arch. However, its correction represents a challenge for professionals due to the extreme range of treatments available.[1]

Orthodontic treatments allow for the repositioning of teeth to achieve harmony with the adjacent teeth, arch and facial form, in order to create a proper environment for gingival health and for a stable and functional occlusion.[2] Cases involving excessive space, discrepancies between the teeth and arch sizes, and changes in color or shape may require additional restoration and periodontal procedures.[3] Therefore, a multidisciplinary collaboration between professionals in the fields of orthodontics, restorative dentistry, and periodontics results in an improved application of their competences for a successful treatment for the patient.[4]

The progress in adhesives for dental hard tissues and the advances in dental ceramics have enabled conservative and long-lasting treatments,[5] since dental ceramics represent one of the most stable materials available. They also offer improved aesthetics due to their ability to reproduce the color, texture, and translucency of natural dental enamel. However, some mechanical limitations, such as their fragility, low fracture toughness, the requirement of a laboratorial phase, and the high cost, may discourage patients and dental professionals from choosing them.[6]

The prefabricated composite resin veneer system is likely to be established as a modern version of direct composite resin restorations and may eventually replace the use of ceramic veneers. The creation of extremely aesthetic and thin lenses, combined with higher pressure and temperature, followed by laser surface vitrification, resulted in improved physical properties of prefabricated composite resin veneers. Thus, they have become an excellent treatment option and a possible alternative to ceramic veneers for the treatment of multiple diastemas.[6]

Therefore, this paper presents a clinical case in which prefabricated composite resin veneers were used to treat diastemas for oral rehabilitation after orthodontic treatment and periodontal surgery in order to achieve aesthetic excellence. It also discusses indications, advantages, and limitations of the technique.

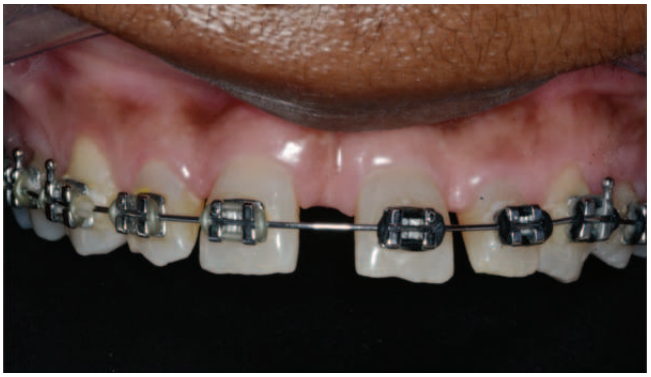

Figure 1: *Initial view after placing braces with lips pulled back.*

CASE REPORT

A 54-year-old woman came to the School of Dentistry, Federal University of Rio de Janeiro, complaining specifically about the aesthetics of her smile and difficulties in speech.

The aesthetic analysis conducted during the clinical examination revealed disharmonic appearance of her smile and the presence of multiple diastemas in the superior and inferior arches, mismatches between teeth, and inconsistent shapes and sizes. The treatment plan for this patient was divided into two phases. In the first phase, an orthodontic treatment was performed with Roth bracket prescription, slot 0.22, and bonding of tooth 15 to 25 **(Figure 1).** During this phase, teeth were aligned and leveled, and their rotations, inclinations, and angulations were corrected in order to reduce vertical and horizontal discrepancies. Due to the discrepancy between bone bases and teeth, the residual spaces remained significant at the end of treatment. Consequently, the spaces were divided in such a way that the teeth were placed in a position that was more harmonic and favorable for occlusion with prefabricated composite resin veneers. For the second phase of treatment, it was decided to use Brilliant TMNG Componeer® prefabricated composite resin veneers (ColteneVigodent SA, Indústria e Comércio, Rio de Janeiro, Brazil) for teeth 14,13,12,11, 21, 22, 23, and 24.

Teeth were measured in order to provide better aesthetic proportions between dental width and height as per the concepts of the Golden Ratio by mapping the necessary changes. Because they were small and presented large spacing, larger veneers (transparent 11L and 21L) were selected. For the other teeth, corresponding veneers were selected (transparent 14L, 13L, 12L, 22L, 23L and 24L).

At the end of the orthodontic treatment, it was observed that the zeniths of teeth 21, 22, and 23 were not aligned with the parallel teeth on the right side. For this reason, a gingivoplasty was performed to re-stablish an aesthetic gingival line **(Figure 2A).** Under local infiltration anesthesia, the bleeding points were determined with an exploratory probe. This was followed by the connection of these points



***Figure 2A**: Approximate view of the upper arch immediately after gingivoplasty of teeth 21, 22, and 23.*
***Figure 2B:** Approximate picture after the orthodontic treatment showing teeth in more harmonic and favorable positions for completion with prefabricated composite resin veneers.*

with a 15c slide using the internal bezel technique and subsequent removal of the gingival collar; 1mm of teeth 21, 22, and 23 were removed, and the length of clinical crowns and the height of the gingival margin were determined. After the area healed, the brace were removed **(Figure 2B).**

Preparation for the veneers was essentially only the abrasion of the more prominent edges on the vestibular surface of teeth for a better setting of the veneers. After relative isolation, the veneers were customized and tested. To cement the parts, the internal surfaces of the veneers and teeth were treated phosphoric acid before the application of adhesive system.



***Figure 3**: Cemented veneers of all teeth.*

The application of the veneers began with teeth 11 and 21. The Brilliant TMNG Componeer® composite resin (enamel A2) was spread on the internal surface of the veneers, which were then positioned and gently pressed. The restorations



***Figure 4:** Final view after cementation of veneers.*

were aligned according to the facial median line and checked for symmetry. The most critical excesses were removed with an exploratory probe and, finally, photoactivation was performed for 40 seconds. Next, the other veneers were also cemented in pairs **(Figure 3).**

Prior to the finishing and polishing stage, phonetic tests were carried out to observe the lip seal. Next, all interferences were diagnosed, occlusal adjustments were made, and measurements were taken. Finishing and polishing were performed using abrasive erasers. The final aspects of the case can be observed in **Figure 4.**

A residual diastema of 0.5 mm could be observed and its maintenance was necessary to preserve the proportionality between the teeth. In this way the central incisors did not get bigger, generating a disharmony of the smile.

DISCUSSION

Apart from functional and phonetic impairments, the changes in color, structural forms, and position caused by developmental pathologies or iatrogenic factors can result in important aesthetic issues for patients.[1] Diastemas have been defined as spaces larger than 0.5mm between the nearest surfaces of adjacent teeth and are a common clinical problem. As observed in the case presented, the patient exhibited generalized diastemas in the upper and lower front teeth, which caused enormous psychological and social discomfort.

In treatments requiring a multidisciplinary approach, communication between specialties is essential for achieving better aesthetic results, particularly in the anterior region of the maxilla. Combined treatments based on a correct diagnosis and an adequate treatment decision aid in the planning of a sequence of therapeutic procedures and constitute the best way to respond to these cases.[7] When these efforts are combined, the functional and aesthetic results are greatly reinforced.[8] Thus, a multidisciplinary treatment related to the one presented in this case is essential for immediate and long-lasting success.

In the present case, the orthodontic treatment enabled pre-restoration alignment, which allowed for both a better aesthetic approach during the subsequent restoration and harmonic teeth repositioning in relation to the adjacent teeth, the arch and the face, thus creating stable and functional occlusion. Next, periodontal surgery restored the aesthetic gum line by repositioning the zeniths and the gingival contour. After the teeth were repositioned and the gingival contour was corrected, the aesthetic of the upper teeth was successfully restored through restoration techniques, with minimal preparation and with the preservation of dental structure in such a way that pulp damage was avoided. These outcomes were achieved with minimal gingival trauma around the restored teeth.[8]

Direct composite resin veneers and laminated composite or ceramic veneers can be used for non-invasive or minimally invasive esthetic treatments.[9,10] The advances of adhesive technologies have made a variety of restorations possible through the use of more conservative techniques. When the color of the substrate is acceptable, very thin veneers (0.3-0.7 mm) can be used.[5] The reasons to choose prefabricated composite resin veneers in the case presented were that this treatment is minimally invasive, fast, and low cost, and also provides substantial aesthetic benefits. They are also extremely thin, pre-shaped, available in different sizes and prepared with pre-polarized hybrid composite resin of high durability.[6] They can be repaired, adjusted and cemented onto the tooth using direct hybrid composite resin. These materials are available in different colors and opacities to match enamel translucency and can therefore closely mimic the appearance of a natural tooth.[11]

A residual diastema can be observed in the result of the treatment presented. This was necessary to maintain the aspect heigth X width of the veneers, and in this way preserve the harmony between the elements. However, this technique does not replace conventional customized ceramic veneers, but it is an alternative that is available to clinicians. It has the advantage of being finalized in only one session without the need for impressions or lab work. In addition, restorations can be personalized (color and shape) through the use of cosmetic contours and reconstruction through the addition of more composite resin and/or dental drilling, as in the case presented, in order to achieve an esthetically pleasing result.[11]

CONCLUSION

The combination of orthodontic treatment, periodontal surgery and the use of prefabricated composite veneers constitute an excellent option for treating teeth with multiple diastemas and resolved the patient's issues in a minimally invasive and easy way. In addition, repairs can be made at any time during or after their application. There are limitations to their use, but with good planning and correct indication, the case can be resolved successfully.

REFERENCES

1.Wolff D, Kraus T, Schach C, Pritsch M, Mente J, Staehle HJ, Ding P. Recontouring teeth and closing diastemas with direct composite buildups: A clinical evaluation of survival and quality parameters. J Dent 2010;38(12):1001-9 Doi:10.1016 / j.jdent.2010.08.017

2.John R, Richard D. Esthetic and Cosmetic Dentistry for Modern Dental Practice: Update 2011 Preface. Calamia JR, Trushkowsky RD, Wolff MS. Dent Clin North Am. 2011;55(2): xiii-xiv. Doi 10.1016/j.cden.2011.03.002

3.Sharma PK, Sharma P. Dental Smile Esthetics: The Assement and Creation of the Ideal Smile. Semin Ortod 2012; 3 (3): 193-201. Doi 10.1053/j.sodo.2012.04.004

4.Kaul A, Singh G. Restoring esthetics using adjuntive orthodontics - Case Reports. J Pierre Fauchard Acad. (India Section) 2013; 27:67-71. Doi 10.1016/j.jpfa.2013.08.002

5.Gresnigt M, Ozcan M. Esthetis Rehabilitation of Anterior Teeth with Porcelain Laminates and Sectional Veneers. J Can Dent Assoc. 2011;77b143.

6.Gomes G, Perdigão J. Prefabricated Composite Resin Veneers – A Clinical Review. J Esthet Restor Dent. 2014;26(5):302-13. Doi: 10.1111/jerd.12114

7.Nagalakshmi S, Sathish R, Priya K, Dhayanithi D. Changes in quality of life during orthodontic correction of midline diastema. J Pharm Bioallied Sci. 2014;6(1):S162-4. doi: 10.4103/ 0975-7406.137435

8.Moon JE, Kim SH, Han JS, Yang JH, Lee JB. Esthetic restorations of maxillary anterior teeth with orthodontic treatment and porcelain laminate veneers: a case report. J Adv Prosthodont. 2010;2(2):61-3. doi:10.4047/jap.2010.2.2.61

9.Korkut B, Yanikoglu F, Gunday M. Direct composite laminate veneers: Three Case Reports. J Dent Res Dent Clin Dent Prospects. 2013;7(2):105-11. doi:10.5681/joddd.2013.019

10.Stawarczyk B, Keul C, Beuer F, Roos M, Schmidlin PR. Tensile bond stregth of veneering resins to PEEK: Impact of diferent adhesives. Dent Mater J. 2013;32(3):441-8. Doi10.4012/ dmj.2013-011

11.Dietschi D, Devigus A. Prefabricated Composited Veneers: Historical Perspective, Indications and Clinical application. Eur J Esthet Dent 2011;6(2):178-87.