ORAL MANIFESTATIONS AND DENTAL APPROACH IN PEDIATRIC PATIENT WITH LAMELLAR CONGENITAL ICHTHYOSIS: 36-MONTH FOLLOW-UP

Giselle Emilãine da Silva **Reis**[1*], Gisele **Marchetti**[1], Bruna Letícia Vessoni Menoncin **Casatti**[1], João Rodrigo **Sarot**[2], José Vitor Nogara Borges de **Menezes**[1], Yasmine Mendes **Pupo**[2]

[1]Department of Stomatology, Universidade Federal do Paraná - UFPR, Curitiba, Paraná, Brazil.
[2]Department of Restorative Dentistry, Universidade Federal do Paraná - UFPR, Curitiba, Paraná, Brazil.

Palavras-chave: Síndromes congênitas. Anestesia geral. Odontopediatria.

RESUMO

Introdução: A ictiose lamelar é uma doença congênita autossômica recessiva que causa ressecamento da pele na região peribucal, o que leva à dor durante a higiene dental, por isso a alimentação dos pacientes com essa doença tende a ser pastosa, podendo levar a problemas bucais. Suspeita-se que a hipossalivação possa ser uma manifestação oral da ictiose lamelar, podendo influenciar na incidência de lesões cariosas. **Objetivo**: Descrever o tratamento de uma paciente do sexo feminino, inicialmente com 2 anos de idade, diagnosticada com ictiose lamelar (IL), que procurou atendimento odontológico com queixa de dor dentária, dificuldade na alimentação e baixo peso. **Relato do caso**: Tratamento restaurador atraumático, exodontias e aplicação tópica de verniz fluoretado foram realizados na paciente, além de posterior instalação de mantenedor de espaço, o qual também funcionou como reabilitador estético. **Conclusão**: Este estudo reforça a necessidade do acompanhamento do paciente com IL pelo cirurgião dentista desde o nascimento do primeiro dente, pois secura da pele perioral e hipossalivação são condições relatadas em indivíduos com ictiose lamelar. Essas condições podem afetar a higiene bucal e a frequência de lesões cariosas.

Keywords: Congenital syndromes. General anesthesia. Pediatric dentistry.

ABSTRACT

Introduction: Lamellar ichthyosis is an autosomal recessive congenital disease that causes dryness of the skin in the perioral region, which leads to pain during dental hygiene. Thus, the diet of patients with this disease tends to be pasty, which can lead to oral problems. Hyposalivation is suspected to be an oral manifestation of lamellar ichthyosis and may exert an influence on the incidence of carious lesions. **Objective**: Describe the treatment of a female patient diagnosed with lamellar ichthyosis who sought dental care initially when two years of age with complaints of dental pain, feeding difficulties and low weight. **Case report**: Atraumatic restorative treatment, extractions and topical application of fluoride varnish were performed in the patient, aesthetic of posterior installation of space, which also functioned as a rehabilitator. **Conclusion**: This study reinforces the need for the follow-up of the patient with LI by the dental surgeon since the birth of the first tooth, as dryness of the perioral skin and hyposalivation are conditions reported in individuals with lamellar ichthyosis. These conditions can affect oral hygiene and the frequency of carious lesions.

Submitted: June 07, 2022
Modification: August 23, 2022
Accepted: August 26, 2022

***Correspondece to**:
Giselle Emilãine da Silva Reis
Address: Avenida Prefeito Lothário Meissner, 632, Jardim Botânico, Curitiba, Paraná, Brazil. Zip Code: 80210-170
Telephone number: +55 (41) 98826-3595
E-mail: gisellereis_86@hotmail.com

INTRODUCTION

Ichthyosis is part of a heterogeneous group of Mendelian cornification disorders that affect the entire skin and are characterized by hyperkeratosis and desquamation.[1] This is a rare disease, with an incidence of 1:300,000 live births and equal distribution between the sexes.[2]

Lamellar-type ichthyosis (LI) is classified as non-syndromic congenital recessive autosomal, with a clear correlation between genotype and phenotype.[2] It is the result of missense mutations in the *ABCA12* gene, which carries a protein that appears to be essential for normal skin development. Mutations in other genes are also involved in this form of ichthyosis presentation, such as *TGM-1*, which encodes the synthesis of *transglutaminase-1 enzyme*,[2,3] *ALOXE3* and *ALIX12B*, which are responsible for the expression of epidermal *lipoxygenase-3* and *12-lipoxygenase* involved in essential fatty acid metabolism,[2-4] and the *NIPAL4* gene, which encodes *ichthyin transmembrane* receptor expression. Mutations in these genes have consequences for the lipid metabolism of the epidermis.[2,4]

The main clinical manifestations appear from birth, such as low weight, collodion membrane, ectropion, eclabium, generalized thick scales, erythema, painful cracks, especially in areas of flexion, alopecia, congenital hypoplasia of the auricular and nasal cartilages, growth delays and short stature.[2] Due to the rarity of the condition, however, the oral and dental manifestations of LI are not well established in the literature.

The purpose of this case report is to present oral manifestations seen in a child with lamellar ichthyosis. We also discuss the clinical approach to dental treatment for patients with this condition and demonstrate the importance of follow-up for maintaining oral health.

CASE REPORT

A 2-year-old young girl with LI visited the dental clinic of the Federal University of Parana with a major complaint of intense pain in the dental origin. This report was conducted with a statement of informed consent signed by the patient's guardian for scientific publication of this case. During the taking of the patient history, the caregivers reported that the patient had difficulty feeding due to pain, difficulty with oral hygiene, a cariogenic diet and low salivary flow. The medical history included malnutrition and low weight.

The extraoral examination revealed fish scales, cicatricial alopecia, atrial cartilage hypoplasia, inverted eyelid appearance and hypohidrosis (Figure 1). The intraoral examination revealed that the majority of teeth were affected by caries. The treatment plan sought to address the patient in an integral way. The first interventions were permeated with playful management, guidelines and preventive care. Due to the patient's young age, it was not possible to perform panoramic radiography, as she exhibited poor behavior and was not able to follow the protocols for the imaging exam. However, it was possible to obtain periapical radiographs.

Due to the occurrence of very extensive caries, extraction was performed of teeth 51, 52, 54, 61, 62 and 64. As teeth 65, 74, 75, 84 and 85 were affected by mid-occlusal carious lesions, we opted for atraumatic restorative treatment (ART). We also observed active white spot lesions on teeth 72 and 73, for which the treatment instituted was the use of fluoride varnish.

Due to behavior management problems related mainly to the patient's very young age, the decision was made to perform all procedures under general anesthesia with the support of an anesthesiologist and constant monitoring. After general anesthesia, intubation and stabilization, a regional blockade technique was performed with mepivacaine 2% and adrenaline. The proposed extractions were performed. Restorative procedures were performed with glass ionomer cement (Vitremer, 3M Espe®, SP, Brazil). Lastly, fluoride varnish (Duraphat®, São Paulo, Brazil) was applied to all teeth. The procedures lasted approximately 60 minutes (Figure 2).

Monthly follow-up was conducted with the patient. Figure 3 shows the results maintained six months after surgery. After this period, a follow-up protocol was established every six months to maintain oral health. After three years, the decision was made to perform space maintenance, which would also serve as an aesthetic rehabilitator, replacing the previously extracted teeth. It was necessary to perform resin addition in the buccal vestibule of canine teeth due to their expulsion and to provide greater stability to the space maintainer. We waited for this period to install the space maintainer so that there was no harm to craniofacial growth and due to the greater maturity that the patient exhibited when using and caring for the appliance (Figure 4). Currently, the patient continues to return periodically to ensure the preservation of the acquired oral hygiene habits and perform oral health prevention.



***Figure 1**: A) Atrial Cartilage Hypoplasia. B) Inverted eyelid appearance. C) Hypohidrosis.*

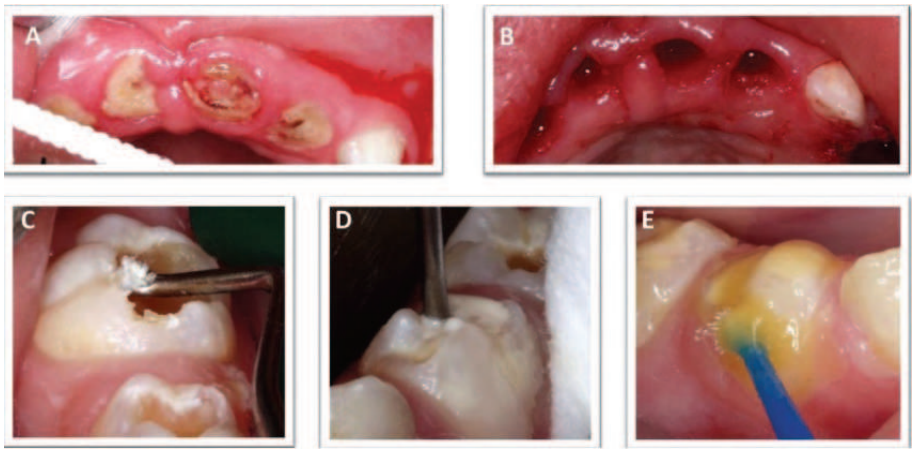

***Figure 2**: A) Initial aspect. B) Extraction of teeth 51, 61, 62, 52, 54 and 64. C) ART on tooth 85. D) Restorative procedures performed with glass ionomer cement on tooth 74. E) Fluoride varnish applied to all teeth.*



***Figure 3**: Intraoral postoperative aspect after six months of follow-up.*



***Figure 4**: A) Intraoral appearance after installation of the space-maintaining and aesthetic appliance. B) Occlusal aspect with use of appliance. C) Final picture of patient.*

DISCUSSION

LI is a skin disease characterized by thick, plaque-like scales distributed throughout the body in addition to itching, pain, inflammation and alopecia.[5] Cutaneous manifestations in visible parts of the body of patients with LI can compromise their quality of life, since it can generate shame or even discrimination, which can lead to mental health disorders.[6] Moreover, LI has autosomal recessive inheritance and its manifestations can lead to difficulties with personal hygiene, oral hygiene and feeding.[7] These characteristics were found in our patient, who had feeding difficulties with consequent low body weight caused by severe dental involvement.

Dental involvement was correlated not only with the parents' difficulty in performing oral hygiene, but also with the child's considerable cariogenic dietary habits and low salivary flow reported by the parents. The transition diet that corresponds to the first three years of the child's life is a peculiar phase, in which the child progresses from a diet restricted to breast milk or infant formula to a variety of textures and family foods.[8] At this stage, dietary and oral hygiene counseling is essential to achieving positive results for the oral clinical status of the child.

A previous case report hypothesized that salivary flow was low in individuals with lamellar ichthyosis due to inadequate transglutaminase (TGM) function.[9] In addition to being related to salivary flow, TGM is also present on the surface of oral mucosal cells and is capable of cross-linking acquired pellicle proteins.[10] Given this, inadequate TGM function would be an important oral manifestation of this disease, increasing the susceptibility of affected patients to developing dental caries.[9] Our case report lends strength to this notion. Although this characteristic was observed in the study cited and the current report, we cannot confirm this correlation. It is necessary to produce genetic studies with a considerable sample size.

Good behavior during pediatric dental care is not always achieved, especially in cases of patients with special needs. General anesthesia is an option for dental treatment in such patients. In the case reported, in addition to the fact that the child was only two years of age, the medical history and clinical characteristics of the disease culminated in the decision for general sedation to perform the procedures. The use of general anesthesia is considered safe and has been widely described as a useful modality for the treatment of patients with special needs.[11]

The proposed dental protocols (extractions and ART) were based on the patient's clinical needs and indications. The early loss of primary teeth may directly interfere with the balance of the patient's stomatognathic system. Therefore, we opted for the installation of a space maintainer appliance, which rehabilitated function and aesthetics and saves space for the proper eruption of the permanent dentition. ART is a minimal intervention procedure that employs high-viscosity glass ionomer cement, which is biocompatible, releases fluoride into adjacent dental structures, has the ability to recharge fluoride ions, has a favorable coefficient of thermal expansion and has longevity similar to conventional treatment.[12]

The primary dentition is very important to guide the eruption of the permanent dentition.[13] The exfoliation of primary teeth and the eruption of permanent teeth is a normal physiological process.[14] When this process is interrupted due to the premature loss of primary teeth, the mesial migration of teeth can occur, resulting in the loss of arch length, which can manifest as malocclusion in the permanent dentition in the form of the crowding and impaction.[15] Thus, when the premature loss of primary teeth occurs, space maintainers are a good treatment option. Moreover, the patient needs to be a certain age due to the

degree of understanding required to use a removable appliance, as in the case presented here.

CONCLUSION

This study underscores the need for dentists to monitor patients with LI from the eruption of the first tooth, because perioral skin dryness and hyposalivation are conditions reported in individuals with lamellar ichthyosis. These conditions can impact oral hygiene and the frequency of carious lesions. Thus, it is important for caregivers to be instructed early about oral hygiene and a cariogenic diet. Moreover, poor oral health has serious consequences for systemic health, as in the case described above, in which the patient had difficulty eating due to dental pain and consequent low body weight, which was quickly restored after treatment.

ACKNOWLEDGMENT

Dr. Oscar Vilmar Schulz Junior for the medical care provided and the general anesthesia that enabled dental care in our patient.

REFERENCES

1. Keerthi KN, Kodhandram GS. Oral manifestations of lamellar ichthyosis: A rare case report. Indian J Paediatr Dermatol. 2016;17(4):283-6. doi: 10.4103/2319-7250.184428.
2. Oji V, Tadini G, Akiyama M, Blanchet BC, Bodemer C, Bourrat E, et al. Revised nomenclature and classification of inherited ichthyoses: results of the First Ichthyosis Consensus Conference in Sorèze. J Am Acad Dermatol. 2010; 63(4):607-41. doi: 10.1016/j.jaad.2009.11.020.
3. Oji V, Hautier JM, Ahvazi B, Hausser I, Aufenvenne K, Walker T, et al. Bathing suit ichthyosis is caused by transglutaminase-1 deficiency: evidence for a temperature-sensitive phenotype. Hum Mol Genet. 2006;15(21):3083-97. doi: 10.1093/hmg/ddl249.
4. Rook A, Wilkinson D, Ebling J. Rook's textbook of dermatology. 8th ed. West Sussex: Blackwell Scientific Publications; 2010.
5. Cortés H, Del Prado-Audelo ML, Urbán-Morlán Z, Alcalá-Alcalá S, González-Torres M, Reyes-Hernández OD, et al. Pharmacological treatments for cutaneous manifestations of inherited ichthyoses. Arch Dermatol Res. 2020;312:237–48. doi: 10.1007/s00403-019-01994-x.
6. Hannig C, Spitzmüller B, Miller M, Hellwig E, Hannig M. Intrinsic enzymatic crosslinking and maturation of the in situ pellicle. Arch Oral Biol. 2008;53(5):416-22. doi: 10.1016/j.archoralbio.2007.12.003.
7. Dreyfus I, Bourrat E, Maruani A, Bessis D, C Chiaverini, Vabres P, et al. Factors associated with impaired quality of life in adult patients suffering from ichthyosis. Acta Derm Venereol. 2014;94(3):344-6. doi: 10.2340/00015555-1710.
8. Devenish G, Mukhtar A, Begley A, Do L, Scott J. Development and relative validity of a food frequency questionnaire to assess intakes of total and free sugars in australian toddlers. Int J Environ Res Public Health. 2017;14:e1361. doi: 10.3390/ijerph14111361.
9. Ramar K, Annamalai S, Hariharavel VP, Aravindhan R, Ganesh C, Ieshwaryah K. Oral manifestation of autosomal recessive congenital ichthyosis in a 2-year-old patient. Case Rep Dent. 2014;2014:483293. doi: 10.1155/2014/483293.
10. Hannig C, Spitzmuller B, Miller M, Hellwig E, Hannig M. Intrinsic enzymatic crosslinking and maturation of the in situ pellicle. Arch Oral Biol. 2008;53(5):416–22. doi: 10.1016/j.archoralbio.2007.12.003.
11. Lim MAWT, Borromeo GL. The use of general anesthesia to facilitate dental treatment in adult patients with special needs. J Dent Anesth Pain Med. 2017;17(2):91-103. doi: 10.17245/jdapm.2017.17.2.91.
12. Raggio DP, Hesse D, Lenzi TL, Guglielmi CA, Braga MM. Is Atraumatic restorative treatment an option for restoring occlusoproximal caries lesions in primary teeth? A systematic review and meta-analysis. Int J Paediatr Dent. 2013; 23(6):435-43. doi: 10.1111/ipd.12013.
13. Barberia E, Lucavechi T. Free end Space Maintainers: Design Utilisation and Advantages. J Clin Pediatr Dent. 2006;31:(1)5–8. doi: 10.17796/jcpd.31.1.p87112173240x80m.
14. Rao AK, Sarkar S. Changes in the arch length following premature loss of deciduous molars. J Indian Soc Pedod Prev Dent. 1999;17(1):28–32. PMID: 10863487.
15. Goenka P, Sarawgi A, Marwah N, Gumber P, Dutta S. Simple fixed functional space maintainer. Int J Clin Pediatr Dent. 2014;7(3):225-8. doi: 10.5005/jp-journals-10005-1272.