EROSIVE TOOTH WEAR IN AN ASTHMATIC CHILD: A CASE REPORT

Nicole Marchioro dos **Santos**[1*], Ingrid de Lima **Flores**[1], Adriela Azevedo Souza **Mariath**[1], Jonas Almeida **Rodrigues**[1]

[1] Department of Surgery and Orthopedics, School of Dentistry, Federal University of Rio Grande do Sul, Porto Alegre, RS, Brazil

Palavras-chave: Desgaste Erosivo Dentário. Criança. Asma.

Resumo

Introdução: O desgaste dentário erosivo é definido como um processo químico mecânico que resulta em uma perda cumulativa de tecido duro, sem o envolvimento de bactérias. Esse processo pode ocorrer em dentes permanentes e decíduos, podendo atingir o tecido dentinário. Pacientes que relatam doenças crônicas, como alergia respiratória e asma brônquica ou doenças agudas recorrentes como amigdalite, rinite alérgica, sinusite e otite, comumente usam medicamentos por períodos prolongados, portanto, mais atenção deve ser dada ao aspecto odontológico, uma vez que os medicamentos podem causar efeitos indesejáveis. **Objetivo**: Este trabalho tem como objetivo relatar e discutir um caso clínico de um paciente de nove anos, asmático, caucasiano, sexo masculino, que faz uso contínuo de medicamentos anti-asmáticos e desenvolveu o desgate erosivo dentário. **Relato do caso**: De acordo com as necessidades do paciente foi realizado instruções de higiene oral (uso de dentifrício contendo fluoreto estanhoso, fio dental e aplicações tópicas de flúor). Uso diário de enxaguatório bucal contendo 0,05% de fluoreto de sódio também foi recomendado e orientações dietéticas foram realizadas. **Conclusão**: O diagnóstico precoce e preciso das lesões de desgaste erosivo e o reconhecimento dos fatores etiológicos específicos permite o profissional elaborar um programa individualizado de prevenção e controle da progressão do desgaste erosivo dentário.

Keywords: Erosive tooth wear. Child. Asthma.

Abstract

Introduction: Erosive tooth wear (ETW) is defined as a mechanical chemical process that results in a cumulative loss of hard tissue without the involvement of bacteria. This process may occur in permanent and deciduous teeth and may also reach the dentin tissue. Patients who report chronic diseases, such as respiratory allergy and bronchial asthma, or recurrent acute diseases, such as tonsillitis, allergic rhinitis, sinusitis, and otitis, commonly use drugs for prolonged periods; thus, more attention should be given to the dental aspects since the drugs may cause undesirable effects. **Objective**: This paper aims to report and discuss a clinical case of a nine-year-old, male, Caucasian, asthmatic patient who continually uses anti-asthmatic medications and has developed ETW. **Case report**: According to the patient's needs, oral hygiene instructions (use of fluoride stannous dentifrice, dental floss, and topical fluoride applications), daily use of mouthwash solution containing 0.05% sodium fluoride, and dietary guidance were recommended. **Conclusion**: An early and accurate diagnosis of ETW lesions and recognition of specific etiological factors allow the professional to elaborate an individualized prevention and control program for ETW progression.

Submitted: March 23, 2018
Modification: April 26, 2018
Accepted: May 12, 2018

***Correspondence to:**
Nicole Marchioro dos Santos
Address: Ramiro Barcelos St 2492, CEP: 90035-003, Porto Alegre, RS, Brazil
Telephone number: +55 51 33085023
E-mail: nicolemarchioros@googlemail.com

INTRODUCTION

Erosive toothwear (ETW) is defined as a chemical-mechanical process that results in the cumulative loss of hard dental tissue without the involvement of bacteria.[1] In addition, ETW can cause dentin sensitivity, loss of vertical dimension, pulp exposure, and aesthetic compromise when anterior teeth are involved.[2] Due to its multifactorial causes, its differential

diagnosis presupposes that, besides physical examination, anamnesis and dietary habits are also considered.[1]

Epidemiological studies have suggested that either the prevalence of ETW is increasing or there is an increased awareness of its occurrence, especially in young adults and adolescents.[3] Currently, ETW is considered a topic of increased interest and concern in daily clinical practice, and its prevalence has varied from 4% to 82% in adults and 10% to 80% in children.[4] Changes in the population's lifestyle, characterized by increased consumption of acidic foods and beverages, are related to the extrinsic factors.[5,6] Some drugs, due to their low pH, represent another important extrinsic etiological factor.[5]

There are systemic diseases that could be part of the risk factors for ETW. Among these, bronchial asthma would make the carrier of the disease more susceptible to the development of erosive lesions.[7] However, this assumption has not yet been confirmed in the literature.[6] The prevalence of asthma in the world population varies from 1% to 20%,[8] and this prevalence is 20% in Brazil.[9] In terms of health issues associated with bronchial asthma, the growing interest in studying this association stems from the fact that asthma is an important global public health problem.[9]

Anti-asthma drugs,[6] such as salbutamol sulfate and ferric supplement,[5,10] and antiallergics, such as brompheniramine maleate (Dimetapp®) and loratadine (Claritin®),[10] have erosive potential. Long-term use of acid medications in the oral cavity of children with chronic disorders causes concern,[10] mainly due to the frequency of ingestion (3 to 4 times a day) and nocturnal use because it is during this period that the protective effects of saliva are reduced. Another problem is the high viscosity of the drug and the side effect of decreasing salivary flow, as these may contribute to the development of ETW.[11] As previous mentioned in the literature, these drugs are effective and have great erosive potential for the teeth, especially when used for the treatment of respiratory diseases, such as antiallergics and bronchodilators, as well as drugs for nutrition and treatment of anemia.[2] Due to this, the pediatric drugs of chronic use were evaluated by some studies regarding the erosive effects of these drugs on deciduous tooth enamel.

Gastroesophageal reflux (GERD) and salivary changes (reduced buffer capacity and salivary flow) are reported as manifestations indirectly associated with bronchial asthma and can be considered risk factors for ETW.[7] Patients with recurrent asthma make prolonged use of medications containing high sucrose concentrations with low pH, and these factors can also lead to ETW.[5] However, little information is known on the association between ETW and bronchial asthma.[6]

Etiological factors should be investigated (intrinsic and extrinsic). Intrinsic factors are an important cause of ETW (among them GERD should be given special attention with referral to a specialist). Extrinsic factors are associated with an acidic diet, when necessary diet advice should be given. All these are associated with dental care (protective dental products, such as topical fluoride, toothpastes, or mouth rinses). In more advanced lesions, restorative procedures should be performed.[1] Therefore, the aim of this case report is to describe the occurrence of ETW of an asthmatic pediatric patient and their respective treatment plan.

CASE REPORT

A nine-year-old Caucasian male visited our pediatric clinic at the Dentistry Faculty, Federal University of Rio Grande do Sul, for routine consultations. Once his mother had noted severe tooth wear, the informed consent was signed, and the guardians allowed the child to be evaluated and treated. During anamnesis, the mother reported the patient had no complaints and that he had used asthma medication since his first months of life. According to the mother's report, the patient had already used the following medications, according to the medical advice and to the crisis period: Aerolin® (salbutamol sulphate), Avamys® (fluticasone furoate), Seretide® (salmeterol xinafoate, fluticasone propionate), Alenia® (formoterol fumarate dihydrate, budesonide), amoxicillin, azithromycin, and prednisolone. In addition, between the ages of 2 and 4 years, the patient made continuous use of Aerolin® spray (salbutamol sulphate) as a preventive method. Nowadays, he uses Avamys® (spray), Seretide® (aerosol inhalation suspension), and prednisolone (tablets). The mother also reported that occasionally the child has heartburn and that she herself does treatment for chronic gastritis.

Regarding the routine of brushing, the mother reported that the patient performs oral hygiene three times a day using fluoride dentifrice without using dental floss. Regarding the diet, a 24-hour reminder interview was conducted, and his mother reported that the patient ingested soft drinks daily after the main meals.

At the clinical examination, a visible plaque index (VPI) of 28.84% and gingival bleeding index (GBI) of 11.95% were recorded. Erosive wear occurred on the palatine faces of the teeth (53, 12, 11, 21, 22, and 63; Figures 1 and 2), occlusal surfaces of the teeth (55, 65, 74, and 75; Figures 1 and 3), incisal teeth (53, 63, 73, and 83; Figure 1), and occlusal surfaces of the teeth (84 and 85; Figure 4). The Basic Erosive Wear Examination (BEWE) index was 3, which indicates hard tissue loss, affecting more than 50% of the surface area.[12] No dentin sensitivity, bruxism, or loss of vertical dimension was detected.

Clinical planning was performed according to the



Figure 1: *Front view, mixed dentition, upper and lower arches.*

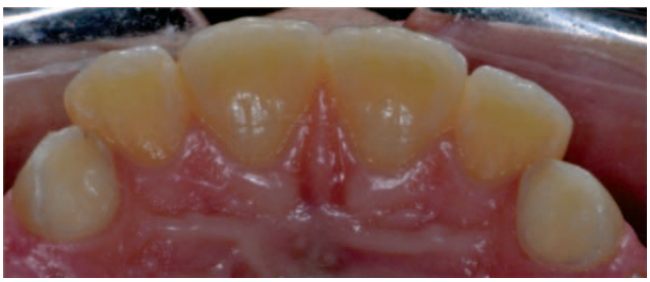

Figure 2: *Erosive tooth wear (BEWE 3) on palatal surface (second sextant).*

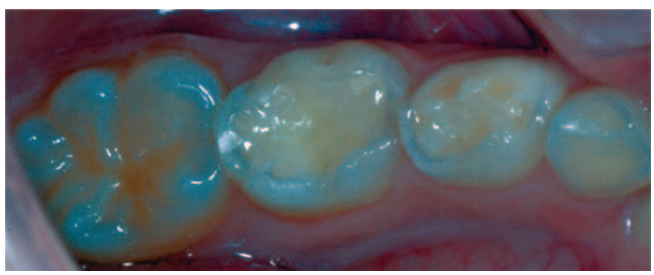

Figure 3: *Erosive wear (BEWE 3) on incisal and occlusal surfaces (third and fourth sextants).*

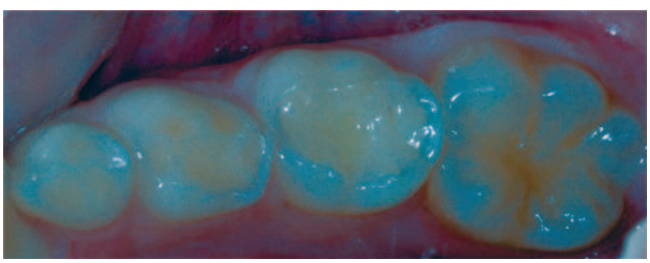

Figure 4: *Erosive wear (BEWE 3) on incisal and occlusal surfaces (fifth and sixth sextants).*

patient's needs and included oral hygiene instructions guiding the use of dentifrice containing stannous fluoride, dental floss, and four topical neutral fluoride applications as well as the daily use of mouthwash solution containing 0.05% sodium fluoride. In addition, dietary guidance was provided (decrease the consumption of soft drinks, avoid the consumption of acidic fruits, and increase water intake). After using asthma medications, the patient was instructed to ingest water and, if possible, chew sugarless gum to increase salivary flow. The patient was referred to a gastroenterologist to investigate the possible association of asthma and ETW with gastric disorders.

DISCUSSION

As described in the case report, the patient is asthmatic. According to the literature, there is a hypothesis that asthmatic patients may present a higher risk of ETW development.[6] For chronic patients, more attention should be paid to dental conditions since the effects caused by medications may be undesirable.[2]

The presence of ETW on the occlusal surfaces (teeth 55, 65, 74, 75, 84, and 85) and on the incisal surfaces (teeth 53, 63, 73, and 83) was verified during the clinical examination using the BEWE index.[12] There is evidence that, due to structural differences, deciduous teeth are more prone to ETW than permanent teeth, as they present a thinner enamel layer, less mineralization, and greater permeability, which could explain the faster progression of ETW in the deciduous dentition.[4]

Considering the type of fluoride compound, NaF, SnF_2, and AmF among others have been studied. There is evidence showing that the use of Sn-containing fluoride seems to provide the best approach for effective prevention of ETW when compared with sodium and amine fluorides.[13] Dentifrices containing stannous fluoride have the potential for reducing the course of ETW.[1] Moreover, Sn-containing fluoride has been suggested because of its mechanism of action, in which metal-rich surface precipitates on the affected enamel.[13] Therefore, stannous fluoride was recommended for the patient.

Extrinsic dietary acids are the cause of a large proportion of ETW.[1] The erosive potential of acidic beverages can include pH and buffering capacity. The greater the buffering capacity of the drink, the longer it will take the saliva to neutralize the acid.[4] The erosive potential of acidic foods and beverages is also related to their physicochemical properties, such as temperature, titratable acidity (total acid level), calcium content, phosphate, type of acid, and fluoride, which alone or combined influence ETW.[14] Phosphoric acid, citric acid, and sodium citrate are commonly found in sports

and soft drinks. Both phosphoric acid and citric acid are triprotic acids that can release up to three hydrogen ions in solution, while phosphate and citrate can sequester calcium ions, though they exhibit erosive potential.[4] When the consumption of fruits and soft drinks is observed at high frequency (one or more times per day), there is a predisposition to develop wear on the palatine surface of the anterior teeth.[1,4] In the present case, ETW may have been potentiated due to the intake of soft drinks.

The professional must recognize the acidic substances responsible for the degradation of the dental structure in the diet of each person and should guide the patient regarding consumption in an intelligent way. This can be implemented by suggesting the reduction of the frequency of consumption or the restriction of consumption to main meals. It is speculated that acidic drink consumption concomitantly with meals would lead to dilution of the erosive effect, reducing damage to the dental substrate.

Regarding the erosive effect of long-term pediatric medicinal products on deciduous enamel, care should be taken to indicate medications to assist in the prevention and treatment of ETW. Oral liquid medicines, sprays, and tablets are usually prescribed for children as the treatment of choice for a short period; for chronic diseases, however, these are consumed daily for very long periods. Some authors argue that certain antiasthmatic drugs have the potential to cause GERD, as they cause relaxation of the smooth muscle, which could affect the lower esophageal sphincter.[6] As this patient presented heartburn, GERD could be also one of the causes of ETW. In relation to the frequency and quantity of the drug use, as in this case, patients that utilize more than one drug have a greater chance of ETW since many children's drugs have low pH values and varying titratable acidity.[15] Powdered versions of the bronchodilator drugs, such as beclomethasone, dipropionate, fluticasone, and terbutaline salmeterol sulfate, have a pH below 5.5 and are more acidic than their aerosolized version; therefore, asthmatic patients who use the powder would be at risk of ETW,[16] as is the case of the patient in the present report using Avamys®, Seretide®, and prednisolone.

The main strategy of prevention and lesion control is to eliminate etiological agents. It is essential to be aware and provide guidance on the causes of ETW. In addition, with the progression of tooth structure loss, pain sensitivity may occur.[2] Therefore, strategies are suggested that provide the following:

- systematic condition treatment,
- reduction of frequency and severity of erosive challenges,
- remineralization and increase of dental surface resistance,
- neutralization of the acids present in the buccal fluid,
- enhancement of salivary defense mechanisms,
- mechanical protection of the dental element, and
- reduction of the influence of other associated wear phenomena.

Other protocols that the dental surgeon should follow are to encourage the following:

- drinking water after using medications and after main meals,
- limiting consumption of acid and sweet substances,
- using sugar-free chewing gum to stimulate salivary flow, and
- using a fluoridated mouthwash daily as prescribed by the dental surgeon.[17]

Related to oral products, there are studies suggesting that some mineral is dissolved from the enamel surface after topical application of acidic oral products with high fluoride content, which would increase the local pH and lead to fluoridated hydroxyapatite reprecipitation. Furthermore, the organic pellicle and the saliva with its buffering capacity lead to an additional protective effect. Highly concentrated weakly acidic fluoride applications are capable of increasing abrasion resistance and decreasing the process of ETW on enamel and dentin.[11]

An early and accurate diagnosis of ETW lesions associated with the recognition of specific etiological factors and the modulating aspects provide support for the professional to elaborate an individualized prevention and control program for ETW progression.

REFERENCES

1. Carvalho TS, Colon P, Ganss C, Huysmans MC, Lussi A, Schluerter N, et al. Consensus report of the European Federation of Conservative Dentistry: erosive tooth wear – diagnosis and management. Clin Oral Investig. 2015 Sep;19(7):1557-61.
2. Nunn JH, Ng SK, Sharkey I, Coulthard M. The dental implications of chronic use of acidic medicines in medically compromised children. Pharm World Sci. 2001 Jun;23(3):118-9.
3. Holbrook WP, Furuholm J, Gudmundsson K, Theodórs A, Meurman JH. Gastric reflux is a significant causative factor of tooth erosion. J Dent Res. 2009 May;88(5):422-6.
4. Taji S, Seow WK. A literature review of dental erosion in children. Australian Dent J. 2010;55:358-67.
5. Zero DT. Etiology of dental erosion – extrinsic factors. Eur J Oral Sci. 1996; 104(2(Pt 2)):162-77.
6. Shaw L, al-Dlaigan YH, Smith A. Childhood asthma and dental erosion. ASDC J Dent Child. 2000 Mar-Apr;67(2):102-6.
7. Sivasithamparam K, Young WG, Jirattanasopa V, Priest J,

Khan F, Harbrow D, et al. Dental erosion in asthma: a case-control study from south east Queensland. Aust Dent J. 2002 Dec;47(4):298-303.
8. Bateman ED, Hurd PJ, Barnes J, Bousquet JM, Drazen JM, FitzGerald P, et al. Global Strategy for asthma management and prevention: GINA executive summary. Eur Respir J. 2018 Jan 31;51(2). [Epub ahead of print]
9. III Consenso Brasileiro No Manejo Da Asma. Capítulo I – Definição, epidemiologia, patologia e patogenia. Rev AMRIGS. 2002 Jul-dez 46(3,4):151-172.
10. Maguire A, Baqir W, Nunn JH. Are sugars-free medicines more erosive than sugars-containing medicines? An in vitro study of paediatric medicines with prolonged oral clearance used regularly and long-term by children. Int J Paediatr Dent. 2007 Jul;17(4):231-8.
11. Hellwig E, Lussi A. Oral hygiene products and acidic medicines. Monogr Oral Sci. 2006;20:112-8.
12. Lussi A. Dental erosion. Clinical diagnosis and case history taking. Eur J Oral Sci. 1996;104:191-8.
13. Magalhães AC, Wiegand A, Buzalaf MAR. Use of dentifrices to prevent tooth wear: harmful or helpful? Braz Oral Res. 2014 28(Spec Iss1):1-6.
14. Johansson AK, Sorvari R, Birkhead D, Meurman JH. Dental erosion in deciduous teeth – an in vivo and in vitro study. J Dent. 2001 Jul:29(5):333-40.
15. Costa CC, Almeida ICS, Costa LC FILHO. Erosive effect of antihistamine-containing syrup on primary enamel and its reduction by fluoride dentifrice. Int J Paediatr Dent. 2006 16:174-80.
16. Tredwin CJ, Scully C, Bagan-Sebastian JV. Drug-induced disorders of teeth. J Dent Res 2005 Jul;84(7):596-602.
17. Widmer RP. Oral health of children with respiratory diseases. Paediatr Respir Rev. 2010 Dec;11(4):226–32.