ORAL MANIFESTATIONS IN A BONE MARROW-TRANSPLANTED ADOLESCENT WITH SYSTEMIC SCLEROSIS: A CASE REPORT

Karla Lorene de França **Leite**[1*], Mariana Leonel **Martins**[1], Gabrielle **Carrozzino**[1], Kriss Mélani Sanga **Gárate**[1], Maysa Lannes **Duarte**[1], Michele Machado Lenzi da **Silva**[1], Gloria Fernanda Barbosa de Araújo **Castro**[1]

[1]Department of Pediatric Dentistry and Orthodontics, School of Dentistry, Universidade Federal do Rio de Janeiro - UFRJ, Rio de Janeiro, RJ, Brazil.

Palavras-chave: esclerose sistêmica. adolescentes. manifestação oral.

RESUMO

Objetivo: relatar as manifestações orofaciais em uma adolescente transplantada de medula óssea com esclerose sistêmica. **Relato do Caso**: uma adolescente de 12 anos foi encaminhada para um centro de referência em atendimento odontológico a pacientes com necessidades especiais com queixa de maloclusão dentária. Na anamnese, a cuidadora relatou diagnóstico de esclerose sistêmica ao nascimento e transplante de medula óssea para controle da doença aos 6 anos de idade. Paciente faz uso crônico de anti-hipertensivos e anti-inflamatórios e refere xerostomia e disfagia. Telangiectasias, atrofia facial, leucomelanodermia, acroesclerose e esclerodactilia foram observadas no exame físico extraoral. Microstomia, ausência de selamento labial, pigmentação extrínseca nos dentes 12, 11, 21 e 22, trespasse horizontal acentuado (11mm) e aumento gengival induzido por medicamentos também foram observados. A higiene bucal era satisfatória e o paciente não apresentava lesões cariosas. A paciente foi encaminhada para tratamento ortodôntico e segue em acompanhamento, por meio de consultas odontológicas preventivas bimestrais. **Conclusão:** a esclerose sistêmica, mesmo quando controlada, pode estar associada a microstomia, selamento labial inadequado, manchas extrínsecas nos dentes, trepasse horizontal acentuado, aumento gengival induzido por medicamentos e xerostomia. Portanto, requer prevenção e controle das doenças bucais, a fim de melhorar o manejo odontológico e monitorar a condição bucal do paciente.

Keywords: systemic sclerosis. Adolescents. oral manifestation.

ABSTRACT

Objective: to report oral manifestations in a bone marrow-transplanted adolescent with systemic sclerosis. **Case report:** a 12-year-old female teenager was referred to a specialized dental care center for patients with special needs with a complaint of dental malocclusion. In the anamnesis, the caregiver reported diagnosis of systemic sclerosis at birth and hematopoietic stem cell transplantation to control the disease at 6 years of age. The patient chronically uses antihypertensive and anti-inflammatory drugs and reports xerostomia and dysphagia. Telangiectasias, facial atrophy, leukomelanoderma, acrosclerosis, and sclerodactyly were observed in the extraoral physical examination. Microstomy, inadequate lip sealing, extrinsic pigmentation on teeth 12, 11, 21 and 22, marked horizontal overjet (11mm) and drug-induced gingival hyperplasia were also observed. Oral hygiene was satisfactory, and the patient had no carious lesions. The patient was referred for orthodontic treatment and is under follow-up with bimonthly preventive dental appointments. **Conclusion:** systemic sclerosis, even when controlled, can be associated with microstomy, inadequate lip sealing, extrinsic tooth staining, marked horizontal overjet, drug-induced gingival hyperplasia, and xerostomia. Therefore, it requires the prevention and control of oral diseases in order to improve dental management and monitor the patient's oral condition.

Submitted: August 19, 2023
Modification: March 31, 2024
Accepted: April 08, 2024

***Correspondence to**:
Karla Lorene de França Leite
Address: Rua Rodolpho Paulo Rocco 325, Cidade Universitária, Rio de Janeiro Caixa Postal: 68066 – Cidade Universitária - CCS-Rio de Janeiro – RJ – Brasil Zip code: 21941-971
Telephone number: +55 (21) 3938-2101
E-mail: karla.l.f.leite@gmail.com

INTRODUCTION

Systemic sclerosis is an autoimmune rheumatic condition that affects connective tissues, characterized by varying degrees of cutaneous and visceral fibrosis and vasculopathy of blood capillaries.[1] Epidemiological studies have reported that this condition affects 35 cases per million individuals.[2] The disease is more frequent in women (4:1 ratio), and it can occur in all age groups, with its peak incidence in adulthood.[3] It carries a high morbidity, with a risk of mortality up to seven times higher than that of the general population, primarily due to cardiopulmonary involvement.[4] Systemic sclerosis in children and adolescents is relatively rare, especially when compared to its occurrence in adults. This disease is most commonly diagnosed in adults, with the incidence increasing with age, and is considered a less frequent condition compared to other rheumatic diseases in children.[5]

The oral manifestations of the disease are influenced by the progression of facial and mucosal fibrosis, which limits mouth opening (microstomy) and leads to the wrinkling of the perioral folds, stiffness of the soft palate, larynx, and oral mucosa. It also affects the function of the salivary glands, which can results in hyposalivation and / or xerostomia.[6,7] It is common to observe caries lesions and periodontal disease in these pacients[8,9], which can be attributed to the difficulty of performing dental treatment and maintaining oral hygiene. The alar region of the nose becomes atrophied, resulting in a contracted nasal appearance referred to as "mouse-like facies".[1] In patients with more than 30 years of disease, mandibular bone resorption can be observed, occasionally leading to spontaneous fractures. In addition, temporomandibular disorders can also occur, involving varying degrees of posterior reabsorption of the mandible ramus, coronoid process, chin, and condyle.[10] However, this bone loss may be associated with the continuous use of medications (bisphosphonates) and /or the progression of the disease.[11-13]

The etiologic factors of systemic sclerosis remain unclear, so to date, no entirely effective treatment has been identified. However, for the patients who do not respond to any pharmacologic interventions, hematopoietic stem cell transplantation may be considered as an approached.[14] Both systemic and oral clinical conditions have a significant impact on the social interactions of patients with systemic sclerosis, resulting in a negative effect on their quality of life.[15,16] However, there are limited case reports in the literature on systemic sclerosis in adolescents, particularly concerning the oral manifestations associated with the disease and the challenges in dental management. Therefore, the present report aims to describe the orafacial manifestations and management of a bone marrow transplant adolescent with systemic sclerosis, in order to assist prevent oral complications and improve the prognosis of the case.

CASE REPORT

Ethical aspects

This case was conducted in compliance with the Helsinki Declaration and by the guide for CARE case reports,[17] and the subject's caregiver signed an informed consent form about the dental treatment and the scientific report of the case.

Anamnesis

An 12-year-old female adolescent sought the clinic for patients with special needs at the Faculty of Dentistry of the Universidade Federal do Rio de Janeiro, Rio de Janeiro, Brazil, in April 2018 with primary complaint of "crooked tooth to put appliance".

During the anamnesis, a diagnosis of systemic sclerosis since birth was reported. There were no complications during pregnancy, no family history of the disease, or other health problems with the parents. The patient underwent a hematopoietic stem cell transplantation at the age of six to control the progression of the disease, following the diagnosis of SSc based on the American College of Rheumatology/EULAR criteria of 2013.[18]

The patient has previously received medical care from a cardiologist, dermatologist, endocrinologist, psychologist, and occupational therapist, but currently she is only under the care of a rheumatologist. She has a history of allergy to non-steroidal anti-inflammatory drugs and regularly takes the following medications: sildenafil citrate (25 mg), amlodipine besylate (0.25 mg), bosentan (31.5 mg), acetylsalicylic acid (5 mg), omeprazole (20 mg), vitamin D (800 U.I.), and kalyamon (10 mL).

General examination

On physical examination, telangiectasias were observed in the ala of the nose, retrusion of the middle third of the face (Figure 1), leukomelanoderma in the region of the lower limbs and elbows, acrosclerosis and sclerodactyly with recurrent episodes of ulcerations in the fingers (digital scars) (Figure 2). Due to the difficulty in grasping objects, the caregiver assisted with body and oral hygiene.



***Figure 1**: A) depicts the frontal view, with the patient seen in frontal view; B) shows the right lateral view, and C) displays the left lateral view. In these profile views, retrusion of the middle third of the face and telangiectasias present in the nose are observed.*



Figure 2. *Patient with a shiny, swollen hand, thickened fingers (acrosclerosis) and the presence of leukomelanoderma. The presence of a dressing is observed as a result of skin dryness (digital scars).*

Oral examination and dental management

On extraoral physical examination, inadequate lip sealing and fibrosis of the periorbital tissue were observed, requiring constant hydration. Signs or symptoms of dysfunctional temporomandibular were not observed on palpation.

In the intraoral physical examination, there was a limitation in the maximum mouth opening (30 mm) and a prominet overjet (11 mm). The patient presented occlusion in Class II, division 1, right subdivision. The oral mucosa exhibited normal appearance, but drug-induced gingival enlargement, especially in the anterior region, was observed, probably associated with the absence of lip sealing and relation of amlodipine medication (Figure 3).



Figure 3*: Intraoral appearance, good oral hygiene and microstomy are observed. Due to mouth opening limitation, intraoral mirrors were not used. A) Superior occlusion from a more palatal angle; B) Presents the same view of the superior occlusion from a more buccal angle; C) View of the inferior occlusion; D) Brownish staining and opaque lines restricted to the permanent maxillary central and lateral incisors, suggestive of extrinsic pigmentation, and the presence of gingival hyperplasia in the anterior region.*

The patient presents incomplete permanent dentition (second maxillary premolars not erupted), absence of carious lesions or accumulation of dental biofilm, with a good oral hygiene. Brown staining and opaque lines were observed on the buccal face of permanent maxillary central and lateral incisors, without discontinuity of the dental structure. The hypothesis of alteration by a chemical agent (use of tetracycline and fluoride intake in childhood) was also ruled out during anamnesis, being suggestive of extrinsic pigmentation (Figure 3D). The depth of the periodontal pocket (BP) and the clinical level of insertion (CI) were determined using a millimeter probe (Williams, Hu-Friedy™) in six locations (mesio-buccal, middle-buccal, disto-buccal, mesio-lingual, middle-lingual and disto-lingual). However, there was no gingival bleeding, with BP < 2 mm and CI < 3 mm in all evaluated sites.

The patient reported having gone to the dentist only once and complained of xerostomia associated with dysphagia. In view of this complaint, the collection of unstimulated saliva was performed, after the clinical examination, with 1 h of fasting, to determine the salivary flow. The collection took place in a reserved environment, with adequate lighting and temperature, in the morning and with the patient seated (90º). The saliva produced in the initial 30 seconds was discarded and then collected for one minute and deposited in a graduated tube.[19] The salivary flow was 0.5 mL / min, being considered normal (> 0.1 mL / min).

The rheumatologist requested a computed tomography (CT) scan to evaluate cervical root resorption. In order to minimize additional radiation exposure, we utilized this medical CT scan for dental evaluation as well. Additionally, a cone beam computed tomography (CBCT) scan was requested specifically to assess the bone integrity of the mandibular ramus, coronoid process, chin, and condyle, as well as to evaluate the position and eruption stage of the second maxillary premolars. No evidence of bone loss was observed, and unerupted teeth were found to be appropriately positioned and at the expected stage of eruption (Figure 4).

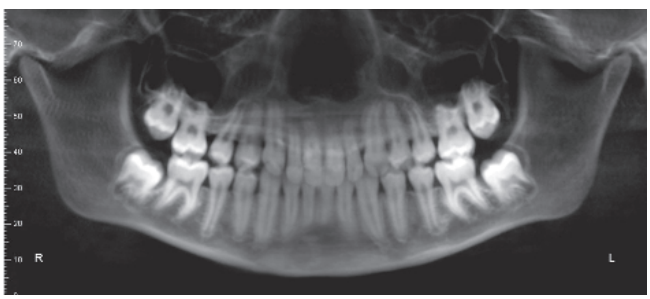

Figure 4. *Panoramic reconstruction without evidence of bone resorption and appropriate position and eruption stage of the second maxillary premolars.*

The patient was referred for orthodontic treatment due to aesthetic complaints and changes observed in the gingival and dental hard tissues during the clinical examination. Oral hygiene instruction was reinforced, including the use of dental floss with an infant dental floss, and the patient continues to be followed up, through bimonthly preventive dental consultations.

DISCUSSION

There is a scarcity of literature reports involving adolescents affected by systemic sclerosis, as the disease typically develops with an average age of 64 ± 13 years, and the average duration of the disease is 12 ± 12 years at the time of death.[20] Given this lack of information, this case report aims to describe the management and physical, oral, and dental findings in an adolescent with systemic sclerosis who underwent a hematopoietic stem cell transplantation. Early multiprofessional follow-up for these patients improves their expectancy and quality of life by allowing for the early diagnose systemic, physical, and oral manifestations, enabling to implementation of preventive and therapeutic measures.

A cohort study investigating the relationship between disease characteristics and orofacial manifestations has revealed that a reduced interincisal distance is correlated with the overall severity of the disease. Additionally, it has been determined that tooth loss is linked to the loss of upper limb function and decreased saliva production.[21] In the present case, it was observed that a hematopoietic stem cell transplantation has served as an alternative to control the progression of the disease, resulting in the milder disease manifestations in this 12-year-old patient. In addition, the maintenance of oral health in this patient may also be attributed to the collaborative efforts of caregivers in ensuring good oral hygiene practices and regular dental visits.

In the present case, despite the presence of microstomy, it has not led to complications in the patient's oral health. This is because the patient is capable of maintaining adequate hygiene, as evidenced by the absence of dental biofilm, dental caries, and periodontal disease. However, the microstomy should still be considered a complicating factor for dental treatment, as any future dental procedures may be hindered by the limited mouth opening. Therefore, it is crucial to emphasize the significance of preventive measures and to inform the patient about potential complications and the necessity for hospital-based interventions.

In the present case, gingival hyperplasia was observed, which might be associated with inadequate lip sealing and the use of amlodipine medication[22], serving as a risk factor for the development of periodontal diseases, including symptoms such as bleeding, discomfort during chewing, and tenderness. In this case, there was no need for surgical intervention to control gingival hyperplasia, therefore, we opted for regular monitoring to assess potential complications. Additionally, staining on the enamel of the maxillary anterior teeth was noted, possibly linked to continuous medication usage and/or extrinsic factors. These alterations can affect the patient's aesthetics and, consequently, have a negative impact on their quality of life. However, the patient's aesthetic concern primarily focused on teeth alignment within the dental arch, with the proposal of microabrasion at the conclusion of orthodontic treatment.

Therefore, the monitoring and preservation of the case should be encouraged, even for individuals considered to be at low risk of developing dental and periodontal problems[1,8]. Due to the progression of the disease and uncontrolled oral manifestations, the patient and the professional must be aware of potential complications.

The chronic use of medications influences dental management, as some drugs, such as systemic steroids, may favor the progression of oral diseases[6-9]. In the present case, the patient uses medication for the treatment of pulmonary arterial hypertension, decreased gastric secretion and vitamin and mineral supplement for the prevention and treatment of calcium deficiencies in general. Thus, caregivers need to be educated about possible complications from regular use of drugs, which can alter the oral microbiota and favor the proliferation of species that establish a commensal environment.[23] Therefore, the importance of providing hygiene and dietary guidelines to prevent these changes in microbiota.

The patient's clinical and imaging examination showed no evidence of tooth mobility or bone loss in the jaw, respectively. This favorable outcome can be attributed to the early transplant, which delayed the progression of bone resorption, considered inherent to the diseas e[11,12,13], significantly improving the disease prognosis and favoring future orthodontic intervention in the patient.

Xerostomia is a common symptom among patients affected by the disease, and when associated with hyposalivation, the use of artificial saliva and reinforcement of oral hygiene guidelines are recommended, this recommendation holds true even in view of the difficulty in using dental floss, as efforts are made to adapt this care[9,16]. Despite the complaint of xerostomia in the present case, no change in salivary flow was observed. Therefore, the patient received no indication for the use of artificial saliva. However, the patient maintains periodic visits to the dentist, contributing to an increased frequency of oral health education practices.

The treatment of systemic sclerosis requires a multidisciplinary approach to patient[4,24] and should be initiated early and preventively. Therefore, it is crucial for physicians to be aware of the potential dental changes in these patients, enabling them to refer patients to dentists for early diagnosis of oral manifestations, thus enhancing clinical management and increasing patient awareness. Likewise, it is important that the dentist has knowledge of this condition and the oral manifestations that may be associated in order to diagnose early and refer the patient for necessary medical treatment.

CONCLUSION

Systemic sclerosis, even when controlled, could be associated with microstomy, inadequate lip sealing, extrinsic pigmentation in teeth, prominent overjet, drug-induced gingival enlargement, and xerostomia. Therefore, it requires prevention and control of oral diseases in order to improve dental management and monitor the patient's oral condition.

Disclosure Statement

The authors declare that they have no conflict of interest.

Funding sources

This study was financed in part by the Coordenação de Aperfeiçoamento de Pessoal de Nível Superior – Brazil (CAPES) – Finance code 001.

REFERENCES

1. Albilia JB, Lam DK, Blanas N, Clokie CM, Sándor GK. Small mouths... Big problems? A review of scleroderma and its oral health implications. J Can Dent Assoc. 2007;73(9):831-6. PubMed PMID: 18028759.

2. Barnes J, Mayes MD. Epidemiology of systemic sclerosis: incidence, prevalence, survival, risk factors, malignancy, and environmental triggers. Curr Opin Rheumatol. 2012;24:165–70. doi: 10.1097/BOR.0b013e32834ff2e8.

3. Foocharoen C, Mahakkanukrauh A, Suwannaroj S, Nanagara R. Clinical characteristics and mortality in systemic sclerosis: a comparison between early- and late-referred diseases. J Med Assoc Thai. 2014;97(1):28-35. PubMed PMID: 24701726.

4. Rubio-Rivas M, Royo C, Simeón CP, Corbella X, Fonollosa V. Mortality and survival in systemic sclerosis: systematic review and meta-analysis. Semin Arthritis Rheum. 2014;44(2):208-19. doi: 10.1016/j.semarthrit.2014.05.010.

5. Foeldvari I. Update on juvenile systemic sclerosis. Curr Rheumatol Rep. 2015;17(3):18. doi: 10.1007/s11926-014-0491-y.

6. Chu CH, Yeung CMK, Lai IA, Leung WK, Mok MY. Oral health of Chinese people with systemic sclerosis. Clin Oral Investig. 2011;15(6):931-9. doi: 10.1007/s00784-010-0472-0. Epub 2010 Oct 12.

7. Yuen HK, Marlow NM, Reed SG, Mahoney S, Summerlin LM, Leite R, *et al*. Effect of orofacial exercises on oral aperture in adults with systemic sclerosis. Disabil Rehabil. 2012;34(1):84-9. doi: 10.3109/09638288.2011.587589. Epub 2011 Sep 27.

8. Yuen HK, Hant FN, Hatfield C, Summerlin LM, Smith EA, Silver RM. Factors associated with oral hygiene practices among adults with systemic sclerosis. Int J Dent Hyg. 2014;12(3):180-186. doi: 10.1111/idh.12056. Epub 2013 Oct 15.

9. Balzer J. The use of adaptive oral hygiene devices and orofacial exercise by adults with systemic sclerosis (scleroderma) seems to improve their gingival health. J Evid Based Dent Pract. 2012;12(2):97-8. doi: 10.1016/j.jebdp.2012.03.015

10. Aliko A, Ciancaglini R, Alushi A, Tafaj A, Ruci D. Temporomandibular joint involvement in rheumatoid arthritis: systemic lupus erythematosus and systemic sclerosis. Int J Oral Maxillofac Surg. 2011; 40(7):704–9. doi: 10.1016/j.ijom.2011.02.026. Epub 2011 Apr 3.

11. Arroyo-Bote S, Bucchi C, Manzanares MC. External Cervical Resorption: A New Oral Manifestation of Systemic Sclerosis. J Endod. 2017;43(10):1740-1743. doi: 10.1016/j.joen.2017.03.040

12. Baron M, Hudson M, Dagenais M, Macdonald D, Gyger G, El Sayegh T, *et al*. Relationship Between Disease Characteristics and Oral Radiologic Findings in Systemic Sclerosis: Results From a Canadian Oral Health Study. Arthritis Care Res (Hoboken). 2016;68(5):673-80. doi: 10.1002/acr.22739.

13. Mugino H, Ikemura K. Progressive systemic sclerosis with spontaneous fracture due to resorption of the mandible: a case report. J Oral Maxillofac Surg. 2006;64(7):1137-9. doi: 10.1016/j.joms.2005.11.037.

14. Burt RK, Shah SJ, Dill K, Grant T, Gheorghiade M, Schroeder J, *et al*. Autologous non-myeloablative haemopoietic stem-cell transplantation compared with pulse cyclophosphamide once per month for systemic sclerosis (ASSIST): an open-label, randomised phase 2 trial. Lancet. 2011;6;378(9790):498-506. doi: 10.1016/S0140-6736(11)60982-3. Epub 2011 Jul 21.

15. Smirani R, Truchetet ME, Poursac N, Naveau A, Schaeverbeke T, Devillard R. Impact of systemic sclerosis oral manifestations on patients' health-related quality of life: A systematic review. J Oral Pathol Med. 2018; 47(9):808-815. doi: 10.1111/jop.12739. Epub 2018 Jul 5.

16. Baron M, Hudson M, Tatibouet S, Steele R, Lo E, Gravel S, *et al*. The Canadian systemic sclerosis oral health study: orofacial manifestations and oral health-related quality of life in systemic sclerosis compared with the general population. Rheumatology (Oxford). 2014;53(8):1386-94. doi: 10.1093/rheumatology/ket441. Epub 2014 Jan 24.

17. Riley DS, Barber MS, Kienle GS, Aronson JK, Schoen-Angerer TV, Tugwell P, *et al*. CARE guidelines for case reports: explanation and elaboration document. J Clin Epidemiol. 2017;89:218-235. doi: 10.1016/j.jclinepi.2017.04.026. Epub 2017 May 18.
18. Costa-Pereira KR, Guimarães AL, Moraes DA, Dias JBE, Garcia JT, Oliveira-Cardoso EA, *et al*. Hematopoietic Stem Cell Transplantation Improves Functional Outcomes of Systemic Sclerosis Patients. J Clin Rheumatol. 2020;26(7S Suppl 2):S131-S138. doi: 10.1097/RHU.0000000000001117.
19. Löfgren CD, Wickström C, Sonesson M, Lagunas PT, Christersson C. A systematic review of methods to diagnose oral dryness and salivary gland function. BMC Oral Health. 2012;8;12:29. doi: 10.1186/1472-6831-12-29.
20. Ingegnoli F, Ughi N, Mihai C. Update on the epidemiology, risk factors, and disease outcomes of systemic sclerosis. Best Pract Res Clin Rheumatol. 2018;32(2):223-240. doi: 10.1016/j.berh.2018.08.005. Epub 2018 Sep 14.
21. Baron M, Hudson M, Tatibouet S, Steele R, Lo E, Gravel S, *et al*. Relationship between disease characteristics and orofacial manifestations in systemic sclerosis: Canadian Systemic Sclerosis Oral Health Study III. Arthritis Care Res (Hoboken). 2015;67(5):681-90. doi: 10.1002/acr.22490.
22.Carty O, Walsh E, Abdelsalem A, MaCarthy D. Case report: drug-induced gingival overgrowth associated with the use of a calcium channel blocker (amlodipine). J Ir Dent Assoc. 2015;61(5):248-51. PubMed PMID: 26665904.
23. Hebecker B, Naglik JR, Hube B, Jacobsen ID. Pathogenicity mechanisms and host response during oral Candida albicans infections. Expert Rev Anti Infect Ther. 2014;12(7):867-79. doi: 10.1586/14787210.2014.916210. Epub 2014 May 7.
24. Scardina GA, Mazzullo M, Messina P. [Early diagnosis of progressive systemic sclerosis: the role of oro-facial phenomena]. Minerva Stomatol. 2002;51(7-8):311-7. PubMed PMID: 12434126.