SKELETAL CLASS III MALOCCLUSION IN CONJUNCTION WITH EARLY CHILDHOOD CARIES INCREASES ORTHODONTIC TREATMENT COMPLEXITY: A CASE REPORT

José **Valldares-Neto** [1]*, Cristiane Barbosa dos **Santos**[1], Breno Soares **Arruda**[1], Ilda Machado Fiuza **Gonçalves**[1]

[1]School of Dentistry, Universidade Federal de Goiás, Goiânia, GO, Brazil

Palavras-chave: Má Oclusão Classe III de Angle. Cárie Dentária. Índice de Necessidade de Tratamento Ortodôntico.

RESUMO

Introdução: Vários índices objetivos de complexidade e necessidade de tratamento ortodôntico foram compilados ao longo dos anos, sendo que a maioria se baseou em características morfológicas da má oclusão. **Objetivo**: O objetivo deste artigo é relatar uma estratégia clínica para o tratamento de múltiplas cáries de primeira infância combinado à má oclusão esquelética de Classe III. **Relato de caso**: Paciente do sexo feminino, 5 anos, procurou tratamento odontológico com queixa de cárie dentária, dor e má oclusão. O plano de tratamento envolveu três etapas: alívio da dor, controle da doença cárie e restauração, e uma abordagem ortodôntica-ortopédica. O tratamento necessitou de uma mudança comportamental nos hábitos alimentares da unidade familiar que precedeu o tratamento da má oclusão. **Resultados**: O caso clínico, considerado complexo, produziu resultado satisfatório quando a atuação integrada das disciplinas de odontopediatria e ortodontia. **Conclusão**: A complexidade do tratamento ortodôntico em crianças também deve ser determinada pelo crescimento craniofacial remanescente e capacidade de colaboração do paciente e dos pais.

Keywords: Angle Class III Malocclusion. Dental Caries. Index of Orthodontic Orthodontic Treatment Need.

ABSTRACT

Introduction: Many objective indexes of orthodontic treatment complexity and need have been compiled over the years, most of which have been based on the morphological characteristics of malocclusion. **Objective**: The aim of this paper is to report a clinical strategy for treating multiple early childhood caries in conjunction with skeletal Class III malocclusion. **Case report**: A 5-year-old female patient sought dental treatment complaining of dental caries, pain, and malocclusion. The treatment plan involved three steps: pain alleviation, carious control and restauration, and, an orthodontic-orthopedic approach. Treatment also involved a behavioral change in eating habits of the family unit preceding the treatment of malocclusion. **Results:** The complex clinical cases can yield satisfactory outcomes when pediatric dentistry and orthodontic disciplines are integrated. **Conclusion**: Orthodontic treatment complexity in children should also be determined by remaining craniofacial growth and both patient and parent's adhesion and compliance.

Submitted: May 26, 2018
Modification: July 10, 2018
Accepted: July 11, 2018

Correspondence to:
Prof. José Valladares-Neto
Faculdade de Odontologia,
Universidade Federal de Goiás
Avenida Universitária esquina com 1ª Avenida, s/ número.
CEP: 74605-220. Goiânia-GO, Brasil
Telephone Number: +55 62 98231-6000
E-mail: jvalladares@uol.com.br

INTRODUCTION

Many objective indexes of orthodontic treatment complexity have been created over the years. Most have been based on the morphological characteristics of malocclusion, which include skeletal discrepancy, and are used to identify the orthodontic treatment needed, severity of malocclusion, difficulties in treating, and treatment outcome.[1] However, early orthodontic treatment can also be influenced by other parameters, such as patient compliance, remaining craniofacial growth, and other types of oral health impairment.[2]

Interceptive Class III malocclusion treatment is always challenging because of the doubtful

prognosis.[3] A treatment choice for 5 to 9-year-olds is the facemask with or without maxillary expansion, which improves overjet with limited influence on sagittal skeletal components, but without much long-term evidence.[3,4] Treatment outcomes depend on the magnitude and direction of remaining craniofacial growth. Severe cases with a clear family history may culminate in the need for orthognathic surgery after cessation of craniofacial growth, even with early orthopedic treatment.[3]

In addition, malocclusion in children may present simultaneously with other types of oral health impairment, such as early childhood caries, toothache and dental loss.[5] In Brazil, the prevalence of early childhood caries is 46% among two to three-year olds,[6] but can affect children of any ethnicity.[7] Occurrence is associated to low income households, little schooling, and larger families.[7-9] In such cases, preventive treatment is neglected and curative treatment is sought by the caregiver when a child feels pain or if carious lesions are perceived.[10]

It seems reasonable to assume that orthodontic treatment complexity increases in children when associated to multiple carious lesions. The aim of this case report was to present a clinical strategy for treating multiple early childhood caries in conjunction with skeletal Class III malocclusion. The CARE case report guidelines were followed.[11]

CASE REPORT

Patient information

A 5-year-old female patient was brought to the Children's Clinic at the Federal University of Goiás School of Dentistry, by her parents, complaining mainly of dental caries and pain. She had previously been treated by mass excavation and had temporary restorations of glass ionomer cement but did not continue with her treatment. This time, she came back complaining of odontogenic pain of intensity 2, according to the FPS-R scale, lasting more than a month.[12] The anamnesis showed that the child did not have supervised brushing and consumed excessive sugar. She had been breastfed exclusively in her first year of life.

Clinical and radiographic findings

The facial profile was concave in a hypodivergent pattern, but with facial thirds unbalanced due to lower third reduction. The lips were passively sealed and the smile-line was low, with marked short maxillary incisor exposition. Initial cephalometric data showed the presence of Class III skeletal malocclusion due to maxillary deficiency, a finding compatible with the facial analysis. In terms of dentition development, she was at the initial mixed dentition stage (eruption of 26, 36, and 46). Her occlusal situation was characterized as Class I, based on the canine relationship with complete anterior crossbite and 50% overbite. The right permanent first molars (16 and 46) were in crossbite probably because of a mild maxillary atresia. An intraoral examination detected the presence of multiple temporary restorations which needed replacing (teeth 51, 52, 53, 54, 61, 62, 63, 64, 65, 74 and 84), and absence of teeth (75 and 85) (**Figures 1**).



***Figure 1**: Pre-treatment photographs.*

Diagnostic assessment

The patient presented a Class III skeletal pattern due to combination of maxillary retrognathism and mandibular prognathism, resulting in a concave facial profile (ANB= -1.5 degrees, Witts= -6.0 mm, SNA= 80.0 degrees, SNB= 81.5 degrees, NAP= -3.0 degrees). Maxillary involvement was also detected in the transversal and vertical dimensions, respectively, due to maxillary atresia and decreased lower facial height with a short smile (SN.GoGn= 29.0 degrees). The functional examination of the occlusion was performed and it was confirmed that there was no functional anterior mandibular shift. The canine sagittal relationship was in Class I and the incisal overjet was negative with anterior crossbite of the four upper incisors. The child also presented with an early loss of lower second primary molars (teeth 75 and 85), multiple temporary restorations and dental caries, pain, and poor oral hygiene.

Therapeutic intervention

The treatment plan was based on three steps: 1- Pain alleviation by eliminating the foci of infection, 2- Carious control and restauration, and 3- Orthodontic-orthopedic treatment. For this purpose, a psychological behavioral conditioning of the patient was undertaken. The first procedures involved oral hygiene instruction and a change in eating habits, extraction (tooth 82), endodontic treatment (tooth 63), dental restorations with composites (teeth 63, 53, 55) and ionomer sealant (tooth 65). During dental restorations, several teeth exfoliated (teeth 51, 52, 61, 62).

After oral health was reestablished, the orthodontic planning involved the use of fixed space maintenance in the edentulous region (teeth 75 and 85), and maxillary atresia and Class III correction through a modified Haas expander followed by a Petit face mask for reverse traction.





***Figure 2**: Orthodontic-orthopedic treatment performed with modified Haas type expander and Petit facial mask.*

Follow-up and outcome

The integrated treatment was performed as planned. With the treatment of carious lesions and the exchange of provisional restorations, bacterial plaque retention sites and infection foci were eliminated, and the oral environment was allowed to adjust. Endodontic (tooth 63) and extraction (tooth 82) treatments led to the relief of pain.

After behavioral and oral health preparation, orthodontic treatment was started. The first orthodontic step was to correct the maxillary atresia by inserting a modified Haas type expander in the second molars and canines. The caregiver was given instruction on the expander activation protocol which consisted of a 1/4 turn twice a day until overcorrection was reached. This process took 2 weeks. The upper dental arch was expanded in intercanine and second molar distances by 4 mm and 5 mm, respectively. During the retention, a Petit type face mask was inserted with medium ½ elastics retained on the expander hook near the maxillary canines with 400g force application on each side. The face mask was recommended for daily use at home (**Figure 2**). The patient received follow-up monthly treatment for 9 months until the bite was uncrossed. Exodontia of the upper deciduous canines was performed after removal of the expander to allow adequate alignment of the upper lateral incisors (12 and 22).





***Figure 3**: Follow-up photographs.*

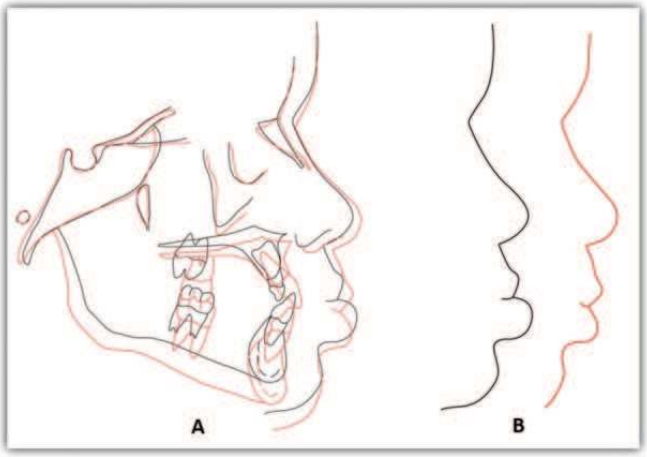

***Figure 4**: Total cephalometric superposition (A) and profile change (B).*

The post treatment short-term results showed a significant improvement in oral health, occlusal relations and facial profile. Greater forward lip projection and increased upper lip vermilion exposure contributed to face harmonization and enhanced the child's self-esteem. **Figures 3** and **4** show the clinical and radiographic improvement after treatment and follow-up (final cephalometric data: ANB= 3.0 degrees, Witts= -1.5 mm, SNA= 81.5 degrees, SNB= 78.5 degrees, SN.GoGn= 31.5 degrees, NAP= 1.0 degree).

DISCUSSION

Complex cases in children's dental clinics require close interdisciplinary integration for strategic clinical decision-making. The term "complexity" in orthodontics should be understood as the amount of effort or skill needed to obtain a successful outcome at the end of treatment and maintain it long-term.[1,2] This article reports a complex case involving a 5-year-old with multiple early childhood caries, pain, poor oral hygiene, and skeletal Class III malocclusion. Orthodontic-orthopedic intervention was recommended with caution because of an unfavorable overall prognosis. Indexes of orthodontic treatment complexity should be based on orthodontic elements, such as severity of the skeletal discrepancy and the unfavorable remaining facial growth, but should also include impaired oral health, such as tooth loss and multiple dental caries disease. In addition, treatment complexity should also be modulated by psychosocial and cultural factors, because treatment goals depend on both patient and parent's adhesion and compliance. Therefore, the concept of orthodontic treatment complexity in children should also include holistic parameters.

Carious disease in both generalized and advanced stages, and severe malocclusion, separately, can compromise a child´s quality of life and could result in their undergoing pain; speech, eating and sleep disorders; general suffering; and bullying. Integration of the specialist teams involved in child dental care is essential for successful treatment, as is education of the family unit.[13,14]

Integrated treatments must systematize a rational sequence of intervention. Treatment efforts must at first concentrate on pain alleviation, and then on carious control. The multifactorial etiology of dental caries goes beyond isolated curative treatment as it requires the involvement of the family in incorporating and maintaining new eating habits. This must be particularly stressed in terms of dietary control, and such preventive attitudes should be maintained for at least the first five years of life.[15] It is well known that dental biofilm one of the factors which triggers the development of caries, and the demineralization phenomenon is maximized when dietary sugar is recurrent. In the case reported, a survey of eating habits showed a diet rich in sugar and carbohydrate consumed at irregular intervals. In addition, the child was in the habit of getting a feeding bottle at night until she was three. The fact that the child took care of her own oral hygiene by herself, without parental supervision, was another aggravating factor. In this age bracket, motor coordination is vital for efficient brushing and cleaning with dental floss.

Preparation of the buccal environment can be grouped into several clinical procedures which aim to revert and control carious activity before definitive restoration and, as in the case reported, before embarking on an orthodontic-orthopedic approach. Its purpose is to quantitatively and qualitatively control buccal microorganisms, and lead to the remineralization by changing oral pH. Initial procedures could include the use of diary reporting of the diet every 3 days, daily mechanical control of biofilm by the patient assisted by parents which includes nightly brushing, using fluoride toothpaste and varnish, and restricting the consumption of cariogenic foods. After this preparation, the superficial part of the caries lesions (infected dentin) should be removed, in a procedure called mass excavation. The tissue removed is rich in denatured collagen and microorganisms abound, whereas in the deeper layer (affected dentin), the collagen is intact and there is a lesser concentration of microorganisms and greater potential for remineralization.[6,7,9,10,16]

Many objective indexes of orthodontic treatment complexity have been compiled over the years, most of which have been based on the morphological characteristics of malocclusion. Normally, pre-treatment dental casts and cephalometric data are used to classify the orthodontic treatment need and complexity. However, this simplistic concept should not be applied alone to orthodontic-orthopedic treatment of children.

The case reported showed cephalometric data and facial characteristics compatible with a skeletal Class III pattern, even with a Class I canine relationship. It is recommended that interceptive skeletal Class III malocclusion be treated using an orthopedic approach during the deciduous or mixed dentition stage, that is, before the pubertal growth spurt.[4,17] More recently, skeletal anchorage has been considered an alternative for patients after lower canine eruption or in early permanent dentition at the latest.[18] Inserting the T-spring was an additional feature used to promote correction of excessive uprightness in the upper incisors and accelerate correction of negative overjet, although the effect was exclusively orthodontic and could also be derived from reverse traction.[19]

Since posttreatment growth cannot be determined in advance, overcorrection of the horizontal overjet and the maintenance of the containment for an adequate period is essential. This should be clarified to the parents and the patient from the outset so that they are properly informed and invited to cooperate with the treatment.

CONCLUSION

Complex clinical cases can attain satisfactory outcomes by integrating pediatric dentistry and orthodontic disciplines. Behavioral changes in the family diet were essential in attaining the immediate goals and improving oral-health-related quality of life. Various factors, such as the severity of the malocclusion, oral health impairment, patient compliance, psychosocial and cultural factors and others can influence orthodontic treatment complexity in children, because treatment goals depend on both patient and parent's adhesion.

Informed consent

Informed consent was obtained from the parents in this study.

Disclosure statement

No potential conflict of interest was reported by the authors.

REFERENCES

1.Bergström K, Halling A, Huggare J, Johansson L. Treatment difficulty and treatment outcome in orthodontic care. *Eur J Orthod.*1998;20(2):145-157.

2.Cassinelli AG, Firestone AR, Beck FM, Vig KW. Factors associated with orthodontists' assessment of difficulty. *Am J Orthod Dentofacial Orthop.*2003; 123(5):497-502.

3.Woon SC, Thiruvenkatachari B. Early orthodontic treatment for Class III malocclusion: A systematic review and meta-analysis. *Am J Orthod Dentofacial Orthop.*2017;151(1):28-52.

4.Kim JH, Viana MA, Graber TM, Omerza FF, BeGole EA. The effectiveness of protraction face mask therapy: a meta-analysis. *Am J Orthod Dentofacial Orthop.*1999;115(6):675-685.

5.Firmino RT, Gomes MC, Vieira-Andrade RG, Martins CC, Paiva SM, Granville-Garcia AF. Case-control study examining the impact of oral health problems on the quality of life of the families of preschoolers. *Braz Oral Res.*2016;30(1):e121.

6.Rosenblatt A, Zarzar P. Breast-feeding and early childhood caries: an assessment among Brazilian infants. *Int J Paediatric Dent.*2004;14(6):439-445.

7.Hooley M, Skouteris H, Boganin C, Satur J, Kilpatrick N. Parental influence and the development of dental caries in children aged 0-6 years: a systematic review of the literature. *J Dent.*2012;40(11):873-885.

8.Avila WM, Pordeus IA, Paiva SM, Martins CC. Breast and bottle feeding as risk factors for dental caries: A systematic review and meta-analysis. *Plos One*.2015 18(11):e0142922.

9.Leong PM, Gussy MG, Barrow SY, de Silva-Sanigorski A, Waters E. A systematic review of risk factors during first year of life for early childhood caries. *Int J Paediatr Dent.*2013;23(4):235-250.

10.Dabawala S, Suprabha BS, Shenoy R, Rao A, Shah N. Parenting style and oral health practices in early childhood caries: a case-control study. *Int J Paediatr Dent.*2017;27(2):35-144.

11.Gagnier JJ, Kienle G, Altman DG, Moher D. Sox H, Riley D. Care Goup. The CARE guidelines: consensus-based clinical case report guideline development. *J Clin Epidemiol.*2014;67(1):46-51.

12.Hicks CL, von Baeyer CL, Spafford PA, van Korfaar I, Goodenough B. The faces pain scale - revised: Towards a common metric in pediatric pain measurement. *Pain.*2001;93(2):171-183.

13.Ramos-Jorge J, Alencar BM, Pordeus IA, Soares ME, Marques LS, Ramos-Jorge ML, Paiva SM. Impact of dental caries on quality of life among preschool children: emphasis on the type of tooth and stages of progression. *Eur J Oral Sci.*2015;123(2):88-95.

14.Dimberg L, Arnrup K, Bondemark L. The impact of malocclusion on the quality of life among children and adolescents: a systematic review of quantitative studies. *Eur J Orthod.*2015;37(3):238-247.

15.Kidd EA, Joyston-Bechal S, Beighton D. Microbiological validation of assessments of caries activity during cavity preparation. *Caries Res.*1993;27(5): 402-408.

16.Feldens CA, Rodrigues PH, Rauber F, Chaffee BW, Vitolo MR. Food expenditures, cariogenic dietary practices and childhood dental caries in southern Brazil. *Caries Res.*2017;47(5):373-381.

17.Lione R, Buongiorno M, Laganà G, Cozza P, Franchi L. Early treatment of Class III malocclusion with RME and facial mask: evaluation of dentoalveolar effects on digital dental casts. *Eur J Paediatr Dent.*2015;16(3):217-220.
18.De Clerck HJ, Cornelis MA, Cevidanes LH, Heyman GC, Tulloch CJ. Orthopedic traction of the maxilla with miniplates: a new perspective for treatment of midface deficiency. *J Oral Maxillofac Surg.*2009;67(10):2123-2129.
19.Showkatbakhsh R, Toumarian L, Jamilian A, Sheibaninia A, Mirkarimi M,Taban T. The effects of face mask and tongue plate on maxillary deficiency in growing patients: a randomized clinical trial. *J Orthod*.2016;40(2):130-136.