DENTINOGENESIS IMPERFECTA TYPE I: CASE REPORT AND MICROSCOPIC ANALYSIS OF DENTINAL TISSUE

Gabriela Reis **Alves**[1], Ana Paula Gomes e **Moura**[1]*, Regina Guenka **Palma-Dibb**[2], Marília Pacífico **Lucisano**[1], Lea Assed Bezerra da **Silva**[1], Raquel Assed Bezerra da **Silva**[1]

[1]Department of Pediatric Dentistry, School of Dentistry, Universidade de São Paulo, Ribeirão Preto, SP, Brazil.
[2]Department of Restorative Dentistry, School of Dentistry, Universidade de São Paulo, Ribeirão Preto, SP, Brazil.

Palavras-chave: dentinogênese imperfeita. osteogênese imperfeita. avaliação microscópica. anomalias dentárias.

RESUMO

Introdução: A Dentinogênese Imperfeita (DI) afeta a dentina dos dentes decíduos e permanentes. Pode estar associada a uma doença óssea hereditária e sistêmica conhecida como Osteogênese Imperfeita. **Relato de Caso**: O objetivo deste trabalho é relatar o caso de uma paciente de 11 anos com diagnóstico de DI tipo I, que teve extraídos dois molares decíduos acometidos pela doença. Os dentes removidos foram submetidos à análise histológica e avaliação por Microscopia Confocal a Laser. **Resultados**: Histologicamente foram observados túbulos desorganizados, com diferentes diâmetros e em menor quantidade, e fibrilas de colágeno apresentavam distribuição irregular. A microscopia confocal mostrou dentina displásica, túbulos irregulares, áreas desprovidas de túbulos dentinários e deposição de grânulos. **Conclusões**: A DI compromete a formação dos túbulos dentinários, o que pode impactar nas propriedades da dentina. Além disso, pode levar a fraturas e desgaste dos dentes, influenciando na saúde e na estética bucal.

Keywords: Dentinogenesis imperfecta. Osteogenesis imperfecta. Microscopic evaluation. Dental anomalies

ABSTRACT

Introdution: Dentinogenesis Imperfecta (DI) affects the dentin of deciduous and permanent teeth. It may be associated with a hereditary and systemic bone disorder known as Osteogenesis Imperfecta. **Case Report:** to report the case of an 11-year-old patient diagnosed with DI type I, who had two deciduous molars affected by the disease extracted. The extracted teeth underwent histological analysis and evaluation using Confocal Laser Microscopy, Histologically, disorganized tubules with different diameters and in lesser quantity were observed, and collagen fibrils exhibited irregular distribution. **Results:** Confocal microscopy showed dysplastic dentin, irregular tubules, areas devoid of dentinal tubules, and granule deposition. **Conclusions:** Dentinogenesis imperfecta (DI) compromises the formation of dentinal tubules, which may affect the structural and mechanical properties of dentin. Furthermore, it can lead to tooth fractures and wear, thereby impacting oral health and aesthetics.

Submitted: october 24, 2024
Modification: october 09, 2025
Accepted: october 09, 2025

***Correspondence to**:
Ana Paula Gomes-Moura
Address: Avenida do Café, s/n - Campus da USP, Ribeirão Preto, SP, Brasil. CEP: 14040-904.
Telephone number: + 55 (16) 3602-3995
E-mail: anapaulamoura@usp.br

INTRODUCTION

Dentinogenesis imperfecta (DI) is a developmental anomaly of dentin linked to autosomal dominant mutations. It is classified into three types: type I, associated with osteogenesis imperfecta; type II, not associated with bone disorders; and type III, similar to type II but affecting a specific population from southern Maryland known as the "Brandywine isolate."[1-3]

Clinically, teeth affected by DI exhibit discoloration, ranging from gray to violet-brown or yellowish-brown, along with high translucency of the dental enamel. Despite the absence of enamel defects, this layer is frequently lost due to a weakened amelodentinal junction. Hypomineralization of the defective dentin leads to fracture and wear in the affected teeth. Radiographic examination often reveals partial or complete obliterations of the pulp space, shortened roots, and bulbous crowns with cervical constrictions. DI can affect both primary and permanent dentitions, with greater severity observed in the primary dentition.[4,5]

DI type I is characterized as a generalized connective tissue disorder that results in increased bone fragility. In addition to recurrent bone fractures, bone deformities, and impaired growth, patients with osteogenesis imperfecta may present with some secondary characteristics: blue sclerae, hearing loss, compromised pulmonary function, heart valve abnormalities, and dental manifestations such as malocclusions and DI.[4-8] Among the causes of osteogenesis imperfecta is a mutation in the COL1A1 and COL1A2 genes, which encode type I collagen, leading to defects in fiber synthesis and structure. Other genes have also been identified as possible causes of osteogenesis imperfecta because they are related to bone mineralization processes, post-translational modification of collagen, collagen processing, and osteoblast differentiation and function.[5,7,8]

Although some studies have examined the morphological and structural characteristics of dentin affected by DI,[9-12] few studies have evaluated this structure using confocal laser microscopy. A greater awareness of the microscopic structure of DI, particularly in cases associated with systemic conditions such as osteogenesis imperfecta, is clinically relevant as it may enhance diagnostic accuracy, enable earlier interventions, and support the development of individualized treatment strategies. Furthermore, understanding the dentinal characteristics of the affected teeth provides a stronger basis for establishing new treatment methods and developing more effective therapeutic materials, thus enhancing the quality of life of these patients.

Thus, the aim of this study was to report the case of an 11-year-old female patient diagnosed with DI type I, from whom two affected primary molars were extracted. The extracted teeth were subjected to histological analysis and evaluated using confocal laser microscopy.

CASE REPORT

This study was approved by the Research Ethics Committee of the School of Dentistry of Ribeirão Preto (Approval number 6.666.848). An 11-year-old female patient presented to School of Dentistry of Ribeirão Preto, affiliated with the University of São Paulo, reporting pain in the maxillary right second primary molar and in the mandibular left second primary molar.

Anamnesis and physical examination confirmed a prior diagnosis of osteogenesis imperfecta. Although no other relevant systemic conditions were present, the patient presented with skeletal and dental manifestations, including a history of multiple bone fractures and a family history of osteogenesis imperfecta (patient's father). Additionally, her height was below the expected range for her chronological age.

Upon clinical examination, it was observed that the patient was in the mixed dentition phase, and that her anterior teeth had a gray-brownish staining pattern. Also, the maxillary right second primary molar (Fig. 1A) and the mandibular right second primary molar (Fig. 1B) exhibited coronal destruction, followed by advanced root resorption (Fig. 2). The permanent successors of both teeth were at Nolla's stage 8 of development. Therefore, extraction of these teeth was recommended.

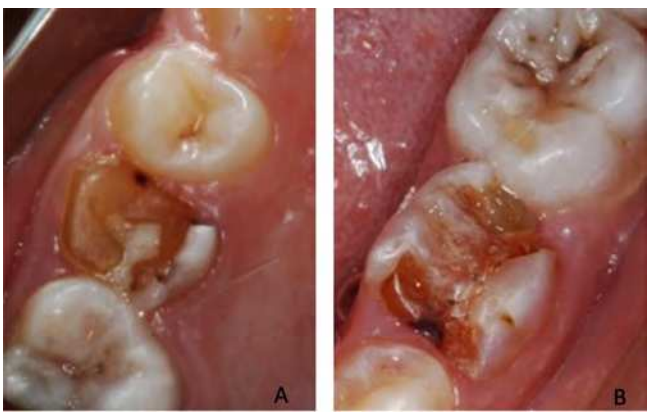

Figure 1: (A) Intraoral photograph of maxillary right second primary molar; (B) Intraoral photograph of mandibular left second primary molar.



Figure 2: Panoramic radiograph of the patient at 11 years of age, showing obliteration of the pulp chamber in maxillary permanent molars and enlarged pulp in mandibular permanent molars.

Radiographic examination revealed obliteration of the pulp chamber, especially in the maxillary permanent first molars and mandibular permanent incisors, while the mandibular permanent second molars presented a wide pulp chamber due to incomplete root development. The mandibular second molars showed an elongated pulp chamber, which is indicative of taurodontism.

Local anesthesia with 2% mepivacaine associated with 1:100,000 epinephrine was administered prior to the extractions. Subsequently, syndesmotomy was performed using a Molt 2-4 elevator, followed by luxation using forceps and levers. Suturing was not necessary after the procedure. The extracted teeth were donated to the Human Tooth Biobank of the School of Dentistry of Ribeirão Preto, University of São Paulo, after authorization by the patient's legal guardian. Post-extraction, the patient has been scheduled for clinical and radiographic follow-up visits every 6 months.

The maxillary right second primary molar underwent histotechnical processing, and the slides were stained with hematoxylin-eosin (H&E) and Masson's trichrome. The mandibular left second primary molar was evaluated through confocal laser microscopy. Initially, the specimens were analyzed in panoramic view, and photomicrographs were subsequently taken at a standardized magnification of 350×.

The microscopic analyses revealed that the superficial dentin adjacent to the amelodentinal junction exhibited uniformly distributed tubules with increased density and larger diameters. The deeper dentin, however, showed a more dysplastic area, with poorly defined and fewer dentinal tubules (Fig. 3).

Masson's trichrome staining revealed the same irregularities in the dentinal tubules previously observed with H&E staining. Additionally, the analysis also confirmed collagen fiber disorganization within the dentin, highlighting abnormal distribution patterns (Fig. 4).

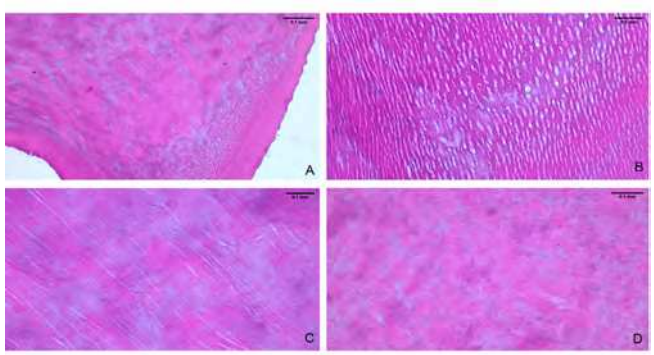

Figure 3: (A) Microscopic image of dentinal tissue stained with hematoxylin- eosin (H&E) at 10x magnification, highlighting the general structure and organization of dentinal tubules; (B) Representative photomicrograph of superficial dentinal tubules at 40x magnification, emphasizing the arrangement and characteristics of the outermost dentin layer; (C) Representative photomicrograph of intermediate dentinal tubules at 40x magnification, showing the transition between the superficial and deeper layers, with distinct structural features; (D) Representative photomicrograph of deeper dysplastic dentin at 10x magnification, illustrating the altered morphology and irregularities in the dentinal structure of deeper layers.

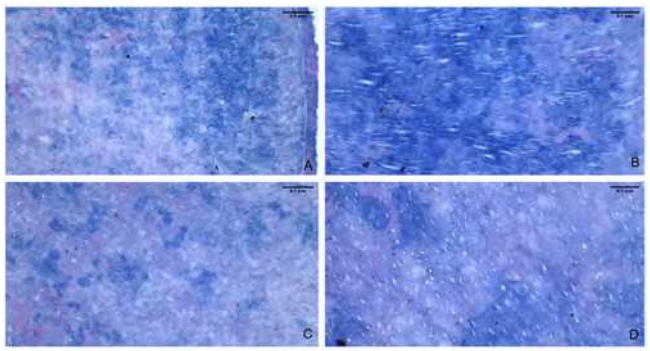

Figure 4: (A) Masson's trichrome staining, illustrating the organization of dentinal tubules at 10x magnification. The staining highlights the structural integrity and arrangement of the dentin matrix; (B) Representative photomicrograph of superficial dentinal tubules at 40x magnification, emphasizing the arrangement and characteristics of the outermost dentin layer; (C) Representative photomicrograph of deeper dentinal tubules at 10x magnification, showing the more central areas of dentin and the density of tubules in this region; (D) Representative photomicrograph of deeper dentinal tubules at 40x magnification, providing a closer view of the structural features and potential alterations in the deeper layers of dentin.

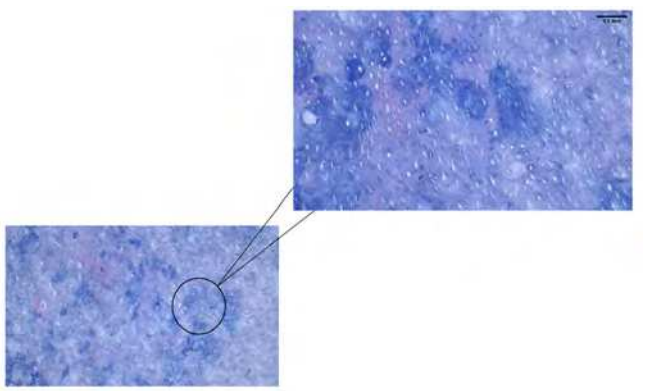

Figure 5: Representative photomicrograph of the innermost layer of dentinal tissue, captured at 40x magnification, highlighting the distinctive globular aspect of the dentin. The image shows the characteristic arrangement of dentinal tubules and the granular deposits. Masson's trichrome staining was used for the histological analysis.

The dentin also exhibited a globular appearance, characterized by rounded, granular structures dispersed within the dentin matrix This irregular configuration may lead to impaired mineralization, making the dentin more prone to fractures and wear over time (Fig. 5).

Confocal laser microscopy analysis also revealed an anomalous dentin structure characterized by areas of irregular calcification and disordered tubules (Figs. 6A and 6B). Most of the dentin exhibited an atypical organization (Fig. 6C), but some areas showed more uniform and more clearly defined dentinal tubules (Fig. 6D). Additionally, the

globular pattern observed with Masson's trichome staining was likewise identified (Fig. 6E).

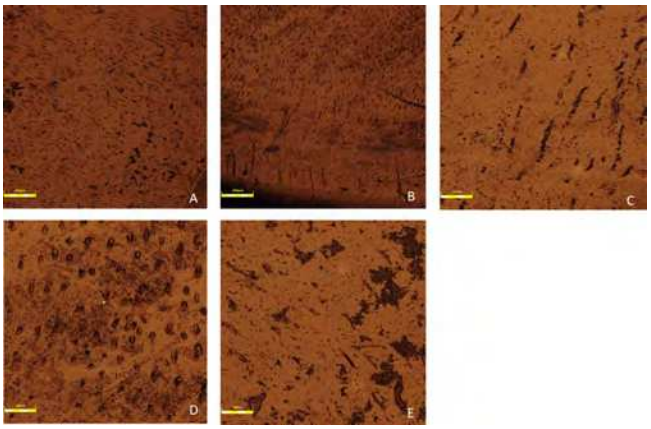

Figure 6: (A and B) Confocal microscopy image demonstrating areas of irregular calcification in the dentin matrix, with disorganized tubules and variable spacing; (C) Detailed observations of disordered tubules and failures in dentin organization, as evidenced by confocal microscopy; (D) Confocal microscopy revealing a more regular and organized structure of root dentin, with more clearly defined tubules; (E) Globular characteristics of dentin, as highlighted by Masson's trichrome staining and corroborated by confocal microscopy.

DISCUSSION

Osteogenesis imperfecta is a rare genetic disorder, with an estimated incidence of approximately 1:15,000 to 1:20,000 live births, caused by autosomal dominant mutations in the COL1A1 and COL1A2 genes, which encode type I collagen (). Osteogenesis imperfecta manifests as a generalized connective tissue disorder with phenotypic manifestations that involve various organs, not being limited to the skeletal system, including cardiovascular and pulmonary anomalies, skin fragility, muscle weakness, hearing loss, and DI.[5-13]

Dentin is a mineralized tissue composed of odontoblasts, which synthesize and secrete an extracellular matrix that subsequently undergoes mineralization. This matrix consists mainly of type I collagen (90%) and non-collagenous proteins and lipids (10%).[14, 15]

In this study, we described the case of an 11-year-old female patient with DI associated with osteogenesis imperfecta type I. Despite collagen impairment, clinical manifestations were primarily restricted to the skeletal system and dentin, with no other relevant systemic involvement. The patient's height was below the expected range for her chronological age, and she had a history of multiple bone fractures.

Regarding the oral manifestations of the disease, the patient has been under dental treatment since the age of 6 years. Analysis of the radiographic records revealed marked characteristics of DI, such as bulbous crowns due to significant cervical constriction, short and thick roots, and pulp chamber obliteration.[15, 16]

Although the enamel in teeth affected by DI typically retains normal features, the compromised dentin provides insufficient support, predisposing it to fracture and subsequent dentin exposure. In these cases, the dentin has a softened consistency and may undergo rapid attrition, presenting as a flat surface. Enamel fractures are due to abnormal fragility at the amelodentinal junction, mainly at the incisal edges of anterior teeth and on the occlusal surfaces of posterior teeth.[17, 18] The extracted teeth showed enamel detachment, which resulted in severe dentin wear.

The current literature consistently demonstrates that DI has a more pronounced effect on primary teeth.[10, 15, 16] Our study corroborates this finding, as the patient presented extremely compromised primary molars, requiring extraction. Both clinical and radiographic examinations revealed enamel detachment as a result of changes at the amelodentinal junction, which eventually exposed the hypomineralized dentin and rapidly wore it down through attrition. In contrast, permanent teeth mainly exhibited the characteristic color changes (yellowish opalescent discoloration) observed in DI.

Despite the general preference for conservative approaches in pediatric dentistry, the extent of coronal destruction and advanced root resorption in these teeth led to the recommendation for their extraction. Additionally, the fragility of the remaining dentin, in both primary and permanent teeth, required careful planning and frequent monitoring to prevent further damage and complications, such as rapid attrition and fractures. Another significant challenge was managing the patient's oral health after the extractions, given the abnormal dentin and enamel characteristics present in DI patients, which increase the risk of premature wear.

Several studies have similarly examined the histological characteristics of DI using H&E and Masson's trichrome staining.[12, 19] Remarkably, the dentin was found to be abnormal and disorganized, with dentinal tubules exhibiting irregular shape and variable diameters. Additionally, dentin adjacent to the enamel showed relatively normal histological features, while dentin surrounding the pulp demonstrated greater dysplasia. These findings are consistent with those available in the literature on the histological patterns described for dentin affected by DI.

Because DI type I is characterized by type I collagen dysfunction, dentinal collagen fibers were investigated using Masson's trichrome staining. This staining technique revealed irregular fiber patterns and a glandular appearance of the dentinal tissue, as described in a previous study.[12]

Ibrahim *et al.*[20] investigated the characteristics of dentinal collagen and concluded that type I collagen in dentin affected by DI associated with osteogenesis imperfecta displays altered morphology and distribution patterns. The study revealed a reduction in the diameter of collagen fibrils and a lack of structural reinforcement around the dentinal tubules, which could compromise the mechanical and structural integrity of the affected dentin.[20]

Previous studies using computed microtomography have shown that teeth affected by DI exhibit variability in pulp chamber size, which may present as either enlargement or obliteration.[12] The obliteration of pulp cavities can be attributed to excessive formation of reparative dentin, likely representing a compensatory response to the rapid wear experienced by these teeth.[12] The radiographic analysis of this case revealed pulpal calcification in permanent first molars, while the erupting second molars displayed enlarged pulp chambers.

A distinctive aspect of this study is the use of confocal microscopy to evaluate dentin in teeth diagnosed with DI. Given the limited number of studies utilizing this method, the present study allowed for the acquisition of high-resolution images of the dentinal tubules, offering insights into the disorganization and structural anomalies of the dentin. Confocal microscopy proved particularly valuable for observing the number and irregular morphology of dentinal tubules, as well as areas of granular deposition. These findings are consistent with histological abnormalities previously reported in studies on DI. Despite the high resolution of confocal microscopy, some limitations were noted. One challenge was distinguishing subtle variations in dentin structure, which are not always apparent with this technique. Additionally, its application in routine clinical practice may be restricted given the need for specialized equipment and expertise.

Based on the clinical case of a patient diagnosed with DI type I, from whom two primary molars were extracted and on the microscopic analyses performed, we can conclude that the dentin of teeth affected by DI is structurally abnormal, with a decreased number of dentinal tubules, irregular organization, and variable diameters. Additionally, granular deposits within the dentin and disorganized collagen fibrils were observed. Confocal laser microscopy confirmed the presence of dysplastic dentinal tissue, characterized by disorganized dentinal tubules, areas with a reduced number of tubules, and granular deposition. The microscopic findings confirm that DI type I compromises the dentin structure, affecting tooth function and patient's oral health.

The treatment plan outlined in this case was multidisciplinary and individualized, given the lack of a standardized protocol for patients with DI. Nevertheless, this study may offer guidance for the diagnosis and treatment of patients with similar characteristics and clinical needs. This study underscores the importance of early diagnosis and appropriate management of patients with DI, as structural alterations in the teeth can lead to complications such as fractures and wear, especially in the primary dentition, which is more severely affected. In accordance with best practices for case reports, we acknowledge the limitations of this study and suggest the need for further investigations, including *in vivo* studies to assess the efficacy of new dental treatments and the broader applicability of confocal microscopy in clinical settings.

REFERENCES

1. Shields ED, Bixler D, el-Kafrawy AM. A proposed classification for heritable human dentine defects with a description of a new entity. Arch Oral Biol. 1973;18(4):543-53. **doi:** 10.1016/0003-9969(73)90075-7.

2. Lee Y, Kim YJ, Hyun HK, Lee JC, Lee ZH, Kim JW. Non-Syndromic Dentinogenesis Imperfecta Caused by Mild Mutations in COL1A2. J Pers Med. 2021;11(6):526. **doi**: 10.3390/jpm11060526.

3. Mao J, Wang L, Jiang Y, Cheng H, Li N, Shi S, *et al*. Nanoscopic wear behavior of dentinogenesis imperfecta type II tooth dentin. J Mech Behav Biomed Mater. 2021;120:104585. **doi**: 10.1016/j.jmbbm.2021.104585

4. Barron MJ, McDonnell ST, Mackie I, Dixon MJ. Hereditary dentine disorders: dentinogenesis imperfecta and dentine dysplasia. Orphanet J Rare Dis. 2008;3:31. **doi:** 10.1186/1750-1172-3-31.

5. Marini JC, Forlino A, Bächinger HP, Bishop NJ, Byers PH, Paepe AD, *et al*. Osteogenesis imperfecta. Nat Rev Dis Primers. 2017;3:17052. **doi:** 10.1038/nrdp.2017.52.

6. Palomo T, Vilaça T, Lazaretti-Castro M. Osteogenesis imperfecta: diagnosis and treatment. Curr Opin Endocrinol Diabetes Obes. 2017;24(6):381-388. **doi:** 10.1097/MED.0000000000000367.

7. Rossi V, Lee B, Marom R. Osteogenesis imperfecta: advancements in genetics and treatment. Curr Opin Pediatr. 2019;31(6):708-715. **doi:** 10.1097/MOP.0000000000000813.

8. Deguchi M, Tsuji S, Katsura D, Kasahara K, Kimura F, Murakami T. Current Overview of Osteogenesis Imperfecta. Medicina (Kaunas). 2021;57(5):464. **doi:** 10.3390/medicina57050464.

9. Gallusi G, Libonati A, Campanella V. SEM-morphology in dentinogenesis imperfecta type II: microscopic anatomy and efficacy of a dentine bonding system. Eur J Paediatr Dent. 2006;7(1):9-17.

10. Majorana A, Bardellini E, Brunelli PC, Lacaita M, Cazzolla AP, Favia G. Dentinogenesis imperfecta in children with osteogenesis imperfecta: a clinical and ultrastructural study. Int J Paediatr Dent. 2010 Mar;20(2):112-8. **doi:** 10.1111/j.1365-263X.2010.01033.x.

11. Davis GR, Fearne JM, Sabel N, Norén JG. Microscopic study of dental hard tissues in primary teeth with Dentinogenesis Imperfecta Type II: Correlation of 3D imaging using X-ray microtomography and polarising microscopy. Arch Oral Biol. 2015 Jul;60(7):1013-20. **doi:** 10.1016/j.archoralbio.2015.03.010.

12. Nutchoey O, Intarak N, Theerapanon T, Thaweesapphithak S, Boonprakong L, Srijunbarl A, *et al*. Phenotypic features of dentinogenesis imperfecta associated with osteogenesis

imperfecta and COL1A2 mutations. Oral Surg Oral Med Oral Pathol Oral Radiol. 2021;131(6):694-701. **doi:** 10.1016/j.oooo.2021.01.003.
13. Subramanian S, Anastasopoulou C, Viswanathan VK. Osteogenesis Imperfecta. 2023 Feb 6. In: StatPearls [Internet]. Treasure Island (FL): StatPearls Publishing; 2024. PMID: 30725642.
14. Butler WT, Brunn JC, Qin C, McKee MD. Extracellular matrix proteins and the dynamics of dentin formation. Connect Tissue Res. 2002;43(2-3):301-7. **doi:** 10.1080/03008200290000682.
15. de La Dure-Molla M, Philippe Fournier B, Berdal A. Isolated dentinogenesis imperfecta and dentin dysplasia: revision of the classification. Eur J Hum Genet. 2015;23(4):445-51. **doi:** 10.1038/ejhg.2014.159.
16. Martín-Vacas A, de Nova MJ, Sagastizabal B, García-Barbero ÁE, Vera-González V. Morphological Study of Dental Structure in Dentinogenesis Imperfecta Type I with Scanning Electron Microscopy. Healthcare (Basel). 2022 Aug 2;10(8):1453. **doi:** 10.3390/healthcare10081453.
17. Seow WK. Developmental defects of enamel and dentine: challenges for basic science research and clinical management. Aust Dent J. 2014;59 Suppl 1:143-54. **doi:** 10.1111/adj.12104.
18. Massé L, Etienne O, Noirrit-Esclassan E, Bailleul-Forestier I, Garot E. Dentine disorders and adhesive treatments: A systematic review. J Dent. 2021 Jun;109:103654. **doi:** 10.1016/j.jdent.2021.103654.
19. Schultz KM, Penner CR. A Review of Selected Dental Anomalies With Histologic Features in the Pediatric Patient. Pediatr Dev Pathol. 2023;26(6):572-582. **doi:** 10.1177/10935266231207045.
20. Ibrahim S, Strange AP, Aguayo S, Shinawi A, Harith N, Mohamed-Ibrahim N, *et al*. Phenotypic Properties of Collagen in Dentinogenesis Imperfecta Associated with Osteogenesis Imperfecta. Int J Nanomedicine. 2019;14:9423-9435. **doi:** 10.2147/IJN.S217420.