MULTIDISCIPLINARY AESTHETIC REHABILITATION: CASE REPORT

Juliana Costa Pereira **Baia**[1], Mariángela Ivette Guanipa **Ortiz**[1*], Gustavo Antônio Martins **Brandão**[1], Armando Rodrigues Lopes **Pereira Neto**[1], Jesuina Lamartine Nogueira **Araújo**[1], Cecy Martins **Silva**[1]

[1]School of Dentistry, Federal University of Pará, Belém, Pará, Brazil.

Palavras-chave: Reabilitação Bucal. Estética Dentária. Aumento da Coroa Clínica. Freio Labial. Ortodontia.

RESUMO

Objetivo: Este trabalho visa relatar um caso clínico que realizou a reabilitação estética de um paciente por meio da integração de diferentes especialidades odontológicas (Ortodontia, Periodontia e Dentística). **Relato do Caso**: Paciente do sexo feminino, com 18 anos, recebeu tratamento ortodôntico compensatório para correção de má-oclusão classe II, overbite e overjet acentuados, e diastemas interproximais. Após tratamento ortodôntico, foi realizada uma gengivoplastia para a remoção do excesso de tecido gengival e aumento da coroa dos dentes, e uma frenectomia para a remoção do freio labial anômalo. Após o tratamento periodontal, foi realizado um clareamento dentário de consultório, e o fechamento dos diastemas anterosuperiores e o recontorno da cosmética dos dentes com resinas compostas microhíbridas. **Conclusão**: Concluiu-se que o planejamento integrado multiprofissional possibilitou o êxito da reabilitação estética/funcional do paciente.

Keywords: Mouth Rehabilitation. Dental Esthetics. Crown Lengthening. Labial Frenum. Orthodontics.

ABSTRACT

Objective: This work aims to report a clinical case that performed the aesthetic rehabilitation of a patient through the integration of different dental specialties (Orthodontics, Periodontics and Dentistry). **Case Report**: An 18-year-old female patient received compensatory orthodontic treatment for correction of class II malocclusion, overbite and overjet, and interproximal diastema. After orthodontic treatment, a gingivoplasty was performed to remove excess gingival tissue and increase the crown of the teeth, and a frenectomy for the anomalous labial frenulum removal. After periodontal treatment the in-office bleaching was conducted, and the diastema was closed with microhybrid composite resins. **Conclusion**: It was concluded that multiprofessional planning made possible the aesthetic / functional rehabilitation of the patient.

Submitted: May 31, 2018
Modification: July 10, 2018
Accepted: July 11, 2018

***Correspondence to:**
Mariángela Ivette Guanipa Ortiz
Address: St Augusto Correa n°1, Guamá, Belém, Pará, Brazil, CEP: 66075-110
Telephone number: (+55 91 989662945) Fixed phone/ (+55 91 99144905) Cell phone
E-mail: mari1791@gmail.com

INTRODUCTION

The appearance of teeth forms part of the overall picture of the facial esthetics, thus dentistry incessantly seeks to meet the esthetic demands of finding a perfect harmony between the white and pink architecture, mainly in the anterior area, which must be pleasant and natural, in order to boost both patient confidence and satisfaction.[1,2]

The equilibrium of the dentogingival relationship is a major factor in the constitution of an esthetic smile and may be related to the extent of the exposed gingival tissue. Exposure of more than 3 cm of gingival tissue when smiling, or short clinical crowns of the anterior superior teeth, generally is regarded as unpleasing for the patient.[1,3] Esthetic periodontal surgeries such as gingivoplasty are usually indicated for resolving these problems.[4]

Another negative factor in self-perceived dental appearance is anterior maxillary diastemas, being a primary concern in dental consultation. For their closure, direct composite restoration is highly promoted, since it conserves more tooth structure, has a lower cost and is reversible. The alternative use of ceramic laminates involves laboratory stages, elevating the treatment's cost as a disadvantage.[2,5] Teeth diastemas along with short clinical crowns cause esthetic discomfort to the patient. Midline diastema, which is treated with a frenectomy, is related to improper attachment of the labial frenum; when associated with other periodontal surgeries such as crown lengthening, it allows closure of the diastema without compromising the symmetrical equilibrium between the width and height of the crown, and without biological space invasion and impairment of periodontal health.[6-8]

This paper aims to present a clinical case report of esthetic rehabilitation of a patient, through the integration of different specialties (orthodontics, periodontics and restorative dentistry).

CASE REPORT

This clinical case was carried out at the School of Dentistry, UFPA. The 18-year-old female patient had previously received compensatory orthodontic treatment for correction of a class II malocclusion, accentuated overbite and overjet, and interincisal diastema (Figure 1). After completion of this treatment, the patient presented 2–3 mm of sulcus depth with a periodontal probe, and absence of inflammation, bleeding, caries or defective restorations. Besides this, anterior short clinical crowns and persisting midline maxillary diastema were present, this last related to an upper labial frenum with low attachment inserted close to the gingival margin, which could cause difficulty for hygiene, loss of the papilla and gingival recession in the area.

To obtain an ideal oral environment and occlusal conditions, esthetic rehabilitation of the anterior teeth was pursued through a dento-facial analysis. The treatment plan consisted of a gingivoplasty surgery on the maxillary anterior region, followed by upper lip frenectomy. Also, tooth bleaching was indicated, with concomitant recontouring of the upper anterior teeth with direct composite resin, for diastema closure. Informed consent was obtained from the patient prior to treatment; the clinical procedures to be performed were detailed, and she agreed to publication of the results, maintaining ethical principles.

Periodontal surgery

A pre-surgical picture of the patient's smile was taken (Figure 2a); subsequently, infiltrative local anesthesia and isolation of the operative field with sterile gaze were performed.



***Figure 1**: Initial intra-oral photos (pre-orthodontic treatment), demostrating increased overbite and overjet, and dental superior diastemas.*

The superior labial frenectomy was initiated by gripping the frenum with a hemostatic forceps and drawing a V-shaped incision on its base with a 15C scalpel blade attached to the scalpel handle (Quinelato, Rio Claro, SP, Brazil). The periosteum was fenestrated at the mucogingival line height, defining the new insertion point for the maxillary labial frenum (Figure 2b). The suture was performed with a 4.0 silk thread (Procare, Rio de Janeiro, RJ, Brazil) (Figure 2c).

After frenectomy, a gingivoplasty surgery was performed, beginning with demarcation of the probe depth so that the external bevel-type incision could be oriented. Through demarcation of bleeding points, the incision was performed with the aid of a 15C scalpel blade (Lamedid Solidor, Osasco, SP, Brazil) along the gingival margin of the superior teeth, from canine to canine (Figure 2d).

The patient was instructed to use a 0.12% chlorhexidine digluconate mouthwash for 14 days. The frenectomy suture was removed within a 7-day postoperative period, and the patient reported great satisfaction with the preliminary results. Weekly post-surgical evaluations were performed during a 30-day period; no complications were reported, and there was complete tissue repair.



Figure 2: (a) Pre-surgical gingival condition, after orthodontic appliance removal (b) V-shaped incision of upper lip frenulum (c) Suture of the incision (d) Gingivoplasty surgery for crown lengthening.

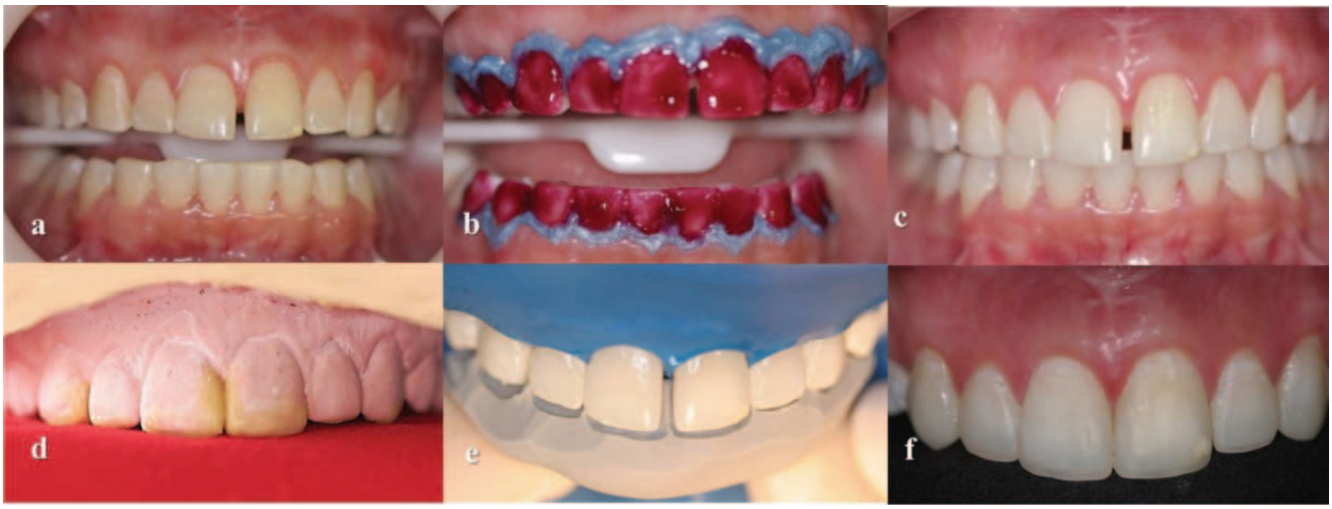

***Figure 3**: (a) 3 months post-surgical gingival condition (b) Isolated field, and application of 35% of hydrogen peroxide, during 45min (c) Teeth after bleaching treatment (d) Wax-up of the model, to create a silicon guide (e) Silicon guide in position, operative field isolated with rubber dam (f) Teeth before the finishing and polishing steps.*

Tooth bleaching

Three months after the surgery (Figure 3a), a prophylaxis with bristle brushes and water/pumice paste was performed (S.S. White, São Cristovão, RJ, Brazil). Then, the initial color (A3/2M2) of the patient's teeth was selected using a spectrophotometer (Easyshade Advance 4.0, Vita Zahnfabrik, Bad Säckingen, WT, Germany).

The gingival tissue of the teeth to be bleached was isolated using a resinous gingival barrier (Top Dam, FGM, Joinville, SC, Brazil), that was polymerized for 30 s (Radii-cal, SDI, Bayswater, VIC, Australia). A 35% hydrogen peroxide (HP) solution was applied on the upper and lower incisors, canines and premolar teeth; three applications of 15 min each were completed, for a total time of 45 min in one session (Figure 3b).

Three bleaching sessions were performed, with a 7-day interval between them. At the end of every session, the teeth were polished with polish paste (Diamond Excel, FGM, Joinville, SC, Brazil) and felt discs (Diamond Flex, FGM, Joinville, SC, Brazil), followed by application of a nanohydroxyapatite-based desensitizing agent (Desensibilize Nano P, FGM, Joinville, SC, Brazil), for 10 min.

Restorative procedure

Thirty days after the end of the tooth-bleaching sessions (Figure 3c), the anterior upper teeth were submitted to re-anatomization. After alginate impression to obtain diagnostic casts, a diagnostic wax-up was performed (Figure 3d); using the golden ratio as a reference, a silicone guide was made to orientate execution of the restorations (Figure 3e).

Absolute isolation of the operative field was performed with a rubber dam. The enamel surface was roughened with a number 3203 diamond-coated bur (KG Sorensen, Cotia, SP, Brazil) on high speed. The adhesive protocol involved 37% phosphoric acid etching (Condac 37, FGM, Joinville, SC, Brazil) for 15 s, followed by the application of a thin and homogeneous adhesive layer (Ambar, FGM, Joinville, SC, Brazil) that was photo-activated for 20 s (Radii-cal, SDI, Bayswater, VIC, Australia).

Microhybrid resins (Opallis, FGM, Joinville, SC, Brazil) were used for the composite resin stratification process which was started by making up the incisal edge with T-Neutral shade (Opallis, FGM, Joinville, SC, Brazil), allowing visualization of its characteristic translucency and incisal third nuances. Opaque White resin (Opallis, FGM, Joinville, SC, Brazil) served for opacification and hiding the black background. For enamel, EA2 (Opallis, FGM, Joinville, SC, Brazil) was inserted, without extending to the area corresponding to the incisal edge, to reproduce the mamelon shape, while DA2 was used for dentin reproduction.

To complete the restorative stage (Figure 3f), fine- and extra-fine-grained diamond-coated burs (2135F and 2135FF, KG Sorensen, Cotia, SP, Brazil) were used, and the polishing was done with the aid of diamond paste for composites (Diamond Excel, FGM, Joinville, SC, Brazil), with sand paper discs (Diamond Pro, FGM, Joinville, SC, Brazil) and felt discs (Diamond Flex, FGM, Joinville, SC, Brazil). Finally, the clinical aspects before and after the esthetic rehabilitation are shown in Figure 4a and b.



***Figure**: 4 (a) Initial smile, after orthodontic appliance removal (b) Smile after the multidisciplinary esthetic rehabilitation treatment.*

DISCUSSION

In the present clinical case, the patient was unsatisfied with her smile, even though orthodontic treatment had improved the overbite and overjet, as well as her facial profile. It has been noticed that in a great number of cases, an esthetically acceptable outcome cannot be obtained through an isolated orthodontic approach. Generally, adjunctive periodontal or restorative procedures are required to accomplish an ideal result.[8] Clinically, it was possible to establish some considerations that led to the indication of gingivoplasty surgery associated with frenectomy and bleaching of the anterior teeth, along with esthetic re-anatomization.

The characteristic diastema of the upper labial frenum is naturally closed after the upper lateral incisors and permanent canines erupt. In cases where closure does not occur, the inferior position of an anomalous frenum can be related to the diastema.[9,10] There is no consensus in the literature about whether maxillary labial frenum hypertrophy is the cause or consequence of midline diastema, or about the ideal intervention period.[7] Frenum hypertrophy could be an etiological factor for re-opening of the diastema, after orthodontic treatment is concluded. Furthermore, it interferes with the patient's esthetics and phonetics.[11]

Midline diastema usually involves orthodontic treatment, in which the forces act by depriving blood vascularization of the transseptal fibers, and new fibers are formed to replace the old ones destroyed by the induced ischemia. Removal of the hypertrophic frenum after the conclusion of orthodontic treatment is suggested, as the newly developed tissues should contribute to the stability of the final result.[12,13] In this clinical case, the frenectomy was performed 2 weeks after conclusion of the orthodontic treatment, as the frenum remained inferiorly positioned and it could have induced an alteration of oral health integrity.

A gingival smile is caused by excessive tissue partially covering the anatomical crown of the teeth, or by altered passive eruption. Gingival surgery is recommended in order to position the gingival margin more apically, without exposing the root surface, observing the amount of keratinized gingiva and the relationship between the cementoenamel junction, gingival margin and the crest of the alveolar bone. Gingivoplasty leads to excellent results, quickly restoring the dentogingival esthetic sought by the patient, through a simple and ambulatory procedure, with local anesthesia.[14]

Besides orthodontic treatment, anterior teeth diastemas can also be solved with direct restorations, without increasing the treatment cost, allowing a quick solution for the esthetic inconvenience caused by the presence of atypical interproximal spaces. Depending on some factors such as the number and the size of the diastemas, direct adhesive restorations may represent an excellent treatment option. However, it is important to establish a treatment plan and determine the cause of the diastemas; they are not recommended when there is ample space between the teeth, because it will not offer a natural solution to the patient.[15,16]

In order to have long-lasting restoration, suitable bonding between the adhesive materials and the dental substrate is required. The polymerization reaction for this adhesion process to be successful is affected by residual oxygen release following the dental bleaching process, as a consequence of the bleaching agent and free radicals being in contact with the monomers, hindering the polymerization reaction and clinically interfering with the restorations.[17,18] For this reason, in the present clinical case, the waiting time for diastema closure and esthetic recontouring was 21 days after the end of the bleaching therapy, as this is the recommended time for complete elimination of the remaining oxygen.

CONCLUSION

Among the varied options to accomplish an esthetic improvement in tooth smile, most cases should be multidisciplinarily addressed in order to develop a treatment protocol that attends to the individual characteristics of the patient, as well as their expectations regarding clinical success. The present clinical case demonstrated that the periodontal plastic associated with direct re-anatomization

and tooth bleaching constitutes esthetic and functional rehabilitation of the patient's smile.

ACKNOWLEDGMENTS

The authors would like to thank the Pro-Rectory of the University Extension of the Federal University of Pará (Proex-UFPa).

REFERENCES

1. Al-Harbi F, Ahmad I. A guide to minimally invasive crown lengthening and tooth preparation for rehabilitating pink and white aesthetics. BDJ. 2018 Feb 23;224(4):228-34. doi: 10.1038/sj.bdj.2018.121.

2. Hwang S, Ha J, Jin M, Kim S, Kim Y. Diastema closure using direct bonding restorations combined with orthodontic treatment: a case report. Restor Dent Endod. 2012 Aug;37(3):165-69. doi: 10.5395/rde.2012.37.3.165.

3. Marques L, Capuano A, Macahdo JG, Belmonte GC, Daher MCV. Reanatomização cosmética associada à cirurgia plástica periodontal, relato de caso clínico. Salusvita. 2012;31(2):169-81.

4. Izolani NO, Molero VC, Goulart RM. Frenectomia: revisão de literatura. Uningá Review. 2014 Apr;18(3):21-5.

5. Romero M, Babb C, Brenes C, Haddock F. A multidisciplinary approach to the management of a maxillary midline diastema: A clinical report. J Prosthet Dent. 2018 Apr;119(4):502-05. doi: 10.1016/j.prosdent.2017.06.017.

6. Bezerra RB, Pitta LDAP, Silva DMD, Silva EVFD. Reabilitação estética e funcional do sorriso: relato de caso clínico. Rev Odontol Arac. 2014;35(1):34-7.

7. Wheeler B, Carrico CK, Shroff B, Brickhouse T, Laskin DM. Management of the Maxillary Diastema by Various Dental Specialties. J Oral Maxillofac Surg. 2018 Apr;76(4):709-15. doi: 10.1016/j.joms.2017.11.024.

8. Vinod K, Reddy YR, Reddy VP, Nandan H, Sharma M. Orthodontic–periodontics interdisciplinary approach. J Indian Soc Periodontol. 2012 Jan;16(1):11–5. doi: 10.4103/0972-124X.94597.

9. Suter VG, Heinzmann AE, Grossen J, Sculean A, Bornstein MM. Does the maxillary midline diastema close after frenectomy?. Quintessence Int. 2014 Jan;45(1):57–66. doi: 10.3290/j.qi.a30772.

10 Delli K, Livas C, Sculean A, Katsaros C, Bornstein MM. Facts and myths regarding the maxillary midline frenum and its treatment: A systematic review of the literature. Quintessence Int. 2013 Feb;44(2):177–87. doi: 10.3290/j.qi.a28925.

11.Koora K, Muthu MS, Rathna PV. Spontaneous closure of midline diastema following frenectomy. J Indian Soc Pedod Prev Dent. 2007 Mar;25(1):23-6. doi: 10.4103/0970-4388.31985.

12.Chaubey KK, Arora V K, Thakur R, Narula IS. Perio-esthetic surgery: Using LPF with frenectomy for prevention of scar. J Indian Soc Periodontol. 2011 Jul;15(3):265–9. doi: 10.4103/0972-124X.85672.

13.Proffit WR, Fields HW, Sarver DM, Ackermannn JL. Contemporary Orthodontics. 5th ed. St Louis: Elsevier Mosby. 2013.

14.Storrer CL, Valverde FK, Santos FR, Deliberador TM. Treatment of gummy smile: Gingival recontouring with the containment of the elevator muscle of the upper lip and wing of nose. A surgery innovation technique. J Indian Soc Periodontol. 2014 Sep;18(5):656–60. doi: 10.4103/0972-124X.142468.

15.Sundfeld RH, Machado LS, de Oliveira FG, Santos EA, Lugato IC, Sundfeld Neto D. Conservative reconstruction of the smile by orthodontic, bleaching, and restorative procedures. Eur J Dent. 2012 Jan;6(1):105-9.

16.Prabhu R, Bhaskaran S, Prabhu KRG, Eswaran MA, Phanikrishna G, Deepthi B. Clinical evaluation of direct composite restoration done for midline diastema closure - long-term study. J Pharm Bioallied Sci. 2015 Aug;7(2):559–62. doi: 10.4103/0975-7406.163539.

17.Khoroushi M, Mazaheri H, Manoochehri A. Effect of CPP-ACP application on flexural strength of bleached enamel and dentin complex. Oper Dent. 2011 Jul-Aug;36(4):372–9. doi: 10.2341/10-280-L.

18.Kavitha M, Selvaraj S, Khetarpal A, Raj A, Pasupathy S, Shekar S. Comparative evaluation of superoxide dismutase, alpha-tocopherol, and 10% sodium ascorbate on reversal of shear bond strength of bleached enamel: An in vitro study. Eur J Dent. 2016 Jan-Mar;10(1):109-15. doi: 10.4103/1305-7456.175693.