IDIOPATHIC EXOSTOSIS: RARITY ON MAXILLARY SINUS

Vanessa de Araújo **Faria**[1]*, Felipe Pinheiro **Vilela**[2], Gabriel Campos **Wendich**[2], Marlivia Gonçalves de Carvalho **Watanabe**[3], Juliano Abreu **Pacheco**[4] , Helena de Freitas Oliveira **Paranhos**[4], Elza Maria Carneiro Mendes Ferreira **Santos**[5], Plauto Christopher Aranha **Watanabe**[3]

[1]Master in Oral Diagnosis at the Oral Diagnosis Course, Dentistry College of São Paulo, University of São Paulo, SP, Brazil.
[2]Undergraduate student of Dentistry at the School of Dentistry of Ribeirão Preto - University of São Paulo, SP, Brazil.
[3]Department of Stomatology, Collective Health and Legal Dentistry of the School of Dentistry of Ribeirão Preto, University of São Paulo, SP, Brazil.
[4]Department of Dental Materials and Prosthodontics of the School of Dentistry of Ribeirão Preto, University of São Paulo, SP, Brazil.
[5]Radiologist, Master's degree in Image Science and Medical Physics of Ribeirão Preto Medical School at the University of São Paulo, SP, Brazil.

Palavras-chave: Exostose. Radiografia Panorâmica

RESUMO

Introdução: Exostoses nos seios paranasais têm sido muito mais relatados na literatura radiológica odontológica, apesar da extensa citação na literatura otorrinolaringológica. **Objetivo:** Neste relato de caso, encontramos uma exostose idiopática rara, que cresceu no seio maxilar. **Relato de caso:** Paciente negra de 68 anos, BGS, acompanhada pelo Serviço de Odontologia do Hospital do Câncer para tratamento de lesões orais (mucosite) e outras condições decorrentes da radioterapia e terapia hormonal (Tamoxifeno), apresentou neoplasia maligna da mama direita em 2015. Não foi realizada biopsia da exostose, pois a paciente está em tratamento e está sendo acompanhada pelo serviço do hospital. Realizaram-se radiografia panorâmica e exame clínico. Ao examinar os exames, foi possível notar uma imagem com dupla radiodensidade, mais radiopaca numa parte externa e menos radiopaca na parte interna, com aspecto de osso trabecular, circunscrito, unilocular, na região do pré-molar pediculado, no interior do seio maxilar esquerdo. Para melhor avaliação e hipótese diagnóstica, foi realizada uma tomografia computadorizada, aplicou-se uma ferramenta para mensuração da densidade do perfil da lesão, evidenciando-se que a suposta lesão invagina para o interior do seio maxilar e tinha densidade óssea semelhante ao osso da crista alveolar. **Conclusão:** Simultaneamente a outras lesões, as exostoses são lesões benignas, apresentam baixa agressividade e rara sintomatologia, sendo indicada exérese somente quando acomete a função, ou por motivos estéticos, ou quando não é possível a confecção de próteses. Muitos dos casos são diagnosticados de modo incidental e a partir de exames radiográficos de rotina em consultórios médicos ou odontológicos e devem ser acompanhados para análise e verificação de seu crescimento.

Keywords: Exostosis. Panoramic Radiography.

ABSTRACT

Introduction: Exostoses in the paranasal sinuses have been reported in a greater number in the dental radiological literature, despite the extensive citation in the otorhinolaryngology literature. **Objective:** This case report was a rare idiopathic expression that grew in the maxillary sinus. **Case report:** A 68-year-old black patient, BGS, followed up by the Odontology Service of Cancer Hospital for treating oral lesions (Mucositis) and other conditions resulting from radiation therapy and hormone therapy (Tamoxifen), presented malignant neoplasm at the right breast in 2015; an exostosis biopsy was not performed, since the patient is being treated and followed up by the hospital service. Panoramic radiography and clinical examination were performed. By analyzing the tests, it was possible to notice an image with double radiodensity, more radiopaque in the external portion and less radiopaque in the internal portion, with an aspect of trabecular bone, circumscribed, unilocular, in the region of pedunculated premolar, inside the left maxillary sinus. In order to have a better assessment and diagnostic hypothesis of the case, a CT scan was performed, a tool was applied to measure the density of the profile of the lesion, thus evidencing that the supposed injury invaginates to the interior of the maxillary sinus and had bone density similar to the alveolar crest bone. **Conclusion:** Simultaneously to other lesions, exostoses are benign lesions, present low aggression and rare symptomatology; exeresis is indicated only when it prevents functioning, or for aesthetics reasons, or when it is not possible to make prostheses. Many cases are incidentally diagnosed from routine radiographic review in medical or dental offices and should be followed up for analysis and verification of their growth.

Submitted: August 28, 2018
Modification: Mach 20, 2019
Accepted: April 10, 2019

***Correspondence to:**
Vanessa de Araujo Faria
Address: University of Sao Paulo .
Avenue of Coffe s/n, Ribeirao Preto, Sao Paulo, SP, Brazil.
Zip code : 14040904
Telephone Number: +55 (16)33153993
E-mail: nessaforp78@yahoo.com.br

INTRODUCTION

Despite the extensive citation in otorhinolaryngology literature, exostoses in the paranasal sinuses have been very few described in dental radiological literature. Exostoses are benign growths, which affect 20% to 25% of native bones, what is called torus, and 5% to 29% of long bones. Although they may appear in any bone of the human skeleton, they rarely appear in facial bones, except for the mandible and maxilla.[4] These bone changes are most often found in adulthood. Within the age group of subjects who are 60 years old or more, the rate is 21.5%; in comparison with a group of subjects aged 13 to 19 years old, the rate is 7.8%. The other age groups—20 to 29 years old, 30 to 39 years old, 40 to 49 years old, and 50 to 59 years old—have demonstrated a similar frequency. When it comes to sex, prevalence is higher among men.[22] Some authors have reported cases of exostoses in patients undergoing nasal irrigation therapy, thus correlating a cold temperature with a possible onset of exostosis.[23]

The etiology and mechanisms of oral exostoses are unclear and there is no consensus among the investigators. Various authors have suggested several etiological factors such as genetic traits, en- vironmental factors, mastication and occlusal stress, inflammation, systemic diseases, and the post- menopausal period. Some authors emphasized a possible autosomal dominant inheritance with a lower penetrance, whereas other authors have reported a correlation between oral exostoses and bruxism, temporomandibular dysfunction and inflammation of gingival tissue.[19]

The need for diagnostic evaluation is essential because exostosis becomes, depending on the clinical planning of the case, a limiting and impeding factor, such as for the preparation of a prosthesis or implant. It is important to make the differential diagnosis of exostosis with osteoma and bone sclerosis.[2,3,5,6,]

A panoramic radiography is the main resource to obtain a view of the entire mouth, including the maxilla and mandible, as well as the surrounding bone structures. It is quite often the first-choice test to evaluate the maxillary sinuses, as it enables one to evaluate the size, pneumatization and findings inside them.[7,28] Despite its importance as a diagnostic aid, radiographic examination must not be indistinctly performed for all individuals, only when the patient's history or their signs and symptoms suggest this need and when the information it offers is of great use.[9,13,14] However, a three-dimensional image may be necessary, such as CBCT obtained in axial sections (the interval between the cuts is variable), in order to increase the accuracy of the images, enabling better diagnosis and planning.[11,14,15,30]

With the use of panoramic radiography in the daily dental practice, many alterations are incidentally discovered (radiographic findings), especially the silent ones. This raises the diagnostic hypothesis wherefrom it is necessary to further research the patient's history, performing complementary tests, such as volumetric tomography which will show size, the relation with adjacent structures, and limits in the three axial, coronal and sagittal projections. This leads to a more accurate planning, and a better assessment of the need for a biopsy, in order to interfere or not in the clinical planning of the case. This article aims at describing an idiopathic and rare case of bilateral exostosis obtained by cone beam computed tomography—CBCT.[1,12,23,24,25]

CASE REPORT

A black 68-year-old female patient, BGS, followed up by the Dentistry Service of Cancer Hospital to treat oral lesions (mucositis) and other conditions resulting from radiotherapy and hormone therapy (Tamoxifeno), presented malignant right-breast neoplasm in 2015. Surgery for tumor removal and axillary lymph nodes dissection was performed in 2016, followed by 12 sessions of radiotherapy, which were finished in January, 2017. The patient takes Tamoxifeno (initiated after the surgical treatment of the second tumor), Diazepam, Haldol, lithium, captropil, and insulin; she does not perform nasal irrigation, presents diabetes mellitus, depression, psychotic episodes, bipolar disorder, and hypertension; she has a complete upper denture and presents teeth 33, 32, 31, 41, 42, and 43 with indication of tooth extraction; the presence of mucositis in the palate was verified after a clinical examination.

As a treatment protocol, patients who will undergo cancer treatment at Cancer Hospital have a panoramic radiography performed, in order to care for their oral health and evaluate the general conditions of their teeth and maxillomandibular complex. This is done to preventively suggest a dental treatment that will improve their oral conditions to continue radiotherapy. After the panoramic radiographic examination (Fig. 1), it was possible to notice an image with a double radiodensity, more radiopaque in the external portion and less radiopaque in the internal portion, with an aspect of trabecular bone, circumscribed, unilocular, in the region of pedunculated premolar, inside the left maxillary sinus. The diagnostic hypotheses included: A dental element inside the sinus—it could simply be a residual root; calcified masses present in the paranasal sinuses, usually found in the maxillary or nasal cavities and often surrounded by inflamed mucosa,[19] it was also possible that the origin was endogenous, such as bone sequestration; and it could yet be blood products, such as thrombus and teeth; or exogenous, such as foreign bodies, benign and asymptomatic;[16] there was also the possibility of exostosis. To better define the diagnosis, a cone beam computed tomography (CBCT) was performed.

This raises the diagnostic hypothesis wherefrom it is necessary to collect further information on the patient's history, performing complementary tests, such as volumetric tomography to visualize size, the relation with adjacent structures and boundaries on all three axial, coronal and

sagittal projections, in order to plan more accurately and assess for the need of a biopsy. This may or may not interfere with in the clinical planning of the case.

Antral exostoses generally do not require surgical approaches. A biopsy examination is not usually suggested, unless the antral exostosis causes clinical symptoms and leads to sinonasal ob- struction. However, a biopsy could be useful in some patients with an inconsistent history or noncharacteristic-appearing lesions.[12]

Radiographic Interpretation in CBCT

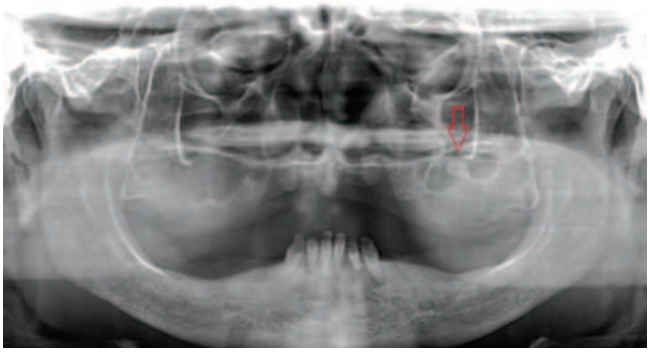

Figure 1: *Panoramic radiograph in centric occlusion, occlusal plane parallel to the ground, and median line* ***upright*** *to the occlusal plane, where the pedunculated image is observed inside the left maxillary sinus.*

Three-dimensional CBCT reveals an aspect of bone trabeculation inside the pedicle, not different from the other aspects of the bone tissue of the region, wrapped in a supposed cortical bone (hyperdense sign). This image was seen in parasagittal sections (Figure 2), and axial, coronal and 3D sections (Figure 3). Imaging Studio - Anne Solutions Version 3.401.

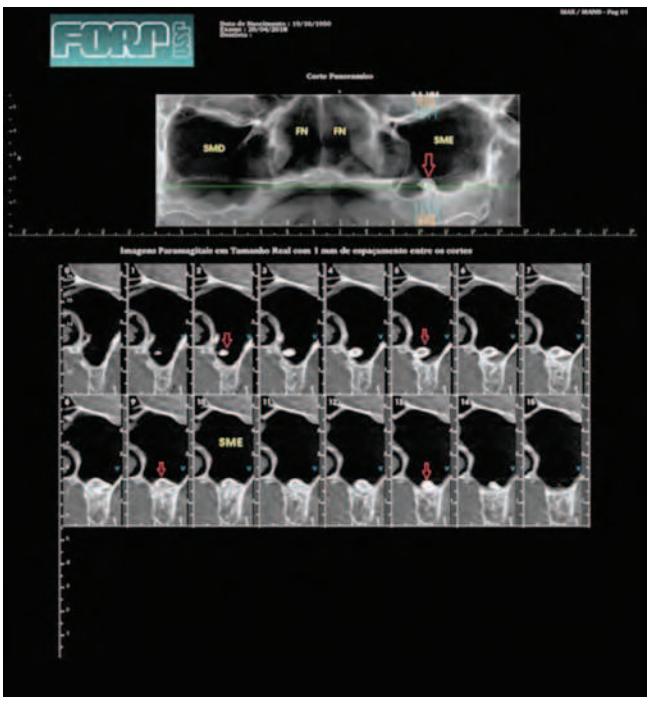

Figure 2*: Tomography - Panoramic and Parasagittal Section and it is possible to see the pedunculated situation of the lesion.*



Figure 3 : *Tomography - Axial, coronal and 3D sections and 3D images CTBC - axial section, coronal section and 3D section. Jaw, left side. CTCB - panoramic section and sagittal section, spaced 1mm between sections. Jaw, left side.*

The coronal tomographic section was obtained using an Imaging Studio software – Anne Solutions Version 3.401 profile line tool under a longitudinal axis, covering from the thickened cortex of the maxillary sinus to the alveolar cortical bone; wherefrom we selected 4 points, from 1 to 4, as described below (Figure 4), evidencing that the supposed injury, which invaginates to the interior of the maxillary sinus, had bone density similar to the bone of the alveolar ridge:

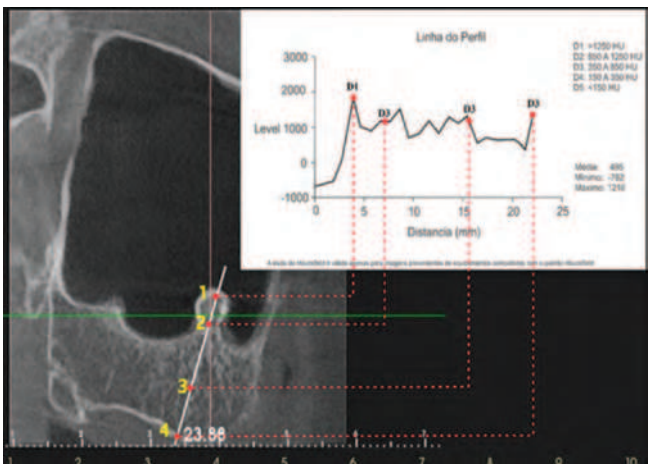

Figure 4*: Tomography - Coronal Section – It is possible to see a tool to measure the density profile of the lesion, which evidences that the supposed injury, which invaginates to the interior of the maxillary sinus, had bone density similar to the bone of the alveolar ridge.*

Tomography OP300. Voxel 0.16. FOV11x11. Imaging Studio – Anne Solutions Version 3.401. Profile Line tool

1. Density in the cortical region of the pedicle;
2. Density in the region of the interior of the pedicle;
3. Density in the bone trabecular region, premolar region;
4. Density in the cortical alveolar bone region.

DISCUSSION

Currently, the use of panoramic radiographic shots enables the discovery of radiographic findings and reveals the need for complementary tests. Volumetric tomography appears as the first choice after the panoramic radiography, showing anatomical aspects and assisting in the planning and outcome of the case. The different dental specialties already benefit from the CBCT method in the diagnostic routine, such as endodontics, surgery and implantology, oral diagnosis, surgery and orthodontics.[10]

Among maxillary sinuses inflammatory / infectious diseases, 10 to 12% are of dental origin[18] and the majority is associated with pulp necrosis,[3] periapical disease, advanced periodontal disease and bucco-sinusal communications.[17] In this clinical case, we believe that exostosis is related to environmental factors, such as climate and nutrition, surgical sequelae, and masticatory tension.[21]

A panoramic radiography was initially performed to evaluate the dental and bone conditions of the maxillomandibular complex. Analyzing the test, it was possible to see that there was a change in the maxillary sinus. The radiographic presentation suggested the presence of a possible dental element, or even residual root. These are the most frequent possible conditions; therefore, they are proposed as a complementary examination to CBCT. In the parasagittal sections (Figure 2, sections 9-12) and coronal sections (Figure 3), the connection / bound of the lesion to the bone tissue of the left maxillary alveolar ridge is evident, where it is possible to verify the absence of the inferior cortex of the maxillary sinus (sections 9 to 12), exactly in the lesion pedicle. This has also defined the lesion as exostosis.

There are procedures performed by dental surgeons that may carry foreign bodies into the maxillary sinuses, resulting in infectious and inflammatory conditions, such as the extrusion of endodontic filling materials, endodontic irrigation, implants incidentally displaced to the sinuses, among others. These infections must be properly interpreted and investigated. It has been stated that it is important to identify and X-ray this condition to avoid unnecessary surgical procedures. It is difficult to clinically diagnose them, because of the asymptomatic nature of this condition, unless the approach is through the endoscope.[20] Although there is little information on antral exostoses, some characteristics have been described by Ohba et al. The mean size reported by these authors (4.7 mm × 7.4 mm) was clearly lower than the individual exostoses, surpassing even the highest measurement of the presented cases (2 mm x 1 mm). In this case, surgical removal will not be necessary, because the dimensions are small, there is no impairment of the function of the maxillary sinus or its aesthetics. It should be followed, though, for some possibility of bone growth, which could compromise this sinus structure of the face.

In view of the clinical similarity of osteomata and exostoses, it is important to note that osteoma, as a benign neoplasm, tends to grow continuously. Thus, it may be suggested that such biological behavior differs from that presented by exostosis, which, because it is an anomaly of development, grows during a certain period and then becomes inactive.[6]

Exostoses are benign lesions that appear simultaneously with other lesions, present low aggressiveness and rare symptomatology. Surgical removal is indicated only when it affects the function or due to aesthetic reasons, or when it is not possible to make dentures. They are commonly found in the maxilla or mandible. Many of the cases are diagnosed incidentally and from routine radiographic examinations in medical or dental offices. They should be monitored for analysis and verification of their growth.

CONCLUSION

CBCT is able to identify exostosis through radiopacity. It is important that the image be monitored, in order to aid in the decision making of performing or not any surgical procedure.

REFERENCES

1. Adelson RT, Kennedy DW. Paranasal sinus exostoses: possible correlation with 191 cold temperature nasal irrigation after endoscopic sinus surgery. Laryngoscope 192 2013;123:24–7. 193.

2. Araujo S.E, Kalil K.R, Bertoni F., Park Y.K, Tumors and tumor-like lesions of bone for surgical pathologists orthopedic surgeons and radiologists. Springer 1988.

3. Bell G.W, Joshi B.B, Macleod, R.I. Maxxilary sinus disease: diagnosis and treatment. Br. Dent. J. 2011. Feb; 210(3): 113-8.doi: 10.1038/sj.bdj.2011.47

4. Bernaba JM. Morphology and incidence of torus palatinus and mandibularis in Brasilian Indians. J Dent Res. 1977 May;56(5):499-501.

5. Bolger WE, Butzin CA, Parsons DS. Paranasal sinus bony anatomic variations and 205 mucosal abnormalities: CT analysis for endoscopic sinus surgery. Laryngoscope 206 1991;101:56–64.207.

6. Boros LF, Carneiro MIS, Boros LH, Boros LF, Boros PAS. Osteoma Compacto Central de Mandiìbula: relato de caso cliìnico. Odontologia Cliìn. Cientiìf. Recife, 10(1): 89-93, 2011
7. De Moraes PH, Costa VO, Olate S, Caria PHF, Barbosa JRA. Estudio morfométrico del seno maxilar mediante tomografías computadorizadas. Evaluación de la reconstrucción total del piso sinusal. Int J Morphol 2012;30:592–8.
8. Eggen S. Torus mandibularis: an estimation of the degree of genetic determination. Acta Odontol Scand.1989; 47(6):409-415.
9. DENTAL RADIOGRAPHIC EXAMINATIONS: RECOMMENDATIONS FOR PATIENT SELECTION AND LIMITING RADIATION EXPOSURE. AMERICAN DENTAL ASSOCIATION - Council on Scientific Affairs. REVISED: 2012.
10.Garib, D.G, et al. Tomografia computadorizada de feixe co□nico (Cone beam): entendendo este novo meìtodo de diagnoìstico por imagem com promissora aplicabilidade na Ortodontia.R Dental Press Ortodon Ortop Facial 139 Maringaì, v. 12, n. 2, p. 139-156, mar./abr. 2007
11.Gracco A, Incerti Parenti S, Ioele C, Alessandri Bonetti G, Stellini E. Prevalence 201 of incidental maxillary sinus findings in Italian orthodontic patients: a retro- 202 spective cone-beam computed tomography study. Korean J Orthod 2012;42: 203 329–34. 204.
12. Haffey T, Woodard T, Sindwani R. Paranasal sinus exostoses: an unusual com- 186 plication of topical drug delivery using cold nasal irrigations. Laryngoscope 187 2012;122:1893–7. 188.
13. Hahnel S, Ertl-Wagner B, Tasman AJ, Forsting M, Jansen O. Relative value of MR 208 imaging as compared with CT in the diagnosis of inflammatory paranasal sinus 209 disease. Radiology 1999;210:171–6. 210.
14. Lana JP, Carneiro PM, Machado VdeC, de Souza PE, Manzi FR, Horta MC. 178 Anatomic variations and lesions of the maxillary sinus detected in cone beam 179 computed tomography for dental implants. Clin Oral Implants Res 2012;23: 180 1398–403. 181
15. Lofthag-Hansen S, Huumonen S, Grondahl K, Grondahl HG. Limited cone-beam 196 CT and intraoral radiography for the diagnosis of periapical pathology. Oral Surg 197 Oral Med Oral Pathol Oral Radiol Endod 2007;103:114–9. 198.
16. Madani G, Beale T.J. Differential diagnosis in sinonasal disease. Semin Ultrasound CT MR. 2009. Feb; 30 (1): 39-45. Doi: 10.1053/j.sult.2008.10.014.
17. Mafee M.F, Tran B.H, Chapa A.R.Imaging of rhino sinusitis and its complications: plain film, CT, and MRI. Clin.Rev Allergy Immune.2006. Jun;30(3): 165-86.doi:10.1385/CRIAI:30:3:165. 238-43.doi: 10.1007/s11882-009-0035-0.
18. Mehra P, Jeong D. Maxillary sinusitis od odontogenic origin. Curr Allergy Asthma Rep 2009. May:9(3):
19. Mossa-Basha M, Blitz A.M. Imaging of the paranasal sinuses. Semin Roentgenol.2013.Jan:48(1): 14-34. doi: 10.1053/j.ro.21012.09.006
20. Ohba T, Langlias RP, Langland OE. Antral exostosis in panoramic radiographs. 182 Oral Surg Oral Med Oral Pathol 1993;76:530–3. 183.
21. Ossenberg, N. S. Mandibular torus: a synthesis of new and previously recorded data and a discussion of its cause. In: CYBULSKI, J. S. Contribution to physical antropology, 1978/1980. Ottawa: National Museum of Canada, 1981, p. 52.
22. Pynn BR1, Kurys-Kos NS, Walker DA, Mayhall JT. Tori mandibularis: a case report and review of the literature. J Can Dent Assoc. 1995 Dec;61(12):1057-8, 1063-6.
23. Ramakrisshnan JB, Pirron JA, Perepletchikov A, Fergusson BJ. Exostoses of the paranasal sinuses . Laryngoscope 2010;120:2532-4.
24. Ramakrishnan JB, Pirron JA, Perepletchikov A, Ferguson BJ. Exostoses of the 184 paranasal sinuses. Laryngoscope 2010;120:2532–4. 185.
25. Ritter L, Lutz J, Neugebauer J, Scheer M, Dreiseidler T, Zinser MJ, et al. Preva- lence of pathologic findings in the maxillary sinus in cone-beam computerized tomography. Oral Surg Oral Med Oral Pathol Oral Radiol Endod 2011;111:634–40.
26. Schwartz K, Eckel L, Black D, Lehman V, Diehn F, Hunt C, et al. Irrigation nose: 189 CT findings of paranasal sinus exostoses. Open Neuroimag J 2012;6:90–1. 190.
27. Shah RK, Dhingra JK, Carter BL, Rebeiz EE. Paranasal sinus development: a radio- 199 graphic study. Laryngoscope 2003;113:205–9. 200.
28. Siegel WM, Pappas JR. Development of exostoses following skin graft vestibuloplasty: report of a case. J Oral Maxillofac Surg. 1986 Jun;44(6):483-4.
29. Torres, I. A. et al; Pseudotoro Mandibular e Toros Mandibulares. v.18, n.1, p.47, 1999.
30. Vallo J, Suominen-Taipale L, Huumonen S, Soikkonen K, Norblad A. Prevalence 211 of mucosal abnormalities of the maxillary sinus and their relationship to dental 212 disease in panoramic radiography: results from the Health 2000 Health Exam- 213 ination Survey. Oral Surg Oral Med Oral Pathol Oral Radiol Endod 2010;109: 214 e 80–7.
31. Watanabe PCA, Arita ES. Imaginologia e Radiologia Odontológica. 1st ed. Rio de 194 Janeiro: Elsevier; 2012. p. 45–54. 195.