IMAGINOLOGICAL EXAMS OF THE FRONTAL SINUS IN HUMAN IDENTIFICATION

Fernanda Nogueira **Reis**[1*], Andreia Cristina Breda de **Souza**[2], Maria Augusta **Visconti**[3]

[1] Department of Oral Diagnosis, Universidade Estadual de Campinas, Piracicaba, SP,Brazil
[2] Department of Social and Preventive Dentistry, Universidade Federal do Rio de Janeiro, Rio de Janeiro- RJ, Brazil
[3] Department of Pathology and Oral Diagnosis, Universidade Federal do Rio de Janeiro, Rio de Janeiro- RJ, Brazil

Palavras-chave: Seio Frontal. Radiologia Forense. Odontologia Legal. Identificação Humana

RESUMO

Introdução: A identificação humana é o processo pelo qual se estabelece a identidade de um indivíduo por meio da comparação entre dados registrados em momentos diferentes. Tratando-se do crânio humano, as regiões mais utilizadas na individualização do mesmo são as áreas da sela túrcica, no osso esfenoide, as células mastoides e o seio frontal. **Objetivo:** O presente trabalho teve como objetivo, através de uma revista da literatura, identificar e descrever as principais técnicas desenvolvidas para a identificação humana, a partir de exames de imagens dos seios frontais, em virtude da contribuição em potencial da radiologia odontológica nesse contexto. **Fonte de dados:** Para isso, foi realizada uma busca bibliográfica, no PUBMED, a partir do uso das seguintes terminologias: *frontal sinus, radiology* e *forensic*. Foram incluídos os artigos publicados entre 2007 e 2017 e excluídos artigos de revisão de literatura, cartas e relatos de caso. **Síntese dos dados:** Em um total de vinte e três artigos selecionados analisou-se a amostra quanto à nacionalidade, homogeneidade, sexo e faixa etária dos indivíduos, além dos tipos de exames de imagem que constituíram essa amostra, seja de origem radiográfica ou tomográfica, e suas diferentes projeções e modalidades. Além disso, classificou-se a literatura quanto às diferentes técnicas e parâmetros empregados para a identificação, sejam eles quantitativos ou morfológicos. **Conclusão:** Através desta busca, conclui-se que o perfil da pesquisa científica mundial, voltada para a identificação humana através de exames de imagem dos seios frontais, utiliza amostras homogêneas, de ambos os sexos e ampla faixa etária, empregando-se majoritariamente a Radiografia Extra-oral Póstero-Anterior e parâmetros qualitativos e quantitativos para a identificação.

Keywords: Frontal Sinus Recognition. Forensic Radiology. Forensic Dentistry. Human Identification.

ABSTRACT

Introduction: Human identification is the process by which the identity of an individual is established by comparing data recorded at different times. In the case of the human skull, the most used areas for the individualization are the Turkish Chair, the sphenoid bone, the mastoid cells, and the frontal sinus. **Objective:** The aim of the present work was to identify and describe the main techniques developed for human identification through a literature review, based on imaging of the frontal sinuses, due to the potential contribution of dental radiology in this context. **Sources of data:** For this, a bibliographic search was performed in PUBMED, using the following terminologies: frontal sinus, radiology, and forensic. Articles published between 2007 and 2017 were included, literature articles, letters, and case reports were excluded. **Synthesis of data:** A total of twenty-three articles were selected, the sample was analyzed for the nationality, homogeneity, sex, and age of the individuals, as well as for the types of imaging tests that constituted this sample, whether of radiographic or tomographic origin and their different projections and modalities. In addition, the literature was classified as to the different techniques and parameters used for identification, whether quantitative or morphological. **Conclusion:** After this research, it was possible to conclude that the profile of the world scientific research aimed at human identification through imaging of the frontal sinuses, consists of homogenous samples, of both sexes, and a wide age group, using mostly posteroanterior extraoral radiographic examination and qualitative and quantitative parameters for identification.

Submitted: Febuary 2, 2019
Modification: March 26, 2019
Accepted: March 27, 2019

***Correspondence to:**
Fernanda Nogueira Reis
Address: Avenida Primavera, 375- Vila Areião, Piracicaba, SP- Brazil.
Telephone Number: 55 (21) 97564-8955
E-mail: fernanda.nreis@outlook.com.br

INTRODUCTION

Human identification is the process by which individuals are by comparing data recorded at different times.[1] However, for the method of identification adopted to be reliable, it needs to follow biological and technical requirements. Thus, essential biological requirements must be considered, such as uniqueness, immutability, and permanence, while the technical requirements are based on practicality and classifiability.[1]

In the case of the human skull, the regions most studied for identification, due to their particularities, are the sella turcica in the sphenoid bone, the mastoid cells, and the frontal sinus:[2] The frontal sinus presents with great variation among human beings; it is considered to be one of the most individualistic anatomical structures of the skeleton, in such a way that even monozygotic twin siblings have frontal sinuses which differ in their characteristics.[3] These are pneumatized cavities, which form at around one year of life but become visible in radiographic images between seven and nine years old, reaching its final configuration at 20 years of age.[2] It is important to note that the frontal sinuses are present in 96% of the adult population,[4] and studies in some populations have demonstrated the bilateral absence of the frontal sinuses at a very low frequency, for example, 0.72% in the Turkish sample.[5]

The first reported case of human identification by frontal sinus analysis was dated as 1925, when Culbert and Law used thirteen points that were considered as "sinus impressions", in addition to variations in other accessory sinuses in the Turkish chair and mastoid process.[2] Since then, many researchers have created different frontal sinus classification systems based on techniques to measure the size, volume, and asymmetry of sinuses.[2]

The primary methods of human identification, determined by The International Criminal Police Organization (INTERPOL) protocol, consist of analyzes of fingerprints, odontological characteristics, and DNA (Deoxyribonucleic Acid).[6] Within Forensic Dentistry, the expert has several methods that can aid in the identification of individuals, such as histopathological, radiographic, and immunological methods.[7] Thus, the selection of the most appropriate identification process should be made individually, considering its particularity.[7]

In this field of expertise, dental radiology is of great use in cases of human cadavers in advanced stages of putrefaction, carbonized, or skeletonized, for example, as is often the case in cases of mass disasters.[8] Other conventional methods of identification, such as papillary analysis, are not possible in these conditions because it can only be performed where soft tissues are preserved.[9] In addition, when antemortem dental records are not available or when the teeth are no longer present at post-mortem, an alternative is to use of extraoral imaging tests.[10]

Therefore, the use of computed tomography (CT) is recommended for the evaluation of the paranasal sinuses, since from the three-dimensional and volumetric analyses of the sinuses, the measurements are more accurate compared to conventional radiographs.[8] In addition, the visualization between small differences in tissue densities is more precise, having values of gray intensity assigned to each structure, and there is no overlap of the anatomical structures.[10]

The use of imaging tests in human identification, comparing post-mortem and antemortem data, is already routine in the medicolegal institutes.[11] In view of this, dental documentation, especially intraoral and extraoral radiographs of the craniofacial complex, can support the processes of human identification, in the case of cadavers without an identity confirmed by fingerprints. Therefore, the aim of the present study was to report, through a review of the literature, the main techniques developed for human identification, based on imaging of the frontal sinuses.

MATERIALS AND METHODS

Study design

An integrative literature review was carried out in the PUBMED database, searching for the terms "frontal sinus" AND "radiology" AND "forensic," totaling 70 articles. For inclusion in the review, the full text of the journal needed to be available in English (n = 67), published between 2007 and 2018 (n = 45), and present in its methodology, a correlation between radiographic methods and human identification (n = 38). On the other hand, articles on literature reviews (n = 37), letters (n = 34), and case reports (n = 30) were excluded, as well as articles focusing only on sex determination (n = 23), leaving a sample of 23 articles.

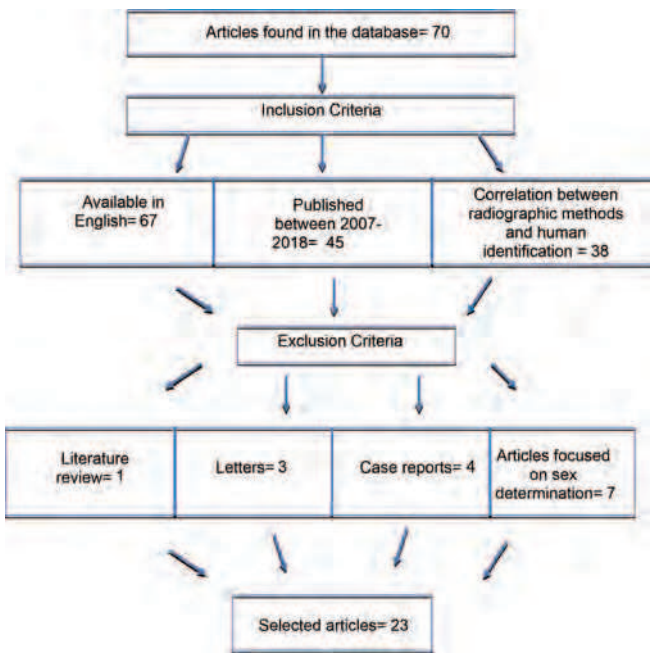

Figure 1: *Flowchart of integrative literature review.*

***Table 1**: Sample characteristics of the articles included in the sample according to the variables studied.*

Authors (Year)	Nationality (sample)	Homogeneity in relation to nationality (sample)	Average age in years (sample)	Sex (sample)	Radiographic exam used	Identification Technique	Parameters
Tatlisumak et al[12] (2007)	Turkish	Homogeneous	44.5	Mixed sample with female prevalence	MSCT	FSS System	Quantitative
Pfaeffli et al[13] (2007)	Swiss	Homogeneous	Uninformed	Uninformed	AP and Lateral Radiographies and MSCT	Superposition	Non-quantitative
Cameriere et al.[14] (2008)	North Irish	Homogeneous	44.5	Mixed sample with male prevalence	PA Radiography	Asymmetry, SS, CUB, PS and SC	Mixed
Tang et al.[15] (2008)	Chinese	Homogeneous	Uninformed	Uninformed	PA Radiography	Asymmetry, CS, height, width, SS, CUB, PS, SC and orbital width ratio	Mixed
Cox et al.[16] (2009)	Peruvian and Canadian	Heterogeneous	Uninformed	Mixed sample with male prevalence	PA Radiography (Caldwell)	A new method for objective morphological comparison	Non-quantitative
Besana et al.[17] (2010)	Canadian	Homogeneous	34.5	Uninformed	PA Radiography	Determine the independence of sinus traits	Quantitative
Uthman et al.[18] (2010)	Iraqi	Homogeneous	Uninformed	Balanced mixed sample	CT (uninformed)	FSS System	Mixed
David et al.[19] (2010)	Indian	Homogeneous	37.5	Balanced mixed sample	PA Radiography	Width, asymmetry	Quantitative
Patil et al.[20] (2012)	Indian	Homogeneous	52	Balanced mixed sample	PA Radiography (Waters)	Shape, NS, width, the distance between the maximum lateral limit and the highest point and between the upper limit, orbital cavities and the highest points	Mixed

***Table 1**: Sample characteristics of the articles included in the sample according to the variables studied.*

Authors (Year)	Nationality (sample)	Homogeneity in relation to nationality (sample)	Average age in years (sample)	Sex (sample)	Radiographic exam used	Identification Technique	Parameters
Kim et al.[21] (2013)	Korean	Homogeneous	25	Mixed sample with male prevalence	CT (uninformed)	Height, width, volume, the distance between the uppermost points, AP depth, AMB, shape, and UEC	Mixed
Nikam et. Al[22] (2015)	Indian	Homogeneous	Above 20	Mixed sample with male prevalence	PA Radiography	Height and maximum width in relation to the different quadrants drawn from a baseline at the margin of the orbits and a tangent line	Quantitative
Hashim et al.[23] (2015)	Malaysian	Homogeneous	Uninformed	Uninformed	Extra oral Radiography (uninformed)	Superposition	Non-quantitative
Beaini et al.[24] (2015)	Brazilian	Homogeneous	27.5	Balanced mixed sample	CBCT	Superposition	Non-quantitative
Cossellu et al.[10] (2015)	Italian	Homogeneous	46.5	Mixed sample with female prevalence	CBCT	Reconstructio, asymmetry, SS, height, width, volume and surface	Mixed
Akhlaghi et al.[25] (2016)	Iranian	Homogeneous	Above 20	Balanced mixed sample	Paranasal CT	Height, width, AP diameter, NS	Quantitative
Soman et al.[26] (2016)	Indian	Homogeneous	Above 14	Balanced mixed sample	PA Radiography	Asymmetry, SS, CUB, PS and SC	Mixed
Rabelo et al.[4] (2016)	Brazilian	Homogeneous	46.5	Mixed sample with female prevalence	Frontal and Lateral Radiographies	FSS System adapted	Mixed
Soares et al.[27] (2016)	Brazilian	Homogeneous	Not applicable	Not applicable	PA and Lateral Radiographies and CBCT	FSS System adapted	Mixed

***Table 1**: Sample characteristics of the articles included in the sample according to the variables studied.*

Authors (Year)	Nationality (sample)	Homogeneity in relation to nationality (sample)	Average age in years (sample)	Sex (sample)	Radiographic exam used	Identification Technique	Parameters
Suman et al.[28] (2016)	Indian	Homogeneous	25	Balanced mixed sample	PA Radiography	Asymmetry, area, SS, CUB, PS and SC.	Mixed
Tatlisumak et al.[29] (2017)	Turkish	Homogeneous	Above 20	Balanced mixed sample	MSCT	Height, width, AP length and volume	Quantitative
Buvuk et al.[3] (2017)	Turkish	Homogeneous	Uninformed	Balanced mixed sample	PA Radiography	Height and width	Quantitative
Verma et al. [30] (2017)	Indian	Homogeneous	24	Balanced mixed sample	PA Radiography	Asymmetry	Non-quantitative
Souza Jr et al. [31] (2018)	Brazilian	Homogeneous	Above 20	Uninformed	CT (uninformed)	Automatic segmentation	Non-quantitative

Synthesis of data

In the 23 articles selected, the different nationalities of the samples obtained were distributed according to the variables described in Table 1. Only four populations were studied in more than one article, with India being the most prominent country. Only one article applied the methodology to individuals of different nationalities, Peruvian and Canadian, worrying about the use of a heterogeneous sample, in order to observe any possible significant differences in the obtained patterns. As for the sample, a broad age group was used in the studies, 14 years old was the youngest age studied. In turn, a sample aged above 20 years old was used in most studies. Among the articles that reported the age group, the average age was found to be 37 years old, 21.7% of the articles reported only the initial age, and 30.4% did not provide information about age.

On the other hand, in relation to the possible differences that could be found between the sexes, all the articles opted to use a mixed sample. In this scenario, almost half of studies, 43.5%, used the same number of imaging exams from men and women, 30.4% used a mixed sample, but there was a prevalence for one sex. The remaining 26.1% did not contain any information about sex, mostly because they came from an archaeological sample of dry skulls.

It is important to mention that all these studies used images of an intact frontal sinus, excluding those of individuals with pathological processes, anomalies, traumas, or a history of orthodontic and surgical treatments that could compromise their anatomy or physiology.

Regarding the imaging tests used, we highlight postoperative extraoral radiography (52.2%), followed by cone-beam computed tomography (13.0%), medical computed tomography (13.0%), and on a smaller scale, other conventional extraoral radiographs.

The methodologies used in each article were divided into two types: metric methods that use quantitative parameters such as height, width, and volume of the frontal sinuses for the evaluation of these structures, and nonmetric or morphological methods that use the frontal sinus in the process of identification, as in the case of the superposition of radiographic images. The data collected in relation to the techniques used for identification in the 23 articles studied showed that the highest percentage was for mixed analysis evaluations that used both metric and morphological parameters (43.5%), followed by those who used only quantitative (30.4%), and finally, those who used non-quantitative variables (26.1%).

DISCUSSION

Regarding the study samples, it could be stated that approaching heterogeneous populations in the same study to evaluate the ethnic factor inherent in each technique was extremely deficient. It was perceived that this was used in only one of the articles analyzed,[16] which was shown by one of the deficiencies found in the profile of the scientific research in this area, which could be explained by the difficulty of exchanging and accessing imaging exams from other countries.

Regarding gender, the results showed that the importance of the use of exams from individuals of both sexes is consolidated, since all the studies that considered this characteristic used a mixed sample, and the majority had an equal division between the sexes.

In addition, the age of the sample was also a determining factor for effective identification, since the final configuration of the frontal sinuses is only reached after the age of 20.[20] However, Tatlisumak et al.[29] explored the pattern of frontal sinus configuration according to age, based on the belief that the frontal sinuses continue to expand to a later age, due to other factors and the influence of mechanical chewing factors.[32] In this case, it was agreed that there is a decrease in the frontal sinus area from the age of 70 years old,[29] but from the analysis performed, it was observed that the authors concluded that new studies need to be performed with less limited samples and looking at different backgrounds.

Regarding the type of image exam selected, it was verified that more than half of the studies used PA (posteroanterior) radiography.[14-17,19,20,22,26-30] Thus, it was noted that conventional extraoral radiography is still the most viable and most used in the research, also emphasizing the increasing use, but still at a smaller scale, of three-dimensional imaging resources, such as concomitant computed tomography.[10,13,18]

In relation to the methodologies and identification parameters of the frontal sinus, the largest number of analyzes used both quantitative and morphological parameters. Among all the parameters used to measure and classify the frontal sinuses, height and width were widely used to obtain asymmetry indices.[10,14,15,19,21,26,28,30] In addition to asymmetry, depth values,[21] volume[10,21,29], and the anteroposterior diameter of the frontal sinuses[25,29] were repeated in several articles from the present analysis.

In 1987, Yoshino developed one of the most widespread classification methods in the world, taking into consideration the area of the breasts, bilateral asymmetry, the superiority of the area on one side, the contour of the upper border, the

presence of partial septa, supraorbital cells, and orbital areas. This methodology is still used in the last years[14,15,21,26,18] in different populations and with some adaptations. In 2008, Cameriere et al.[14] replaced some of the variables, such as asymmetry, with indices corresponding to the frontal sinus areas and the orbits corresponding to each side, performing tests of image proportions.

As for tomographic reconstructions, in 2007 Tatlisumak[12] developed a methodology that was subsequently used in different studies and populations for human identification with a high degree of agreement and acceptance, using qualitative and quantitative parameters. This methodology is known as the FSS System,[4,12,18,27] this method uses a range of twelve standardized parameters: presence of the frontal and left frontal sinuses, central frontal sinus, presence and type of interosseous septum, type of deviation within the transverse septum, number of incomplete and complete intra-septae within the right and left frontal sinus, the number of scaling (curved cuts) of the right and left frontal sinus. Such standardization facilitates the collection and transfer of data so that this methodology has been tested and improved in different populations.

Cone beam computed tomography allowed Cossellu et al. to correlate quantitative variables through statistical analysis, reaching a high efficacy in the analyzes of the same observer and of different observers.[10] However, the challenge is the applicability of the Tatlisumak methodology in conventional radiographs, considering the reality of Brazilian expertise.

In 2016, Soares et al.[27] analyzed the results obtained from radiographic and tomographic images and found a greater concordance in the tomographic data in relation to the quantitative parameters. However, in both the imaging modalities, reliability, and reproducibility were satisfactory. In this study, it was suggested that the distance between the highest points of the right and left sinuses be excluded among the identification parameters. Rabello[4] tested this classification system on frontal and lateral extraoral radiographs, obtaining good results regarding the applicability if the radiographs were acquired after rigorous calibration and specialized training. There was also a greater efficacy and reproducibility in the analyzes made by the same examiner when compared with data between the different examiners, which is not a problem since the identification is made by a single expert.

Moreover, six articles opted for identification through non-quantitative parameters,[13,16,23,24,30,31] that were purely morphological. The overlapping of radiographic images through tracings,[13,23,24] without the use of metric variables, has great value for the everyday expert. This technique has been improved using digital radiographs and software that allow the outline of the trace to be no longer made in an empirical way, which could lead to false identification. In relation to tomography, the superposition technique is also gaining momentum, since the superposition of three-dimensional reconstructions can be done when there is a tomographic image of the individual at the antemortem moment, as was done in Beaini's research.[24]

CONCLUSION

The quality of a specific approach should not be fully evaluated by the accuracy of the technique since its reproducibility must also be proven. There is a need for human frontal sinus identification methods to be extended to other populations in order to evaluate possible variations, thus contributing to the increased reliability of the technique.

Additional and valuable information, such as nationality, sex, and age patterns, can be added to the current multifactorial methods, aiming at the improvement and development of less invasive techniques; increasing its precision through the use of more modern three-dimensional images; increasing the fidelity of the method.

Thus, the encouragement of scientific research in this field is of vital importance in Brazil, and dental radiology is a potential field of research, aiming at increasing the accuracy of the techniques used for human identification in expert exams involving frontal sinuses.

REFERENCES

1.Daruge, Eduardo; Daruge Júnior, Eduardo; Francesquini Júnior, Luiz. Tratado de Odontologia Legal e Deontologia. Rio de Janeiro: Guanabara Koogan, 2017.

2.Reichs KJ. Forensic Science lnternatiod Quantified comparison of frontal sinus patterns by means of computed tomography. 1993;61:141–68.

3.Buyuk SK, Karaman A, Yasa Y. Association between frontal sinus morphology and craniofacial parameters: A forensic view. J Forensic Leg Med. 2017;49:20–3.

4.Rabelo KA, dos Anjos Pontual ML, de Queiroz Jordão N, de Paiva KM, de Moraes Ramos-Perez FM, dos Santos MS, et al. Human identification by FSS system adapted to cephalometric radiographs. Forensic Sci Int. 2016;262:227–32.

5.Çakur B, Sumbullu MA, Durna NB. Aplasia and agenesis of the frontal sinus in Turkish individuals: A retrospective study using dental volumetric tomography. Int J Med Sci. 2011;8(3):278–82.

6.International Criminal Police Organization. Interpol DVI Guide. Lyon: OIPC – Interpol; 2013. Disponível em: < https://www.interpol.int/INTERPOL-expertise/Forensics/DVI-Pages/DVI-guide>.

7.Reverte Coma, JM. El diente en Antropología Forense. In: REVERTE COMA, JM. Antropología Forense. Madrid: Secretaria General Tecnica, Centro de Publicaiones, 1991. p. 325-390

8.Almeida, MSC. Estudo da Identificação Humana por meio da imaginologia dos seios frontais. Análise dos procedimentos de estimativa da idade cronológica do indivíduo pela avaliação dentária no Instituto Médico Legal de Fortaleza. 2012. [dissertation]. Universidade Federal da Paraíba. Faculdade de Odontologia, João Pessoa, 2012.

9.Gonçalves AS, Marcelino JC, Prado MM, Silva RF. Identificação humana utilizando radiografia pa de seios maxilares: relato de caso. Rev Bras Odontol Leg RBOL. 2014; 1(1);

10.Cossellu G, De Luca S, Biagi R, Farronato G, Cingolani M, Ferrante L, et al. Reliability of frontal sinus by cone beam-computed tomography (CBCT) for individual identification. Radiol Medica. 2015;120(12):1130–6.

11.Soriano EP, Carvalho, MVD, Santos, FB, Campello, RIC, Mendoza, CC. A radiologia no processo de identificação odontolegal. Rev. ABO Nac. 2008;16: 180–184.

12.Tatlisumak E, Yilmaz Ovali G, Aslan A, Asirdizer M, Zeyfeoglu Y, Tarhan S. Identification of unknown bodies by using CT images of frontal sinus. Forensic Sci Int. 2007;166(1):42–8.

13.Pfaeffli M, Thali MJ, Bolliger SA, Braun M, Vock P, Dirnhofer R. Post-mortem radiological CT identification based on classical ante-mortem X-ray examinations. Forensic Sci Int. 2006;171(2–3):111–7.

14.Cameriere R, Ferrante L, Molleson T, Brown B. Frontal sinus accuracy in identification as measured by false positives in kin groups. J Forensic Sci. 2008;53(6):1280–2.

15.Tang JP, Hu DY, Jiang FH, Yu XJ. Assessing forensic applications of the frontal sinus in a Chinese Han population. Forensic Sci Int. 2009;183(1–3):104.e1-104.e3.

16.Cox M, Malcolm M, Fairgrieve SI. A new digital method for the objective comparison of frontal sinuses for identification. J Forensic Sci. 2009;54(4):761–72.

17.Besana JL, Rogers TL. Personal identification using the frontal sinus. J Forensic Sci. 2010;55(3):584–9.

18.Uthman AT, AL-Rawi NH, Al-Naaimi AS, Tawfeeq AS, Suhail EH. Evaluation of frontal sinus and skull measurements using spiral CT scanning: An aid in unknown person identification. Forensic Sci Int. 2010;197(1–3):124.e1-124.e7.

19.David M, Saxena R. Use of frontal sinus and nasal septum patterns as an aid in personal identification: A digital radiographic pilot study. J Forensic Dent Sci. 2011;2(2):77.

20.Patil N, Karjodkar FR, Sontakke S, Sansare K, Salvi R. Uniqueness of radiographic patterns of the frontal sinus for personal identification. Imaging Sci Dent. 2012;42(4):213–7.

21.Lee U-Y, Kim D-I, Kwak D-S, Han S-H, Park S-O. Identification Using Frontal Sinus by Three-Dimensional Reconstruction from Computed Tomography*. J Forensic Sci. 2012;58(1):5–12.

22.Nikam SS, Gadgil RM, Bhoosreddy AR, Shah KR, Shirsekar VU. Personal Identification in Forensic Science Using Uniqueness of Radiographic Image of Frontal Sinus. J Forensic Odontostomatol. 2015 Jul 1;33(1):1-7.PMID: 26851444

23.Hashim N, Hemalatha N, Thangaraj K, Kareem A, Ahmed A, Hassan NFN, et al. Practical relevance of prescribing superimposition for determining a frontal sinus pattern match. Forensic Sci Int [Internet]. 2015;253:137.e1-137.e7. Available from: http://dx.doi.org/10.1016/j.forsciint.2015.05.020

24.Beaini TL, Duailibi-Neto EF, Chilvarquer I, Melani RFH. Human identification through frontal sinus 3D superimposition: Pilot study with Cone Beam Computer Tomography. J Forensic Leg Med [Internet]. 2015;36:63–9. Available from: http://dx.doi.org/10.1016/j.jflm.2015.09.003

25.Akhlaghi M, Bakhtavar K, Moarefdoost J, Kamali A, Rafeifar S. Frontal sinus parameters in computed tomography and sex determination. Leg Med [Internet]. 2016;19:22–7. Available from: http://dx.doi.org/10.1016/j.legalmed.2016.01.008

26.Soman B, Sujatha G, Lingappa A. Morphometric evaluation of the frontal sinus in relation to age and gender in subjects residing in Davangere, Karnataka. J Forensic Dent Sci. 2016;8(1):57.

27. Soares CBRB, Almeida MSC, Lopes P de ML, Beltrão RV, Pontual A dos A, Ramos-Perez FM de M, et al. Human identification study by means of frontal sinus imaginological aspects. Forensic Sci Int. 2016;262:183–9.

28.Suman JL, Jaisanghar N, Elangovan S, Mahaboob N, Senthilkumar B, Yoithapprabhunath TR, Srichinthu KK. Configuration of frontal sinuses: A forensic perspective. J Pharm Bioall Sci 2016;8, Suppl S1:90-5

29.Tatlisumak E, Etli Y, Keskin S, Bora A, Hekimoglu Y, Gumus O, et al. The effects of gender and age on forensic personal identification from frontal sinus in a Turkish population. Saudi Med J. 2017;38(1):41–7.

30.Verma K, Nahar P, Pal Singh M, Mathur H, Bhuvaneshwari S. Use of frontal sinus and nasal septum pattern as an aid in personal identification and determination of gender: A radiographic study. J Clin Diagnostic Res. 2017;11(1):ZC71-ZC74.

31.Souza LA d., Marana AN, Weber SAT. Automatic frontal sinus recognition in computed tomography images for person identification. Forensic Sci Int [Internet]. 2018;286:252–64. Available from: https://doi.org/10.1016/j.forsciint.2018.03.029

32.McLaughlin RB, Rehl RM, Lanza DC. Clinically relevant frontal sinus anatomy and physiology. Otolaryngol Clin North Am. 2001;34(1):1–22.