DENTAL IMPLANTS PLACED BUCCALLY TO THE MANDIBULAR CANAL IN MOLAR REGIONS WITH SEVERE VERTICAL BONE LOSS: CASE REPORTS

Nilo Guliberto Martins **Chavarry**[1]*

[1]Department of Dental Clinic, Division of Periodontics, Dental School, Universidade Federal do Rio de Janeiro, Rio de Janeiro, RJ, Brazil

Palavras-chave: Nervo Mandibular. Implantes Dentários. Perda do Osso Alveolar. Perda do dente .

RESUMO

Introdução: A perda óssea alveolar severa em região posterior de mandíbula é um sério fator limitante para instalação de implantes dentários osseointegráveis. Novas técnicas cirúrgicas são necessárias visando contornar a falta de osso vertical. **Objetivo:** O objetivo deste estudo foi apresentar uma técnica alternativa de inserção de implante dentário na região posterior lateral da mandíbula em pacientes com atrofia vertical severa de rebordo alveolar. **Relatos de casos**: Foram selecionados 4 pacientes com características anatômicas específicas que atendiam aos requisitos da técnica. Seis implantes foram instalados lateralmente ao canal mandibular por vestibular e foram restaurados após o tempo de cicatrização de pelo menos dois meses. A média da avaliação de seguimento do implante foi de 3 anos. Nenhum implante foi perdido e todos eles atenderam às exigências estéticas e funcionais da oclusão, estando em ótimas condições clínicas. **Conclusão:** A técnica mostrou-se minimamente invasiva, segura, conservadora e eficaz como alternativa de tratamento para reabilitação dentária em regiões posteriores de mandíbula com atrofia óssea severa. Entretanto, ela requer experiência, preparo e habilidade do profissional que visa não lesionar o nervo alveolar inferior e, ao mesmo tempo, instalar corretamente o implante em uma posição que permita sua restauração funcional e estética.

Keywords: Inferior Alveolar Nerve. Dental Implant. Alveolar Bone Loss. Tooth Loss.

ABSTRACT

Introduction: Alveolar bone loss in posterior regions of the mandible is a serious limiting factor for the installation of osseointegrated dental implants. New surgical procedures are needed to circumvent the lack of vertical bone. **Objective:** The objective of this study was to present an alternative technique for dental implants in the lateral posterior region of the mandible in patients with severe vertical ridge atrophy **Case Reports:** Four patients with the specific anatomical characteristics that met the requirements of the technique were selected. Six implants were inserted buccally to the mandibular canal and were restored after at least two months of healing time. The mean follow up period of the implants was 3 years. No implant was lost during this time. All of them remained in excellent clinical condition and met the aesthetic criteria and functional demands of occlusion. **Conclusion:** The technique presented here proved to be minimally invasive, safe, conservative and effective as an alternative treatment option for dental rehabilitation in mandibular posterior regions with severe bone atrophy. However, it requires experience, preparation and skill of the professional in order not to damage the inferior alveolar nerve and at the same time install the implant in the correct position, thus allowing its functional and aesthetic rehabilitation.

Submitted: January 29, 2019
Modification: April 12, 2019
Accepted: April 17, 2019

***Correspondence to:**
Nilo Guliberto Martins Chavarry
Address: Av. Visconde de Pirajá - Ipanema, Rio de Janeiro - RJ, Rio de Janeiro-RJ, Zip code: 22410-920
Telephone Number: +55 21 988959113
Email: nilochavarry@gmail.com

INTRODUCTION

The placement of dental implants in the mandible posterior region (MPR) is always a challenge for dental surgeons when there is severe bone atrophy due to dental losses.[1] The reduced vertical distance (VD) between the crest of the alveolar ridge and the roof of mandibular canal (MC) makes this area unsuitable for the use of standard implants above the inferior alveolar nerve (IAN).[2] Therefore, in order to have a safety margin and not injure the IAN on drilling into the bone, it is recommended to decrease the VD by 2 millimeters to be used as the appropriate implant length in the MPR.[3] The shortest implant available in size is 4mm and so, following this rule, it requires a VD of at least 6mm to insert an implant. Several techniques of vertical ridge augmentation have been proposed in the literature to counteract this bone loss (BL). [4,5] However, there have also been many complications regarding these approaches, such as pain, edema, suture dehiscence, infection, loss of sensation and graft failure.[6] In addition, bone graft surgeries increase costs, patient morbidity and extend dental treatment. Therefore, these procedures should be avoided whenever possible. [3] One study described a 3 D topography model of the mandibular canal and the trajectory of the inferior alveolar nerve in histological sections. These authors found that in 70% of the cases these structures follow a bucco-lingual location very close to the lingual bone cortical plate, both in the ramus and in the body of the mandible. [7] According to another study that used cone beam computed tomography images (CBCT) from 500 mandibular canals, the variation of the horizontal distance (HD) between the buccal cortical plate and the mandibular canal was up to 7mm in the molar region.[8] This area may be considered suitable for dental implants.[9] The present work aimed to use this bone region to insert implants and to offer dental surgeons a simple and safe alternative to overcome difficult cases with severe posterior ridge atrophy.

CASE REPORTS

Treatment Technique

A virtual surgery was carried out beforehand on a computer, using specific Software (DentalSlice, Copyright 2015) to manipulate the dental implant using cone beam tomography. The CBTC delimits the horizontal distance precisely from the outer edge of the mandible to the canal. Based on this distance and with the aid of diagnostic waxing, the point of entry of the implant into the bone is established respecting a safety margin of nearly 1 mm from the vestibular edge and 2 mm from the MC. The inclination of the implant, in turn, is defined by the position of the opposing tooth (Figure 1E). Often, a lingual slope of approximately 25 to 30 degrees is necessary to achieve optimal occlusion. From the 3D surgical planning, a guide can be made by prototyping. It provides precise references for the transoperative procedures that allow greater accuracy in the final positioning of the implant. However, the surgical guide was not used in any of the cases in this study. But, for a less experienced professional, it can be an extremely useful device. The preoperative, transoperative and postoperative procedures were based on standard guidelines for implant placement. Blockage of the inferior alveolar nerve, lingual nerve and buccal nerve was carried out through local anesthesia with infiltrative injections. A central incision in the edentulous alveolar ridge was performed and the mucoperiosteal flap was elevated and one relaxing incision at the posterior extremity was also made. A wide lateral view of the mandible is essential to guide the preparation of the implant bed. The mandible lateral border is a major reference for implant placement without damaging the IAN. The drill was mounted at a contra-angle of 1:21 at 55,000 rpm, with a torque of 50 Ncm and with an irrigation of 50 mL/minute. The drilling usually started in the center of HD, but eventually an even more lateral approach is needed. In brief, at least, 1 mm of vestibular cortical bone must be left to assure implant integrity. Also, the depth gauges must be checked constantly as the drill penetrates into the bone to ensure the inclination of the implant aligned with the opposing tooth. The implant was then placed, and the final position checked. At the reentry surgery, the transmucosal abutment was placed, followed by a healing period of 30 days. A single and experienced operator (NGMC) performed all the surgeries and restorative procedures.

Case 1

A 60 year-old female patient with the absence of her lower posterior right teeth 29, 30, 31 and 32 complained of masticatory difficulties. No periodontal disease was detected in the remaining teeth assessed by Clinical Attachment Loss (CAL), Periodontal Pocket Depth (PPD) and Bleeding on Probing (BOP). One dentist had tried an autogenous bone block for vertical ridge augmentation (Figure 1A). The whole graft was lost due to infection (Figure 1B). A preoperative CBCT detected a VD < 5 mm and a HD of 7mm at position 31 (Figure 1C). The patient received oral hygiene instructions at two consecutive weekly sessions to lower the Plaque Index (PI) to <20% of the dental surfaces. Six months after the bone block failure, two implants were planned and inserted in the region of teeth 31 and 30 maintaining a safe distance from the mental nerve (Figure 1D). The most posterior implant in 31

position, [3.3mm diameter (D) x 10mm length (L)], whose VD was less than 5mm, was installed buccally to the MC at a 7mm HD (Figure 1E). The prosthetic planning consisted of a partially fixed metal ceramic bridge with 3 elements including the 29 in cantilever (Figure 1F,G, H). The prosthesis has been in place for 8 years and there has been no BL and no gingival inflammation around the implants. The patient reports that her chewing has returned to normal and is comfortable.

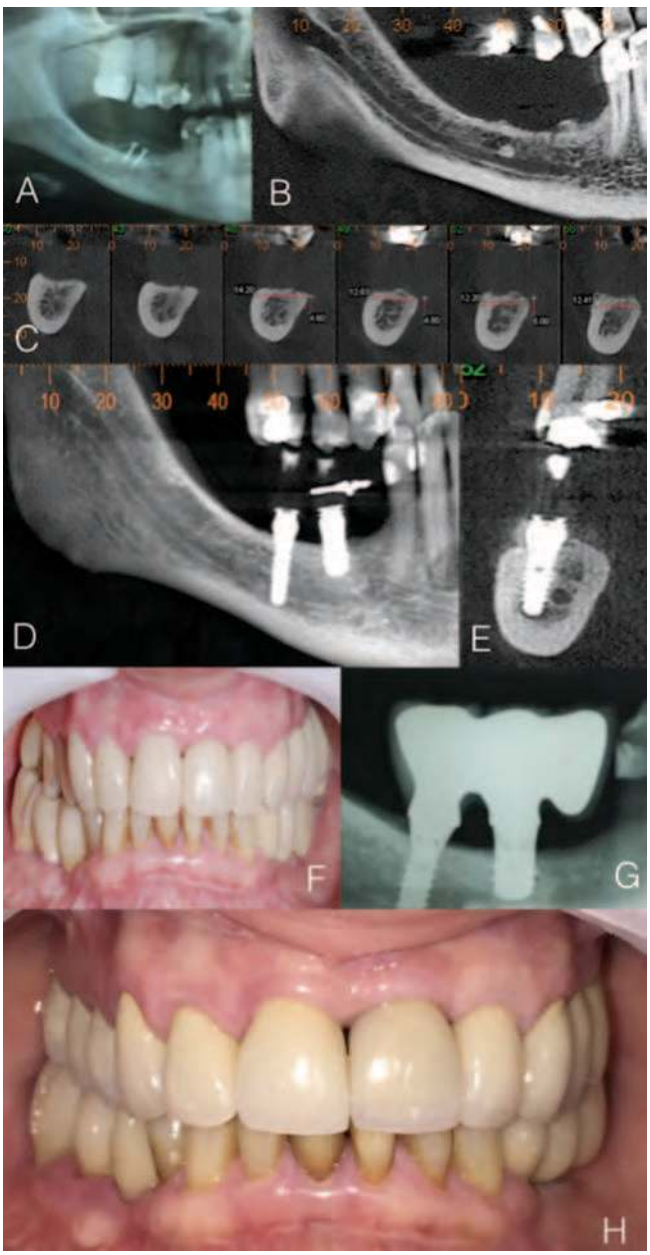

Figure 1: *[A] Bone block graft fixation screws. An attempt at vertical gain that did not work; [B,C] Panoramic and transaxial CBCT images of the mandibular canal (MC) before the implants ; [D] Implant 31 appears to have transfixed the IAN; [E] The implant 31 passes buccally to the MC; [F] Fixed Provisional Restorations (FPR). [G] X-ray of Metal-Ceramic bridge; [H] Definitive restorations.*

Case 2

A 55-year-old woman complained of having serious problems with her lower removable partial denture. At the clinic she reported she was willing to have implants in order to improve her chewing capacity. The clinical assessment showed severe BL in the MPR on both sides (Figure 2A). Tooth 26 had a mobility grade 3, with more than 50% loss of periodontal bone support (Figure 2B) probably in part because it served as a retainer and support for the removable dental prosthesis. An initial CBCT of the region of the teeth 30 and 31 showed a VD of less than 5mm (Figure 2C). Consequently, four implants were proposed to restore occlusion in the fourth quadrant (Figure 2 D,E). The two most posterior implants, [3.3mm (D) x 10mm (L)], were placed buccally to the MC (Figure 2F). Fixed Provisional Restorations (FPR) improved the chewing, swallowing and aesthetics (Figure 2G). Tooth 26 has become firm and healthy. After 4 years of follow-up the four implants are in excellent clinical condition with no signs of inflammation and no BL around the implants.

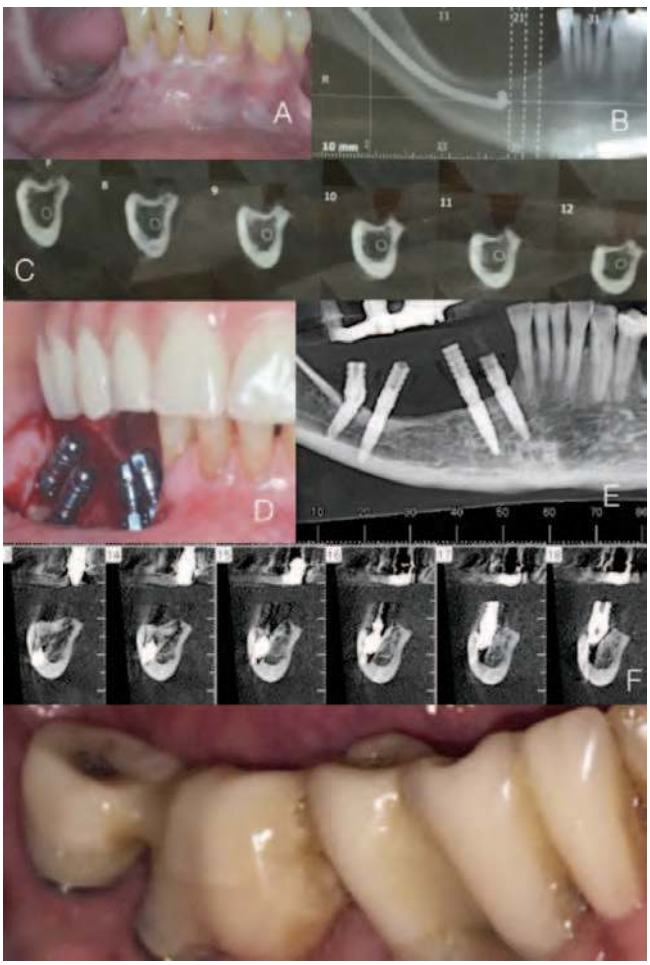

Figure 2: [A] Severe BL in the MPR; [B,C] CBCT images show the proximity of the MC to the ridge crest (VD ≤ 5mm); [D] Implants are in a good occlusal relationship with their antagonists; [E,F] The implants 30 and 31 pass buccally to the MC and are anchored in the inferior cortical of the mandible; [G] FPR.

Case 3

A 57-year-old male with a severely resorbed MPR complained of pain due to his lower removable prosthesis. The cause of the problem was his prosthesis compressing the IAN, onto the surface of the ridge due to insufficient bone above the MC (VD<1mm) (Figure 3 A,B). Two of the three implants, [3.3 (D) x 10mm (L)], that were made were anchored buccally to MC in the basilar of the mandible in positions of teeth 18 and 19 (Figure 3 C,D,E,F). The third one was installed conventionally next to the canine (Figure 3 G). The patients chewing improved considerably and after the FPR (Figure 3 H,I) he did not have any more pain. The implants have been followed up for more than a year and they are in a very good clinical and tomographic condition.

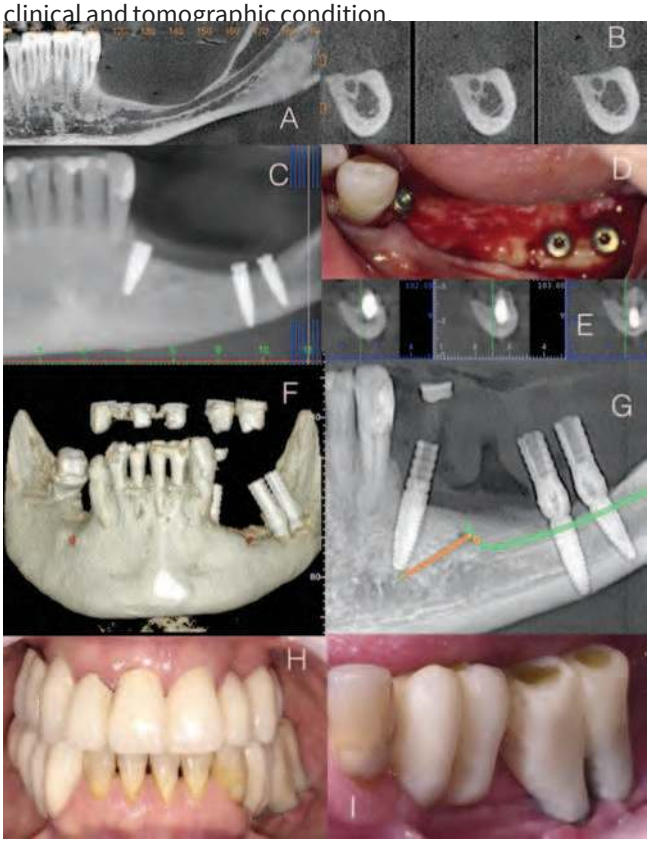

***Figure 3**: [A] Severe BL in the MPR ; [B] The Preoperative CBCT shows no bone above the canal; [C] Implants anchored in the basilar of the mandible;[D] Surgical approach; [E] The Postoperative CBCT shows the implants 18 and 19 passing alongside the nerve; [F] Mandible 3D view of the implants 18 and 19 in the extreme lateral position; [G] Panoramic view of the implants and its titanium provisional abutments; [H] Front and [I] lateral view of FPR.*

Case 4

Another case in which CBCT showed a VD < 6mm (Figure 4 A,C) was a 68-year-old female patient who came to the dental clinic using a complete removable upper prosthesis. All posterior teeth in the inferior arch were absent with the exception of tooth 28. The periodontal status assessed by CAL, PPD, PI and BOP, revealed active periodontal disease with bone loss and anterior migration of lower teeth. She underwent a nonsurgical periodontal treatment which included supra and subgingival scaling and root planning together with instructions of oral hygiene. After recovering her periodontal health (no site with PPD e" 4mm, less than 20% of sites with visible plaque and less than 30% of sites with BOP), two implants were installed in order to restore this quadrant prosthetically (Figure 4B). The most posterior implant, [3.3 (D) x 10mm (L)], was positioned BMC (Figure 4D). Despite the divergence between the angulations of the two implants (Fig. 4E), the bolted fixed prosthesis had a passive seating (Figure F). The patient reported comfort in chewing after 7 months of using her FPR. The clinical and tomographic aspects of the implants are absolutely normal and the lower anterior teeth improved their stability and clinical periodontal parameters.

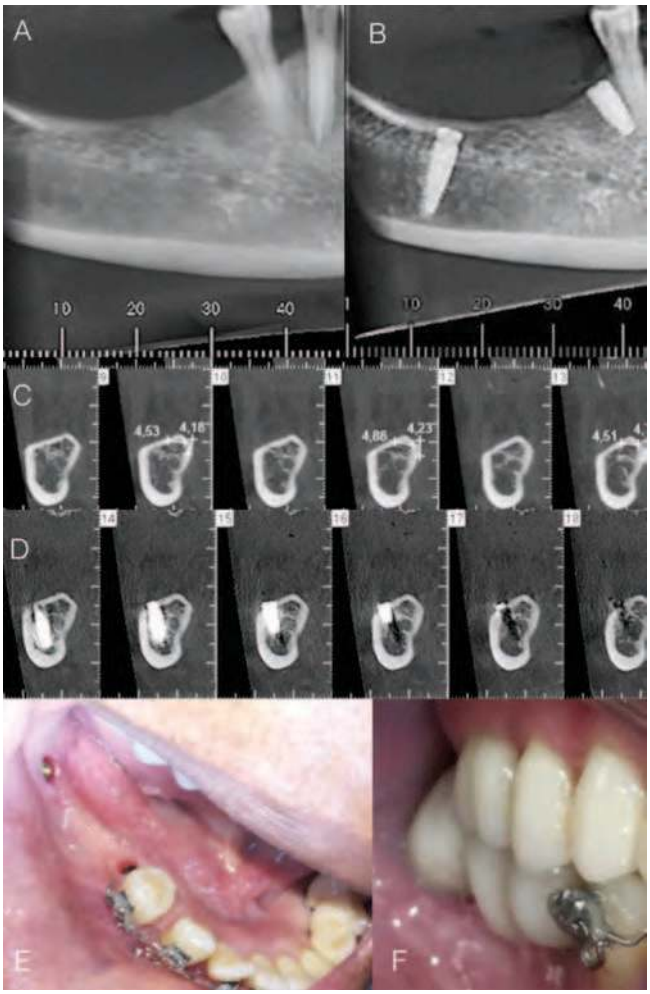

***Figure 4**: [A] Pre and [B] postoperative panoramic view; [C] Pre and [B] postoperative transaxial CBCT of the MPR ; [E] Clinical view of the Implants 31 and 29; [F] FPR in good relationship with their antagonists.*

DISCUSSION

The present study demonstrated that the six implants installed buccally to the mandibular canal had an excellent osseointegration and all of them were restored satisfactorily. No bone loss was detected by CBCT and no clinical gingival inflammation, assessed by BOP, was found around the implants during the mean follow-up time of 3 years. The absence of gingival bleeding after probing (BOP) is an important indicator of periodontal stability with a high prognostic value. Support Periodontal Therapy (SPT) was provided for all patients on a quarterly basis. Motivation and instruction of oral hygiene with interdental brushes, compact tuft and super floss every three months contributed to the excellent quality of the gingival tissue, especially around the implants. PI with less than 20% remained stable, for everyone, at each SPT session. No systemic diseases, such as diabetes mellitus, osteoporosis, arterial hypertension or smoking habits were detected during the anamnesis interview. All participants informed that they were not taking any type of therapeutic drug at baseline. Patients reported improvements in oral functions especially in their chewing and biting capacity, self-esteem, and social relationships. One patient experienced a light paresthesia that ceased spontaneously after 30 days. These results are in accordance with the results of a study that evaluated the clinical outcome of implants positioned lateral to MC over 10 years. [2] The authors reported high cumulative survival rates for implants installed alongside the IAN, and stated that this technique is conservative and predictable, [2,10] although little disseminated among implant dentists. The study reported on 135 implants, and only six were lost. Many morphometric studies regarding the course and position of the IAN have shown that there is sufficient bone available buccally to it for a dental implant, [7,8,9] but prospective clinical assessments of implants using this approach are very scarce in the literature. On the other hand, bone graft surgeries with stem-cell growth factors are gaining space in order to overcome difficulties of the vertical bone augmentation of the ridge in the MPR ,[11] but this technique increases costs, risk of failure and extend treatment time. Likewise, indications for extractions of the lower anterior teeth increase in posterior mandibular edentulous patients, especially for those professionals who opt to follow the Branemark protocol. [12,28] In fact, the peculiar anatomy of the lateral region of the mandible requires careful analysis and accurate planning to make this region possible to receive implants that must be restored with harmony for occlusal. Despite the outermost position of the implants in the arch, and due to the technique itself the biomechanical aspects in posterior occlusion must be respected. The clinician should circumvent this atypical position to obtain an optimal occlusal plane, an acceptable crown to implant ratio and establish a mutually protected occlusion to achieve a successful outcome. As soon as the mandible moves in any direction, none of the posterior teeth should be in the occlusion position. To achieve these criteria, for the six implants inserted buccally to the MC presented here, five needed 30° tilted abutments (Figure 3G) to direct the lower buccal cusp tip of the prosthetic crowns in centric relation against their antagonists and in one case only, a straight one was used (Figure 1E). The three-dimensional position of the implant in the arch is the key to the success of a restoration. Is it worth having bone, if the implant cannot be restored due to its bad position? Is it worth having an implant if it does not remain fixed in the mouth for a long time due to excessive occlusal forces? However, this lateral mandible region with a thick cortical layer surrounding the trabecular bone and this anatomical characteristic potentiates the osseointegration force of the implant. Moreover, this bone has a high mineral density, greater hardness and greater resistance to fracture compared to the posterior superior region. Another important aspect of this technique is that, unlike the ultra-short implants (4mm), or short implant (6 - 8mm) modals, longer implants of 10 to 12 mm or more can be inserted. According to some authors, implants of 6 and 8mm tested in the MPR submitted to vertical forces, presented a similar survival rate to standard-length implants and also a similar bone resorption rate. These authors concluded that increasing implant length does not increase its capacity to support loads. [13] However, horizontal forces provide greater deformations in the cortical bone than vertical forces. [14] Furthermore, the performance of the ultra-short implants has not been tested with severe BL and increased interocclusal space. [15] Incidentally, implants of 4 and 6 mm in length are not available in the narrow version and this therefore precludes their use in thin bony crests. In contrast to previous studies cited, short implants failed more than longer implants due to their reduced anchorage and lower load-bearing capacity. [10] In all the cases presented here, there was no bone height above the mandibular canal to install even the smallest implant available. Even though short implants are a viable alternative, the use of long implants, in these cases, should be the first therapeutic choice. [16] Even more stability and rigidity can be achieved if the implants are splinted in fixed multiunit reconstructions. This strategy reduces bone stress and the bending forces of the tilted implants. [17] In addition, to increase the resistance to bone fatigue and fracture even more, the basilar of the mandible can be used as an anchorage for implants to achieve a bicorticalization insertion. Also, the vertical soft and hard tissue losses due to

tooth loss present on severe ridge atrophies are compensated by the increase in the height of the prosthetic teeth, which constitutes, in fact, the crowbar that sometimes pushes the implant to the limit. Until recently, there was no reference to the maximum acceptable crown to implant ratio. The empiricism of this relationship revealed proportions much higher than the maximum recommended for crown to root ratio (which is 1). Fortunately, implants support crowns greater than their length better than natural roots do. The 5th EAO Consensus Conference 2018 states that the use of singletooth restorations with crown to implant ratio between 0.9 and 2.2 is not expected to increase BL or failure rates and therefore it is a viable treatment option.[15] Due to the limited amount of bone buccally to MC and to preserve IAN integrity, the use of small diameter implants (SDI) is almost always recommended. All the implants inserted in this case report had a 3.3mm diameter, exactly the same diameter as all 135 implants installed lateral to the MC in the retrospective study, mentioned previously. [2] This could be considered a shortcoming of this technique, if it were not for the resistance of the material, used to make the dental implants, against fracture. Binary titanium-zirconium (TiZr) alloys were used in all six implants (SDI) reported in this study, and they demonstrated strengths of up to 40% greater than conventional grade IV titanium implants.[18] Although specific indication for SDI has been primarily for the incisor region, some studies have demonstrated high success rates in selected MPRs.[19] Another aspect to mention concerning the buccal approach is the lack of keratinized tissue (KT) in this region. This can be considered a weak point of the technique that must be overcome by respecting all the periodontal biological principles that should be applied by analogy to dental implants. Among them are the precise adaptation of the restorations and the manufacturing of the correct emergent profile, which must allow easy access to clean all the prosthetic surfaces, especially the interproximal areas. The patient should be included in a strict periodontal maintenance program, with frequent visits to the dentist, in order to have healthy long-life implants, even in areas with little or lacking masticatory mucosa. [20] Finally, it is worth emphasizing that this technique may be a simple option to reconstruct the posterior teeth in severe atrophic mandibles such as Kennedy class 1 cases and then carry out the maintenance of the anterior teeth in the mouth instead of extracting them to install a Branemark protocol.[15] The preservation of natural teeth with their mechanoreceptors in the periodontal ligament constitutes a protective factor for the maintenance of healthy implants over the years as well as for better control of the occlusal overload on peri-implant tissue. Prospective randomized long-term studies should be performed aimed at comparing the implants placed buccally to the mandibular canal with implants placed above the IAN after bone augmentation procedures.

CONCLUSION

The implants inserted buccally to the mandibular canal in the first and second molar regions may be considered effective and as an alternative technique for the rehabilitation of posterior atrophic ridges with severe vertical bone loss.

ACKNOWLEDGMENTS

I would like to thank Professor Eduardo Jorge Feres-Filho for teaching me the first steps in implantology.

REFERENCES

1. Stellingsma C, Vissink A, Meijer HJA, Kuiper C, Raghoebar GM. Implantology and the Severely Resorbed Edentulous Mandible. Crit Rev Oral Biol Med. 2004;15(4):240–8.
2. Cruz M, Cruz G, Cruz F, Morales-Vadillo R, Cruz-Pierce S. Lateral Approach to the Maxillary Sinus and Mandibular Canal in Severely Atrophied Posterior Alveolar Bone. Int J Oral Maxillofac Implants. 2018;33(2):412–8.
3. Bolle C, Felice P, Barausse C, Pistilli V, Trullenque-Eriksson A, Esposito M. 4 mm long vs longer implants in augmented bone in posterior atrophic jaws: 1-year post-loading results from a multicentre randomised controlled trial. Eur J Oral Implantol. 2018;11(1):31–47.
4. Louis PJ. Vertical Ridge Augmentation Using Titanium Mesh. Oral Maxillofac Surg Clin North Am. 2010;22(3):353–68.
5. Felice P, Marchetti C, Iezzi G, Piattelli A, Worthington H, Pellegrino G, et al. Vertical ridge augmentation of the atrophic posterior mandible with interpositional bloc grafts: bone from the iliac crest vs. bovine anorganic bone. Clinical and histological results up to one year after loading from a randomized-controlled clinical trial. Clin Oral Implants Res. 2009;20(12):1386–93.
6. Kaing L, Grubor D, Chandu A. Assessment of bone grafts placed within an oral and maxillofacial training programme for implant rehabilitation. Aust Dent J. 2011 Dec;56(4):406–11.
7. Kim ST, Hu K-S, Song W-C, Kang M-K, Park H-D, Kim H-J. Location of the mandibular canal and the topography of its neurovascular structures. J Craniofac Surg. 2009 May;20(3):936–9.
8. Leite GMF, Lana JP, de Carvalho Machado V, Manzi FR, Souza PEA, Horta MCR. Anatomic variations and lesions of the mandibular canal detected by cone beam computed tomography. Surg Radiol Anat. 2014 Oct;36(8):795–804.
9. Daróz SR, Cardoso ES, Manso MC, Vidigal GM Jr. Evaluation

of bone width lateral to the mandibular canal as an alternative approach for implant installation. Implant Dent. 2013 Feb;22(1):97–101.
10. Krekmanov L. Placement of posterior mandibular and maxillary implants in patients with severe bone deficiency: a clinical report of procedure. Int J Oral Maxillofac Implants. 2000 Sep;15(5):722–30.
11. Gjerde C, Mustafa K, Hellem S, Rojewski M, Gjengedal H, Yassin MA, et al. Cell therapy induced regeneration of severely atrophied mandibular bone in a clinical trial. Stem Cell Res Ther [Internet]. 2018;9(1). Available from: http://dx.doi.org/10.1186/s13287-018-0951-9
12. Brånemark P-I, Zarb GA, Albrektsson T. Tissue-integrated prostheses: osseointegration in clinical dentistry. Quintessence Pub Co; 1985. 350 p.
13. Scarano A, Mortellaro C, Brucoli M, Lucchina AG, Assenza B, Lorusso F. Short Implants: Analysis of 69 Implants Loaded in Mandible Compared With Longer Implants. J Craniofac Surg [Internet]. 2018 Apr 4; Available from: http://dx.doi.org/10.1097/SCS.0000000000004518
14. Cozzolino F, Apicella D, Wang G, Apicella A, Sorrentino R. Implant-to-bone force transmission: a pilot study for in vivo strain gauge measurement technique. J Mech Behav Biomed Mater. 2018 Oct 15;90:173–81.
15. Hämmerle CHF, Cordaro L, Apaza Alccayhuaman KA, Botticelli D, Esposito M, Colomina LE, et al. Biomechanical aspects: Summary and consensus statements of group 4. The 5th EAO Consensus Conference 2018. Clin Oral Implants Res. 2018;29:326–31.
16. Renouard F, Nisand D. Impact of implant length and diameter on survival rates. Clin Oral Implants Res. 2006 Oct;17 Suppl 2:35–51.
17. Krekmanov L, Kahn M, Rangert B, Lindström H. Tilting of posterior mandibular and maxillary implants for improved prosthesis support. Int J Oral Maxillofac Implants. 2000 May;15(3):405–14.
18. Grandin HM, Michelle Grandin H, Berner S, Dard M. A Review of Titanium Zirconium (TiZr) Alloys for Use in Endosseous Dental Implants. Materials . 2012;5(8):1348–60.
19. Jackson BJ. Small-Diameter Implants: A 7-Year Retrospective Study. J Oral Implantol. 2017 Apr;43(2):125–9.
20. Wennström JL, Bengazi F, Lekholm U. The influence of the masticatory mucosa on the peri-implant soft tissue condition. Clin Oral Implants Res. 1994 Mar;5(1):1–8.