IN VIVO EVALUATION OF INFLAMMATION AND MATRIX METALLOPROTEINASE EXPRESSION IN DENTAL PULP INDUCED BY LUTING AGENTS IN DOGS

Alexandra Mussolino de **Queiroz**[1], Thais Helena Andreoli do **Amaral**[1], Paôla Caroline da Silva **Mira**[1], Francisco Wanderley Garcia **Paula-Silva**[1], Paulo **Nelson-Filho**[1], Raquel Assed Bezerra da **Silva**[1], Léa Assed Bezerra da **Silva**[1]*

[1]Department of Children's Clinic of the School of Dentistry of Ribeirão Preto-USP, Ribeirão Preto, SP, Brazil.

Palavras-chave: Agentes Cimentantes. Cimento Resinoso. Cimento de Ionômero de Vidro. Capeamento Pulpar Indireto. Metaloproteinases de Matriz.

RESUMO

Objetivo: Avaliar a resposta tecidual inflamatória e a expressão de metaloproteinase de matriz (MMP) -2 e -9 no complexo polpa-dentina em resposta aos cimentos RelyX™ Unicem (RU) e Ketac Cem™ Easymix (KC). **Métodos**: Cavidades classe V foram preparadas em 56 dentes de seis cães, e capeamento pulpar indireto foi realizado com cimento de RU (n = 20), KC (n = 20), óxido de zinco e eugenol (controle, n = 16). Aos 7 e 70 dias após o capeamento pulpar indireto, os animais foram eutanasiados, e os tecidos foram removidos para avaliação histológica. A distância entre o assoalho da cavidade e a camada odontoblástica foi medida, e os números de células inflamatórias, fibroblastos e odontoblastos foram contados no tecido pulpar. Os níveis de expressão de MMP-2 e -9 foram avaliados por imuno-histoquímica. Análises estatísticas foram realizadas para todos os experimentos (nível de significância = 5%). **Resultados**: A espessura da dentina remanescente entre o assoalho da cavidade e a câmara pulpar foi semelhante para todos os materiais, variando de 469 a 739 µm (p> 0,05). Aos 7 dias, KC e RU induziram uma pequena resposta inflamatória no complexo polpa-dentina, semelhante ao controle (p> 0,05). Aos 70 dias, a RU induziu uma resposta tecidual caracterizada por menos odontoblastos e mais células mononucleares (p <0,05), enquanto o KC induziu uma resposta semelhante ao controle (p> 0,05). Os agentes cimentantes induziram baixos níveis de expressão de MMP-2 e MMP-9, semelhantes ao controle (p> 0,05). **Conclusão**: Os agentes cimentantes KC e RU são materiais compatíveis para uso em cavidades profundas próximas ao tecido da polpa dentária, embora a UR tenha levado a uma população odontoblástica levemente diminuída, com maior porcentagem de células mononucleares.

Keywords: Luting Agents. Resin Cements. Glass Ionomer Cement. Indirect Pulp Capping. Matrix Metalloproteinases.

ABSTRACT

Objectives: To evaluate the inflammatory tissue response and matrix metalloproteinase (MMP)-2 and -9 expression in the pulp-dentin complex in response to RelyX™ Unicem (RU) and Ketac Cem™ Easymix (KC) cements. **Methods**: Class V cavities were prepared in 56 teeth from six dogs, and indirect pulp capping was performed using RU (n=20), KC (n=20), zinc oxide, and eugenol cement (control, n=16). At 7 and 70 days following indirect pulp capping, the animals were euthanized, and tissues were removed for histological evaluation. The distance from the cavity floor to the odontoblastic layer was measured, and the numbers of inflammatory cells, fibroblasts, and odontoblasts were counted in pulp tissue. MMP-2 and -9 expression levels were immunohistochemically assessed. Statistical analyses were performed for all experiments (significance level=5%). **Results**: The dentin remnant thickness between the cavity floor and the pulp chamber was similar for all materials, ranging from 469 to 739 µm (p>0.05). At 7 days, KC and RU induced a small inflammatory response in the pulp-dentin complex, similar to the control (p>0.05). At 70 days, RU induced a tissue response characterized by fewer odontoblasts and more mononuclear cells (p<0.05), whereas KC induced a response similar to the control (p>0.05). Luting agents induced low levels of MMP-2 and MMP-9 expression, similar to the control (p>0.05). **Conclusion**: KC and RU luting agents are compatible materials for use in deep cavities close to dental pulp tissue, although RU led to a slightly diminished odontoblastic population with a higher percentage of mononuclear cells.

Submitted: December 13, 2018
Modification: January 26, 2019
Accepted: April 1, 2019

***Correspondence to:**
Léa Assed Bezerra da Silva
Address: Faculdade de Odontologia de Ribeirão Preto da Universidade de São Paulo. Avenida do Café, s/n. Ribeirão Preto, SP, Brazil. Zip Code: 14040-904.
Telephone Number: 55 16 3315-3984. Fax: 55 16 3315-4102.
E-mail: lea@forp.usp.br

INTRODUCTION

Cementation is a clinical procedure performed to fix one or more indirect restorations to a prepared tooth support (crown or root portion) by means of a luting agent.[1,2] Ketac™ Cem Easymix glass-ionomer cement (KC) is a conventional glass ionomer cement that presents adequate adhesive strength, low moisture sensitivity, low solubility, radiopacity, good marginal sealing, and fluoride release and is indicated for the cementation of metal and metal-ceramic crowns, orthodontic bands, and intraradicular posts.[3,4] Resin cements have also become popular in light of advancements in their physical and mechanical properties, including wear resistance, chemical adherence to tooth structures, resins, and porcelains, and favorable aesthetic appearance, especially for use in nonmetal restorations or those with visible edges.[3,5] RelyX™ Unicem (RU) is a resin cement that has dual polymerization, adhesive capacity, low moisture sensitivity, low linear expansion, fluoride release, superior marginal integrity, and good aesthetic properties and is indicated for cementation of ceramic, resin, or metal crowns and intraradicular posts and cores. In addition, it does not require any pretreatment of tooth tissues prior to cementation.[5]

The mechanical, chemical and biological properties of KC and RU have been investigated previously.[4,6,7,8,9,10,11,12,13,14,15,16] Because most teeth that require prosthetic treatment exhibit extensive coronal damage, investigations of the biological tissue response induced by luting agents on teeth with pulp vitality are relevant to understand the mechanisms of inflammatory reactions.

Matrix metalloproteinases (MMPs) are enzymes present in the dentin matrix that are involved in tissue remodeling.[17,18,19] High levels of MMP-9 are found in teeth with pulpitis,[20,21] whereas MMP-2 levels may be reduced.[20] Self-etching dentin adhesives are able to increase collagenolytic activity in the dentin-pulp complex by activating MMPs *in vitro*,[22,23,24] while zinc oxide and eugenol cement inhibit MMP expression *ex vivo*.[25] The effect of glass ionomer luting cements and resin cements on *in vitro* or *in vivo* MMP expression in dental pulp has not been investigated, albeit we have previously demonstrated that MMP synthesis is augmented when those cements are applied to subcutaneous connective tissue.[16]

Therefore, the aim of this study was to histopathologically evaluate the inflammatory tissue response to KC, a glass ionomer cement, and RU, a resin-based cement, as well as the expression of MMP-2 and -9 in dog dentin-pulp complexes.

MATERIALS AND METHODS

All animal procedures were performed according to the protocols reviewed and approved by the Animal Care Committee of the University of Sao Paulo in compliance with the applicable ethical guidelines and regulations of the international guiding principles for biomedical research involving animals (#11.1.540.53.9).

Indirect pulp capping in deep cavities

The second and third maxillary premolars and the second, third, and fourth mandibular premolars of six mongrel dogs of both genders, aged 12-18 months and weighing 10 kg, were used. Initially, the animals were preanesthetized with an endovenous injection of Neozine (1 mg/kg; Aventis Pharma, São Paulo, SP, Brazil) 15 minutes before the procedure. Next, anesthesia was induced with endovenous administration of Zoletil® 50 (0.1 ml/kg; Virbac do Brasil Ind. e Com., São Paulo, SP, Brazil). After endotracheal intubation, anesthesia was maintained with isoflurane (Abbott Laboratórios do Brasil Ltda., Rio de Janeiro, RJ, Brazil) administered with an inhalation device (Takaoka KT-20, São Paulo, SP, Brazil). During the entire procedure, the animals received an isotonic solution of 0.9% sodium chloride (Glicolabor Indústria Farmacêutica Ltda., Ribeirão Preto, SP, Brazil). Standardized radiographs of the teeth to be treated were taken using custom-made film-holding devices and size 2 periapical films (Ultraspeed; Eastman Kodak Co., Rochester, NY, USA). An exposure time of 1 second was used, and the X-ray equipment (Heliodent; Siemens Medical Systems, Iselin, NJ, USA) was set to 60 kVp and 10 mA. The exposed films were processed using the time/temperature method.

After the dental arch was isolated with a rubber dam, the operative field was cleaned with 3% hydrogen peroxide and 1.0% chlorhexidine gluconate. Class V cavities extending mesiodistally were prepared on the buccal surface of each tooth using a #1015 diamond bur (S.S.White Artigos Dentários Ltda, Rio de Janeiro, RJ, Brazil) in a high-speed turbine under refrigeration with water until a deep cavity was created. The depth was standardized by the length of the active area of the bur (3 mm).[4] After every four cavity preparations, a new diamond bur was used to ensure cutting effectiveness and to prevent overheating. The cavities were well irrigated with sterilized physiological saline solution (Glicolabor Indústria Farmacêutica Ltda.) to remove enamel and dentine debris and dried with cotton pellets.

Then, the pulpal wall was coated with the material corresponding to each of the groups (1, 2, and 3) according to the manufacturer's instructions. A total of 56 teeth were randomly assigned to three groups. **Group 1** (experimental) included 20 teeth treated with a glass ionomer cement (Ketac™ Cem Easymix, 3M ESPE, Seefeld, Germany); **Group 2** (experimental) included 20 teeth treated with a resin cement

(RelyX™ Unicem *clicker*-type packaging, 3M ESPE, Seefeld, Germany) that was photopolymerized for 20 seconds at 450 mW/cm^2(as measured with a curing radiometer); and **Group 3** (control) included 16 teeth treated with standard cavity filling cement (zinc oxide and eugenol cement, S.S.White Artigos Dentários Ltda, Rio de Janeiro, Brazil). All variables were tested in the same animal because each hemiarch was treated with different experimental protocols on a rotation system. Sample size was determined as recommended by ISO 7405:2008.[26] After placing each material on the pulpal wall, the cavities were filled with silver amalgam (Velvalloy™, S.S White Artigos Dentários Ltda, Rio de Janeiro, Brazil).

The animals were observed for possible dietary changes, inflammation, or tissue suppuration over the course of the experiment.

After the recommended experimental periods of 7 and 70 days after the procedures, the teeth of each group were submitted to standard radiographic examination, and the animals were submitted to euthanasia by anesthetic overdose. For this, the animals received injectable Neozine (Aventis) at a dosage of 1 mg/kg weight, which was slowly injected. Euthanasia was then induced with 20% potassium chloride (100 mg/kg), which was slowly, intravenously injected.

After that, teeth were removed with bone and adjacent tissue in a single block using a diamond disc under constant water cooling and then subjected to fixation in 10% formaldehyde solution for 72 hours. At the end of this period, demineralization was carried out using ethylene diamine tetra acetic acid (EDTA; Merck, Darmstadt, Germany) with pH 7.4, adjusted with sodium hydroxide (Chem. Ind. e Com. Ltda., Diadema, Brazil).

Histological evaluation

The demineralization process was activated by using a microwave oven (Sharp Carousel, São Paulo, Brazil) at 30°C at medium/maximum power to avoid tissue changes. The pieces were irradiated in glass vessels containing water and ice every 10 minutes for a period of 4 hours/day, with intervals of 5 minutes between irradiations. Complete demineralization of the samples, evidenced by means of radiographs of the pieces, was achieved in approximately 20 days. After demineralization, the pieces were washed in running water for 24 hours, dehydrated in increasing concentrations of alcohol, diaphanized in xylol and embedded in paraffin. The blocks were sectioned into 5-µm-thick semiserial cuts. For histopathological analysis, the slides were stained by hematoxylin and eosin (HE), and intermediate slides of each series were stained by the Brown & Brenn method.

The specimens were examined by an examiner who was blinded to the treatment groups using a Zeiss Axio Imager M1 binocular light microscope (Carl Zeiss AG Light Microscopy, Göttingen, Germany). The intra-examiner calibration showed a kappa value = 0.83.The thickness of the remaining dentin between the cavity floor and the pulp chamber was measured in µm using images obtained from three sections per specimen (5×) in three regions (half the length of the cavity floor and two equidistant regions from the first measurement and the lateral wall, to the right and to the left). The numbers of inflammatory cells (mononuclear and polymorphonuclear–PMNs), fibroblasts, and odontoblasts were estimated in three regions of the interface between the dentin layer in contact with the material and the pulp tissue (63×), using the *cell counter* tool of ImageJ version 1.42q software (NIH, Bethesda, MD, USA), in conjunction with the Axio Cam MRc5 video camera (Carl Zeiss AG Light Microscopy).Dichotomous data were analyzed with Fisher's exact test. Continuous data were analyzed with two-way analysis of variance followed by Bonferroni post hoc tests for multiple comparisons (significance level= 5%).

Immunohistochemistry

The slides were deparaffinized in xylol (3 immersions of 5 minutes each) and hydrated in a decreasing series of alcohol (2 immersion in 100% alcohol, followed by immersion in 95% alcohol and 1 immersion in 80% alcohol for 2 minutes each passage). They were then placed in distilled water for 5 minutes and kept in phosphate buffered saline (PSB) for another 5 minutes.

The Goat ImmunoCruz™ system (Santa Cruz Biotechnology Inc., Santa Cruz, CA,USA) was used for immunohistochemical experiments. Briefly, tissue sections were quenched in peroxidase buffer for 5 minutes, and antigen retrieval was performed by incubation with 0.05% Proteinase K obtained from *Engyodontium album* at 37°C for 15 minutes (Sigma-Aldrich, St. Louis, MO, USA). Nonspecific binding was blocked by treating sections with donkey serum blocker for 30 minutes, and then, sections were incubated for 1 hour with primary polyclonal goat antibodies for MMP-2 (5.0 µg/ml; Santa Cruz Biotechnology Inc., sc-8835) and MMP-9 (5.0 µg/ml; Santa Cruz Biotechnology Inc., sc-6840). Then, sections were incubated with anti-goat secondary antibody for 30 minutes, followed by horseradish peroxidase-streptavidin for 20 minutes, and the enzyme substrate 3,3'-diaminobenzidine for 5 minutes. Tissues were counterstained with Harris's hematoxylin and mounted using standard protocols. Negative controls were included in which the primary antibody was replaced with goat immunoglobulin G (IgG). Blinded microscopic analysis was performed using a Zeiss Axio Imager M1 binocular light microscope (Carl Zeiss AG Light Microscopy) at 10, 20, 40, 63,and 100× magnification.

RESULTS

Histopathological evaluation

No specimen was lost during the histopathological procedure; therefore, analysis was performed on all 56 teeth. The thickness of dentin remnants between the cavity floor and the pulp chamber was similar for the three materials at both time points, with medians varying from 469 to 739 µm (Figure 1), with no significant differences among groups (p>0.05).

At 7 days, the cellular response induced by RU, KC, and zinc oxide and eugenol (control) was not different (p>0.05). However, at 70 days, KC induced a cellular response comparable to that elicited by control cement with respect to all evaluated cell types (p>0.05). In contrast, RU caused a cellular response characterized by a lower percentage of odontoblasts and a higher percentage of mononuclear cells than the control condition (p<0.05); however, the percentages of fibroblasts and PMNs were similar(p>0.05) (Figures 1and 2). No bacteria were observed in any group at either time point.

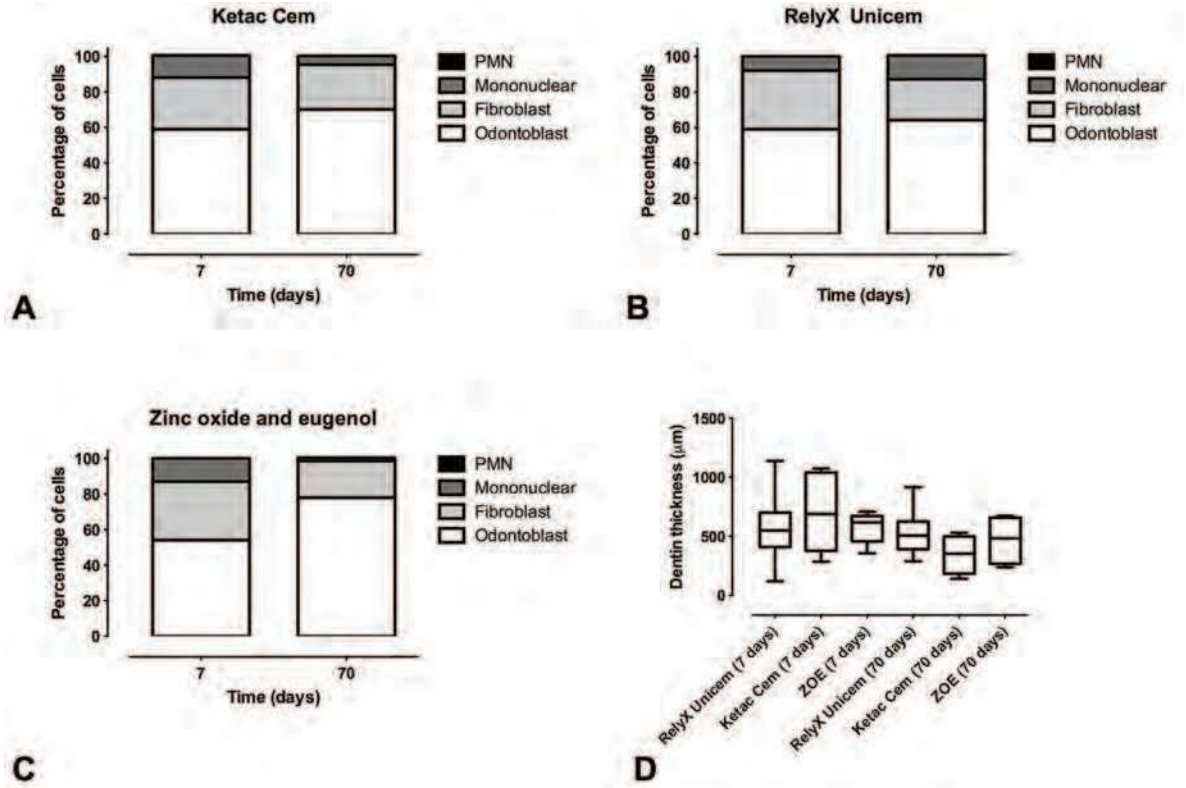

Figure 1: *Percentages of odontoblasts, fibroblasts, mononuclear cells, and polymorphonuclear (PMN) cells at 7 and 70 days.**A**- KC, **B**- RU, **C**- control. **D**- Dentin thickness (µm) in the different groups (KC, RU, and control) at 7 and 70 days. The middle bar represents the average dentin thickness for each group.*

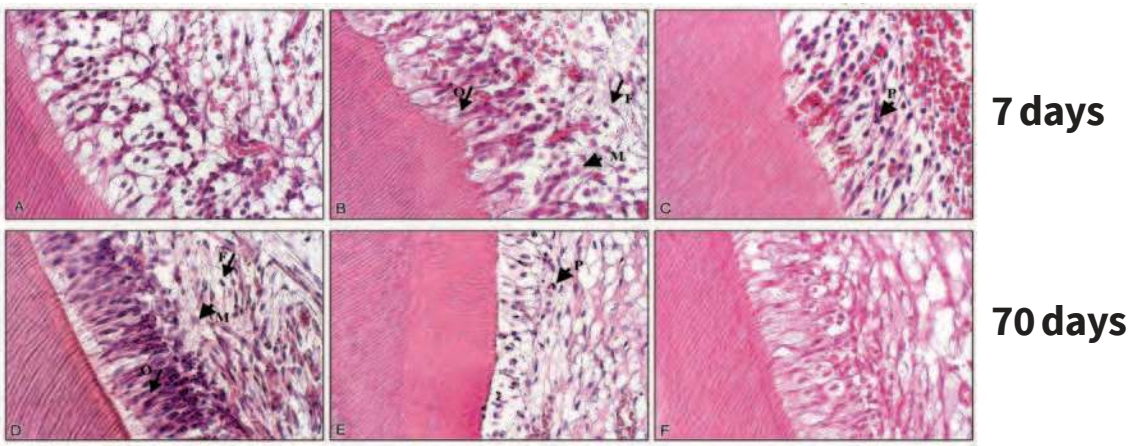

Figure 2: *Representative photomicrographs of the dentin-pulp complex of dog teeth immediately below the cavity floor at 7 (**A, B, C**) and 70 days (**D, E, F**) after indirect pulp capping with KC (**A, D**), RU (**B, E**), zinc oxide and eugenol (control; **C, F**), showing the integrity of pulp tissue. At 70 days, there was a lower density of odontoblasts in the RU group than in the KC and control groups. **O** stands for odontoblast, **F** stands for fibroblast, **M** stands for mononuclear inflammatory infiltrate, **P** stands for polymorphonuclear inflammatory infiltrate. Original magnification 40× (**E**), 63× (**A**-**D**, **F**)*

Immunohistochemical evaluation

No specimen was lost during the histopathological procedure; therefore, analysis was performed on all 56 teeth.

MMP-2 expression

KC (Figure 3)

At 7 days, predentin and odontoblasts were clearly stained, and a subset of mononuclear cells was also stained, particularly around the cellular membrane. Fibroblasts were stained weakly for MMP-2.

At 70 days, predentin was weakly stained, with no clear distinction from the remaining dentin. Positive cytoplasmic and perinuclear staining was observed in both odontoblasts and mononuclear cells. Fibroblasts were poorly stained.

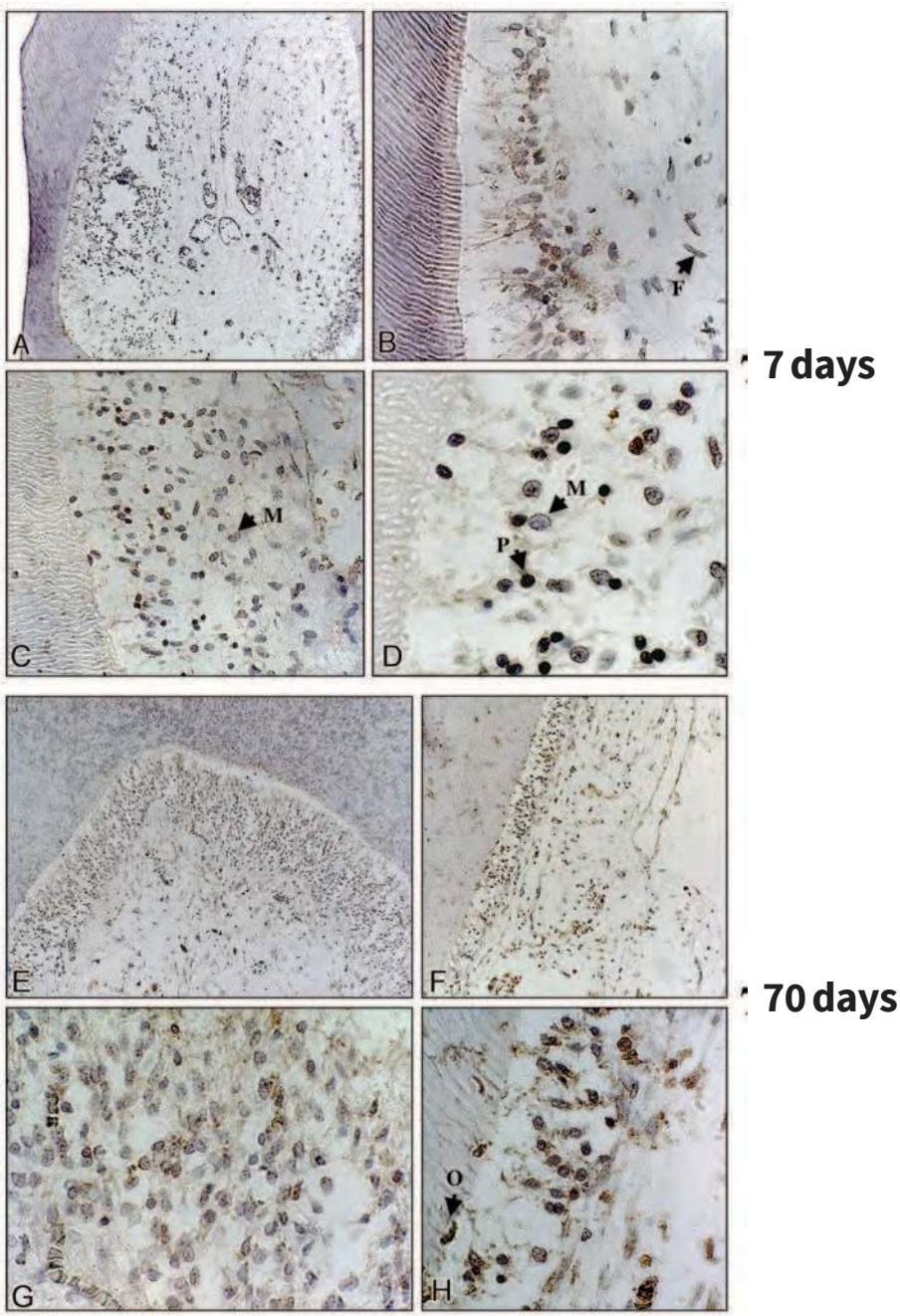

Figure 3: *MMP-2 immunohistochemistry in the dentin-pulp complex at 7 and 70 days after indirect pulp capping with KC. At 7 and 70 days, odontoblasts were clearly stained, but fibroblasts were not. Some mononuclear cells were also positive for MMP-2.* ***O*** *stands for odontoblast,* ***F*** *stands for fibroblast,* ***M*** *stands for mononuclear inflammatory infiltrate,* ***P*** *stands for polymorphonuclear inflammatory infiltrate. Original magnification 10× (**A, F**), 20× (**E**), 40× (**C**), 63× (**B, G, H**), 100× (**D**).*

RU (Figure 4)

Predentin was weakly stained at 7 days. Odontoblasts, mononuclear cells, and fibroblasts showed well-defined cytoplasmic and perinuclear staining.

At 70 days, predentin was weakly stained, and there was no clear distinction from the remaining dentin. Positive cytoplasmic and pericellular staining was observed in some odontoblasts and mononuclear cells. Fibroblasts were negative for MMP-2.

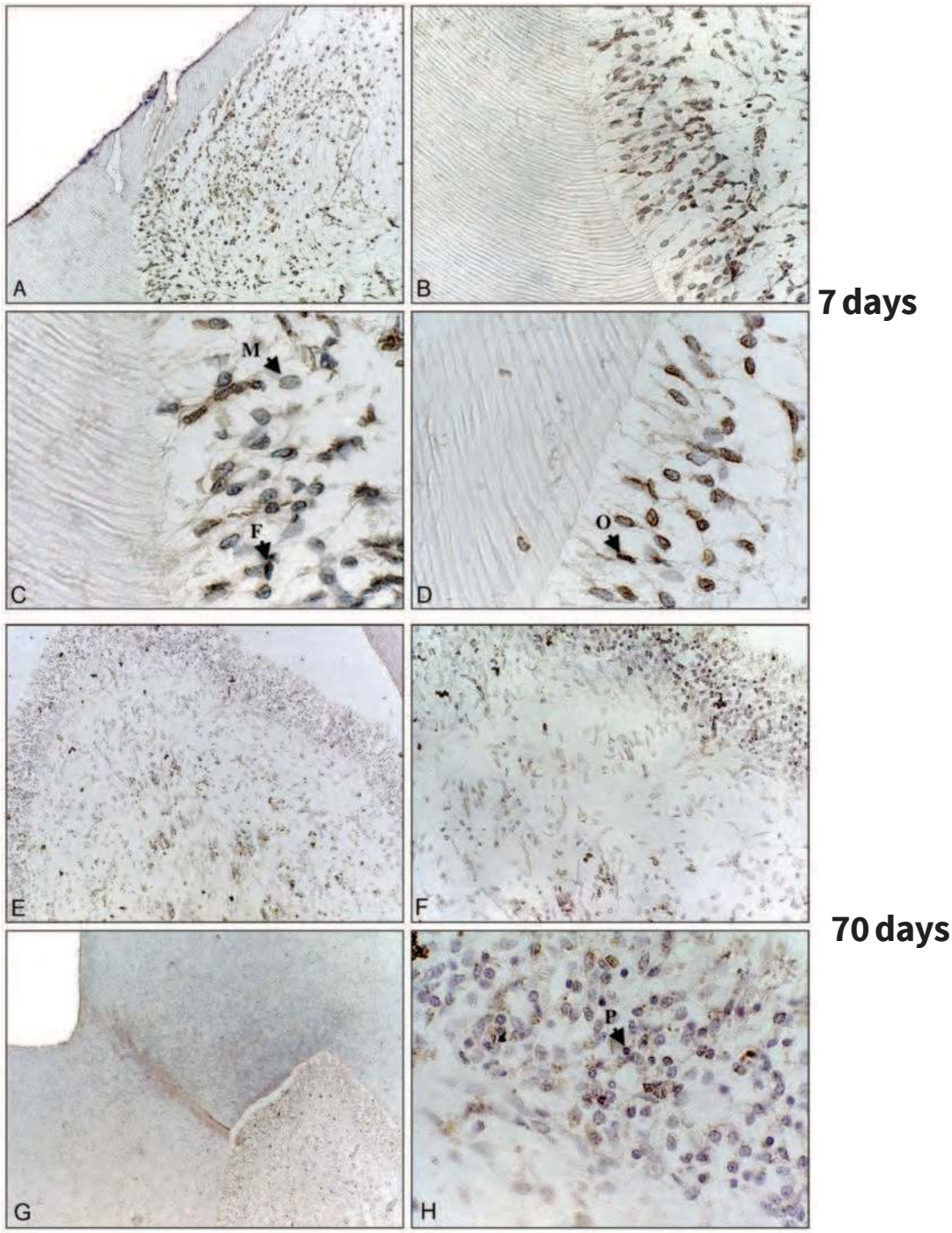

Figure 4: *MMP-2 immunohistochemistry in the dentin-pulp complex at 7 and 70 days after indirect pulp capping with RU.At 7 days, odontoblasts, mononuclear cells, and fibroblasts showed well-defined cytoplasmic and pericellular staining, and at 70 days, positive cytoplasmic and pericellular staining was observed in some odontoblasts and mononuclear cells. Fibroblasts were not positive for MMP-2.* ***O*** *stands for odontoblast,* ***F*** *stands for fibroblast,* ***M*** *stands for mononuclear inflammatory infiltrate,* ***P*** *stands for polymorphonuclear inflammatory infiltrate. Original magnification 5× (****G****), 10× (****A****, ****E****), 20× (****F****), 40× (****B****), 63× (****H****), 100× (****C****, ****D****).*

Zinc oxide and eugenol (control; Figure 5)

At 7 days, predentin was weakly stained. Some mononuclear cells and odontoblasts were stained. The stained mononuclear cells showed positivity around the membrane and occasional perinuclear staining. Fibroblasts were negative for MMP-2.

At 70 days, predentin was even more weakly stained for MMP-2, and a clear distinction with the remaining dentin was not observed. Positive cytoplasmic and perinuclear staining was observed in odontoblasts and mononuclear cells. Fibroblasts were not stained.

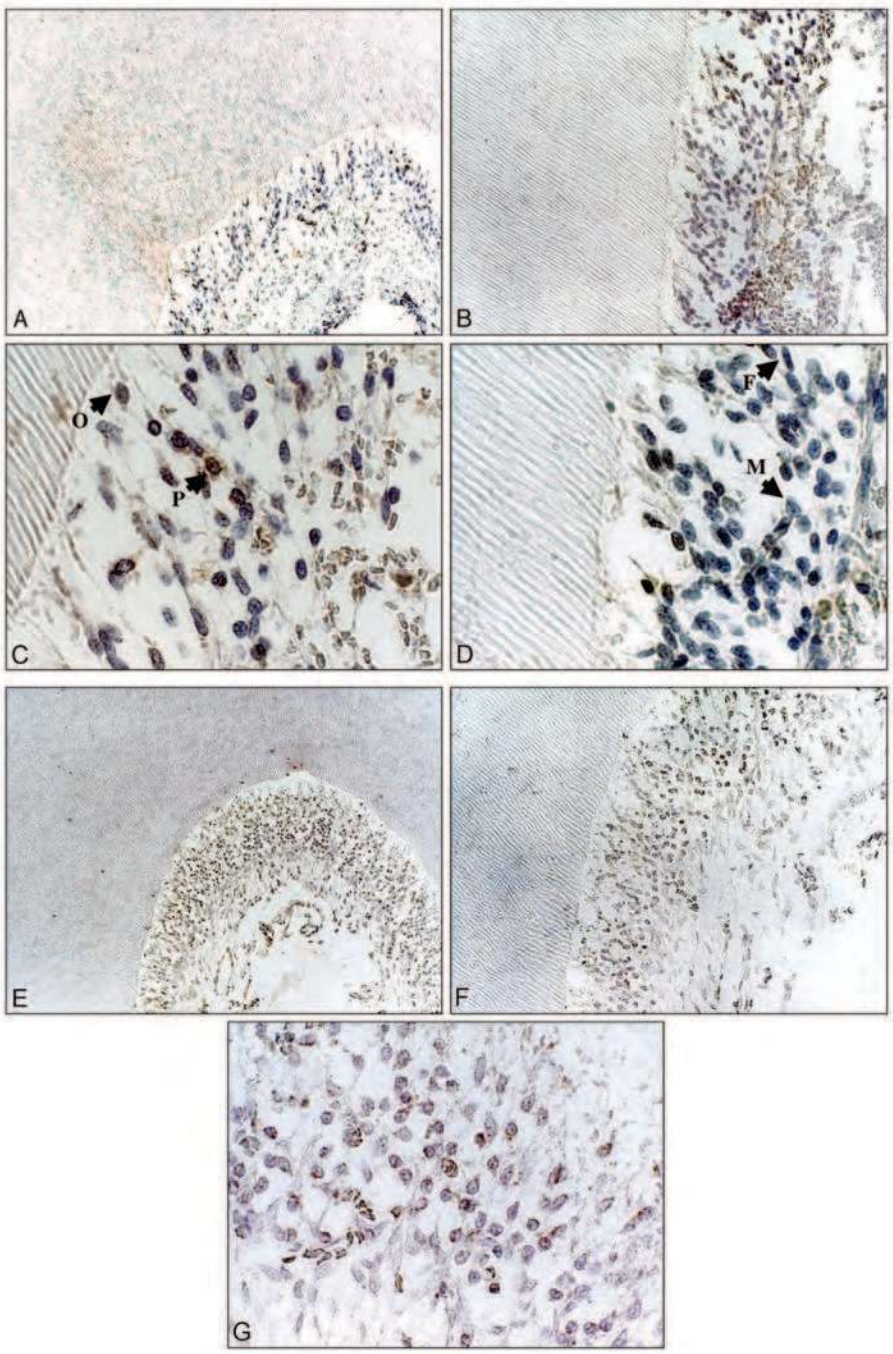

Figure 5: *MMP-2 immunohistochemistry in the dentin-pulp complex at 7 and 70 days after indirect pulp capping with zinc oxide and eugenol. At 7 days, predentin, odontoblasts and mononuclear cells were poorly stained, and positive staining was not evident in fibroblasts.* ***O*** *stands for odontoblast,* ***F*** *stands for fibroblast,* ***M*** *stands for mononuclear inflammatory infiltrate,* ***P*** *stands for polymorphonuclear inflammatory infiltrate. Original magnification 10× (**A**, **E**), 20× (**F**), 40× (**B**), 63× (**G**), 100× (**C**, **D**).*

MMP-9 expression

KC (Figure 6)

At 7 days, predentin was negative. Only a few odontoblasts and mononuclear cells were weakly stained, and there was no evidence of positive staining in fibroblasts.

At 70 days, predentin was not stained. Only a small sub set of odontoblasts and mononuclear cells were positive for MMP-9. Fibroblasts were not stained.

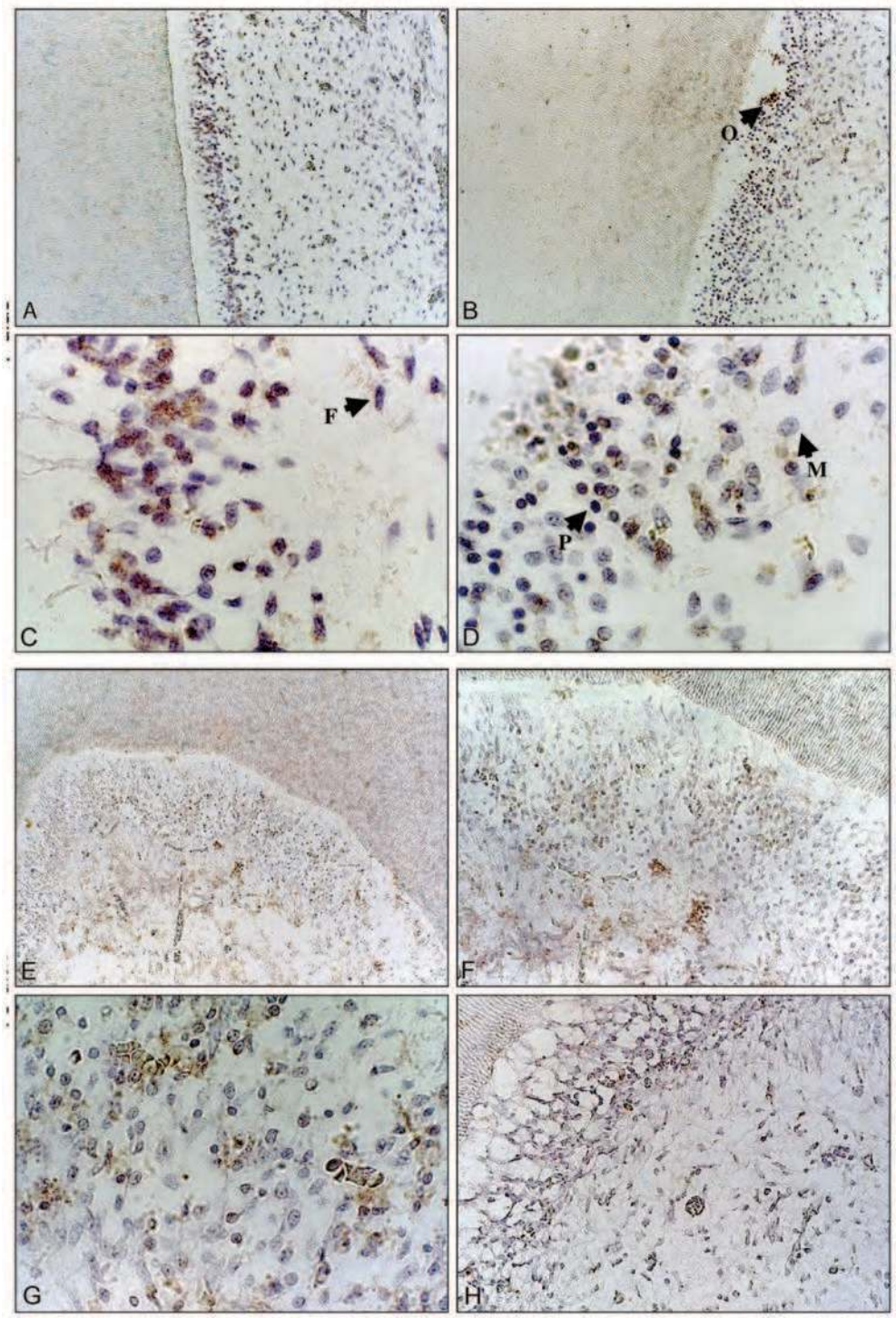

Figure 6: *MMP-9 immunohistochemistry in the dentin-pulp complex at 7 and 70 days after indirect pulp capping with KC. At 7 days, only a few odontoblasts and mononuclear cells were stained, with no evidence of positive staining in fibroblasts. MMP-9 staining decreased over time.* ***O*** *stands for odontoblast,* ***F*** *stands for fibroblast,* ***M*** *stands for mononuclear inflammatory infiltrate,* ***P*** *stands for polymorphonuclear inflammatory infiltrate. Original magnification 10× (**E**), 20× (**A**, **B**), 40× (**F**, **H**), 63× (**G**), 100× (**C**, **D**).*

RU (Figure 7)

At 7 days, predentin, odontoblasts, and mononuclear cells were slightly stained. There was no significant positive staining in fibroblasts.

At 70 days, predentin was negative for MMP-9. Most odontoblasts were also negative. Some mononuclear cells showed perinuclear staining, but most did not. Fibroblasts were not stained.

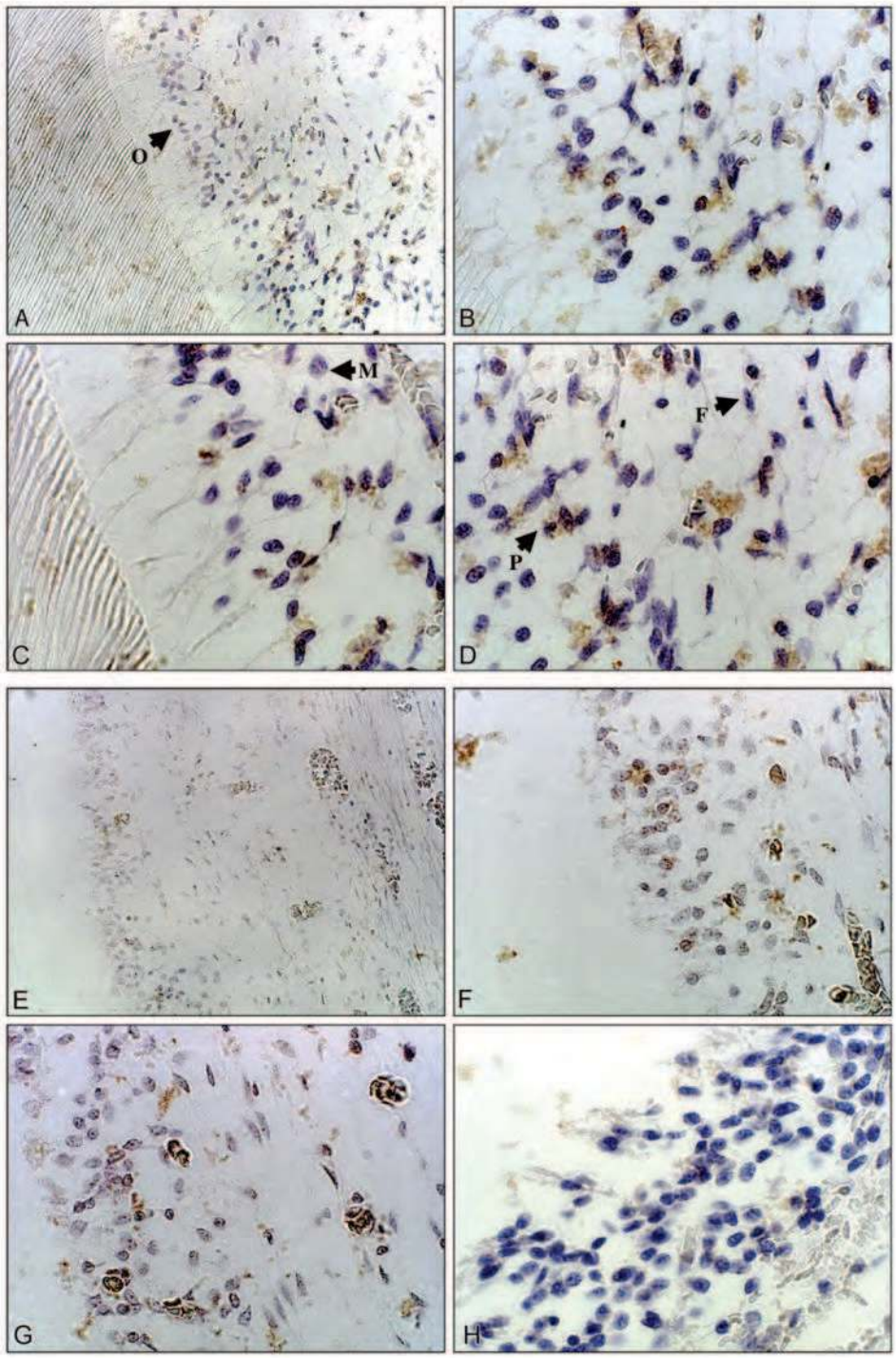

Figure 7: *MMP-9 immunohistochemistry in the dentin-pulp complex at 7 and 70 days after indirect pulp capping with RU. At 7 days, only a few odontoblasts and mononuclear cells were stained, with no evidence of positive staining in fibroblasts. MMP-9 staining decreased over time. Negative control: IgG.* ***O*** *stands for odontoblast,* ***F*** *stands for fibroblast,* ***M*** *stands for mononuclear inflammatory infiltrate,* ***P*** *stands for polymorphonuclear inflammatory infiltrate. Original magnification 40× (**A**,**E**), 63× (**F, G**), 100× (**B, C, D, H**).*

Zinc oxide and eugenol (control; Figure 8)

At 7 days, predentin, odontoblasts and mononuclear cells were poorly stained, and positive staining was not evident in fibroblasts.

At 70 days, predentin, mononuclear cells, and fibroblasts were negative for MMP-9, while some odontoblasts were weakly stained.

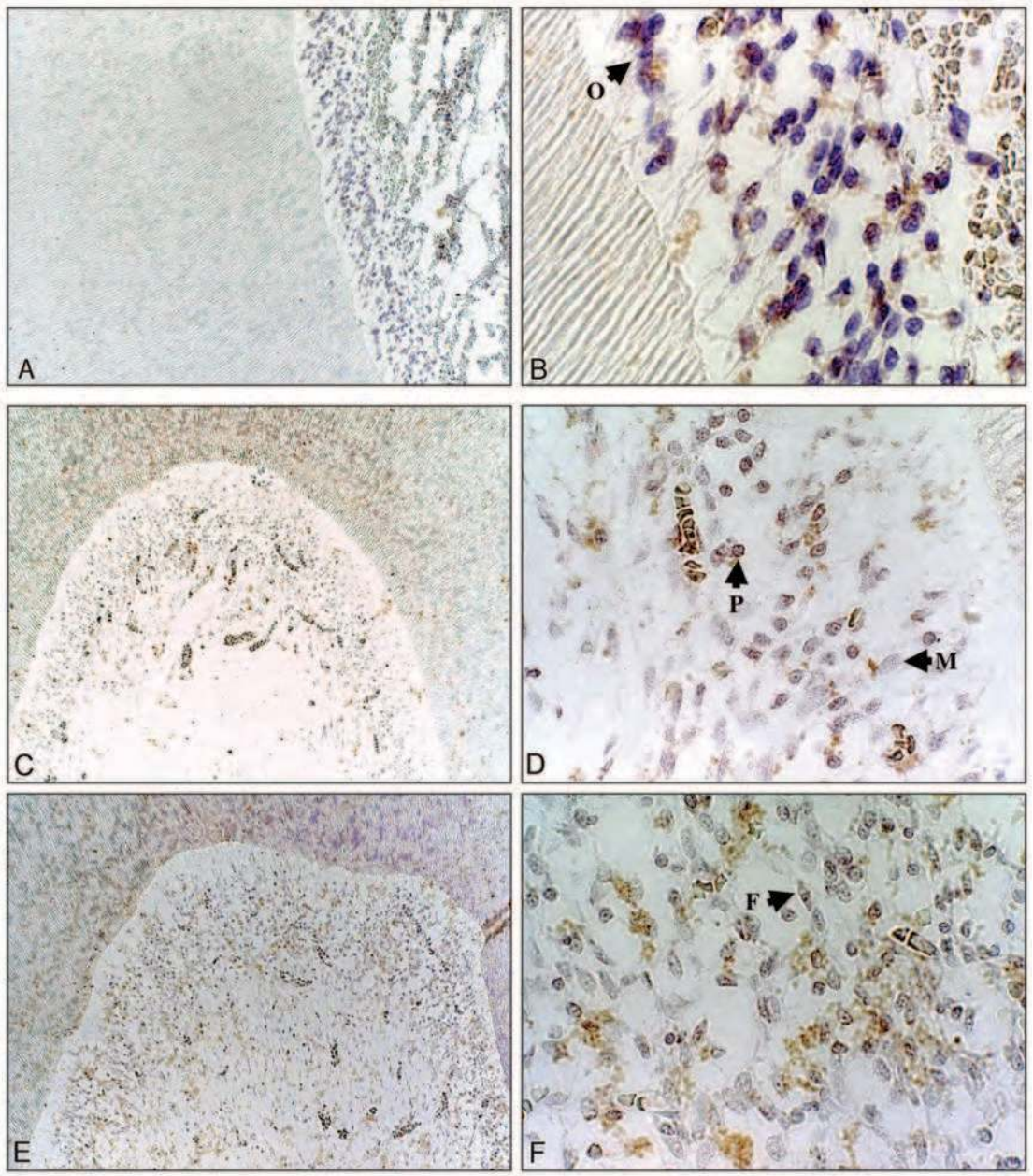

Figure 8: *MMP-9 immunohistochemistry in the dentin-pulp complex at 7 and 70 days after indirect pulp capping with zinc oxide and eugenol. At 70 days, predentin, mononuclear cells, and fibroblasts were negative for MMP-9, while some odontoblasts were weakly stained.* ***O*** *stands for odontoblast,* ***F*** *stands for fibroblast,* ***M*** *stands for mononuclear inflammatory infiltrate,* ***P*** *stands for polymorphonuclear inflammatory infiltrate. Original magnification 20× (****A****,* ***C****,* ***E****), 100× (****B****,* ***D****,* ***F****).*

DISCUSSION

In KC-treated teeth, higher percentages of odontoblasts and fibroblasts were observed 7 and 70 days after indirect pulp capping. Only a small percentage of mononuclear cells was observed at 7 days, and this value decreased over time. These results corroborate those of previous studies that KC has a low potential to cause cytotoxic and genotoxic effects[6,27,28] or induce inflammation *in vivo.*[15]

With respect to RU, fewer odontoblasts and greater numbers of mononuclear cells were observed compared with control and KC-treated teeth. However, there were no unsatisfactory pulp reactions with tissue damage at either time point, and odontoblasts and fibroblasts were the most prevalent cell types. These results corroborate those of a previous study, which reported minimal inflammatory response and tissue disruption at 7 and 60 days after indirect pulp capping of human teeth. However, a severe inflammatory response was observed when pulp was accidentally exposed.[14]

Several variables modulate RU cytotoxicity, depending, among other factors, on the curing strategy.[9] In the present study, the compatibility of RU after indirect pulp capping in deep cavities demonstrates that the remaining dentin, even if it is thin, can act as a barrier against the diffusion of possibly harmful chemical components in the material, thus avoiding direct contact of these components with the underlying connective pulp tissue and attenuating possible toxic effects.[29] Our findings support a previous *in vitro* investigation that used dentin disks to investigate the cytotoxicity of RU and found that more than 80% of cells remain viable after 24 hours or 7 days of indirect contact with the cement.[30] As recommended by ISO 7405:2008,[26] the cavities prepared in this study had a remaining dentin thickness ranging from 469 to 739 µm, with no difference between groups, and this may have limited the irritant effects of the cement on the pulp tissue.

Intense MMP-2 staining in the predentin area was only observed in KC-treated mice at 7 days, which appeared to be similar to dentin positivity at 70 days. For the RU,zinc oxide and eugenol cements, predentin was weakly stained for MMP-2 at 7 and 70 days. The increased expression of MMP-2 in the initial period after KC treatment can be attributed to its low initial pH. MMP-9 is an inflammatory marker in teeth with pulpitis,[20,21] and the low level of MMP-9 expression and minimal tissue inflammation observed in this study demonstrate that KC and RU are compatible with the dentin-pulp complex.

Weak acids are capable of activating dentin MMPs, which have collagenolytic and gelatinolytic activities.[23] The increase in MMP-2 expression at 7 days after using KC can be explained by its low initial pH.[31,32] MMP expression levels in the RU group were low and similar to the control group. This effect might be due to the material's pH, which increases from 2.0 to 4.0 during the first 60 minutes and to 7.0 after 24-48 hours.[33] Because it is not acidic after a day, it would not be likely to stimulate MMP activity.

From a clinical perspective, we believe that in adhesive restorations, a main issue is degradation of the hybrid layer. Currently, deterioration can be explained by the activation of endogenous enzymes such as MMPs present in the dentin, most likely due to the acidic properties of the adhesive systems.[34,35] Furthermore, we believe that, in general, the cementing agents used in the present study should not be used directly on the exposed pulp tissue. Although KC can be applied in deep dentin, RU should be preceded by the use of a protective agent on the pulp wall prior to cementation.

CONCLUSION

After indirect pulp capping of deep cavities in dog teeth, KC exhibited tissue compatibility similar to that of the control, whereas RU triggered a cellular response characterized by higher and lower percentages of mononuclear cells and odontoblasts, respectively. The luting agents induced low MMP-2 and-9 expression levels at 7 days and 70 days after indirect pulp capping.

ACKNOWLEDGEMENTS

The authors wish to thank Fundação de Amparo à Pesquisa do Estado de São Paulo (FAPESP #2009/54573-6 to LABS and #2005/57988-1 to THAA) and Conselho Nacional de Desenvolvimento Científico e Tecnológico (CNPq) for financial support. The authors do not report any conflicts of interest.

REFERENCES

1.Costa CAS, Giro EMA, Nascimento AB, Teixeira HM, Hebling J. Short-term evaluation of the pulpo-dentin complex response to a resin-modified glass-ionomer cement and a bonding agent applied in deep cavities. Dent Mater 2003; 19:739-746.

2.Jivraj SA, Kim TH, Donovan TE. Selection of luting agents:part 1. J Calif Dent Assoc 2006;34:149-60.

3.de la Macorra JC,Pradíes G. Conventional and adhesive luting cements. Clin Oral Investig 2002;6:198-204.

4.Manso AG, González-Lopez S, Bolaños-Carmona V, Maurício PJ, Félix SA, Carvalho PA. Regional bond strength to lateral walls in class I and II ceramic inlays luted with four resin cements and glass-ionomer luting agent. J Adhes Dent 2011;13:455-465.

5.Ferracane JL, Stansbury JW, Burke FJ. Self-adhesive resin cements - chemistry, properties and clinical considerations. J Oral Rehabil 2011;38:295-314.

6.Bakopoulou A, Mourelatos D, Tsiftsoglou AS, Giassin NP, Mioglou E, Garefis P. Genotoxic and cytotoxic effects of different types of dental cement on normal cultured human lymphocytes. Mutat Res 2009; 672:103-112.
7.Bitter K, Perdigão J, Hartwig C, Neumann K,Kielbassa AM. Nanoleakage of luting agents for bonding fiber posts after thermomechanical fatigue.J Adhes Dent 2011;13:61-69.
8.Mazzitelli C, Monticelli F, Toledano M, Ferrari M,Osorio R. Dentin treatment effects on the bonding performance of self-adhesive resin cements.Eur J Oral Sci 2010;118:80-86.
9.Monteiro GQ, Souza FB, Pedrosa RF, Sales GC, Castro CM, Fraga SN, et al. In vitro biological response to a self-adhesive resin cement under different curing strategies. Biomed Mater Res B Appl Biomater 2010;92:317-321.
10.Nakamura T, Wakabayashi K, Kinuta S, Nishida H, Miyamae M,Yatani H. Mechanical properties of new self-adhesive resin-based cement.J Prosthodont Res 2010;54:59-64.
11.Santos RL, Moura MF, Carvalho FG, Guênes GM, Alves PM, Pithon MM. Histological analysis of biocompatibility of ionomer cements with an acid-base reaction.Braz Oral Res 2014;28:1-7.
12.Schenke F, Federlin M, Hiller KA, Moder D,Schmalz G. Controlled, prospective, randomized, clinical evaluation of partial ceramic crowns inserted with RelyX Unicem with or without selective enamel etching: results after 2 years.Clin Oral Investig 2012;16:451-461.
13.Schmid-Schwap M, Franz A, König F, Bristela M, Lucas T, Piehslinger E, et al. Cytotoxicity of four categories of dental cements. Dent Mater 2009;25:360-368.
14.Souza Costa CA, Hebling J, Randall RC. Human pulp response to resin cements used to bond inlay restorations. Dent Mater 2006;22:954-962.
15.de Queiroz AM, Amaral THA, Paula-Silva FWG, Nelson-Filho P, Silva RAB, Gaton-Hernádez PM, et al. Luting agents differentially modulate inflammation and matrix metalloproteinases in connective tissue. Rev Cient CRO-RJ (Rio de Janeiro Dental Journal) 2018; 3:18-15.
16.Ulker HE, Sengun A. Cytotoxicity evaluation of self adhesive composite resin cements by dentin barrier test on 3D pulp cells. Eur J Dent 2009;3:120-6.
17.Krane SM, Inada M. Matrix metalloproteinases and bone. Bone 2008;43:7-18.
18.Martin-De Las Heras S, Valenzuela A, Overall CM. The matrix metalloproteinase gelatinase A in human dentine. Arch Oral Biol 2000;45:757-765.
19.Mazzoni A, Mannello F, Tay FR, Tonti GA, Papa S, Mazzotti G, Di Lenarda R, Pashley DH and Breschi L. Zymographic analysis and characterization of MMP-2 and -9 forms in human sound dentin. J Dent Res, 2007; 86: 436-440.
20.Gusman H, Santana RB, Zehnder M. Matrix metalloproteinase levels and gelatinolytic activity in clinically healthy and inflamed human dental pulps. Eur J Oral Sci 2002;110:353-357.
21.Tsai CH, Chen YJ, Huang FM, Su YF, Chang YC. The up regulation of matrix metalloproteinase-9 in inflamed human dental pulps. J Endod 2005;31:860-862.
22.Lehmann N, Debret R, Roméas A, Magloire H, Degrange M, Bleicher F, et al. Self-etching increases matrix metalloproteinase expression in the dentin-pulp complex. J Dent Res 2009;88:77-82.
23.Nishitani Y, Yoshiyama M, Wadgaonkar B, Breschi L, Mannello F, Mazzoni A, et al. Activation of gelatinolytic/collagenolytic activity in dentin by self-etching adhesives. Eur J Oral Sci 2006;114:160-166.
24.Tay FR, Pashley DH, Loushine RJ, Weller RN, Monticelli F, Osorio R. Self-etching adhesives increase collagenolytic activity in radicular dentin. J Endod 2006;32:862-868.
25.Santos MC, de Souza AP, Gerlach RF, Trevilatto PC, Scarel-Caminaga RM, Line SR. Inhibition of human pulpal gelatinases (MMP-2 and MMP-9) by zinc oxide cements. J Oral Rehabil 200;31:660-664.
26.International Standard Organization (ISO 7405:2008). Dentistry - Preclinical evaluation of biocompatibility of medical devices used in dentistry. Geneve, 2008.
27.Ribeiro DA, Marques ME, Salvadori DM. Biocompatibility of glass-ionomer cements using mouse lymphoma cells in vitro. J Oral Rehabil 2006;33:912-917.
28.Ribeiro DA, Marques ME, Salvadori DM. Genotoxicity and cytotoxicity of glass ionomer cements on Chinese hamster ovary (CHO) cells. J Mater Sci Mater Med 2006;17:495-500.
29.Stanley HR. Local and systemic responses to dental composites and glass ionomers. Adv Dent Res 1992;6:55-64.
30.Soares DG, Brito CA, Tavares da Silva RHB, Ribeiro APD, Hebling J, de Souza Costa CA. Cytocompatibility of HEMA–free resin–based luting cements according to application protocols on dentine surfaces. Int Endod J 2016;49:551-60.
31.Bapna MS, Mueller HJ. Leaching from glass ionomer cements. J Oral Rehabil 1994;21(5):577-83.
32.Perotti R, Perotti M. Variation, over time, in the pH of the materials used for pulpal-dentinal protection. A new measurement method. Minerva Stomatol;44(5):241-3.
33.3M ESPE. Technical product profile: Rely X Unicem. Germany (Seefeld): 3M ESPE Dental Products; 2007. 60p.
34.Altinci P, Mutluay M, Seseogullari-Dirihan R, Pashley D, Tjäderhane L, Tezvergil-Mutluay A. NaF Inhibits Matrix-Bound Cathepsin-Mediated Dentin Matrix Degradation. Caries Res. 2016;50(2):124-32.
35.Tjäderhane L, Nascimento FD, Breschi L, Mazzoni A, Tersariol ILS, Geraldeli S, Tezvergil-Mutluay A, Carrilho M, Carvalho RM, Tay FR, Pashley DH. Strategies to prevent hydrolytic degradation of the hybrid layer - A review. Dent Mater 2013;29(10):999-1011.