# DIRECT BONDED SPACE MAINTAINER: AN ALTERNATIVE IN CLINICAL PRACTICE AFTER UNILATERAL PREMATURE LOSS OF POSTERIOR PRIMARY TOOTH

Camila Silva de **Amorim**[1], Gabriella Fernandes **Rodrigues**[1], Rafael dos Reis **Moraes**[1], Lucianne Cople **Maia**[1], Matheus Melo **Pithon** [2*]

[1]Department of Pediatric Dentistry and Orthodontics, Universidade Federal do Rio de Janeiro (UFRJ), Rio de Janeiro, RJ, Brazil.
[2]Department of Healthy I, Southwest Bahia State University (UESB), Jequié, BA, Brazil and Department of Pediatric Dentistry and Orthodontics, Universidade Federal do Rio de Janeiro (UFRJ), Rio de Janeiro, RJ, Brazil.

**Palavras-chave:** Mantenedor de Espaço. Dente Decíduo. Resina Composta. Má Oclusão.

**RESUMO**

**Introdução:** A dentição decídua é de extrema importância, pois exerce função mastigatória, atua como guia de erupção para os dentes permanentes, estimula o crescimento ósseo e auxilia na digestão e fonação. Em casos de perda prematura de algum dente, é necessário que o profissional faça um planejamento adequado para manutenção do espaço, de forma que este não seja perdido até a erupção do sucessor permanente, evitando assim o estabelecimento de más-oclusões. **Objetivo:** Descrever as etapas clínicas para confecção e instalação do aparelho mantenedor de espaço adesivo, bem como o acompanhamento até a erupção do sucessor. **Relato do caso:** Menina, 8 anos, apresentou fístula adjacente ao segundo molar inferior direito decíduo. Após avaliação clínica e radiográfica, foi indicada a exodontia do dente, devido à impossibilidade de realizar o tratamento endodôntico. Confeccionou-se e instalou-se o aparelho mantenedor de espaço adesivo, como uma alternativa ao banda-alça, comumente utilizado nesses casos de perda unilateral. **Conclusão:** O mantenedor de espaço colado foi uma boa opção para o caso apresentado, pois foi capaz de cumprir sua função até a erupção do dente sucessor, constituindo-se uma boa alternativa na prática clínica, devido à otimização do tempo e economia de material que proporciona.

**Keywords:** Space Maintenance. Deciduous Tooth. Composite Resins. Malocclusion.

**ABSTRACT**

**Introduction:** The primary dentition is extremely important, because besides the importance during chewing, acts as a guide to eruption for permanent teeth, stimulates the bone growth and helps in digestion and phonation. In cases of premature loss, it is necessary that the professional make adequate planning to space maintenance, so that it is not lost until the eruption of the permanent successor, thus avoiding the establishment of malocclusions. **Objective:** To describe the clinical steps for preparation and placement of a direct bonded space maintainer, as well as the follow-up until the eruption of the successor tooth. **Case report:** Girl, eight years old, presented an adjacent fistula to the primary mandibular right second molar. After clinical and radiographic evaluation, tooth extraction was indicated, due to the impossibility of performing the endodontic treatment. A direct bonded space maintainer was made and installed as an alternative to the band and loop, commonly used in these cases of unilateral loss. **Conclusion:** The direct bonded space maintainer was a good option for the case presented, as it was able to fulfill its function until the eruption of the successor tooth. It is a good alternative in clinical practice due to the time optimization and material savings it provides.

Submitted: Febuary 14, 2019
Modification: March 20, 2019
Accepted: March 25, 2019

***Correspondence to**:
Matheus Melo Pithon
Address: Av. Otávio Santos, 395, sala 705, Centro Odontomédico Dr. Altamirando da Costa Lima, Recreio, CEP 45020-750 – Vitória da Conquista – Bahia, Brazil
Telephone Number:
E-mail: matheuspithon@gmail.com

## INTRODUCTION

The primary dentition is very important because besides the importance during chewing, acts as a guide for the eruption of permanent teeth, stimulates the bone growth and aids in digestion and phonation.[1] Therefore, premature loss of primary teeth can result in some negative consequences in both dentitions and cause an imbalance in the normal development of the stomatognathic system.[1]

Some of the main reasons that lead to premature extraction of deciduous teeth are pulpal pathology and alveolar bone abscess due to carious lesions or trauma.[2, 3] The loss of primary teeth before normal physiological exfoliation might result in the collapse of vertical and horizontal occlusal relationships in primary and permanent dentitions.[4] In this way, the placement of space maintainers becomes necessary after premature loss of primary teeth to preserve the integrity of the dental arch.[5]

Although the literature is divergent on the indication of space maintainers, it is generally considered important for children during the mixed dentition stage,[3] being important to consider the child's stage of dental development, the dental arch involved and what primary tooth is missed [6]. One of the most commonly used space maintainers in pediatric dentistry is the band and loop,[7] which is indicated for the premature loss of single, unilateral or bilateral, maxillary or mandibular primary molars.[4]

Some complications related to the use of the band and loop space maintainer include, caries as a result of cement loss, loop fracture with the wire embedded into the gingival tissues, an inability to control for rotations or tipping of the supporting teeth, and gingival inflammation.[8] There are also financial disadvantages related to the lab cost and the chair time for the two appointments associated with preparation of the device and delivery. [3] These disadvantages have led to the development of space maintainers using new designs and materials, such as the use of direct bonded space maintainers.[8]

Therefore, the aim of this case report is to describe the clinical steps for preparation and placement of a direct bonded space maintainer, as well as the follow-up until the eruption of the successor tooth.

## CASE REPORT

Girl, eight years old, attended at Pediatric Dentistry Dental Clinic at School of Dentistry – Universidade Federal do Rio de Janeiro with a chief complain of swelling of the right side of the mouth, near the tooth. Medical history revealed no systemic abnormalities. At the oral examination, the child was in the mixed dentition, and presented palate atresia, Angle class II molars, convex profile, 5 mm overjet and anterior open bite associated had mouth breathing. A Composite Resin restoration was found in primary mandibular left first molar, a Glass Ionomer restoration was found in the primary mandibular right second molar (Figure 1A) with adjacent fistula (Figure 1B) and absence of active carious lesions in the remaining teeth.

At the radiographic examination of the primary mandibular right second molar, radiopaque restorative material was observed in half of the dentin extension, with an underlying radiolucent area (Figure 2A). In the panoramic radiography previously requested to aid in orthodontic planning, it was observed the root of the deciduous tooth had more than 2/3 rhizolyze and the permanent successor was in Nölla's stage 7 (Figure 2B). Due to the clinical and radiographic characteristics, the extraction of the primary mandibular right second molar and the placement of a direct bonded space maintainer were indicated. To avoid contamination of the conditioned enamel with blood, the bonding of the maintainer was performed before the extraction. The child was cooperative and all the clinical procedure was performed in a single appointment, without the need of previous molding to make the maintainer.

To begin, the referring space to the tooth which would be extracted was measured using a millimeter ruler (Maquira, Maringa, PR, Brazil). The measurement was transferred for the stainless steel wire 0,9mm, 036" (Morelli, Sorocaba, SP, Brazil) with aid a pen (Pilot, São Paulo, SP, Brazil) (Figure 3A). Straight folds (Figure 3BC) with loopings at its ends (Figure 3D) to increase retention of composite resin were made with the help of bird beak pliers #139 (Starlet, São Paulo, SP, Brazil). The supporting teeth used for the placement of the maintainer were the permanent mandibular right first molar and mandibular right first premolar.

The bonding was performed after the teeth prophylaxis with a paste of pumice stone (SS White, São Paulo, SP, Brazil) and water, with the aid of a rubber cup (Microdont, São Paulo, SP, Brazil) in low-speed motor. Enamel conditioning was performed with 37% phosphoric acid (Condac 37, FGM, Joinville, SC, Brazil), for thirty seconds, washing with water for twice the time, adhesive system application (Prime & Bond 2.1, Dentsply, Petrópolis, RJ, Brazil) and bonding the wire to the teeth with composite resin (Z100, 3M ESPE, Saint Paul, MN, USA), following the manufacturer's instructions.

The tooth extraction was performed after drying the mucosa, topical (Benzotop 200mg/g, Rio de Janeiro, RJ, Brazil) and local anesthesia of the inferior alveolar and lingual nerves, with complementation in vestibular papilla, using lidocaine 2% with epinephrine 1: 100.000 (Alphacaine 100,

DFL, Rio de Janeiro, Brazil). The tooth was detached and dislocated with the aid of a Molt detacher (Duflex/ SS White, São Paulo, SP, Brazil) and child forceps # 21 (Quinelato, São Carlos, SP, Brazil).

After hemostasis of the region, both the child and the parents were instructed that food should be liquid/pasty and cold on the first two days. To facilitate clot formation in the alveolus, it was advised that the child should rest during the day, after the extraction, in a way that the head would be higher in relation to the body. In addition, it was informed that the anesthesia would last for a few hours and that they should be aware of the child's behavior during this period, preventing her from biting the cheek/lips and consequently a soft tissue trauma.

Instructions on care after placement of the device were also passed. The oral hygiene instructions were reinforced, encouraging flossing daily and brushing with fluoride dentifrice, supervised by parents at least at night. Furthermore, it was advised to avoid chewing hard and/or sticky foods on the device. Besides that, if any failure occurred, especially the wire fracture or adhesive failure in one or both supporting teeth, parents and patient were instructed to make contact with the professionals responsible for the treatment. The child was asked to return in seven days for healing follow-up.

Every twenty-seven days, a follow-up was done to check the adherence of the maintainer or any situations that were out of the expected. Approximately three months after, in the appointments performed during interceptive orthodontic treatment, the eruption of the successor tooth was observed (Figure 4). In this way, the direct bonded space maintainer was removed and the remaining composite resin was removed with multilayer drills in low-speed. The occlusion was checked and the enamel of the supporting teeth was polished.




***Figure 1:*** *A - Composite resin restoration in primary mandibular left first molar, Glass Ionomer restoration in primary mandibular right second molar. B - Dental fistula adjacent to the primary mandibular right second molar.*

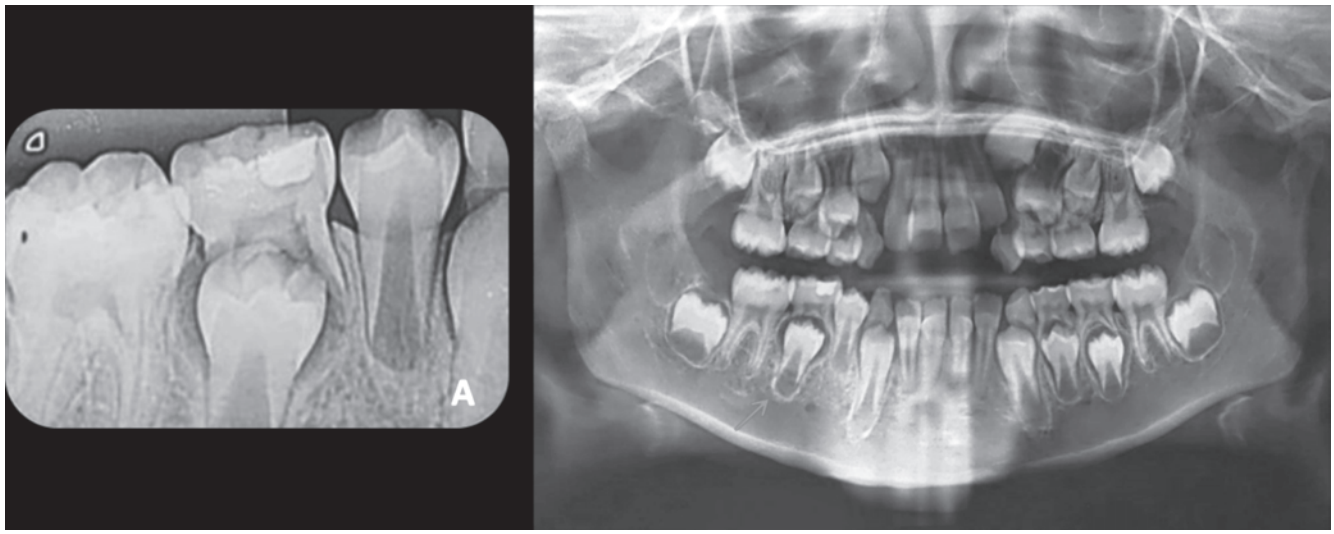


***Figure 2****: A - Periapical radiograph showing radiopaque restorative material in half of the dentin extension, with an underlying radiolucent area. B - Panoramic radiograph showing the root of the deciduous tooth had more than 2/3 rhizolyte and the permanent successor was in Nölla's stage 7.*




***Figure 3**: A - Transfer of space from the tooth to the wire. B- Straight folds over pen markings. C - Check of space measurement after wire fold. D - Maintainer completed after the looping realization at the ends that would be bonded on the teeth.*

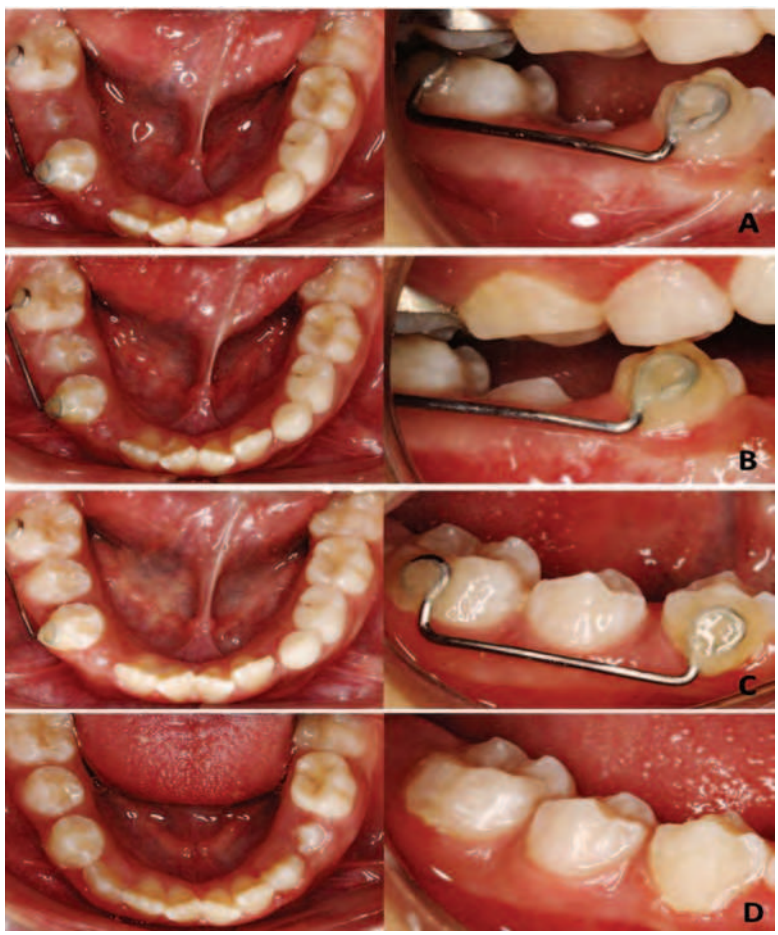


***Figure 4**: Clinical follow-up of the direct bonded space maintainer and sucessor eruption. A - Twenty-seven days later. B - Fifty-four days later. C - Eighty one days later. D - Clinical appearance after the removal of the device.*

## DISCUSSION

As described in the case report, the primary mandibular right second molar had a dental fistula and the extraction was indicated due to advanced rhizolysis and impossibility of endodontic treatment. According to the literature, tooth loss after Nölla's stage 6, causes acceleration of eruption of the successor tooth, however if it occurs before Nölla's stage 8, it is indicated the placement of the space maintainer.[9] As the child's tooth was still in Nölla's stage 7, it was chosen by the direct bonded space maintainer, whose effectiveness in preserving the space loss has been proven in previous studies.[10-12]

This type of space maintainer can easily be prepared by the professional during the dentist appointment, without the need of lab stage.[11] This is one of the advantages of the present adhesive maintainer compared with the traditional and most used band and loop space maintainer for posterior unilateral loss.[4] In addition to the time-saving, because it is done in a single step, there is also material saving. Alginate impressions are usually made to construct a working dental stone model, to serve as a basis for making the device.[8] However, in this case, the stainless steel wire was folded and adjusted directly on the supporting teeth, thus eliminating material expenditure and one more clinical step.

The most common cause of failure of direct bonded space maintainers is the failure of the composite-enamel bond.[13] However, due to the fact that primary extraction happened when the radicular formation of the permanent was in Nölla's stage 7, there was an acceleration in its eruption and the maintainer only stayed for a period of three months, such failure was not observed throughout the treatment. In a study found in the literature, the mean survival length in months was 9.20.[8] Due to the time of treatment reported to have been lower than that generally observed, the failures may not have occurred. However, it is important to keep in mind that maintainers should be selected, with the expectation that the period of space maintenance will likely require replacements, repairs and perhaps even a number of different types of space maintainers until the endpoint of therapy.[13]

Parents and patient collaboration for the proposed treatment, following the instructions given at the time of the device placement, are essential for the good prognosis of the case. Another fact that may have collaborated for not to have adhesiveness failure, was that unlike the design of direct bonded space maintainers made in other studies,[8,10,11] in this case report a looping was made at the ends of the wire, where the composite resin would be added, offering greater retention. This looping by generating a rounded contour would also prevent a piercing lesion in the child mucosa if this maintainer loosened. In addition, all steps of the adhesive technique were followed carefully and using good quality materials. The different space maintainer designs, bonding systems, and resin materials used in the different studies can explain the variation of the failure rate of these maintainers between the studies.[8]

It is known that there is no strong evidence that favors a particular method of space maintenance.[13] However, in face of the premature loss of primary molars, it is necessary to plan and deliver the more appropriate space maintainer, even knowing that space maintenance starts with preserving natural teeth free of caries.[14] To determine the best maintainer for each case, it is important to perform a good diagnosis, keeping in mind the estimated time that the maintainer will be used until the eruption of the successor tooth. The integrity of the appliance also depends on the correct execution of the chosen technique and the maintenance in periodic appointments, such as those in this case that were monthly.

In this way, this case report can conclude that the direct bonded space maintainer was a good choice for the case presented, because it was able to fulfill its function until the successor tooth eruption. For providing time optimization and material savings, can be used in situations where there is a limitation of available materials, as in the public service. Also, in cases where the acceleration of the successor's eruption is expected and the time of stay in function is lower, minimizing the chance of failures to occur.

## ACKNOWLEDGEMENT

This Case Report was conducted during the master's stage of Camila Silva de Amorim under the supervision of the Prof. Matheus Melo Pithon. This Case Report was partially supported by Coordenação de Aperfeiçoamento de Pessoal de Nível Superior – Brasil (CAPES) – Finance code 001

## REFERENCES

1. Lopez-Gomez SA, Villalobos-Rodelo JJ, Avila-Burgos L, Casanova-Rosado JF, Vallejos-Sanchez AA, Lucas-Rincon SE, et al. Relationship between premature loss of primary teeth with oral hygiene, consumption of soft drinks, dental care, and previous caries experience. Scientific reports. 2016;6:21147.

2. Dentistry AAoP. Management of the Developing Dentition and Occlusion in Pediatric Dentistry. Pediatric dentistry. 2017;39(6):334-47.

3. Law CS. Management of premature primary tooth loss in the child patient. Journal of the California Dental Association. 2013;41(8):612-8.

4. Srivastava N, Grover J, Panthri P. Space Maintenance with an Innovative "Tube and Loop" Space Maintainer (Nikhil Appliance). International journal of clinical pediatric dentistry. 2016;9(1):86-9.
5. Lin YT, Lin WH, Lin YT. Immediate and six-month space changes after premature loss of a primary maxillary first molar. Journal of the American Dental Association (1939). 2007;138(3):362-8.
6. Qudeimat MA, Fayle SA. The longevity of space maintainers: a retrospective study. Pediatric dentistry. 1998;20(4):267-72.
7. Qudeimat MA, Sasa IS. Clinical success and longevity of band and loop compared to crown and loop space maintainers. European archives of paediatric dentistry : official journal of the European Academy of Paediatric Dentistry. 2015;16(5):391-6.
8. Tunc ES, Bayrak S, Tuloglu N, Egilmez T, Isci D. Evaluation of survival of 3 different fixed space maintainers. Pediatric dentistry. 2012;34(4):e97-102.
9. Ruellas A, Nojima, MC, Araújo, MTS, Sant'anna, EF, Freitas, AOA. Análise das dentições, manutenção e recuperação de espaço, pequenos movimentos. In: Maia L, Primo, LG. Odontologia integrada na infância. 1. São Paulo: Gen/ Santos; 2012.
10. Santos VL, Almeida MA, Mello HS, Keith O. Direct bonded space maintainers. The Journal of clinical pediatric dentistry. 1993;17(4):221-5.
11. Simsek S, Yilmaz Y, Gurbuz T. Clinical evaluation of simple fixed space maintainers bonded with flow composite resin. Journal of dentistry for children. 2004;71(2):163-8.
12. Yilmaz Y, Kocogullari ME, Belduz N. Fixed space maintainers combined with open-face stainless steel crowns. The journal of contemporary dental practice. 2006;7(2):95-103.
13. Ahmad AJ, Parekh S, Ashley PF. Methods of space maintenance for premature loss of a primary molar: a review. European archives of paediatric dentistry : official journal of the European Academy of Paediatric Dentistry. 2018;19(5):311-20.
14. Simon T, Nwabueze I, Oueis H, Stenger J. Space maintenance in the primary and mixed dentitions. The Journal of the Michigan Dental Association. 2012;94(1):38-40.