PULPAL AND PERIAPICAL RESPONSE OF DOGS' TEETH AFTER PULPOTOMY AND USE OF ENAMEL MATRIX DERIVATIVE AS A CAPPING AGENT

Léa Assed Bezerra da **Silva**[1*], Lisa Danielly Curcino **Araujo**[1], Marcela Martín del Campo **Fierro**[1], Francisco Wanderley Garcia de **Paula-Silva**[1], Raquel Assed Bezerra da **Silva**[1], Paulo **Nelson Filho**[1], Alberto **Consolaro**[1], Mário Roberto **Leonardo**

[1]Department of Pediatric Clinic, School of Dentistry of Ribeirão Preto, University of São Paulo, Ribeirão Preto, SP, Brazil.

Palavras-chave: Pulpotomia. Esmalte Dentário. Hidróxido de Cálcio. Óxido de Zinco e Eugenol.

RESUMO

Objetivo: Avaliar a resposta pulpar e periapical de dentes de cães após pulpotomia e uso de Derivados de Matriz de Esmalte (EMD) como agente de capeamento. **Métodos**: A pulpotomia foi realizada em 40 dentes de 4 cães e o tecido pulpar remanescente foi recuperado com os seguintes materiais: Grupos I e IV: EMD (Emdogain®); Grupos II e V: hidróxido de cálcio; Grupos III e VI: cimento de óxido de zinco e eugenol. Após 7 dias (Grupos I, II e III) e 70 dias (Grupos IV, V e VI), os animais foram eutanásiados e os dentes foram removidos e processados para análise histológica; foram analisados pelo teste de Kruskal-Wallis, seguido pelo teste de Dunn ou Mann Whitney ($\alpha = 0,05$). **Resultados**: Período de 7 dias: no Grupo I, observou-se infiltrado inflamatório leve a moderado e intensa proliferação vascular, enquanto o Grupo II apresentou infiltrado inflamatório leve e tecido pulpar intacto ($p < 0,05$). O grupo III apresentou infiltrado inflamatório moderado a grave. Período de 70 dias: os grupos IV e VI mostraram, na formação da ponte de dentina, que o tecido pulpar remanescente apresentava áreas necróticas com células inflamatórias na região periapical, reabsorção óssea e de cemento ($p > 0,05$). No Grupo V, houve formação de ponte de dentina, ausência de inflamação e ausência de reabsorção tecidual mineralizada ($p < 0,05$). **Conclusão**: O EMD como material de cobertura após pulpotomia não mostrou resposta tecidual satisfatória ou capacidade de induzir deposição de tecido mineralizado na polpa dentária.

Keywords: Pulpotomy. Dental Enamel. Calcium Hydroxide. Zinc Oxide and Eugenol.

ABSTRACT

Objective: To evaluate the pulpal and periapical response of dogs' teeth after pulpotomy and use of Enamel Matrix Derivative (EMD) as capping agent.

Methods: Pulpotomy was performed in 40 teeth from 4 dogs and the remaining pulp tissue was recovered with the following materials: Groups I and IV: EMD (Emdogain®); Groups II and V: calcium hydroxide; Groups III and VI: zinc oxide and eugenol cement. After 7 days (Groups I, II, and III) and 70 days (Groups IV, V, and VI), the animals were euthanized and the teeth were removed and processed for histological analysis; were analyzed using Kruskal-Wallis test followed by Dunn test or Mann Whitney test (α=0.05). **Results**: *7-day period:* in Group I, it was observed a mild to moderate inflammatory infiltrate and intense vascular proliferation while Group II presented a mild inflammatory infiltrate and an intact pulp tissue ($p < 0.05$). Group III presented a moderate to severe inflammatory infiltrate. *70-day period*: Groups IV and VI showed no dentin bridge formation, the remaining pulp tissue presented necrotic areas with inflammatory cells in the periapical region and bone and cementum resorption ($p > 0.05$). In Group V, there was dentin bridge formation, absence of inflammation and absence of mineralized tissue resorption ($p < 0.05$). **Conclusion**: EMD as a capping material after pulpotomy did not show either satisfactory tissue response or capacity of inducing deposition of mineralized tissue in dental pulp.

Submitted: April 29, 2019
Modification: August 25, 2019
Accepted: September 9, 2019

***Correspondence to:**
Léa Assed Bezerra da Silva
Address: Rua Hortêncio Mendonça Ribeiro, 414 – Alto da Boa Vista. Ribeirão Preto – SP – Brasil. Zip code:14025-590.
Telephone number: +55 (16) 3602-3984
E-mail: lea@forp.usp.br

INTRODUCTION

The objective of pulpotomy is to induce a dentinogenic reparative response after amputation of inflamed dental pulp. Although calcium hydroxide and mineral trioxide aggregate are the materials of choice for this procedure, mostly because the ability to forms a dentine bridge completely, several bioactive agents have been developed for pulp capping, including enamel matrix derivative (EMD).[1,2] Some studies have suggested that EMD stimulates odontoblastic differentiation and subsequent collagen matrix mineralization[3,4] to achieve dentinogenesis.[5,6]

Emdogain® is a gel that consists of EMD in a vehicle of propylene glycol alginate (PGA), used to induce biological regeneration in cases of loss of insertion of the periodontal ligament via promoting proliferation, migration and differentiation of fibroblasts from the periodontal ligament (PDL).[7,8] This formulation contains an extract of enamel matrix proteins of low molecular weight, mainly amelogenin. Emdogain® is produced by heat of EMD and PGA to reduce the risk of microbial contamination.[9] Clinical evaluations have demonstrated that Emdogain® induces regeneration of cement, insertion of PDL fibers, and bone repair.[8,10-15]

Although Emdogain® have been evaluated regarding the capacity of induce dentin repair after direct pulp capping,[3-6;16,17] the results have been divergent.[18] Some authors described that EMD induces the deposition of a newly formed "dentin-like" tissue.[3,5,6,17] On the other hand, other authors demonstrated that the ability to form a structural barrier to protect the pulp is unlikely, since the EMD induces the formation of disorganized islets of mineralized tissue.[2,18,19,20]

Although the enamel matrix derivative (Emdogain®) has been widely evaluated for PDL regeneration, few studies have been aimed to evaluate the use of this material in the conservative therapy of pulp tissue. Therefore, the purpose of this study is to evaluate the pulpal and periapical response of dogs' teeth after pulpotomy and use of EMD as capping agent, comparing with others materials.

MATERIAL AND METHODS

Operative procedures

The experimental protocol was conducted in compliance with the specifications of the Animal Experimentation Ethics Committee of the University of São Paulo, Brazil (#2008.1.87.53.9) and according to International Organization for Standardization 7405:2008.[21]

The second, third and fourth mandibular premolars, and the second and third maxillary premolars of 4 twelve-month-old male and female dogs of undefined breed, coming from the same litter and weighing 15 kg were selected for this study. A total of 40 teeth (80 roots) were assigned to 6 groups as described in (Table 1).

The animals were anesthetized intravenously with Neozine (1 mg/kg body weight; Aventis Pharma Ltda, Souzano, Brazil). Supplementary anesthesia was provided when required. The animals were maintained with isotonic saline plus 2.5% glucose (Glicolabor Indústria Farmacêutica Ltda, Ribeirão Preto, Brazil). Periapical radiographs were taken prior to the operative procedures and 7 and 70 days post-operatively using a custom-made film-holding device for standardization of the radiographic technique in dogs.[22]

After placement of a rubber dam and disinfection with 3% hydrogen peroxide and 2% chlorhexidine digluconate, coronal access was performed using air / water cooled high-speed #1015 diamond burs (KG Sorensen Indústria e Comércio, São Paulo, Brazil). The burs were replaced every 4 cavity preparations to ensure cutting efficiency and avoid overheating. The pulp chamber was irrigated with sterile saline and the coronal pulp was amputated at the level of the root canal entrances using sharp curettes. Hemostasis was obtained by copious irrigation of the pulp chamber with saline.

All experimental groups were tested in the same animal and were performed in alternate quadrants in a change-over system distributed at random. The materials were prepared according to the manufactures' instructions.

Table 1: *Material used in this study, number of teeth per group and experimental periods.*

Group	Material	Number of teeth / roots	Experimental period
I	EMD (Emdogain®)	12 / 24	7 days
II	Calcium hydroxide (Negative control)	4 / 8	7 days
III	Zinc oxide and eugenol (Positive control)	4 / 8	7 days
IV	EMD (Emdogain®)	12 / 24	70 days
V	Calcium hydroxide (Negative control)	4 / 8	70 days
VI	Zinc oxide and eugenol (Positive control)	4 / 8	70 days

***Chart 1**: Results from histopathological analysis of dental pulp and periapical area, regarding presence of dentin barrier, inflammatory response, pulpal hemorrhage, focal osteodentinogenesis, pulpal necrosis, external root resorption and periodontal ligament thickness. Values are expressed in number of teeth.*

Parameter	Score	7 days			70 days			*Comparison between periods*	
		Emdogain® (n=12)	Calcium Hydroxide (n=4)	Zinc Oxide and Eugenol (n=4)	Emdogain® (n=12)	Calcium Hydroxide (n=3)[&]	Zinc Oxide and Eugenol (n=3)[&]		
Dentin barrier thickness	0 (None)	10	4	4	-[#]	0	2	EMD	-[#]
	1 (Thin)	0	0	0	-[#]	1	1	CH	$p = 0.0357$*
	2 (Medium)	0	0	0	-[#]	1	0	ZOE	$p = 0.0384$*
	3 (Thick)	0	0	0	-[#]	1	0		
	Not evaluated[$]	2	0	0	0	0	0		
Comparison among groups		$p > 0.05$			$p = 0.0975$				
Inflammatory response	0 (None)	2	3	0	-[#]	1	0	EMD	-[#]
	1 (Mild)	6	1	1	-[#]	2	3	CH	$p = 0.1535$
	2 (Moderate)	4	0	1	-[#]	0	0	ZOE	$p = 0.0111$*
	3 (Severe)	0	0	2	-[#]	0	0		
	Not evaluated[$]	0	0	0	0	0	0		
Comparison among groups		$p = 0{,}0002$* EMD × CH = $p < 0.05$*; EMD × ZOE = $p > 0.05$; CH × ZOE = $p < 0.05$*			$p = 0.1740$				
Hemorrhage	0 (Absent)	0	4	4	-[#]	3	3	EMD	-[#]
	1 (Present)	12	0	0	-[#]	0	0	CH	$p > 0.05$
Comparison among groups		$p < 0.0001$* EMD × CH = $p < 0.05$*; EMD × ZOE = $p < 0.05$*; CH × ZOE = $p > 0.05$			$p > 0.05$			ZOE	$p > 0.05$
Focal osteodentinogenesis	0 (Absent)	4	4	4	-[#]	3	3	EMD	-[#]
	1 (Present)	6	0	0	-[#]	0	0	CH	$p > 0.05$
	Not evaluated[$]	2	0	0	0	0	0	ZOE	$p > 0.05$
Comparison among groups		$p < 0.0001$* EMD × CH = $p < 0.05$*; EMD × ZOE = $p < 0.05$*; CH × ZOE = $p > 0.05$			$p > 0.05$				
Pulpal necrosis	0 (Absent)	12	4	4	0	3	3	EMD	$p < 0.001$*
	1 (Present)	0	0	0	12	0	0	CH	$p > 0.05$
Comparison among groups		$p > 0.05$			$p < 0.0001$* EMD × CH = $p < 0.05$*; EMD × ZOE = $p < 0.05$*; CH × ZOE = $p > 0.05$			ZOE	$p > 0.05$
External root resorption	0 (Absent)	12	4	4	1	3	1	EMD	$p < 0.0001$*
	1 (Present)	0	0	0	11	0	2	CH	$p > 0.05$
Comparison among groups		$p > 0.05$			$p = 0.0004$ EMD × CH = $p < 0.05$*; EMD × ZOE = $p > 0.05$; CH × ZOE = $p < 0.05$*			ZOE	$p < 0.0025$*
Periodontal ligament thickness	0 (None)	12	4	4	0	2	0	EMD	$p < 0.001$*
	1 (Mild)	0	0	0	2	1	1	CH	$p > 0.3123$
	2 (Moderate)	0	0	0	7	0	2	ZOE	$p < 0.006$*
	3 (Severe)	0	0	0	3	0	0		
	Not evaluated[$]	0	0	0	0	0	0		
Comparison among groups		$p > 0.05$			$p = 0.0007$ EMD × CH = $p < 0.05$*; EMD × ZOE = $p > 0.05$; CH × ZOE = $p < 0.05$*				

*Note: [&] tooth lost during histological preparation; [$] tooth not evaluated due to incorrect histological sectioning; -[#] pulpal necrosis; parameter could not be evaluated; *statistically significant; EMD (enamel matrix derivative, CH (calcium hydroxide), ZOE (zinc oxide and eugenol cement).*

The following materials were used as capping agents: Groups I and IV: Enamel matrix derivative (Emdogain® - Biore AB - Malmö - Sweden), available in the form of a gel containing 30 mg / ml EMD in PGA recovered with gutta-percha; Groups II and V: 0.5 g calcium hydroxide p.a. (Calcium Hydroxide zur Analyse; Merck, Darmstadt, Germany) mixed with 0.5 mL saline recovered with a calcium hydroxide cement layer (Dycal®; Dentsply Indústria e Comércio Ltda;Brazil); Groups III and VI: zinc oxide and eugenol cement (IRM®; Dentsply Indústria e Comércio Ltda,Brazil;1 scoop of powder zinc oxide mixed with 1 drop of eugenol). In all groups the access cavity was restored with amalgam (Velvalloy; SS White Dental Articles Ltda, Rio de Janeiro, Brazil).

The dogs were euthanized by anesthetic overdose 7 days (Groups I, II, and III) and 70 days (Groups IV, V, and VI) after pulpotomy. The maxillas and mandibles were removed and the anatomic pieces containing the teeth were sectioned using water-cooled diamond disks.

Histological processing

The pieces were fixed in buffered 10% formalin for 72 hours at room temperature and demineralized in an etilenediaminetetracetic acid (EDTA)-based solution activated in a microwave oven (Sharp Carousel; São Paulo, SP, Brazil). After demineralization, the pieces were neutralized in 5% sodium sulfate (JT Baker, Xalostoc, Mexico), washed in running water for 24 hours, dehydrated in ascending ethanol grades, cleared in xylol and embedded in paraffin, according to the standard processing.

The blocks were serially sectioned and 5-µm-thick longitudinal cuts were obtained and stained with hematoxylin and eosin (HE), Mallory's Trichrome and Brown & Brenn staining technique for histological analysis under optical microscopy by one blind examiner. Slides were analyzed subjectively and semi-quantification evaluation was performed according to presence of dentin barrier, inflammatory response, pulpal hemorrhage, focal osteodentinogenesis, pulpal necrosis, external root resorption and periodontal ligament thickness. Scores were attributed to each parameter, according to our research group previously (Chart 1), and data were analyzed by means of Kruskal-Wallis and Dunn's post test or Mann-Whitney test (α=0.05), using Graph Pad Prism 5.0 Software (San Diego, EUA).[23,24,25]

RESULTS

Group I (7 days) - Emdogain®

At the interface with the material, the pulp tissue presented a mixed inflammatory infiltrate composed of polymorphonuclear neutrophils and mononuclear inflammatory cells. Inside some cells, granules of a dark material were found, indicating that macrophages migrated to the pulp tissue to phagocyte the material. No signal of dentinogenesis and dentine barrier were found, even in the lateral walls in the middle third of the root canal pulp tissue, away from the cut surface. In some specimens, foci of osteodentin, characterized by bone matrix permeated by osteoblast-like cells, were irregularly distributed, creating an area similar to a primary immature bone. In the middle third of the root pulp tissue, it was observed an intense hemorrhage with exuberant erythrocytes irregularly and diffusely distributed throughout extracellular spaces. Close to the apex, the cementum surface was regular presenting cementoblasts throughout its extension in addition to fibers and absence of resorption areas (Figure 1).

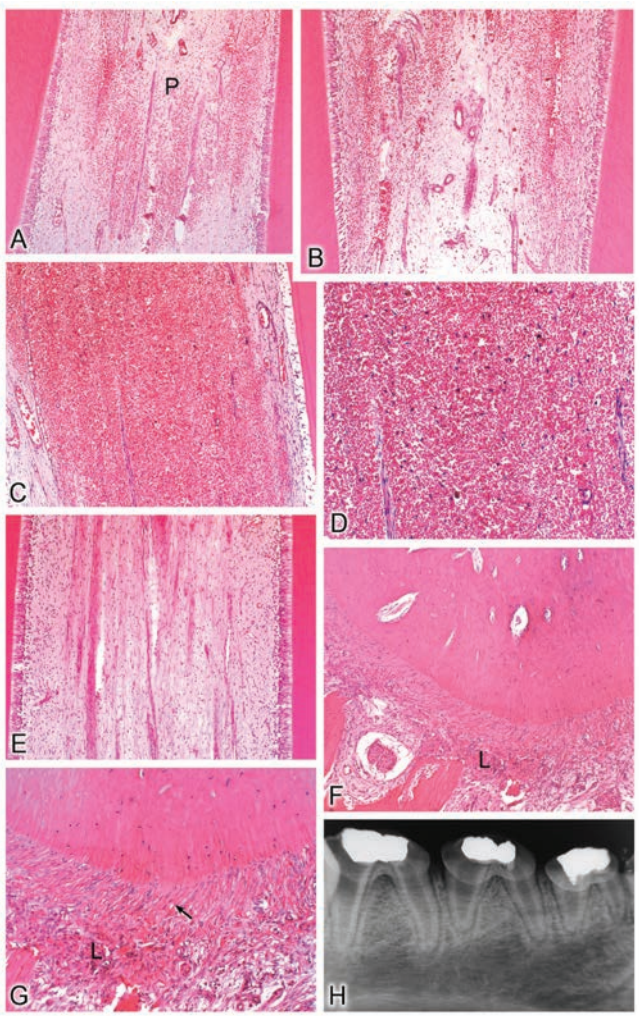

***Figure 1**: Emdogain® (7 days). (A, B) Cervical and medium third of the root canal demonstrating hemorrhagic dental pulp tissue (20×). (C, D) Higher magnification of A and B (40 and 60×). (E) Apical third demonstrating intact odontoblastic layer and periapical area (20×). (F, G) Normal periodontal ligament: absence of inflammatory cells and intense presence of fibers (20 and 40×) (L- periodontal ligament; P- pulp; Arrow (Sharpey fiber).(H) Conventional periapical radiographic showing intact lamina dura and bone tissue.*

Group II (7 days) – Calcium hydroxide

At the interface of the material with the pulp tissue it was observed a zone of coagulative necrosis. The pulp tissue presented an infiltration of neutrophils and mononuclear leukocytes in some specimens. In others, the pulp tissue presented a new odontoblastic layer, with odontoblastic cells aligned with dentin walls, although no dentin barrier formation had been observed. Pulp tissue adjacent to the material presented a slight mononuclear inflammatory infiltrate and a slightly increased number of vessels. In some areas a new advanced organization of odontoblastic layer was found. The periodontal ligament was intact. There were no areas of alveolar bone resorption and a large number of osteoblasts were observed.

Group III (7 days) – Zinc oxide and eugenol cement

Pulp tissue close to the material presented a concentrated mononuclear inflammatory cell infiltrate with few areas of edema. Root canal pulp tissue presented congested vessels and accentuated vessel proliferation and no dentin barrier formation. At the root apex, the apical delta canals were widened and filled with intact connective tissue. There were no resorption areas on the cementum surface. Periodontal ligament showed a large number of collagen fibers and intense angioblastic proliferation.

Group IV (70 days) - Emdogain®

In this period, all specimens showed necrosis of the pulp tissue and apical periodontitis. No dentin bridge was observed in any specimen of this group and odontoblastic layer was absent along dentin walls. Cementum surface was irregular due to resorption areas, with resorption lacunae containing or not clastic cells. In the periodontal ligament, inflammatory cells of mononuclear and polymorphonuclear type were more concentrated close to the apex, forming one or more foci. Generalized edema and scarce presence of cells was observed. Alveolar bone resorption areas determined an increase in apical periodontal ligament thickness (Figure 2).

Group V (70 days) – Calcium hydroxide

The pulp at the interface with the material presented normal characteristics, with an organized and mature odontoblastic layer and production of reparative dentin, well organized in its deeper layers. In the superficial layers of the dentin barrier, there was some cellular inclusions and

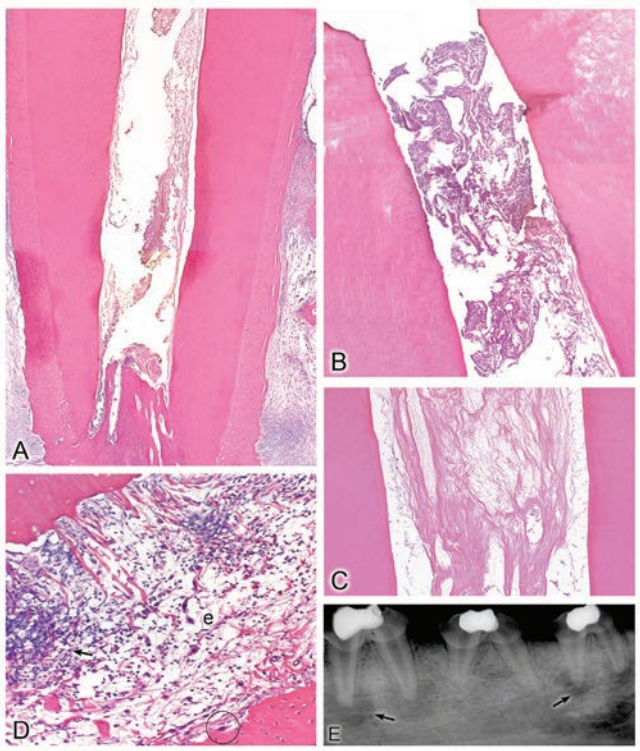

***Figure 2**: Emdogain® (70 days). (A, B) Dental pulp tissue with necrosis and no dentin bridge formation (20 and 40×). (C) Medium third of the root canal demonstrating tissue necrosis (20×). (D) Apical and periapical areas showing a widened periodontal ligament with inflammatory cells, generalized edema and fibrous dissociation. Bone and cementum present areas of resorption with clastic cells (circle) (60×). (E) Conventional periapical radiograph showing disruption of lamina dura and presence of radioluscent areas indicating apical periodontitis.*

invagination of pulp tissue. At the apical and periapical regions, cementum was regular; periodontal ligament showed a dense connective tissue, no inflammatory cells and intense presence of collagen fibers. The alveolar bone showed high presence of osteoblasts aligned on its surface.

Group VI (70 days) – Zinc oxide and eugenol cement

In this group, formation of mineralized tissue bridge was not observed in any specimen. The pulp tissue was inflamed with moderate number of mononuclear inflammatory cells in all roots. Areas of fibers dissociation were frequently observed along the extension of the root pulp tissue, concomitantly with edema and areas of necrosis. Apical cementum surface presented non-repaired resorption areas. The apical foramina were widened and contained inflamed tissue remnants. The periodontal ligament thickness was increased with presence of moderate inflammatory infiltrate and generalized edema. Alveolar bone was resorbed and non-repaired.

DISCUSSION

Our results, comparing the effects of enamel matrix derivative and calcium hydroxide on the pulp tissue in pulpotomy are similar to those reported by Olsson et al.[17] and Darwish et al. [19] and divergent to results found by Nakamura et al. [6]

At 7 days, there was no sign of dentinogenesis in teeth treated with Emdogain®, although foci of osteodentin, characterized by bone matrix permeated by osteoblast-like cells, was irregularly distributed creating an area similar to primary immature bone. Likewise, in enamel matrix derivative-treated teeth it has been reported that mineralized tissue forms as isolated masses inside the dental pulp. [2, 20] These authors reported that islands of hard tissue that formed in response to enamel matrix derivative, at 12 weeks after pulpotomy is unlikely to provide a structural barrier to protect the pulp as those bridge-like structures formed in calcium hydroxide-treated teeth. This difference may in part be due to the vehicle (PGA) used, since this material is a gel and does not leave a solid coating over the amputated dental pulp as would be done by calcium hydroxide.

However, we observed severe hemorrhage in the pulp tissue in contact with Emdogain® within 7 days following pulpotomy. Possible reason for that is the consistency of the gel, which facilitates its diffusion into the extracellular matrix, causing bleeding in the pulp tissue by diapedesis. Also, it has been speculated that PGA as vehicle may not be appropriate for pulp capping procedure due to it physical nature. [17] Total lack of pulpal healing could be seen at 70 days, when we observed the necrotic pulp tissue and apical periodontitis in all specimens. Although EMD induced early dentin bridge formation, pulpal inflammation followed by tissue necrosis were observed later on (at 3 months).[19]

On the other hand, in all specimens of the calcium hydroxide groups (II and V), there was mild inflammatory infiltrate in the pulp tissue in the 7-day experimental period and formation of dentin bridge obliterating the pulp exposure in the 70-day period, as previously demonstrated.[19,26-32] These findings are consistent with those of previous studies that used calcium hydroxide as a capping material after pulpotomy and also had results within the standard of normality. [26-32]

Overall, the unsatisfactory results obtained with zinc oxide and eugenol in our study are in agreement with the literature, [19, 30-32] as was demonstrated by the absence of dentin bridge formation in most specimens, the moderate inflammatory infiltrate in the pulp tissue, the periodontal ligament thickness moderately increased, and the resorption of cementum and bone.

Our results show that enamel matrix derivative in PGA vehicle (Emdogain®) did not show either satisfactory apical and periapical response or capacity of inducing mineralized tissue deposition when used to recover the root canal pulp remnant after pulpotomy.

Acknowledgments

The authors knowledge the Fundação de Amparo à Pesquisa do Estado de São Paulo for Financial Support (2007/08284-7) .The authors deny any conflicts of interest.

REFERENCES

1.Kaida H, Hamachi T, Anan H, Maedak K. Wound healing process of injured pulp tissues with Emdogain gel. J Endod 2008;34(1):26-30.
2.Fransson H, Petersson K, Davies JR. Dentine sialoprotein and collagen I expression after experimental pulp capping in humans using Emdogain gel. Int Endod J 2010 (In Press).
3.Ishizaki NT, Matsumoto K, Kimura Y, Wang X, Yamashita A. Histopathological study of dental pulp tissue capped with enamel matrix derivative. J Endod 2003;29(3):176-9.
4.Nakamura Y, Slaby I, Matsumoto K, Ritchie HH, Lyngstadaas SP. Immunohistochemical characterization of rapid dentin formation induced by enamel matrix derivative. Calcif Tissue Int 2004;75:243-52.
5.Nakamura Y, Hammarström L, Lundberg E, Ekdahl H, Matsumoto K, Gestrelius S, Lyngstadaas SP. Enamel matrix derivative promotes reparative processes in the dental pulp. Adv Dent Res 2001;15:105-7.
6.Nakamura Y, Hammarström L, Matsumoto K, Lyngstadaas SP. The induction of reparative dentine by enamel proteins. Int Endod J 2002;35(5):407-17.
7.Heijl L, Heden G, Svärdström G, Ostgren A. Enamel matrix derivative (Emdogain) in the treatment of intrabony periodontal defects. J Clin Periodontol 1997;24:705-14.
8.Rasperini G, Ricci G, Silvestri M. Surgical technique for treatment of infrabony defects with enamel matrix derivative (Emdogain): 3 case reports. Int J Periodontics Restorative Dent 1999;19(6):578-87.
9.Nagano T, Iwata T, Ogata Y, Tanabe T, Gomi K, Fukae M, Arai T, Oida S. Effect of heat treatment on bioactivities of enamel matrix derivatives in human periodontal ligament (HPDL) cells. J Periodontal Res 2004;39(4):249-56.
10.Hammarström L. Enamel matrix, cementum development and regeneration. J Clin Periodontol 1997;24:658-68.
11.Mellonig JT. Enamel matrix derivative for periodontal reconstructive surgery: technique and clinical and histologic case report. Int J Periodontics Restorative Dent 1999;19(1):8-19.
12.Aimetti M, Romano F, Pigella E, Piemontese M. Clinical evaluation of the effectiveness of enamel matrix proteins

and autologous bone graft in the treatment of mandibular Class II furcation defects: a series of 11 patients. Int J Periodontics Restorative Dent 2007;27(5):441-7.

13.Saito A, Hayakawa H, Ota K, Fujinami K, Nikaido M, Makiishi T. Treatment of periodontal defects with enamel matrix derivate: clinical evaluation at early healing stages. Bull Tokyo Dent Coll 2010;51(2):85-93.

14.Sculean A, Schwarz F, Becker J, Brecx M. The application of an enamel matrix protein derivative (Emdogain) in regenerative periodontal therapy: a review. Med Princ Pract 2007;16(3):167-80.

15.Sculean A, Schwarz F, Chiantella GC, Arweiler NB, Becker J. Nine-year results following treatment of intrabony periodontal defects with an enamel matrix derivative: report of 26 cases. Int J Periodontics Restorative Dent 2007;27(3):221-9.

16.Igarashi R, Sahara T, Shimizu-Ishiura M, Sasaki T. Porcine enamel matrix derivative enhances the formation of reparative dentine and dentine bridges during wound healing of amputated rat molars. J Electron Microsc (Tokyo) 2003;52(2):227-36.

17.Olsson H, Davies JR, Holst KE, Schröder U, Petersson K. Dental pulp capping: effect of Emdogain gel on experimentally exposed human pulps. Int Endod J 2005;38(3):186-94.

18.Wang HH, Sarmast ND, Shadmehr E, Angelov N, Shabahang S, Torabinejad M. Application of Enamel Matrix Derivative (Emdogain) in Endodontic Therapy: A Comprehensive Literature Review. J Endod. 2018;44(7):1066-79.

19.Darwish SS, Abd El Meguid SH, Wahba NA, Mohamed AA, Chrzanowski W, Abou Neel EA. Root maturation and dentin-pulp response to enamel matrix derivative in pulpotomized permanent teeth. J Tissue Eng. 2014; 5:2041731414521707.

20.Kiatwateeratana T, Kintarak S, Piwat S, Chankanka O, Kamaolmatyakul S, Thearmontree A. Partial pulpotomy on caries-free teeth using enamel matrix derivative or calcium hydroxide: a randomized controlled trial. Int Endod J 2009;42(7):584-92.

21.International Organization for Standardization (ISO). ISO 7405: Dentistry – Preclinical evaluation of biocompatibility of medical devices used in dentistry – Test methods for dental materials. Switzerland; 2008.

22.Cordeiro RCL, Leonardo MR, Silva LAB, Cerri PS. Desenvolvimento de um dispositivo para padronização de tomadas radiográficas em cães. RPG 1995;2:138-40.

23.Queiroz AM. Expressão de metaloproteinases da matriz e resposta tecidual frente a agentes cimentantes. Estudo no tecido conjuntivo subcutâneo de camundongos e no complexo dentino-pulpar de dentes de cães. Ribeirão Preto, 2011. 129 p. Tese de Livre-Docência: Faculdade de Odontologia de Ribeirão Preto/USP.

24.Queiroz AM, Assed S, Consolaro A, Nelson-Filho P, Leonardo MR, Silva RA, Silva LA. Subcutaneous connective tissue response to primary root canal filling materials. Braz Dent J 2011;22(3):203-11.

25.Silva LA, Azevedo LU, Consolaro A, Barnett F, Xu Y, Battaglino RA, Cañadas PS, de Oliveira KM, Silva RA. Novel endodontic sealers induce cell cytotoxicity and apoptosis in a dose-dependent behavior and favorable response in mice subcutaneous tissue. Clin Oral Investig 2017. In press.

26.Nosrat IV, Nosrat CA. Reparative hard tissue formation following calcium hydroxide application after partial pulpotomy in cariously exposed pulps of permanent teeth. Int Endod J 1998;31:221-6.

27.Silva LAB, de Paula e Silva FW, Leonardo MR, Assed S. Pulpal and periapical response of dogs' teeth after pulpotomy and use of recombinant human bone morphogenetic protein-7 as a capping agent. J Dent Child 2007;74(2):79-84.

28.Silva LAB, Leonardo MR, Nelson-Filho P, Medeiros AS, Rossi MA. Pulp response of anionic lyophilized collagen matrix with or without hydroxyapatite after pulpotomy in dog's teeth. Mat Res 2006;9(2):175-180.

29.Six N, Lasfargues JJ, Goldberg M. Differential repair responses in the coronal and radicular areas of the exposed rat molar pulp induced by recombinant human bone morphogenetic protein 7 (osteogenic protein 1). Arch Oral Biol 2002;47:177-87.

30.Fadavi S, Anderson AW. A comparison of the pulpal response to freeze-dried bone, calcium hydroxide, and zinc oxide-eugenol in primary teeth in two cynomolgus monkeys. Pediatr Dent 1996;18:52-6.

31.Holland R, Souza V, Mello W, Nery MJ, Bernabé PFE, Otoboni-Filho JA. The influence of the sealing material in the healing process of inflamed pulps capped with calcium hydroxide or zinc oxide-eugenol cement. Acta Odontol Pediatr 1981;2:5-9.

32.Watts A, Paterson RC. Pulpal response to a zinc oxide-eugenol cement. Int Endod J 1987;20:82-6.