RIO DE JANEIRO DENTAL JOURNAL

REVISTA CIENTÍFICA DO CRO-RJ

revcientifica.cro-rj.org.br

Editors-in-Chief
Lucianne Cople Maia
Andréa Fonseca-Gonçalves

Volume 4 - Nº1
January - April, 2019

ISSN 1518-5249
e-ISSN 2595-4733

IMAGEM FREEPIK

CRO RJ

The official journal of the
Conselho Regional de Odontologia do Rio de Janeiro

REVISTA CIENTÕFICA DO CRO-RJ (RIO DE JANEIRO DENTAL JOURNAL)

Conselho Regional de Odontologia do Rio de Janeiro
President: Outair Bastazini
Secretary: Renato Codeceira Lopes Gonçalves
Financial officer: Outair Bastazini Filho
Counselors: Felipe Melo de Araújo, Marcello Roter Marins dos Santos, Ricardo Hidalgo, Altair Dantas de Andrade, Juarez D´Avila Rocha Bastos, Michele Dias Nunes Tameirão, Sávio Augusto Bezerra de Moraes

Editors-in-Chief/Editoras-chefes
• Lucianne Cople Maia de Faria
Professora Titular do Departamento de Odontopediatria e Ortodontia da Universidade Federal do Rio de Janeiro - maia_lc@ufrj.br
• Andréa Fonseca-Gonçalves
Professora Adjunta do Departamento de Odontopediatria e Ortodontia da Universidade Federal do Rio de Janeiro - andrea.goncalves@odonto.ufrj.br

Associate Editors / Editores Associados
Alessandra Buhler Borges (Unesp – SJC), Brazil
Alexandre Rezende Vieira (Universidade de Pittsburgh), EUA
Anna B Fuks (Universidade Hebraica de Jerusalém), Israel
Antonio Carlos de Oliveira Ruellas (UFRJ), Brazil
Casimiro Abreu Possante de Almeida (UFRJ), Brazil)
Glória Fernanda Barbosa de Araújo Castro (UFRJ), Brazil
Júnia Maria Cheib Serra-Negra (UFMG), Brazil
Kátia Regina Hostilio Cervantes Dias (UFRJ), Brazil
Laura SalignacGuimarães Primo (UFRJ), Brazil
Luiz Alberto Penna (UNIMES), Brazil
Marco Antonio Albuquerque de Senna (UFF), Brazil
Mauro Henrique Abreu (UFMG)
Senda Charone (UnB), Brazil
Tatiana Kelly da Silva Fidalgo (UERJ), Brazil
Walter Luiz Siqueira (Universidade Western Ontario), Canadá

Ad Hoc Consultants
Adilis Kalina Alerxandria de França (UNIVERSO), Brazil
Alessandra Reis Silva Loguercio (UEPG), Brazil
Alfredo Carrillo Canela (UAA), Paraguai
Aline Abrahão (UFRJ), Brazil
Ana Maria Gondim Valença (UFPB), Brazil
Andréa Neiva da Silva (UFF), Brazil
Andréa Pereira de Morais (UNIVERSO), Brazil
Andréa Vaz Braga Pintor (UFRJ), Brazil
Bianca Marques Santiago (UFPB), Brazil
Branca Heloisa Oliveira (UERJ), Brazil
Brenda Paula F. de Almeida Gomes (FOP-UNICAMP), Brazil
Camillo Anauate Netto (GBPD), Brazil
Carlos José Soares (UFU), Brazil
Celso Silva Queiroz (UERJ), Brazil
Cinthia Pereira M. Tabchoury (FOP/UNICAMP), Brazil
Cláudia Maria Tavares da Silva (UFRJ), Brazil
Cláudia Trindade Mattos (UFF), Brazil
David Normando (UFPA), Brazil
Denise Fernandes Lopes Nascimento (UFRJ), Brazil
Eduardo Moreira da Silva (UFF), Brazil
Fabian Calixto Fraiz (UFPR), Brazil
Fernanda BarjaFidalgo Silva de Andrade (UERJ), Brazil
Frederico Barbosa de Sousa (UFPB), Brazil
Gisele Damiana da Silveira Pereira (UFRJ), Brazil
Issis Luque Martinez (PUC), Chile
Jônatas Caldeira Esteves (UFRJ), Brazil
José Valladares Neto (UFG), Brazil
Lívia Azeredo Alves Antunes (UFF/Nova Friburgo), Brazil
Luciana Pomarico Ribeiro (UFRJ), Brazi
Maíra do Prado (FO-UVA), Brazil
Maria Augusta Portella Guedes Visconti (UFRJ), Brazil
Maria Cynésia Medeiros de Barros (UFRJ), Brazil
Maria Eliza Barbosa Ramos (UERJ), Brazil
Maria Elisa Janini (UFRJ), Brazil
Mariane Cardoso (UFSC), Brazil
Mario Vianna Vettore (University of Shefield), United Kingdom
Maristela Barbosa Portela (UFF), Brazil
Matheus Melo Pithon (UESB), Brazil
Matilde da Cunha Gonçalves Nojima (UFRJ), Brazil
Martinna Bertolini (University of Connecticut), USA
Michele Machado Lenzi da Silva (UFRJ), Brazil
Miguel Muñoz (UVP), Brazil
Mônica Almeida Tostes (UFF), Brazil
Paula Vanessa P. Oltramari-Navarro (UNOPAR), Brazil
Paulo Nelson Filho (FORP),Brazil
Patrícia de Andrade Risso (UFRJ), Brazil
Rafael Rodrigues Lima (UFPA),Brazil
Rejane Faria Ribeiro-Rotta (UFG), Brazil
Roberta Barcelos (UFF), Brazil
RogérioLacerda Santos (UFJF) Brazil
Ronaldo Barcellos de Santana (UFF), Brazil
Ronir Ragio Luiz (IESC/UFRJ), Brazil
Samuel Jaime Elizondo Garcia (Universidad de León), México
Sandra Torres (UFRJ), Brazil
Taciana Marco Ferraz Caneppele (UNESP), Brazil
Tiago Braga Rabello (UFRJ), Brazil
Thiago Machado Ardenghi (UFSM), Brazil
Yuri Wanderley Cavalcanti (UFPB), Brazil
Wilton Wilney Ney Padilha (UFPB), Brazil

Disclaimer
The Publisher, CRO-RJ and Editors cannot be held responsible for errors or any consequences arising from the use of information contained in this journal; the views and opinions expressed do not necessarily reflect those of the Publisher, CRO-RJ and Editors, neither does the publication of advertisements constitute any endorsement by the Publisher,CRO-RJ and Editors of the products advertised.

MAIL/CORRESPONDÊNCIA
All mail shoud be sent to revistacientifica@cro-rj.org.br
Toda correspondência deve ser enviada à Secretaria no endereço abaixo:
revistacientifica@cro-rj.org.br

ISSN (print): 1518-5249
e-ISSN 2595-4733

CONSELHO REGIONAL DE ODONTOLOGIA DO RIO DE JANEIRO
REVISTACIENTÍFICADOCRORJ(
RIODEJANEIRODENTALJOURNAL)
Rua Araújo Porto Alegre, 70, 5º andar, Centro, Rio de Janeiro-RJ - Cep 20030-015 • Tel. (21) 3505-7600. - Site: www.cro-rj.org.br
Graphic Design: Claudio Santana
Librarian: Vinicius da Costa Pereira
Trainee Librarian: Aline Chahoud
Information Technology Intern: Moisés Limeira e Paulo Felippe
Available on: www.revcientifica.cro-rj.org.br
2018 - Conselho Regional de Odontologia do Rio de Janeiro

Revista Científica do CRO-RJ (Rio de Janeiro Dental Journal)

Volume 4, Number 1

Summary
Contents

Editorial

Why teeth are susceptible to caries? an evolutionary perspective.
Alexandre R. Vieira ---------- 1

Review

Imaginological exams of the frontal sinus in the human identification.
Fernanda Nogueira Reis, Andreia Cristina Breda de Souza, Maria Augusta Visconti ---------- 2

Autotransplantation of teeth with complete rhizogenesis: a literature review.
Bruna Ribeiro da Silva, Tatiana Kelly da Silva Fidalgo, Emmanuel João Nogueira Leal Silva ---------- 10

The use of hypnosis in dental care- a literature review.
Pâmella de Morais Seabra, Aline dos Santos Letieri**,** Adílis Kalina Alexandria, Thais Rodrigues Campos Soares ---------- 16

Original Article

Peri-implant status in partially edentulous individuals subjected to dental implant rehabilitation .
Carina Maciel Silva-Boghossian, Priscila de Paula Nascente de Godoi, Tamyris Ignácio Wakoff, Claudia Maria Pereira --- 21

Genetic polymorphism in *ESR2* and risk of tooth agenesis.
Guido Artemio Marañón-Vásquez, Paula Porto Spada, Marjorie A. Omori, João Zielak, José Tarcísio Lima Ferreira, Mônica Tirre de Souza Araújo, Mírian Aiko Nakane Matsumoto, Erika Calvano Küchler ---------- 28

Severity of periodontal disease in smokers.
Feser Gustavo, Dulong Ivette, Funosas Esteban, Radica Ernesto, Quintero Anabela, Antuña Maria Virginia, Boccio Ileana, Barros Andres, Bello Delfina, Grimoldi Carla, Basaldella Nazaret, Gonzalez Riano Emiliana, Pedrol Santiago ---------- 34

Severe malocclusion negatively impacts adolescents' quality of life.
Yasmin Pissolati Mattos Bretz, Gabriela Luíza Nunes Souza, Larissa Corradi-Dias, Júnia Maria Serra-Negra, Saul Martins Paiva, Lucas Guimarães Abreu ---------- 41

Oral health-related quality of life of 8-10 year-old children with traumatic dental injury.
Lívia Azeredo Alves Antunes, Eluza Piassi, Ana Júlia Milani, Leonardo dos Santos Antunes, Ronir Raggio Luiz, Anna Thereza Thomé Leão, Lucianne Cople Maia ---------- 48

Oral health condition and interpersonal relationship of scholars of a public institution.
Maria Cardoso de Castro Berry, Sylvia Tristão, Luciana Pomarico, Ivete Pomarico Ribeiro de Souza ---------- 55

***In vivo* evaluation of inflammation and matrix metalloproteinase expression in dental pulp induced by luting agents in dogs.**
Alexandra Mussolino de Queiroz, Thais Helena Andreoli do Amaral, Paôla Caroline da Silva Mira, Francisco Wanderley Garcia Paula-Silva, Paulo Nelson-Filho, Raquel Assed Bezerra da Silva, Léa Assed Bezerra da Silva ---------- 61

Odontometric study of premolars for sex determination.
Rodrigo da Silva Andrade, Larissa Chaves Cardoso Fernandes, Maria Izabel Cardoso Bento, Kenio Costa de Lima, Patrícia Moreira Rabello, Bianca Marques Santiago ---------- 73

Influence of three treatment protocols for dental fluorosis in the enamel surface: an *in vitro* study.
Rodrigo Barros Esteves Lins, Ana Karina Maciel de Andrade, Rosângela Marques Duarte, Sônia Saeger Meireles ---------- 79

Original Article

Surface microhardness of different restorative materials exposed to *candida albicans* biofilm isolated from the oral cavity of HIV-infected children.
Leandro Costa, Larissa Soares-Silva, Paulini Malfei de C. Costa, Adrielle Mangabeira, Maristela Portela, Gloria Fernanda Castro ---------- 87

Case Report

Maxillary expansion, constriction, and protraction through facial mask to correct anterior crossbite: case report.
Nayara Priscilla Pereira Lemos, Livia Helena Lourenço Leal Amoroso, Erika Josgrilberg Guimarães, Natália Pereira de Oliveira, Renata Pilli Jóias ---------- 92

Aesthetic solution for ceramic restoration over a molten metal core.
Isabel Ferreira Barbosa, Ericles Otávio, Livia Rodrigues Menezes, Fernanda Signorelli Callazans, Mauro Sayão Miranda ---------- 97

Idiopathic exostosis: rarity on maxillary sinus.
Vanessa de Araújo Faria, Felipe Pinheiro Vilela, Gabriel Campos Wendich, Marlivia Gonçalves de Carvalho Watanabe, Juliano Abreu Pacheco , Helena de Freitas Oliveira Paranhos, Elza Maria Carneiro Mendes Ferreira Santos, Plauto Christopher Aranha Watanabe ---------- 102

Dental implants placed buccally to the mandibular canal in molar regions with severe vertical bone loss: case reports.
Nilo Guliberto Martins Chavarry ---------- 107

Direct bonded space maintainer: an alternative in clinical practice after unilateral premature loss of posterior primary tooth.
Camila Silva de Amorim, Gabriella Fernandes Rodrigues, Rafael dos Reis Moraes, Lucianne Cople Maia, Matheus Melo Pithon ---------- 114

Complicated crown fracture treatment and its impact on quality of life related to oral health: report of two cases.
Lívia Roberta Piedade de Oliveira, Tacíria Machado Bezerra, Thaís Rodrigues Campos Soares, Patrícia de Andrade Risso, Lucianne Cople Maia ---------- 120

WHY TEETH ARE SUSCEPTIBLE TO CARIES? AN EVOLUTIONARY PERSPECTIVE

The question 'why we evolved to have dental caries?" was posed to me during the 2017 ORCA meeting with the challenge to share my answer to the broader community of cariologists. This manuscript is my response to the challenge and is centered on the premise of the question, evolution.

The reason why we humans experience dental caries can be thought as a consequence of the process of evolution. Within this process, is the concept of natural selection, which was discovered by Charles Darwin[1] and Alfred Russel Wallace[2]. The idea was championed in Charles Darwin's widely known book "On the Origin of Species."[3] By natural selection, our teeth became a mineralized structure that is susceptible to dissolution under acidic conditions. The mineralized structure is the result of a balanced act that is not perfect and is dictated by the behavior of charged particles near a semi-permeable membrane that can lead to an uneven distribution of minerals since different charged substances might be unable to pass the membrane, creating uneven electrical charges (the Gibbs-Donan effect).[4] This phenomenon potentially explains a variation of individual susceptibility to dental caries that innate, and adds to other factors such as influences of diet, quality of saliva, and oral hygiene behaviors.

One misconception regarding natural selection is that we are evolving to get more fit, and that means we are becoming better. Before talking about teeth specifically, let us think about two different organs. Bone, as an example, evolved to be a mineralized and though structure, but it is not unbreakable. It does not need to be. Under regular circumstances, the mineral density of bone in humans is sufficient for humans to survive and sustain their mobility. Bones will break if one falls from a certain height but the number of these events was not often enough to impact survival of our species and favor the ones that can survive long falls. From the bone metabolism standpoint, we seldom survived past young adult life and the consequences of ageing and osteopenia were never an issue. Another interesting organ is the brain. Human brains are unique in many ways and have evolved to accommodate complex cultural and linguistic abilities and other more advanced cognitive functions. Hence, the brain has a sophisticated ability to deduce cause, agency, and intent, therefore it can anticipate danger and formulate associations of predictive value that helped us survive.[5] The consequence of this ability to deduce cause is that humans now have a need to deduce cause. Fulfilling this need by anecdotal explanations that carry an emotional component are favored by many in contrast to information based on current evidence, which often needs to be processed and is not readily available to be used. Hence, superstitious and supernatural explanations of the natural world and the origin of the universe satisfy many people, despite some having college level education.

Back to teeth, human teeth evolved through natural selection to allow humans to obtain nutrients from solid foods, which allowed brain and other organs to become more sophisticated. Roots and raw vegetables required a powerful tool to be broken down and the human stomatognathic system can generate forces as strong as 350 lb.[6] While most other vertebrate species simply replace dentitions when they break, mammals have at most two generations of teeth, so fracture is not desirable. Human teeth, like of the other mammals, have composite structures and complex arrangements of mineralized matter that have evolved to resist fracture.[7] To make teeth harder, the easy solution was using calcium, which is the third most abundant metal in Earth's crust (fifth most common element), after iron and aluminum. Calcium reacts slowly with water but dissolves readily in dilute or concentrated acids. Individuals with softer teeth (less calcium content) probably had difficulties in gaining satisfactory levels of nutrition, had more fractures, and were less likely to survive and individuals with harder teeth were probably more successful. The ultimate consequence of this process was hard teeth rich in calcium but highly susceptible to acidic solutions. This was never an issue to humans until their diet dramatically changed with the introduction of refined sugars. Sugars provided bacteria in the biofilm with a "new" readily source of energy and that boosted the production of acids on top of tooth surfaces. The harder tooth, which evolved to be able to handle a raw diet, was not built to resist to low pH environments lasting long times and dental caries experience exploded in humans.

The increase in disease prevalence allowed for the observation of population patterns in which certain individuals appear to be more susceptible to the disease, whereas certain individuals appear to be resistant. Therefore, we believe it is worth defining the biological parameters, including genomic variation, that determine why certain individuals are more or less susceptible to dental caries. After working on this topic for more than a decade,[8,9] we realized this effort has been hampered by poor definitions of disease affection. Our latest approach has been to rethink how the phenotype can be defined and look for ways that patterns of disease progression can be used to understand the biological component modulating the host affected by dental caries.[10] We envision that one day we will use genomic information to decide how often individuals should be seen by the dentist, if they are more susceptible to demineralization, or if certain restorative treatments are more likely to fail.[11-13] Dental caries prevention may be tailored to the ones that will benefit the most and treatment will be centered to individual needs guided by biological predictors that can be defined at chairside.

REFERENCES

1. Darwin CR. On the tendency of species to form varieties; and on the perpetuation of varieties and species by natural means of selection. Journal of the Proceedings of the Linnean Society, Zoology 1858;3:46–52.
2. Wallace AR. On the tendency of species to form varieties; and on the perpetuation of varieties and species by natural means of selection. Journal of the Proceedings of the Linnean Society, Zoology 1858;3:53–63.
3. Darwin CR. On the origin of species by means of natural selection. J. Murray: London, 1859.
4.Donnan FG. Theorie der membrangleichgewichte und membranpotentiale bei vorhandensein von nicht dialysierenden elektrolyten. Ein beitrag zur physikalisch-chemischen physiologie. Zeitschrift für Elektrochemie und angewandte physikalische Chemie, 1911;17(10): 572-81.
5. Diamond JM. The world until yesterday: what can we learn from traditional societies? Penguin Books Ltd.: London, 2012.
6. Misch CE. Dental implant prosthetics. Elsevier: Amsterdam, 2015.
7. Lucas PW. Dental functional morphology: How teeth work. Cambridge University Press: Cambridge, 2014.
8. Vieira AR, Modesto A, Marazita ML. Caries: Review of human genetics research. Caries Res. 2014; 48(5):491-506. doi: 10.1159/000358333.
9. Nibali L, Di Iorio A, Tu YK, Vieira AR. Host genetics role in the pathogenesis of periodontal disease and caries. J Clin Periodontol. 2017;44(Suppl 18):S52-S78. doi: 10.1111/jcpe.12639.
10. Weber ML, Søvik JB, Mulic A, Deeley K, Tveit AB, Forella J, et. al. Redefining the phenotype of dental caries. Caries Res. 2018;52(4):263-271. doi: 10.1159/000481414
11. Vieira AR, Gibson CW, Deeley K, Xue H, Li Y. Weaker dental enamel explains dental decay. PLoS ONE. 2015; 10:e0124236. doi: 10.1371/journal.pone.0124236.
12. Vieira AR, Hilands KM, Braun TW. Saving more teeth – a case for personalized care. J Pers Med. 2015; 5(1):30-35. doi: 10.3390/jpm5010030.
13. Vieira AR, Silva MB, Souza KA, Filho AVA, Rosenblatt A, Modesto A. A pragmatic study shows failure of dental composite fillings is genetically determined: A contribution to the discussion on dental amalgams. Front Med (Lausanne). 2017;4:186. doi: 10.3389/fmed.2017.00186.

Alexandre R. Vieira, DDS, MS, PhD

Department of Oral Biology, School of Dental Medicine, University of Pittsburgh; Professor, Director of Clinical Research, Director of Student Research Department of Oral Biology, Department of Pediatric Dentistry, School of Dental Medicine, Department of Human Genetics, Graduate School of Public Health, Clinical and Translational Sciences Institute, University of Pittsburgh, USA.

335 Sutherland Dr., Pittsburgh, PA 15261 - Phone (412) 383-8972 ; FAX (412) 624-3080

E-mail: arv11@pitt.edu , http://www.dental.pitt.edu/vieira_lab/index.php

IMAGINOLOGICAL EXAMS OF THE FRONTAL SINUS IN HUMAN IDENTIFICATION

Fernanda Nogueira **Reis**[1*], Andreia Cristina Breda de **Souza**[2], Maria Augusta **Visconti**[3]

[1] Department of Oral Diagnosis, Universidade Estadual de Campinas, Piracicaba, SP,Brazil
[2] Department of Social and Preventive Dentistry, Universidade Federal do Rio de Janeiro, Rio de Janeiro- RJ, Brazil
[3] Department of Pathology and Oral Diagnosis, Universidade Federal do Rio de Janeiro, Rio de Janeiro- RJ, Brazil

Palavras-chave: Seio Frontal. Radiologia Forense. Odontologia Legal. Identificação Humana

RESUMO

Introdução: A identificação humana é o processo pelo qual se estabelece a identidade de um indivíduo por meio da comparação entre dados registrados em momentos diferentes. Tratando-se do crânio humano, as regiões mais utilizadas na individualização do mesmo são as áreas da sela túrcica, no osso esfenoide, as células mastoides e o seio frontal. **Objetivo:** O presente trabalho teve como objetivo, através de uma revista da literatura, identificar e descrever as principais técnicas desenvolvidas para a identificação humana, a partir de exames de imagens dos seios frontais, em virtude da contribuição em potencial da radiologia odontológica nesse contexto. **Fonte de dados:** Para isso, foi realizada uma busca bibliográfica, no PUBMED, a partir do uso das seguintes terminologias: *frontal sinus, radiology* e *forensic*. Foram incluídos os artigos publicados entre 2007 e 2017 e excluídos artigos de revisão de literatura, cartas e relatos de caso. **Síntese dos dados:** Em um total de vinte e três artigos selecionados analisou-se a amostra quanto à nacionalidade, homogeneidade, sexo e faixa etária dos indivíduos, além dos tipos de exames de imagem que constituíram essa amostra, seja de origem radiográfica ou tomográfica, e suas diferentes projeções e modalidades. Além disso, classificou-se a literatura quanto às diferentes técnicas e parâmetros empregados para a identificação, sejam eles quantitativos ou morfológicos. **Conclusão:** Através desta busca, conclui-se que o perfil da pesquisa científica mundial, voltada para a identificação humana através de exames de imagem dos seios frontais, utiliza amostras homogêneas, de ambos os sexos e ampla faixa etária, empregando-se majoritariamente a Radiografia Extra-oral Póstero-Anterior e parâmetros qualitativos e quantitativos para a identificação.

Keywords: Frontal Sinus Recognition. Forensic Radiology. Forensic Dentistry. Human Identification.

ABSTRACT

Introduction: Human identification is the process by which the identity of an individual is established by comparing data recorded at different times. In the case of the human skull, the most used areas for the individualization are the Turkish Chair, the sphenoid bone, the mastoid cells, and the frontal sinus. **Objective:** The aim of the present work was to identify and describe the main techniques developed for human identification through a literature review, based on imaging of the frontal sinuses, due to the potential contribution of dental radiology in this context. **Sources of data:** For this, a bibliographic search was performed in PUBMED, using the following terminologies: frontal sinus, radiology, and forensic. Articles published between 2007 and 2017 were included, literature articles, letters, and case reports were excluded. **Synthesis of data:** A total of twenty-three articles were selected, the sample was analyzed for the nationality, homogeneity, sex, and age of the individuals, as well as for the types of imaging tests that constituted this sample, whether of radiographic or tomographic origin and their different projections and modalities. In addition, the literature was classified as to the different techniques and parameters used for identification, whether quantitative or morphological. **Conclusion:** After this research, it was possible to conclude that the profile of the world scientific research aimed at human identification through imaging of the frontal sinuses, consists of homogenous samples, of both sexes, and a wide age group, using mostly posteroanterior extraoral radiographic examination and qualitative and quantitative parameters for identification.

Submitted: Febuary 2, 2019
Modification: March 26, 2019
Accepted: March 27, 2019

***Correspondence to:**
Fernanda Nogueira Reis
Address: Avenida Primavera, 375- Vila Areião, Piracicaba, SP- Brazil.
Telephone Number: 55 (21) 97564-8955
E-mail: fernanda.nreis@outlook.com.br

INTRODUCTION

Human identification is the process by which individuals are by comparing data recorded at different times.[1] However, for the method of identification adopted to be reliable, it needs to follow biological and technical requirements. Thus, essential biological requirements must be considered, such as uniqueness, immutability, and permanence, while the technical requirements are based on practicality and classifiability.[1]

In the case of the human skull, the regions most studied for identification, due to their particularities, are the sella turcica in the sphenoid bone, the mastoid cells, and the frontal sinus:[2] The frontal sinus presents with great variation among human beings; it is considered to be one of the most individualistic anatomical structures of the skeleton, in such a way that even monozygotic twin siblings have frontal sinuses which differ in their characteristics.[3] These are pneumatized cavities, which form at around one year of life but become visible in radiographic images between seven and nine years old, reaching its final configuration at 20 years of age.[2] It is important to note that the frontal sinuses are present in 96% of the adult population,[4] and studies in some populations have demonstrated the bilateral absence of the frontal sinuses at a very low frequency, for example, 0.72% in the Turkish sample.[5]

The first reported case of human identification by frontal sinus analysis was dated as 1925, when Culbert and Law used thirteen points that were considered as "sinus impressions", in addition to variations in other accessory sinuses in the Turkish chair and mastoid process.[2] Since then, many researchers have created different frontal sinus classification systems based on techniques to measure the size, volume, and asymmetry of sinuses.[2]

The primary methods of human identification, determined by The International Criminal Police Organization (INTERPOL) protocol, consist of analyzes of fingerprints, odontological characteristics, and DNA (Deoxyribonucleic Acid).[6] Within Forensic Dentistry, the expert has several methods that can aid in the identification of individuals, such as histopathological, radiographic, and immunological methods.[7] Thus, the selection of the most appropriate identification process should be made individually, considering its particularity.[7]

In this field of expertise, dental radiology is of great use in cases of human cadavers in advanced stages of putrefaction, carbonized, or skeletonized, for example, as is often the case in cases of mass disasters.[8] Other conventional methods of identification, such as papillary analysis, are not possible in these conditions because it can only be performed where soft tissues are preserved.[9] In addition, when antemortem dental records are not available or when the teeth are no longer present at post-mortem, an alternative is to use of extraoral imaging tests.[10]

Therefore, the use of computed tomography (CT) is recommended for the evaluation of the paranasal sinuses, since from the three-dimensional and volumetric analyses of the sinuses, the measurements are more accurate compared to conventional radiographs.[8] In addition, the visualization between small differences in tissue densities is more precise, having values of gray intensity assigned to each structure, and there is no overlap of the anatomical structures.[10]

The use of imaging tests in human identification, comparing post-mortem and antemortem data, is already routine in the medicolegal institutes.[11] In view of this, dental documentation, especially intraoral and extraoral radiographs of the craniofacial complex, can support the processes of human identification, in the case of cadavers without an identity confirmed by fingerprints. Therefore, the aim of the present study was to report, through a review of the literature, the main techniques developed for human identification, based on imaging of the frontal sinuses.

MATERIALS AND METHODS

Study design

An integrative literature review was carried out in the PUBMED database, searching for the terms "frontal sinus" AND "radiology" AND "forensic," totaling 70 articles. For inclusion in the review, the full text of the journal needed to be available in English (n = 67), published between 2007 and 2018 (n = 45), and present in its methodology, a correlation between radiographic methods and human identification (n = 38). On the other hand, articles on literature reviews (n = 37), letters (n = 34), and case reports (n = 30) were excluded, as well as articles focusing only on sex determination (n = 23), leaving a sample of 23 articles.

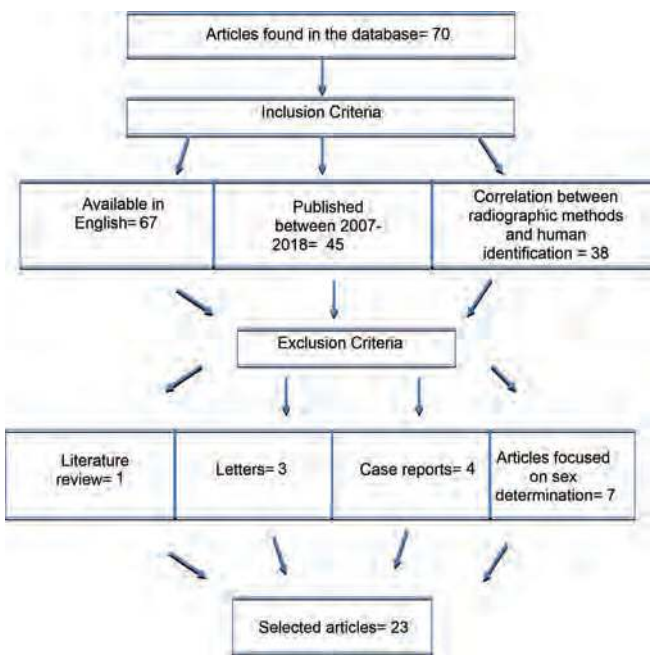

Figure 1: *Flowchart of integrative literature review.*

***Table 1**: Sample characteristics of the articles included in the sample according to the variables studied.*

Authors (Year)	Nationality (sample)	Homogeneity in relation to nationality (sample)	Average age in years (sample)	Sex (sample)	Radiographic exam used	Identification Technique	Parameters
Tatlisumak et al[12] (2007)	Turkish	Homogeneous	44.5	Mixed sample with female prevalence	MSCT	FSS System	Quantitative
Pfaeffli et al[13] (2007)	Swiss	Homogeneous	Uninformed	Uninformed	AP and Lateral Radiographies and MSCT	Superposition	Non-quantitative
Cameriere et al.[14] (2008)	North Irish	Homogeneous	44.5	Mixed sample with male prevalence	PA Radiography	Asymmetry, SS, CUB, PS and SC	Mixed
Tang et al.[15] (2008)	Chinese	Homogeneous	Uninformed	Uninformed	PA Radiography	Asymmetry, CS, height, width, SS, CUB, PS, SC and orbital width ratio	Mixed
Cox et al.[16] (2009)	Peruvian and Canadian	Heterogeneous	Uninformed	Mixed sample with male prevalence	PA Radiography (Caldwell)	A new method for objective morphological comparison	Non-quantitative
Besana et al.[17] (2010)	Canadian	Homogeneous	34.5	Uninformed	PA Radiography	Determine the independence of sinus traits	Quantitative
Uthman et al.[18] (2010)	Iraqi	Homogeneous	Uninformed	Balanced mixed sample	CT (uninformed)	FSS System	Mixed
David et al.[19] (2010)	Indian	Homogeneous	37.5	Balanced mixed sample	PA Radiography	Width, asymmetry	Quantitative
Patil et al.[20] (2012)	Indian	Homogeneous	52	Balanced mixed sample	PA Radiography (Waters)	Shape, NS, width, the distance between the maximum lateral limit and the highest point and between the upper limit, orbital cavities and the highest points	Mixed

Table 1: *Sample characteristics of the articles included in the sample according to the variables studied.*

Authors (Year)	Nationality (sample)	Homogeneity in relation to nationality (sample)	Average age in years (sample)	Sex (sample)	Radiographic exam used	Identification Technique	Parameters
Kim et al.[21] *(2013)*	Korean	Homogeneous	25	Mixed sample with male prevalence	CT (uninformed)	Height, width, volume, the distance between the uppermost points, AP depth, AMB, shape, and UEC	Mixed
Nikam et. Al[22] *(2015)*	Indian	Homogeneous	Above 20	Mixed sample with male prevalence	PA Radiography	Height and maximum width in relation to the different quadrants drawn from a baseline at the margin of the orbits and a tangent line	Quantitative
Hashim et al.[23] *(2015)*	Malaysian	Homogeneous	Uninformed	Uninformed	Extra oral Radiography (uninformed)	Superposition	Non-quantitative
Beaini et al.[24] *(2015)*	Brazilian	Homogeneous	27.5	Balanced mixed sample	CBCT	Superposition	Non-quantitative
Cossellu et al.[10] *(2015)*	Italian	Homogeneous	46.5	Mixed sample with female prevalence	CBCT	Reconstructio, asymmetry, SS, height, width, volume and surface	Mixed
Akhlaghi et al.[25] *(2016)*	Iranian	Homogeneous	Above 20	Balanced mixed sample	Paranasal CT	Height, width, AP diameter, NS	Quantitative
Soman et al.[26] *(2016)*	Indian	Homogeneous	Above 14	Balanced mixed sample	PA Radiography	Asymmetry, SS, CUB, PS and SC	Mixed
Rabelo et al.[4] *(2016)*	Brazilian	Homogeneous	46.5	Mixed sample with female prevalence	Frontal and Lateral Radiographies	FSS System adapted	Mixed
Soares et al.[27] *(2016)*	Brazilian	Homogeneous	Not applicable	Not applicable	PA and Lateral Radiographies and CBCT	FSS System adapted	Mixed

Table 1: *Sample characteristics of the articles included in the sample according to the variables studied.*

Authors (Year)	Nationality (sample)	Homogeneity in relation to nationality (sample)	Average age in years (sample)	Sex (sample)	Radiographic exam used	Identification Technique	Parameters
Suman et al.[28] *(2016)*	Indian	Homogeneous	25	Balanced mixed sample	PA Radiography	Asymmetry, area, SS, CUB, PS and SC.	Mixed
Tatlisumak et al.[29] *(2017)*	Turkish	Homogeneous	Above 20	Balanced mixed sample	MSCT	Height, width, AP length and volume	Quantitative
Buvuk et al.[3] *(2017)*	Turkish	Homogeneous	Uninformed	Balanced mixed sample	PA Radiography	Height and width	Quantitative
Verma et al. [30] *(2017)*	Indian	Homogeneous	24	Balanced mixed sample	PA Radiography	Asymmetry	Non-quantitative
Souza Jr et al. [31] *(2018)*	Brazilian	Homogeneous	Above 20	Uninformed	CT (uninformed)	Automatic segmentation	Non-quantitative

Synthesis of data

In the 23 articles selected, the different nationalities of the samples obtained were distributed according to the variables described in Table 1. Only four populations were studied in more than one article, with India being the most prominent country. Only one article applied the methodology to individuals of different nationalities, Peruvian and Canadian, worrying about the use of a heterogeneous sample, in order to observe any possible significant differences in the obtained patterns. As for the sample, a broad age group was used in the studies, 14 years old was the youngest age studied. In turn, a sample aged above 20 years old was used in most studies. Among the articles that reported the age group, the average age was found to be 37 years old, 21.7% of the articles reported only the initial age, and 30.4% did not provide information about age.

On the other hand, in relation to the possible differences that could be found between the sexes, all the articles opted to use a mixed sample. In this scenario, almost half of studies, 43.5%, used the same number of imaging exams from men and women, 30.4% used a mixed sample, but there was a prevalence for one sex. The remaining 26.1% did not contain any information about sex, mostly because they came from an archaeological sample of dry skulls.

It is important to mention that all these studies used images of an intact frontal sinus, excluding those of individuals with pathological processes, anomalies, traumas, or a history of orthodontic and surgical treatments that could compromise their anatomy or physiology.

Regarding the imaging tests used, we highlight postoperative extraoral radiography (52.2%), followed by cone-beam computed tomography (13.0%), medical computed tomography (13.0%), and on a smaller scale, other conventional extraoral radiographs.

The methodologies used in each article were divided into two types: metric methods that use quantitative parameters such as height, width, and volume of the frontal sinuses for the evaluation of these structures, and nonmetric or morphological methods that use the frontal sinus in the process of identification, as in the case of the superposition of radiographic images. The data collected in relation to the techniques used for identification in the 23 articles studied showed that the highest percentage was for mixed analysis evaluations that used both metric and morphological parameters (43.5%), followed by those who used only quantitative (30.4%), and finally, those who used non-quantitative variables (26.1%).

DISCUSSION

Regarding the study samples, it could be stated that approaching heterogeneous populations in the same study to evaluate the ethnic factor inherent in each technique was extremely deficient. It was perceived that this was used in only one of the articles analyzed,[16] which was shown by one of the deficiencies found in the profile of the scientific research in this area, which could be explained by the difficulty of exchanging and accessing imaging exams from other countries.

Regarding gender, the results showed that the importance of the use of exams from individuals of both sexes is consolidated, since all the studies that considered this characteristic used a mixed sample, and the majority had an equal division between the sexes.

In addition, the age of the sample was also a determining factor for effective identification, since the final configuration of the frontal sinuses is only reached after the age of 20.[20] However, Tatlisumak et al.[29] explored the pattern of frontal sinus configuration according to age, based on the belief that the frontal sinuses continue to expand to a later age, due to other factors and the influence of mechanical chewing factors.[32] In this case, it was agreed that there is a decrease in the frontal sinus area from the age of 70 years old,[29] but from the analysis performed, it was observed that the authors concluded that new studies need to be performed with less limited samples and looking at different backgrounds.

Regarding the type of image exam selected, it was verified that more than half of the studies used PA (posteroanterior) radiography.[14-17,19,20,22,26-30] Thus, it was noted that conventional extraoral radiography is still the most viable and most used in the research, also emphasizing the increasing use, but still at a smaller scale, of three-dimensional imaging resources, such as concomitant computed tomography.[10,13,18]

In relation to the methodologies and identification parameters of the frontal sinus, the largest number of analyzes used both quantitative and morphological parameters. Among all the parameters used to measure and classify the frontal sinuses, height and width were widely used to obtain asymmetry indices.[10,14,15,19,21,26,28,30] In addition to asymmetry, depth values,[21] volume[10,21,29], and the anteroposterior diameter of the frontal sinuses[25,29] were repeated in several articles from the present analysis.

In 1987, Yoshino developed one of the most widespread classification methods in the world, taking into consideration the area of the breasts, bilateral asymmetry, the superiority of the area on one side, the contour of the upper border, the

presence of partial septa, supraorbital cells, and orbital areas. This methodology is still used in the last years[14,15,21,26,18] in different populations and with some adaptations. In 2008, Cameriere et al.[14] replaced some of the variables, such as asymmetry, with indices corresponding to the frontal sinus areas and the orbits corresponding to each side, performing tests of image proportions.

As for tomographic reconstructions, in 2007 Tatlisumak[12] developed a methodology that was subsequently used in different studies and populations for human identification with a high degree of agreement and acceptance, using qualitative and quantitative parameters. This methodology is known as the FSS System,[4,12,18,27] this method uses a range of twelve standardized parameters: presence of the frontal and left frontal sinuses, central frontal sinus, presence and type of interosseous septum, type of deviation within the transverse septum, number of incomplete and complete intra-septae within the right and left frontal sinus, the number of scaling (curved cuts) of the right and left frontal sinus. Such standardization facilitates the collection and transfer of data so that this methodology has been tested and improved in different populations.

Cone beam computed tomography allowed Cossellu et al. to correlate quantitative variables through statistical analysis, reaching a high efficacy in the analyzes of the same observer and of different observers.[10] However, the challenge is the applicability of the Tatlisumak methodology in conventional radiographs, considering the reality of Brazilian expertise.

In 2016, Soares et al.[27] analyzed the results obtained from radiographic and tomographic images and found a greater concordance in the tomographic data in relation to the quantitative parameters. However, in both the imaging modalities, reliability, and reproducibility were satisfactory. In this study, it was suggested that the distance between the highest points of the right and left sinuses be excluded among the identification parameters. Rabello[4] tested this classification system on frontal and lateral extraoral radiographs, obtaining good results regarding the applicability if the radiographs were acquired after rigorous calibration and specialized training. There was also a greater efficacy and reproducibility in the analyzes made by the same examiner when compared with data between the different examiners, which is not a problem since the identification is made by a single expert.

Moreover, six articles opted for identification through non-quantitative parameters,[13,16,23,24,30,31] that were purely morphological. The overlapping of radiographic images through tracings,[13,23,24] without the use of metric variables, has great value for the everyday expert. This technique has been improved using digital radiographs and software that allow the outline of the trace to be no longer made in an empirical way, which could lead to false identification. In relation to tomography, the superposition technique is also gaining momentum, since the superposition of three-dimensional reconstructions can be done when there is a tomographic image of the individual at the antemortem moment, as was done in Beaini's research.[24]

CONCLUSION

The quality of a specific approach should not be fully evaluated by the accuracy of the technique since its reproducibility must also be proven. There is a need for human frontal sinus identification methods to be extended to other populations in order to evaluate possible variations, thus contributing to the increased reliability of the technique.

Additional and valuable information, such as nationality, sex, and age patterns, can be added to the current multifactorial methods, aiming at the improvement and development of less invasive techniques; increasing its precision through the use of more modern three-dimensional images; increasing the fidelity of the method.

Thus, the encouragement of scientific research in this field is of vital importance in Brazil, and dental radiology is a potential field of research, aiming at increasing the accuracy of the techniques used for human identification in expert exams involving frontal sinuses.

REFERENCES

1.Daruge, Eduardo; Daruge Júnior, Eduardo; Francesquini Júnior, Luiz. Tratado de Odontologia Legal e Deontologia. Rio de Janeiro: Guanabara Koogan, 2017.

2.Reichs KJ. Forensic Science lnternatiod Quantified comparison of frontal sinus patterns by means of computed tomography. 1993;61:141–68.

3.Buyuk SK, Karaman A, Yasa Y. Association between frontal sinus morphology and craniofacial parameters: A forensic view. J Forensic Leg Med. 2017;49:20–3.

4.Rabelo KA, dos Anjos Pontual ML, de Queiroz Jordão N, de Paiva KM, de Moraes Ramos-Perez FM, dos Santos MS, et al. Human identification by FSS system adapted to cephalometric radiographs. Forensic Sci Int. 2016;262:227–32.

5.Çakur B, Sumbullu MA, Durna NB. Aplasia and agenesis of the frontal sinus in Turkish individuals: A retrospective study using dental volumetric tomography. Int J Med Sci. 2011;8(3):278–82.

6.International Criminal Police Organization. Interpol DVI Guide. Lyon: OIPC – Interpol; 2013. Disponível em: < https://www.interpol.int/INTERPOL-expertise/Forensics/DVI-Pages/DVI-guide>.

7.Reverte Coma, JM. El diente en Antropología Forense. In: REVERTE COMA, JM. Antropología Forense. Madrid: Secretaria General Tecnica, Centro de Publicaiones, 1991. p. 325-390

8.Almeida, MSC. Estudo da Identificação Humana por meio da imaginologia dos seios frontais. Análise dos procedimentos de estimativa da idade cronológica do indivíduo pela avaliação dentária no Instituto Médico Legal de Fortaleza. 2012. [dissertation]. Universidade Federal da Paraíba. Faculdade de Odontologia, João Pessoa, 2012.

9.Gonçalves AS, Marcelino JC, Prado MM, Silva RF. Identificação humana utilizando radiografia pa de seios maxilares: relato de caso. Rev Bras Odontol Leg RBOL. 2014; 1(1);

10.Cossellu G, De Luca S, Biagi R, Farronato G, Cingolani M, Ferrante L, et al. Reliability of frontal sinus by cone beam-computed tomography (CBCT) for individual identification. Radiol Medica. 2015;120(12):1130–6.

11.Soriano EP, Carvalho, MVD, Santos, FB, Campello, RIC, Mendoza, CC. A radiologia no processo de identificação odontolegal. Rev. ABO Nac. 2008;16: 180–184.

12.Tatlisumak E, Yilmaz Ovali G, Aslan A, Asirdizer M, Zeyfeoglu Y, Tarhan S. Identification of unknown bodies by using CT images of frontal sinus. Forensic Sci Int. 2007;166(1):42–8.

13.Pfaeffli M, Thali MJ, Bolliger SA, Braun M, Vock P, Dirnhofer R. Post-mortem radiological CT identification based on classical ante-mortem X-ray examinations. Forensic Sci Int. 2006;171(2–3):111–7.

14.Cameriere R, Ferrante L, Molleson T, Brown B. Frontal sinus accuracy in identification as measured by false positives in kin groups. J Forensic Sci. 2008;53(6):1280–2.

15.Tang JP, Hu DY, Jiang FH, Yu XJ. Assessing forensic applications of the frontal sinus in a Chinese Han population. Forensic Sci Int. 2009;183(1–3):104.e1-104.e3.

16.Cox M, Malcolm M, Fairgrieve SI. A new digital method for the objective comparison of frontal sinuses for identification. J Forensic Sci. 2009;54(4):761–72.

17.Besana JL, Rogers TL. Personal identification using the frontal sinus. J Forensic Sci. 2010;55(3):584–9.

18.Uthman AT, AL-Rawi NH, Al-Naaimi AS, Tawfeeq AS, Suhail EH. Evaluation of frontal sinus and skull measurements using spiral CT scanning: An aid in unknown person identification. Forensic Sci Int. 2010;197(1–3):124.e1-124.e7.

19.David M, Saxena R. Use of frontal sinus and nasal septum patterns as an aid in personal identification: A digital radiographic pilot study. J Forensic Dent Sci. 2011;2(2):77.

20.Patil N, Karjodkar FR, Sontakke S, Sansare K, Salvi R. Uniqueness of radiographic patterns of the frontal sinus for personal identification. Imaging Sci Dent. 2012;42(4):213–7.

21.Lee U-Y, Kim D-I, Kwak D-S, Han S-H, Park S-O. Identification Using Frontal Sinus by Three-Dimensional Reconstruction from Computed Tomography*. J Forensic Sci. 2012;58(1):5–12.

22.Nikam SS, Gadgil RM, Bhoosreddy AR, Shah KR, Shirsekar VU. Personal Identification in Forensic Science Using Uniqueness of Radiographic Image of Frontal Sinus. J Forensic Odontostomatol. 2015 Jul 1;33(1):1-7.PMID: 26851444

23.Hashim N, Hemalatha N, Thangaraj K, Kareem A, Ahmed A, Hassan NFN, et al. Practical relevance of prescribing superimposition for determining a frontal sinus pattern match. Forensic Sci Int [Internet]. 2015;253:137.e1-137.e7. Available from: http://dx.doi.org/10.1016/j.forsciint.2015.05.020

24.Beaini TL, Duailibi-Neto EF, Chilvarquer I, Melani RFH. Human identification through frontal sinus 3D superimposition: Pilot study with Cone Beam Computer Tomography. J Forensic Leg Med [Internet]. 2015;36:63–9. Available from: http://dx.doi.org/10.1016/j.jflm.2015.09.003

25.Akhlaghi M, Bakhtavar K, Moarefdoost J, Kamali A, Rafeifar S. Frontal sinus parameters in computed tomography and sex determination. Leg Med [Internet]. 2016;19:22–7. Available from: http://dx.doi.org/10.1016/j.legalmed.2016.01.008

26.Soman B, Sujatha G, Lingappa A. Morphometric evaluation of the frontal sinus in relation to age and gender in subjects residing in Davangere, Karnataka. J Forensic Dent Sci. 2016;8(1):57.

27. Soares CBRB, Almeida MSC, Lopes P de ML, Beltrão RV, Pontual A dos A, Ramos-Perez FM de M, et al. Human identification study by means of frontal sinus imaginological aspects. Forensic Sci Int. 2016;262:183–9.

28.Suman JL, Jaisanghar N, Elangovan S, Mahaboob N, Senthilkumar B, Yoithapprabhunath TR, Srichinthu KK. Configuration of frontal sinuses: A forensic perspective. J Pharm Bioall Sci 2016;8, Suppl S1:90-5

29.Tatlisumak E, Etli Y, Keskin S, Bora A, Hekimoglu Y, Gumus O, et al. The effects of gender and age on forensic personal identification from frontal sinus in a Turkish population. Saudi Med J. 2017;38(1):41–7.

30.Verma K, Nahar P, Pal Singh M, Mathur H, Bhuvaneshwari S. Use of frontal sinus and nasal septum pattern as an aid in personal identification and determination of gender: A radiographic study. J Clin Diagnostic Res. 2017;11(1):ZC71-ZC74.

31.Souza LA d., Marana AN, Weber SAT. Automatic frontal sinus recognition in computed tomography images for person identification. Forensic Sci Int [Internet]. 2018;286:252–64. Available from: https://doi.org/10.1016/j.forsciint.2018.03.029

32.McLaughlin RB, Rehl RM, Lanza DC. Clinically relevant frontal sinus anatomy and physiology. Otolaryngol Clin North Am. 2001;34(1):1–22.

AUTOTRANSPLANTATION OF TEETH WITH COMPLETE RHIZOGENESIS: A LITERATURE REVIEW

Bruna Ribeiro da **Silva**[1], Tatiana Kelly da Silva **Fidalgo**[2], Emmanuel João Nogueira Leal **Silva**[3*]

[1]Department of Endodontics, Grande Rio University (UNIGRANRIO), Rio de Janeiro, RJ, Brazil
[2]Department of Paediatric Dentistry, Rio de Janeiro State University (UERJ), Rio de Janeiro, RJ, Brazil
[3]Department of Endodontics, Rio de Janeiro State University (UERJ), Rio de Janeiro, RJ, Brazil

Palavras-Chave: Endodontia. Autotransplante. Rizogênese Completa.

RESUMO

Objetivo: O objetivo da presente revisão da literatura foi verificar as taxas de sucesso, assim como seus fatores predisponentes, do autotransplante dentário em dentes com rizogênese completa. **Métodos:** Uma busca eletrônica foi executada no PubMed usando *MeSH terms* e termos livres específicos. Inicialmente, um total de 115 títulos e resumos foram identificados. Um estudo adicional foi identificado como relevante após uma busca das listas de referência. Após a aplicação dos critérios de elegibilidade, apenas 8 artigos foram selecionados. **Resultados:** De forma geral, os estudos incluídos demonstram elevadas taxas de sucesso, baseado nos parâmetros estabelecidos, como manutenção do ligamento periodontal, cicatrização periapical e saúde periodontal. Além disso, os estudos selecionados na presente revisão apontaram que fatores como os protocolos de extração e reimplante, o tempo de proservação utilizado no estudo e o tempo no qual foi realizado o tratamento endodôntico do elemento transplantado, podem afetar a taxa de sucesso do autotransplante dentário. **Conclusão:** De acordo com a presente revisão de literatura pode-se concluir que embora ainda existam poucos estudos de autotransplante realizados em pacientes com rizogênese completa, a técnica tem se mostrado uma opção viável e com moderada taxa de sucesso para a substituição de elementos dentários perdidos.

Keywords: Endodontics. Autotransplantation. Complete Rhizogenesis

ABSTRACT

Objective: The objective of the present literature review tis o verify the success rates, as well as the predisposing factors, associated to success rates of dental autotransplant treatments in teeth with complete rhizogenesis. **Methods:** An electronic search was performed on PubMed database using MeSH terms and free terms. Initially, a total of 115 titles and abstracts. An additional study was identified as relevant after a search of reference lists. After eligibility criteria appliance, only 8 articles were selected. **Results:** In general, the included studies show high success rates, based on established parameters such as periodontal ligament maintenance, periapical healing and periodontal health. In addition, the selected studies pointed out that factors such as extraction and reimplantation protocols, the time of follow-up used in the study and the time in which the endodontic treatment of the transplanted element was performed, can affect the success rate of dental transplant therapy. **Conclusion:** According to the present literature review, it can be concluded that although there are still few studies of autotransplantation performed in patients with complete rhizogenesis, the technique has proven itself as a viable option with moderate success rate for replacement of lost dental elements.

Submitted: December 17, 2018
Modification: Febuary 5, 2019
Accepted: Febuary 7, 2019

***Correspondence to**:
Dr Emmanuel João Nogueira Leal Silva
Address: Dental School – Grande Rio University -UNIGRANRIO Endodontics Department. Rua Herotides de Oliveira, 61/902 ,Icaraí – Niterói – RJ – Brazil.
Telephone number: 55 (21) 83575757
E-mail: nogueiraemmanuel@hotmail.com

INTRODUCTION

Dental autotransplantation consists of the surgical transposition of a tooth from its original site to another, replacing a lost tooth which the dental treatment is not possible in the same patient.[1] Dental autotransplantation is a treatment option to reestablish the masticatory and aesthetic function of edentulous spaces.[2, 3] This technique presents advantages when compared to other therapeutic options (eg dental implants, fixed or removable prostheses), such as greater resistance to occlusal load, recovery of proprioceptive function, and maintenance of the periodontal ligament and bone.[2, 4, 5] In addition, the total cost of an autotransplant is lower than the other therapies previously mentioned, especially the dental implants.

The longevity and prognosis of dental autotransplantation with incomplete rhizogenesis teeth are well established in the dental literature, being comparable to those with dental implants.[2] However, unfavorable and / or contradictory survival rates of autotransplanted teeth with complete rhizogenesis have been reported.[4, 6] These success rates can be varied as they are influenced by different factors, such as case selection, patient age, type of transplanted tooth, storage, the receiving site, the surgical technique and the dentist's ability.

Due to the above mentioned reasons, it is clear that divergent failure rates reported in the dental literature can be directly influenced by differences in pre, trans and postoperative protocols. Therefore, it is important the knowledge about dental autotransplantation technique in teeth with complete rhizogenesis, as well as to understand which factors may be related to the success rates of this procedure. The aim of the present study was to review publications available in the scientific literature on the success of performing autotransplantation on teeth with complete rhizogenesis.

MATERIALS AND METHODS

Research Strategy

A systematic search was carried out in the PubMed database of the US National Library of Medicine with the combination of the following descriptors: "Autotransplantation", "Transplantation", "Teeth", "Root". The Boolean operators "AND" and "OR" were applied to combine the terms and create the search strategy. Reference lists of identified articles or literature reviews have also been searched to identify other potentially relevant articles.

Selection of studies

The titles and abstracts of all articles identified from the electronic search were independently evaluated by 2 collaborators (B.R.S. and E.J.N.L.S). Any disagreement between the authors was resolved through discussion.

Full-text copies of all remaining articles were obtained and further analysis was performed independently by each evaluator to determine whether or not the studies were eligible for this study based on specific inclusion and exclusion criteria.

The published studies were selected for inclusion based on the following criteria:

1. Studies in humans;
2. Use of dental autotransplant procedures;
3. Report of long-term success rates based on clinical and radiographic evaluation;
4. Studies in English.

The exclusion criteria were as follows:

1. Animal, in vitro or ex vivo studies and review articles;
2. Personal opinion;
3. Inadequate data from clinical and radiographic examination.

The researchers examined the remaining list of articles to reach a consensus that the inclusion and exclusion criteria were followed and that the major studies were included.

RESULTS

Initially, a total of 115 titles and abstracts were retrieved after an electronic search in both electronic databases using the specific combination of terms and keywords. It were identified 25 additional studies after a search of reference lists. After the first selection phase, 90 articles were excluded based on the pre-defined exclusion criteria.

The complete text of the remaining articles (n = 8) was obtained and submitted to independent judged by each of the evaluators.[7-11] The eight studies met the inclusion criteria and were included in the present literature review.

Table 1 presents the main results obtained in the articles selected for the present literature review.

The major of articles performed the surgical procedures according to Andreasen et al (1990).[4] Breflly, the donor tooth was submitted to extraction that was conducted carefully in order to do not damage the root surface. The socket was adjusted to receive the donor tooth using burs. Then, the transplanted tooth was inserted in the adapted socket in a infraocclusion position and the flaps were sutured and finally the the tooth was splinted.

Table 1: *Main results obtained from included papers.*

Study	Success rate	Reasons for failures	Follow-up period(years)	Mean age(years)	Technique	Endodontic treatment
SUGAI *et al.* 2010	88%	Radicular resorption; Periodontite; Root fracture.	3	39	Andreasen et al., (1990)[4]	After 3 weeks
AOYAMA *et al.* 2012	84.4%	Severe mobility; Severe inflamation; Periodontite; Repsortion.	5	40	Andreasen et al., (1990)[4]	After 3 weeks
YOSHINO *et al.* 2013a	68.3%	Radicular resorption; Clinical attachment loss.	5-15	43.7	Andreasen et al., (1990)[4]	After 3 weeks
YOSHINO et al. 2013b	89.9%	Clinical attachment loss;	3.4	NP	Andreasen et al., (1990)[4]	After 3 weeks
YOSHINO *et al.* 2013c	72.9%	Radicular resorption; Clinical attachment loss; Healing failure.	10	NP	Andreasen et al., (1990)[4]	After 3 weeks
YOSHINO *et al.* 2013d	75.4%	Radicular resorption; Clinical attachment loss; Radicular fracture, Dental caries.	5-15	55	Andreasen et al., (1990)[4]	After 3 weeks
YU *et al.* 2017	90.80%	Radicular resorption.	9.9	33.1	Complete exposure of the surgical site, an ostectomy was performed for minimally traumatic removal of the donor tooth. the recipient site was adjusted using dental implant drills and guided bone regeneration (GBR) was used when necessary. The suture and splint were performed.	At the 3–6-month recall, teeth were treated endodontically with calcium hydroxide if the teeth reacted negatively to sensitivity tests

Table 1: *Main results obtained from included papers.*

Study	Success rate	Reasons for failures	Follow-up period(years)	Mean age(years)	Technique	Endodontic treatment
ABELLA *et al.* 2018	91.7%	Severe inflamation; Tooth mobility.	2	41.5	The teeht was luxated passively with fórceps. The recipient socket was prepared a little larger than the donor using surgical round burs. A 3D tooth replica was used for guiding template. the transplanted teeth were stabilized with nonabsorbable surgical sutures and a wire splint.	Before surgery. In cases of impossobility to treat before, the root canal treatment was started 2 weeks after transplantation.

Note: NP – Non-provided

DISCUSSION

The present literature review had as main objective to evaluate the success rate reported in the studies that carried out the technique of dental autotransplante with complete rhizogenesis. In addition, the factors reported in these studies that may affect the success rates of this therapeutic modality were also evaluated.

The success rates of the selected studies varied, with the lowest success rate of 41% found in the study of Yoshino et al. 2013[11] and the highest success rate of 91.7% reported by Abella et al. 2018.[9] The difference of success between the different studies can be justified by different factors such as the technique used during the extraction and reimplantation protocols and the follow-up period. Different authors used varied techniques for extraction procedure and during the dental reimplantation. These differences may also explain the different success rates observed among the studies. An example of how the protocol can directly influence the success of therapy is demonstrated in the study of Yu et al. 2017.[12] In this study, dental reimplantation was performed with and without guided bone regeneration and treatment had different success rates: 93.3% with absence of guided bone regeneration and 88.9% with guided bone regeneration. Regarding the follow-up period, while Abella et al. 2018[12] had a success rate of 91.7% in a follow-up period of only two years, Yoshino et al. 2013[11] demonstrated a tendency to decrease the success rate with the increasing follow-up period. These authors reported that the success rate in the first 5 years was 100%, reducing to 72.7% in 10 years and to 54.5% after 15 years of follow-up.

Other factors pointed out by the studies is suggest to present a direct influence on the success rate of dental reimplants, such as the age and gender of the patient, and the endodontic treatment monitoring in the transplanted elements. However, divergences were found between studies. Yu et al. 2017,[12] demonstrated that age was an important factor for the failure rate, and the risk of loss of the transplanted tooth is higher in elder patients. In contrast, Yoshino et al. 2013[11] did not observe significant changes in the success rate of dental transplantation in patients of different ages. Regarding the gender factor, all studies report that there is no significant difference in success rates in male or female patients, except the study Yoshino et al. 2013,[10] the author suggests that women have a higher success rate in dental transplant therapy than male patients. The authors justify this difference in the fact that female subjects is more

collaborative in dental treatments and also presents better oral hygiene habits.

Regarding endodontic treatment, due to the revascularization is not expected the endodontic treatment is usually recommended before surgery or 2 weeks after transplantation. Aoyoma et al. 2012[7] reports that although endodontic treatment is performed after surgery, it presents a risk for transplantation, since the risk of infection remains in the transplanted tooth. Also, Abella et al. 2018[9] states that endodontic treatment should be performed prior to surgery if possible and 2 weeks after surgery if the tooth is not accessible for the procedure. These authors emphasize that a treatment performed before 2 weeks can cause damage to the periodontal ligament and if performed then the dental element can develop into a state of pulp necrosis and consequent periradicular lesion with possibility of apical inflammatory resorption. It is important to state that all authors recommend performing endodontic treatment in all cases of dental transplantation of teeth with complete rhizogenesis, since they suggest that revascularization of these teeth are improbable.

Two types of sequelae may occur after performing the dental transplant technique: root resorption and dental ankylosis. Root resorption may occur mainly in cases where extraoral time is significant, or by local factors such as inflammation and lesions on the root surface. Specific treatments of root resorption involve the use of intracanal medications and the monitoring of the tooth. Even in the cases of ankylosis, although it cannot be considered a physiological condition, it does not necessarily result in tooth loss. One way to prevent the occurrence of ankylosis is stabilization of the transplanted tooth using semi-rigid restraint. This type of restraint allows slight movement of this tooth during the post-surgical period. When the tooth is stable in the alveolar bone, it is not necessary invasive interventions.

Two relevant aspects should be emphasized in the present review: the need of antibiotic therapy and the tooth splitting. The literature is controversial regarding the need of antibiotic therapy in cases of dental transplants. The studies included in this review demonstrated different results when antibiotic therapy was used or not. Since surgery is planned and performed under aseptic conditions, many authors does not recommend the use of antibiotic therapy. This is in agreement with the guidelines of the International Association of Dental Traumatology (IADT) for cases of avulsions[13]. Although dental transplants and cases of dental avulsion are different, in both cases there is a dislocation of the tooth in the alveolar bone - intentional or not - and a rupture of the vasculature and the fibers of the periodontal ligament. Therefore, both conditions can be comparable.

The reported splinting of the cases used in this review were performed to stabilize the transplanted teeth, in addition prevents the bacterial colonization, optimizing the teeth integration and preventing ankylosis. The studies demonstrated that the splint was performed with resin and orthodontic wire, absorbable suture yarns or the two materials together. Splinting should be performed to improve the chances of success, since it optimizes teeth integration. The splint performed in the studies was semi-rigid for the reasons cited above.

The success rates of autotransplantation as well as its long term survival rates will depends on several variables, such as the bone condition of patient, the surgical technique which includes the bone and periodontal preservation, the correct split choice, the endodontic treatment preformed at the proper moment, the patients homecare and patients' response. All these factors minimize the chance of ankilosys and inflammatory resorption and improve the tooth prognosis. [7]

CONCLUSION

Dental autotransplantation of teeth with complete rhizogenesis is a viable procedure for recovering function and aesthetics. This procedure presents a moderate success rates that varied among the studies. The success rates are increased when the dental reimplantation is performed using strict protocols. In addition, the follow-up period of 5 years is recommended.

REFERENCES

1. Tanaka T, Deguchi T, Kageyama T, Kanomi R, Inoue M, Foong KW. Autotransplantation of 28 premolar donor teeth in 24 orthodontic patients. Angle Orthodontist 2008; 78:12-9.
2. Tsukiboshi M. Autotransplantation of teeth: requirements for predictable success. Dent Traumatol 2002; 18:157-80.
3. Miller HM. Transplantation: a case report. J Am Dent Assoc 1950:40;237.
4. Andreasen JO, Paulsen HU, Yu Z, Bayer T, Schwartz O. A long-term study of 370 autotransplanted premolars. Part II. Tooth survival and pulp healing subsequent to transplantation. Eur J Orthod 1990; 12:14-24.
5. Kim S, Lee SJ, Shin Y, Kim E. Vertical bone growth after autotransplantation of mature third molars: 2 case reports with long-term follow-up. J Endod 2015; 41:1371-4.
6. Kristerson L. Autotransplantation of human premolars. A clinical and radiographic study of 100 teeth. Int J Oral Surg 1985;14:200-13.
7. Aoyama S, Yoshizawa M, Niimi K, Sugai T, Kitamura N, Saito C. Prognostic factors for autotransplantation of teeth

with complete root formation. Oral Surg Oral Med Oral Pathol Oral Radiol 2012;114: S216-28.
8. Sugai T, Yoshizawa M, Kobayashi T, Ono K, Takagi R, Kitamura N, et al. Clinical study on prognostic factors for autotransplantation of teeth with complete root formation. Int J Oral Maxillofac Surg 2010; 39:1193–203.
9. Abella F, Ribas F, Roig M, González Sánchez JA, Durán-Sindreu F. Outcome of autotransplantation of mature third molars using 3-dimensional–printed guiding templates and donor tooth replicas. J Endod 2018; 44:1567-74.
10. Yoshino K, Ishizuka Y, Sugihara N, Kariya N, Namura D, Noji I, et al. Gender difference in tooth autotransplantation with complete root formation: a retrospective survey. J Oral Rehabil 2013b;40;368–74.
11.Yoshino K, Kariya N, Namura D, Noji I, Mitsuhashi K, Kimura H, et al. Suvival rate in Autotransplanted Premolars with complete Root Formation: A Retrospective Clinical Survey. Bull Tokyo Dent Coll 2013 a; 54:27-35.
12.Yu HJ, Jia P, Lv Z, Qiu LX. Autotransplantation of third molars with completely formed roots into surgically created sockets and fresh extraction sockets: a 10-year comparative study. Int J Oral Maxillofac Surg 2017; 46:531–8.
13. Andersson L, Andreasen JO, Day P, Heithersay G, Trope M, Diangelis AJ, et al. International Association of Dental Traumatology guidelines for the management of traumatic dental injuries: 2. Avulsion of permanent teeth. Dent Traumatol 2012;28:88-96.

THE USE OF HYPNOSIS IN DENTAL CARE – A LITERATURE REVIEW

Pâmella de Morais **Seabra**[1], Aline dos Santos **Letieri**[2], Adílis Kalina **Alexandria**[1], Thais Rodrigues Campos **Soares**[1*]

[1]Dental School of Universidade Salgado de Oliveira, Niteroi, RJ, Brazil.
[2]Department of Pediatric Dentistry and Orthodontics, School of Dentistry, Universidade Federal do Rio de Janeiro, Rio de Janeiro, RJ, Brazil.

Palavras-chave: Hipnose. Odontologia. Assistência Odontológica. Assistência Ambulatorial. Hipnose em Odontologia.

RESUMO

Introdução: A hipnose é uma técnica que envolve a indução de um estado especial de consciência em que a mente consciente relaxa enquanto a mente inconsciente se manifesta trabalhando a imaginação. **Objetivo**: Realizar uma revisão de literatura para avaliar as diferentes técnicas utilizadas para induzir a hipnose e a necessidade de seu uso no atendimento odontológico, bem como, seus resultados. **Fontes de dados**: Uma pesquisa bibliográfica foi realizada nas bases de dados Google Acadêmico e PubMed para identificar estudos para revisão. Não houve restrição de idioma ou ano. Os critérios de inclusão foram os estudos que abordaram o tema de interesse. **Síntese dos dados:** A hipnose visa melhorar o atendimento, controlando a ansiedade, o medo e as fobias dos pacientes. Entretanto, seu uso é pouco conhecido pelos pacientes e profissionais no contexto do tratamento odontológico. Existem duas técnicas de hipnose, a saber, hipnose essencial e hipnose por fixação objetal. As principais indicações são a necessidade de controlar o medo e a ansiedade do paciente durante o tratamento odontológico e preparar os pacientes antes de realizar procedimentos cirúrgicos. Pode ser usado em associação com anestésicos locais, mas essa combinação não é essencial. **Conclusão**: A hipnose pode ser eficaz no controle dos sentimentos dos pacientes relacionados ao atendimento odontológico, sendo a hipnose pela fixação do objeto a técnica mais utilizada para esse fim. É considerado fácil, rápido, indolor, com baixos custos e acessível a qualquer dentista que tenha completado o treinamento específico neste campo.

Keywords: Hypnosis. Dentistry. Dental Care. Ambulatory Care. Hypnosis. Dental.

ABSTRACT

Introduction: Hypnosis is a technique that involves inducing a special state of consciousness in which the conscious mind relaxes while the unconscious mind manifests itself by working the imagination. **Objective**: To perform a literature review to evaluate the different techniques used to induce hypnosis and the need for its use in dental care, as well as, its results. **Sources of data:** A bibliographic search was performed in the Google Academic and PubMed databases to identify studies for review. There was no restriction on language or year. Inclusion criteria were studies that addressed the topic of interest. **Synthesis of data**: Hypnosis aims to improve care by controlling patients' anxiety, fear and phobias. However, its use is little known by patients and professionals in the context of dental treatment. There are two techniques of hypnosis, namely essential hypnosis and hypnosis by object fixation. The main indications are the need to control the patient's fear and anxiety during dental treatment and to prepare the patients before performing surgical procedures. It can be used in association with local anesthetics, but this combination is not essential. **Conclusion**: Hypnosis can be effective at controlling patients' feelings related to dental care, being the hypnosis by object fixation the most used technique with this purpose. It is considered easy, quick, painless, with low costs and accessible to any dentist who has completed specific training in this field.

Submitted: November 27, 2018
Modification: January 23, 2019
Accepted: January 26, 2019

***Correspondence to**:
Thais Rodrigues Campos Soares
Address: Curso de Odontologia, Universidade Salgado de Oliveira
Rua Marechal Deodoro, 263, Centro, Niterói/RJ, Brasil – CEP: 24030-060
Telephone number: 55 (21) 21384865
Email: dra.thaissoares@yahoo.com.br

INTRODUCTION

The aim of dentistry is to restore and maintain oral health, often using highly technologically developed techniques. However, the oral health of the Brazilian population is still considered bad, with dental caries being the most common and debilitating diseases affecting the oral cavity.[1] Although the DMFT index in Brazil has been one of the world's highest, the prevalence of dental caries has been declining since 1970, thanks to investment in oral health, which has expanded access to public dental services, especially for the poorest population.[2,3] Despite this advance in dentistry, there are still many people who do not seek or cannot access dental care.[1]

There are three main factors that might explain why the Brazilian oral health situation remains precarious: the socioeconomic conditions of the population, making it difficult to access the places of care because of high costs; the lack of information on oral hygiene; and the fear and/or phobia of going to the dentist.[1] This problem in oral health does not present as a threat to life initially, but directly affects the quality of life, with an impact on aesthetics and chewing, besides causing pain and discomfort and functional and social limitations.[4,5]

During the dental treatment of children, the dentist uses techniques related to behavioural control, and when these techniques are not effective, there are other methods that can be used to help improve care.[6] Despite the fact that many adults are afraid of dental care, the use of such techniques during their treatment is not common. Some methods that could be used for both adults and children with fears or phobias would be the use of drugs to control anxiety, conscious sedation with nitrous oxide or hospital care under general anaesthesia. There are also less widely used but more accessible and less invasive methods, such as acupuncture and hypnosis.[7]

The definition of hypnosis has undergone several modifications over the years. It was the American psychiatrist Milton Erickson who carried out new studies and defined hypnosis as it is known nowadays, i.e. as being a special state of consciousness. According to the Federal Council of Dentistry (FCD) in 2008, hypnosis can be performed by any qualified dentist, after completing a certified training course.[8,9]

In view of the above, the objective of the present study was to perform a literature review on the use of hypnosis as an aid to dental care, focusing mainly on its different techniques and its main indications and results.

MATERIALS AND METHODS

Study design

To conduct the literature review, a bibliographic search was performed in the Google Academic and in MEDLINE, via PubMed, databases. The descriptors "Hypnosis", "Dentistry", "Hypnosis Dental", "Dental Care", "Ambulatory Care" and "Treatment" were used with the Boolean operators "AND" and "OR". The search strategy used in MEDLINE (via PubMed) was: ((((Hypnosis OR Hypnosis Dental)) AND (Dentistry OR Dental Care))) AND (Ambulatory Care OR Treatment).

There was no restriction on language or year. Inclusion criteria were clinical investigations or literature reviews that addressed the use of hypnosis in dentistry, showing their main indications, the techniques used and/or the principal results. Studies that did not mention the techniques of hypnosis used as an aid in dental treatment, or those that did not report their indications or results, were excluded.

Synthesis of data

History

Hypnosis was first performed in the 18th century by the Viennese physician Franz Anton Mesmer, who coined the term Animal Magnetism or Mesmerism. The idea of Mesmerism was that animate organisms were subject to magnetic influences. Mesmer performed experiments in which he placed magnets next to his own body, requiring only contact with his hand for the therapeutic effect to be achieved.[8,10]

With the abandonment of Mesmerism, James Braid proposed, in 1841, a new technique, called Hypnosis, also known as Braidism or Neurohypnotism. This involved making a person enter into a trance through nervous system fatigue, usually by fixation on an object. Braid's technique does not depend on magnetism, but on the patient's physical and psychic state. When hypnosis occurs, the responsibility is deposited in the professional, who takes control of the patient's body, allowing the elimination of symptoms and the control of the behaviour.[8,10]

Sigmund Freud (1856–1939), a famous Viennese physician who is considered the "Father of Psychoanalysis", became interested in hypnosis, together with Charcot, with the aim of finding a physiological explanation of suggestion in the nervous system. However, Freud later abandoned hypnosis and set out for free association. With the emergence of psychoanalysis, hypnosis declined in popularity.[8,10] However, in the 20th century, the American psychiatrist Milton Erickson resumed his studies on the technique, his style being known as Ericksonian Hypnosis.[8]

In 1966, the Brazilian president Castelo Branco extended the practice of hypnosis to dentists, through article

6, items I and VI of law number 5081, which came into force in August of that year. Before being allowed to practice hypnosis, dental professionals need to obtain a certificate issued by the FCD after attending a course coordinated by a dentist qualified in the practice of hypnosis by the FCD, and to carry out a minimum of 180 hours theoretical and practical training, in addition to other requirements.[8,9]

Hypnosis has been practiced for years and has undergone various changes, both in its concept and practice. In scientific terms, hypnosis consists of a special state of consciousness, where the conscious mind, the left side of the brain, relaxes, allowing induction, while the unconscious mind, the right side of the brain, manifests itself, working the imagination. The dentist manages to reach the patient in this hypnotic state, usually using a monotonous and repetitive voice, in a quiet and calm environment.[11]

The physiological processes that allow the body under hypnosis to dispel pain have been studied. The most recent theory is that which considers exteroceptors (pain receptors) and the ascending reticular activating system (ARAS), which are bundles of cells close to the brain. When a person knows that he is going to undergo some painful process, he begins to release mainly cortisol, a hormone that produces stress and ends up depleting the brain. The hypnosis technique causes ARAS to induce the production of serotonin (well-being hormone) and beta-endorphins, creating an antagonism with cortisol. Recent studies using computed tomography have shown that the ARAS image changes from a state of pain to well-being when the patient is hypnotized.[11]

Patients with a history of psychosis who have a poorly established reality, children under 4 years old and elderly people, especially those with low intellectual activity, are contraindicated for hypnosis.[11] In these and other cases, the patient may be given medications to control anxiety prior to dental care. Benzodiazepines are the most commonly used oral tranquilizer drugs. In addition, there are reports of the use of *Valeriana officinalis*, which, unlike benzodiazepines, is practically free of side effects[12]. In addition to medications, the professional can use inhaled sedation with nitrous oxide.[13]

Main indications

Hypnotic practice provides techniques and methods that increase therapeutic efficacy in all dental specialties, requiring no resources such as drugs or complex instruments, and can be used in the clinical environment.[9]

The practice of hypnosis has several indications in dental care, the main one being to reassure the patient who is fearful or anxious about the treatment, thus facilitating the professional's work.[14]

In dentistry, in addition to being used as a substitute or adjuvant for local anaesthesia[19], hypnosis may be indicated for:

- Treating and/or controlling anxieties, fears and phobias related to dental procedures;
- Conditioning the patient for the adoption of hygiene habits, adaptation to the treatment and to the use of medicines, reeducation of food intake habits and the control of parafunctional habits;
- Preparing patients for surgery, helping to improve the patient's psychological condition;
- Adapting and motivating behaviours directed towards the dental treatment[9].

Techniques

Two classical techniques of hypnosis, called essential hypnosis and hypnosis by object fixation, have been studied. The first involves taking the patient through five degrees of trance: hypnoidal, light, medium, deep and somnambulic (Table 1). The second technique, called object-fixation hypnosis, involves asking the patient to stare at any point in the room or an object placed about 25 cm from his face. Then, the professional makes suggestions in a repetitive and monotonous way regarding muscle relaxation, weight on the eyelids and tearing. In response, the patient tends to close his eyes, so the hypnotist orders the patient to sleep. Then,

***Table 1**: Degrees of trance in Essential Hypnosis and its characteristics*

Degrees of Trance	Characteristics
HYPNOIDAL	Fatigue of the eyelids; apparent drowsiness; eye closure; deep mental relaxation; heavy limbs.
LIGHT	Complete physical relaxation; limb movement challenging.
MEDIUM	Involuntary automatic movement; partial amnesia; superficial anaesthesia (may stop feeling pain); selective deafness.
DEEP	Complete amnesia and anaesthesia; visual and auditory hallucinations; able to open eyes and talk while in the trance.
SOMNAMBULIC	Loss of the senses; sleepwalking; hallucinations.

Source: MARTINS, BATISTA, 2002[14]

the hypnotized individual will present similar characteristics to those hypnotized using the first technique, such as anesthesia and amnesia, among others.[14] Both are efficient, possessing several similarities and a few differences, with the methodology used to hypnotize being verbal, repeated and monotonous suggestion in both cases.[8]

Hypnotic technique can be suffered some modifications for young patients. Hypnorelaxation can include induction, deepening, special place/garden imagery and awakening. Stories or adventures, also can used, with individually tailored and elaborated with direct, indirect and ego strengthening suggestions to create absorbing and pleasant experiences.[15-18]

All techniques are similarity between them is the role of the professional, who first offers suggestions to the patient and, later, gives orders. This gradual sequence is of paramount importance to the success of hypnotic practice.[14]

The practice of hypnosis is efficient, regardless of the technique used, has several indications, and can be performed by any qualified dentist.[9,14] However, not all patients are eligible to receive hypnosis, as patients with mental impairment, the elderly or children under 4 years of age and patients undergoing psychiatric treatment.[11] In these situations, it is possible to use oral drugs such as benzodiazepines and *Valeriana officinalis.*[12]

Despite the effectiveness of using benzodiazepines for anxiety control, they have more contraindications than hypnosis. Diazepam (a representative of the benzodiazepines most commonly used in dentistry) has been indicated as a causative factor of cleft lip and cleft palate, so its use is contraindicated in pregnant women. It should also not be used in patients with sleep apnea, severe respiratory failure, children with physical or mental impairment, and people dependent on other central nervous system depressant drugs.[12]

Valeriana officinalis is a plant that produces a compound that is effective against anxiety and mild imbalances of the nervous system and, unlike benzodiazepines, has practically no known contraindications or harmful consequences. However, scientific research on its clinical use is scarce, and data on its use as an adjuvant to dental treatment is practically nonexistent.[12]

In addition to oral medications, conscious inhalation sedation with nitrous oxide and oxygen, which was first used for medicinal purposes in 1844, is another option. Its use is also effective in controlling the behaviour of odontophobic patients, since it has an anxiolytic, relaxing and slightly analgesic effect. This practice is extremely safe and has few contraindications. However, it is a technique that is underutilized in Brazil by dentists.[13,20] It can be used alongside hypnosis, with relaxation achieved through verbal suggestion, which will facilitate subsequent inhalation conscious sedation,[11] a combination of great clinical utility.[22]

Compare with other control techniques, hypnosis does not require any specific equipment, unlike conscious inhalation sedation with nitrous oxide and oxygen, which requires the use of relatively large and expensive equipment.[20] Also, a systematic review showed the benefits of non-pharmacological interventions on reducing mental distress were demonstrated with largest effects being shown for hypnosis. However, further high quality trials are needed to strengthen the promising evidence.[23]

CONCLUSION

The use of hypnosis in dental care has great value, since it allows patients who are fearful, phobic or anxious about the treatment to be treated better and more effectively, while also facilitating the dentist's work. In addition, it is considered an easy, painless, inexpensive technique that any professional who has undertaken appropriate training can use.

The hypnosis by object fixation the most used technique, however it is still surrounded by many myths, which hampers its use. In view of this situation, more studies are needed to confirm the efficacy of technique in order to reduce people's fear.

REFERENCES

1. Pauleto ARC, Pereira MLT, Cyrino EG. Saúde bucal: uma revisão crítica sobre programações educativas para escolares. Ciênc. Saúde Colet. 2004;9:121-130.
2. Cury JA, Tenuta LMA, Ribeiro CCC, Leme AFP. The importance of fluoride dentifrices to the current dental caries prevalence in Brazil. Braz. Dent. J. 2004;15(3):167-174.
3. Brasil. Ministério da Saúde. Secretaria de Atenção à Saúde. Secretaria de Vigilância em Saúde. SB Brasil 2010: Pesquisa nacional de saúde bucal: resultados principais. 2011.
4. Tesch FC, Oliveira BHD, Leão A. Mensuração do impacto dos problemas bucais sobre a qualidade de vida de crianças: aspectos conceituais e metodológicos. Cad. Saúde Pública. 2007;23:2555-2564.
5. Menezes KE, Pereira CAS, Pedro ACB, Dias AGA. Avaliação do impacto da doença cárie na qualidade de vida de crianças com faixa etária de 6 a 12 anos, atendidas na clínica odontológica da Faculdade São Lucas. Rev. Odontol. Univ. São Paulo. 2017;21(1):24-30.
6. Albuquerque CM, Gouvêa CVDD, Moraes RDCM, Barros RN, Couto CFD. Principais técnicas de controle de comportamento em Odontopediatria. Arq Odontol. 2010;46(2):110-5.
7. Appukuttan DP. Strategies to manage patients with dental

anxiety and dental phobia: literature review. Clin Cosmet Investig Dent. 2016;8:35.
8. Alakija G. Hipnose. Sitientibus, Feira de Santana. 1992;9(6):103-119.
9. Brasil. Conselho Federal de Odontologia. Resolução CFO-82/2008. Reconhece e regulamenta o uso pelo cirurgião-dentista de práticas integrativas e complementares à saúde bucal. Diário Oficial, Brasília, 26 jul. 2008. Available from: http://cfo. org. br/servicos-e-consultas/atonormativo.
10. Roza LAG. Textbook Freud e o inconsciente. 24ª ed. Rio de Janeiro: Jorge Zahar Ed. 2009.
11. Seixas L. Hipnose: sem dor e sem anestesia. c2015 [cited 2018 Nov 05]. Available from: http://www.samejspenser.com.br/2010/12/hipnose-sem-dor-e-sem-anestesia.html.
12. Soldatelli MV, Ruschel K, Isolan TMP. *Valeriana officinalis*: an alternative for the control of dental anxiety? Stomatos. 2010;16(30):89-97.
13. Picciani BLS, Humelino MG, dos Santos BM, dos Santos VDCB, de Oliveira Costa G, Silva-Júnior GO, et al. Sedação inalatória com óxido nitroso/oxigênio: uma opção eficaz para pacientes odontofóbicos. Rev. Bras. Odontol. 2014;71(1):72-5.
14. Martins F, Batista A. Atos de fala e hipnose. Psic. Rev. 2002;8(11):92-104.
15. Al-Harasi S, Ashley PF, Moles DR, Parekh S, Walters V. Hypnosis for children undergoing dental treatment. Cochrane Database of Systematic Reviews 2010, Issue 8. Art. No.: CD007154. DOI: 10.1002/14651858.CD007154.pub2.
16. Trakyali G, Sayinsu K, Muezzinoglu AE, Arun T. Conscious hypnosis as a method for patient motivation in cervical headgear wear- a pilot study. European Journal of Orthodontics 2008;30(2):147–52.
17. Gokli MA, Wood AJ, Mourino AP, Farrington FH, Best AM. Hypnosis as an adjunct to the administration of local anesthetic in pediatric patients. ASDC Journal of Dentistry for Children 1994;61(4):272–5.
18. Braithwaite K. Hypnorelaxation versus inhalation sedation in orthodontic extractions. MSc project. Department of Sedation and Special Care Dentistry. Guy's, King's and StThomas' Dental Institute of King's College 2005.
19. Erickson MH, Hershman S, Secter IL. Hipnose médica e odontológica: aplicações práticas. Workshopsy, 1994.
20. Oliveira ACB, Pordeus IA, Paiva SM. O uso do óxido nitroso como uma opção no controle de comportamento em Odontopediatria. J Bras Odontopediatr Odontol Bebê. 2003;6(32):344-50.
21. Atterbury RA. The use of verbal relaxation therapy for sedation during dental therapy. Anesth Prog. 1984;31(1):27-30.
22. Barber J, Donaldson D, Ramras S, Allen GD. The relationship between nitrous oxide conscious sedation and the hypnotic state. J Am Dent Assoc. 1979;99(4):624-626.
23. Burghardt S, Koranyi S, Magnucki G, Strauss B, Rosendahl J. Non-pharmacological interventions for reducing mental distress in patients undergoing dental procedures: Systematic review and meta-analysis.J Dent. 2018 Feb;69:22-31.
24. Neubern, M. Milton Erickson e o cavalo de tróia: A terapia não convencional no cenário da crise dos paradigmas em psicologia clínica. Psicol. : Reflex. Crít. 2002;15(2):363-372.

PERI-IMPLANT STATUS IN PARTIALLY EDENTULOUS INDIVIDUALS SUBJECTED TO DENTAL IMPLANT REHABILITATION

Carina Maciel **Silva-Boghossian**[1*], Priscila de Paula Nascente de **Godoi**[1], Tamyris Ignácio **Wakoff**[1], Claudia Maria **Pereira**[1]

[1]School of Dentistry, Postgraduate Program in Dentistry, and Postgraduate Program in Translational Biomedicine, University of Grande Rio (UNIGRANRIO), Duque de Caxias, RJ, Brazil.

Palavras-chave: Implantes Dentários. Doença Periodontal. Doença Peri-implantar

RESUMO

Objetivo: A reabilitação oral com o emprego de implantes dentários é uma rotina na clínica odontológica. Entretanto, as doenças peri-implantares podem se estabelecer ao redor dos implantes dentários com o passar do tempo. O objetivo deste estudo foi avaliar a saúde peri-implantar de indivíduos submetidos a tratamento com implantes dentários comparados a indivíduos com saúde periodontal e periodontite. **Métodos**: Os participantes do estudo foram submetidos a questionários anamnésicos e exame periodontal/ peri-implantar completo. Foram incluídos 20 indivíduos Portadores de Implantes Dentários (45% mulheres; idade média de 57,2 anos), 35 indivíduos com Saúde Periodontal (28,6% mulheres; idade média de 24,1 anos) e 25 indivíduos com Periodontite (20% mulheres; idade média de 47,5 anos). Estes últimos não possuíam implantes dentários. Diferenças significativas foram analisadas através dos testes Wilcoxon, Qui-quadrado e Kruskal-Wallis. **Resultados**: O grupo Portadores de Implantes Dentários possuía uma média de 3,9 implantes com tempo médio de instalação de 5,1 anos. Doença peri-implantar foi detectada em 75% dos indivíduos com implantes dentários, sendo 70% mucosite peri-implantar. Implantes dentários apresentaram profundidade de sondagem e nível clínico de inserção significativamente maior quando comparado a dentes dos mesmos indivíduos (p d" 0,004), ou de indivíduos com saúde periodontal (p < 0,0001). Apesar de implantes apresentarem menor acúmulo de biofilme dental, apresentaram maiores porcentuais de sangramento à sondagem comparado a dentes (nos mesmos indivíduos; p = 0,002) e a indivíduos com saúde periodontal (p < 0,0001). **Conclusão**: A população estudada apresenta uma relativamente alta prevalência de doença peri-implantar. Além disto, foi possível constatar que as características clínicas do tecido peri-implantar se assemelharam àquelas de indivíduos com periodontite.

Keywords: Dental Implants. Periodontal Disease. Peri-implant Disease.

ABSTRACT

Objective: Oral rehabilitation with dental implants has become a daily routine in dental clinics. However, peri-implant diseases can affect the tissues around dental implants over time. The aim of this study was to evaluate peri-implant health status in partially edentulous individuals rehabilitated with dental implants in comparison with either periodontally healthy individuals or those with periodontitis. **Methods:** Study participants were subjected to anamnestic questionnaires and full periodontal/ peri-implant examination. Twenty-five dental implant carriers (45% women; mean age, 57.2 years), 35 periodontally healthy individuals (28.6% women; mean age, 24.1 years), and 25 subjects with periodontitis (20% women; mean age, 47.5 years) were included. Those in the healthy and periodontitis groups had no dental implants. Significant differences were analyzed by Wilcoxon, Chi-square, and Kruskal-Wallis tests. **Results:** The dental implant carriers had an average of 3.9 implants with an average time of 5.1 years since insertion. Peri-implant disease was detected in 75% of individuals in the Dental Implant Carriers group (70% had peri-implant mucositis). Dental implants presented probing depths and clinical attachment levels significantly higher when compared with those of unaffected teeth from the same individuals (pd"0.004), or with teeth from periodontally healthy individuals (p<0.0001). Although implants presented less dental biofilm, they presented higher percentages of bleeding on probing compared with unaffected teeth in the same individuals (p=0.002) and with teeth in periodontally healthy individuals (p<0.0001). The population studied had a relatively high prevalence of peri-implant disease. **Conclusion:** It is possible to verify that the clinical characteristics of the peri-implant tissues resembled those of individuals with periodontitis.

Submitted: February 21, 2019
Modification: April 3, 2019
Accepted: April 5, 2019

[*]**Correspondence to:**
Dr. Carina M. Silva-Boghossian
Address: Rua Barão de Guaratiba 228, Gloria, Rio de Janeiro, RJ, Brazil,
Zip code: 22211-150.
Telephone number: +55 (21) 26727877
E-mail: carinabogho@unigranrio.edu.br

INTRODUCTION

The discovery of osseointegration facilitated the development of stable implants that can replace diverse body structures. In dentistry, in particular, the use of dental implants presents highly predictable outcomes over the long term.[1] Moreover, in some cases, dental implants are the only viable solution for rehabilitation.[2]

However, complications may arise due to factors such as surgical trauma, inadequate surgical procedures, inadequate use of antibiotics in the pre- and post-operative periods, pressure exerted by the prosthesis during healing, bacterial infection during or after surgery, improper initial loading, incorrect prosthesis planning, occlusal overload, and parafunctional activity.[2] Furthermore, peri-implant inflammation may develop, leading to two types of diseases, peri-implant mucositis and peri-implantitis.[3,4] Clinically, peri-implant mucositis is reversible inflammation concentrated in peri-implant soft tissues.[4,5] Conversely, peri-implantitis indicates that marginal bone loss is present around dental implants, which can result in implant loss.[3,4] Progression from peri-implant mucositis to peri-implantitis has been studied retrospectively.[6] It has been found that the onset of peri-implantitis may occur in most cases 3 years after dental implant insertion, when signs of bone loss can be detected.[6]

The estimation of the prevalence of peri-implant mucositis is around 48% for dental implants with 9 to 14 years of insertion.[3] In terms of peri-implantitis, its prevalence may vary from 6.6% to 36.6% in dental implants with 10 years of insertion.[3,7] In smokers, this prevalence might be higher, since smoking is a risk factor for peri-implantitis.[8]

Many factors can contribute to the increased risk of peri-implant disease, especially peri-implantitis.[2] A previous history of periodontitis may be considered the main factor.[3,7] In those studies, classification of periodontitis was based on the 1999 American Academy of Periodontology definition,[9] and most studies do not differentiate aggressive from chronic periodontitis.[8] Eradication of periodontitis in partially edentulous individuals is essential to avoid the presence of a reservoir of pathogenic species that can infect peri-implant sites.[10,11] Conversely, even patients with no history of periodontitis, particularly young individuals, may need follow-up and periodic peri-implant evaluation after final prosthesis insertion to prevent eventual peri-implant diseases that can occur late in life.[1,3,7] The lack of a maintenance program for those individuals, especially those treated at dental schools, may lead to negative peri-implant outcomes.[8] Therefore, the aim of this study was to evaluate peri-implant health status in partially edentulous individuals rehabilitated with dental implants in comparison with periodontally healthy individuals and those with periodontitis.

MATERIALS AND METHODS

Study population

This cross-sectional study was carried out from March 2014 to March 2015. The study population consisted of individuals treated at the Dental Clinic of the School of Dentistry and in the Implantology Specialization Clinic of UNIGRANRIO Duque de Caxias. Individuals rehabilitated with dental implants were treated between 2008 and 2013. Patients had no history of periodontitis at the time of dental implant insertion. Included individuals read and signed an informed consent explaining the study protocol, which was approved by the Research Ethics Committee of UNIGRANRIO (# 481.082).

Selection of individuals treated with dental implants to comprise the case group (Dental Implant Carriers group) was initially based on 316 dental records in the Post-Graduation Clinic archive from 2008 to 2013. After being screened, 74 individuals presented characteristics that were in accordance with the inclusion criteria of the present study. Due to telephone contact problems, it was possible to contact only 20 individuals, who underwent clinical examination (Figure 1). None of the participants in the Dental Implant Carriers group was in a maintenance program. Screening of participants without dental implants to comprise control groups (Healthy, N=35, and Periodontitis, N=25) was performed among individuals seeking treatment at the School of Dentistry Clinic. Participants in the Healthy and Periodontitis groups were included before treatment initiation.

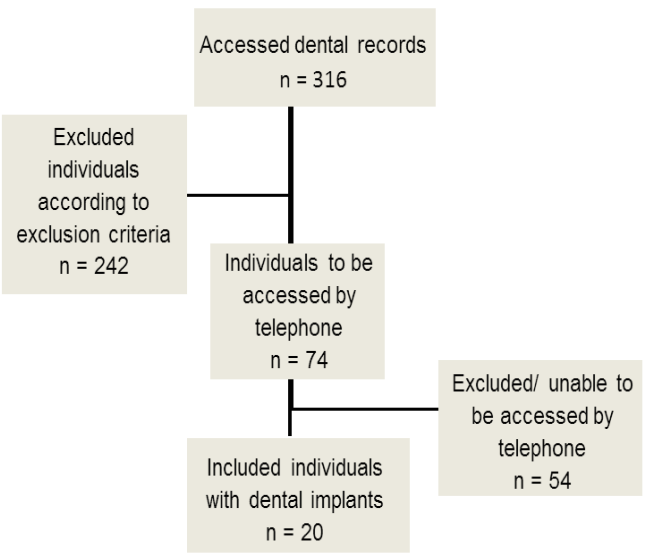

Figure 1: *Flow chart of the inclusion of individuals with dental implants.*

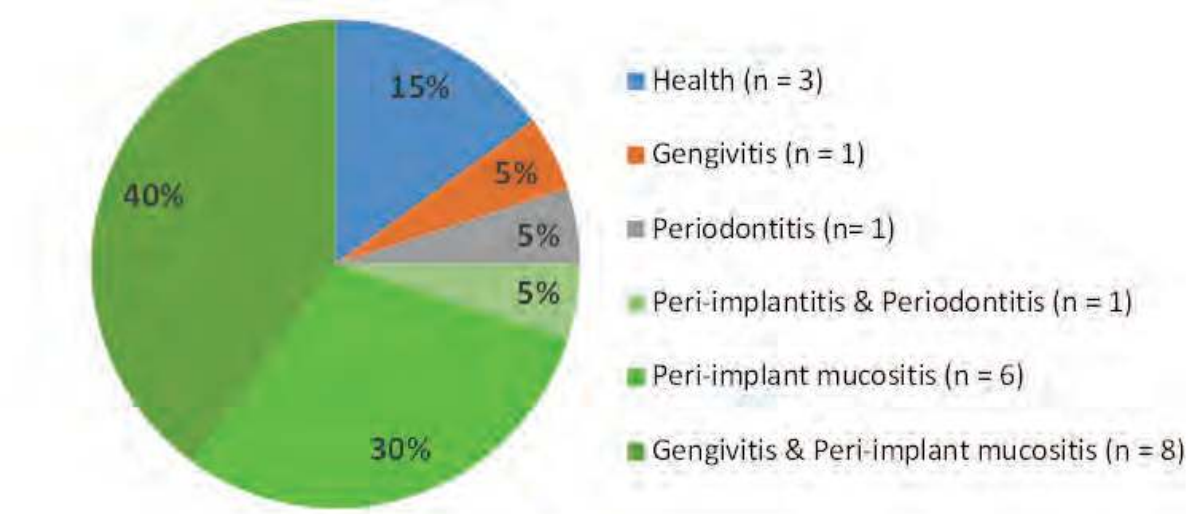

Figure 2: *Evaluation of the peri-implant tissue conditions in the individuals in the Dental Implant Carriers group.*

Inclusion criteria specified that individuals should be adults (> 18 years) with at least 14 teeth and/or dental implant(s). In addition, patients with dental implants should have had them inserted for at least 3 years prior to examination. Individuals with the following conditions were not included in the study: localized aggressive periodontitis; known diseases of the immune system (e.g. HIV-positive); diabetes; pregnant or breastfeeding; needing chemoprophylaxis for dental care; and having received periodontal treatment in the preceding year.

Included individuals were subjected to anamnestic questionnaires to register gender, skin color (race), general and oral health, and time of implant placement for Dental Implant Carriers.

Clinical examination

Clinical examinations were performed by a calibrated examiner who double-measured probing depths (PD), and clinical attachment levels were taken at one-week intervals in 5 patients from the Periodontitis group. The intracorrelation coefficient for clinical attachment level was 0.91 and that for PD was 0.87. In addition to registering the numbers of teeth and implants present, the clinical examination included dichotomized records of the presence of dental biofilm, bleeding on probing (BOP), suppuration on probing, and measurement in mm of PD and clinical attachment level. PD measured the distance between the gingival/mucosal margin and the most apically probable portion, in mm,[12,13] while clinical attachment level measured the distance from the implant/crown or enamel junction to the most apically probable portion, also in mm.[12,13] Periodontal examination was performed at six sites per tooth/implant, excluding third molars, by means of the Carolina do Norte probe (Hu-Friedy; Chicago) for teeth and the Colorvue® probe (Hu-Friedy) for implants. For Dental Implant Carriers, the numbers of implants present were recorded as well as the time of insertion. After clinical examination, dental implants with PD > 5 mm were subjected to radiographic examination for evaluation of alveolar bone loss.

Based on a report by da Silva-Boghossian and others,[14] periodontally healthy individuals should not present e" 10% of sites with BOP and/or attachment loss with BOP; individuals with gingivitis should have > 10% of sites with BOP without attachment loss in those teeth with BOP; and individuals with periodontitis should have PD > 4 mm with attachment loss and BOP. The diagnoses of peri-implant mucositis was defined when BOP was present; when increased PD (> 4 mm) and BOP were present with radiographic evidence of alveolar bone loss, peri-implantitis was identified.[3] All individuals diagnosed with disease were referred for treatment at the School of Dentistry of UNIGRANRIO.

Data analysis

All statistical tests used in the present study were performed with a statistical program (SPSS Statistics 20, IBM Brazil, São Paulo, Brazil). The frequency of sites with BOP and dental biofilm, as well as the median and interquartile ranges (IR) of PD and attachment level, were calculated for each patient, and then in the group. Mean age, distribution of skin colors among individuals, and gender were also calculated. Mean values were also obtained for the number of implants inserted per patient, as well as the average insertion times. Participants were grouped according to their periodontal/peri-implant diagnoses. For categorical data, the Chi-square test was used. Differences in periodontal and peri-implant clinical data in individuals with dental implants were analyzed by the Wilcoxon statistical test. Differences among and between diagnostic groups were verified by Kruskal-Wallis and Mann-Whitney tests, respectively. The significance level was established at 5%.

Table 1: *Demographic data of the studied individuals.*

Variables	Groups			
	Dental Implant Carriers (N=20)	Healthy (N=35)	Periodontitis (N=25)	*p* value
Median for age (years; 95% confidence interval)	50.5 (46.7-58.5)	24.5 (20.5-36.1)	48 (44.3-54.3)	<0.0001*
% Females	45	28.6	20	NS**
% Smokers	0	2.9	28	0.001**
Skin color				
% White	35	51.4	60	NS**
% Black individuals with lighter skin	15	11.4	12	
% Black individuals with dark skin	50	37.1	28	

*Note: * Kruskal-Wallis test; ** Chi-square test; NS, non-significant.*

Table 2: *Periodontal clinical data from the included individuals.*

Variables	Groups				
	Dental Implant Carriers (N=20)		Healthy (N=35)	Periodontitis (N=25)	*p* value
	Teeth	Implants			
Median (mm; IR)					
PD	2 (0.6)	2.8 (1.4)*	2 (0.3) ‡	2.6 (0.7)	<0.0001
CAL	2.2 (1.1)	2.8 (1.5)*	2 (0) ‡	2.9 (1.3)	<0.0001
Median % (IR)					
Biofilm	12 (18)	0 (0)*	13.7 (28.2)	38.7 (44.9) §	<0.0001
Calculus	6 (16)	0 (0)*	5.9 (12.8)	17 (26.8) §	<0.0001
BOP	10 (29.5)	50 (51.5)*	2.9 (5.4) ‡	42.5 (38)	0.001
Mean % (± SD)					
Suppuration	0.4 (1.3)	1.5 (4.4)	0	0.6 (1.9)	NS
Dental implants Mean number of implants inserted (± SD)	-	3.9 (3.)	-	-	N/A
Mean time of insertion (in years; ± SD)	-	5.1 (2.1)	-	-	

*Note: * p d" 0.005, intra-group analysis, Wilcoxon test. † Kruskal-Wallis test, inter-group analysis. ‡ p < 0.0001, Mann-Whitney test, between Implants and Healthy groups. § p<0.0001, Mann-Whitney test, between Implants and Periodontitis groups. IR, Interquartile Range. SD, standard deviation. PD, probing depth. CAL, clinical attachment level. BOP, bleeding on probing.*

RESULTS

The mean age of those in the Dental Implant Carriers group was 57.2 (± 12.6) years, while for those in the Healthy group it was 24.1 (± 7.4), and in the Periodontitis group, 47.5 (± 8.2). Those averages were significantly different among groups (< 0.0001; Kruskal-Wallis test). Overall, most participants were females. However, in the Periodontitis groups only 20% of the individuals were female. There were no smokers in the Dental Implant Carriers group. In the Healthy and Periodontitis groups, 2.9% and 28% were smokers, respectively, with a significant difference between groups (p=0.001). Distribution of skin colors did not differ among groups (Table 1).

Periodontal clinical data are presented in Table 2. Median values for PD and CAL were, respectively, for teeth and implants in the Dental Implant Carriers group, 2 mm (1.6-2.3) and 2.2 mm (1.8-2.7), and 2.8 mm (2.6-3.7) and 2.8 mm (2.6-4.2), with statistically significant differences between them (p=0.001; Wilcoxon test). It was observed that the mean PD for teeth and implants in the Dental Implant Carriers group was 1.9 (± 0.7) and 3.1 (± 1.04) mm, respectively (data not shown). When values of PD in the Implant group were compared with those in the Healthy group (2 mm; IR, 0.3), a statistically significant difference was found (p<0.0001; Mann-Whitney test). CAL also differed significantly between teeth and implants in the Dental Implant Carriers group (p=0.004) and among groups (p<0.0001). CAL was also higher in the group with Implants when compared with the Healthy group (2 mm, 1.9-2.1), p<0.0001. The median percentages of biofilm (12% and 0%, respectively) and dental calculus (6% and 0%, respectively) were significantly greater in teeth compared with implants in the Dental Implant Carriers group (p=0.003). However, the percentages of biofilm (38.7%) and calculus (17%) were higher in the Periodontitis group compared with the other groups (p<0.0001). Conversely, BOP was significantly higher in the Implants group (50%) compared with teeth (10%) in the Dental Implant Carriers (p=0.002) and Healthy (2.9%) groups (p<0.0001).

A mean 3.9 (± 3) dental implants were present in the Dental Implant Carriers group, ranging from 1 to 7 implants (Table 2). Time of insertion ranged from 3 to 7 years, and the mean time of insertion was 5.1 (± 2.1) years.

Figure 2 shows the periodontal/peri-implant diagnoses of the individuals from the Dental Implant Carriers group. It was observed that only 15% of them were healthy in terms of periodontitis and peri-implantitis; 5% had gingivitis, and 5% had periodontitis with no disease in the implants. Remaining individuals (75%) presented peri-implant disease: peri-implantitis and periodontitis (5%), peri-implant mucositis (30%), and peri-implant mucositis and gingivitis (40%).

DISCUSSION

Peri-implant mucositis is an inflammatory response to bacteria present in dental biofilm, and it can be considered a precursor of peri-implantitis.[15] Therefore, the aim of this study was to evaluate peri-implant health status in partially edentulous individuals rehabilitated with dental implants at the Specialization Clinic of Implantology, UNIGRANRIO Caxias.

The current investigation faced an immense operational difficulty in recruiting individuals rehabilitated with dental implants in the past in the post-graduation clinic of UNIGRANRIO, because most of the participants' contact details (cell or telephone numbers) were outdated, and we could not reach past patients. However, it was possible to detect a high prevalence (75%) of peri-implant disease in the studied individuals. That prevalence is comparable with the highest reported by the American Academy of Periodontology, in which the prevalence of individuals with peri-implant mucositis ranged from 31 to 60%.[3] Moreover, a prevalence of peri-implantitis ranged from 6.6% to 36.6% in implants with 10 years of insertion.[3] That broad range in the findings may be the result of different methodological criteria adopted to evaluate the presence of peri-implant disease, or differences in study populations. Other aspects that can influence different results are the presence of risk factors, as well as times of implantation[16-18]; nevertheless, that was not the case for the implant group in our study, since there were neither smokers nor individuals with diabetes.

It should also be noted that some studied individuals had peri-implantitis but no periodontal disease in their teeth. In fact, in general, it was observed that the clinical parameters evaluated (PD, CAL, and BOP) were higher in implants compared with teeth in the same individuals. Similar results were previously reported, showing that mean PD and CAL in teeth (2.27 and 2.03, respectively) and in implants (3.36 and 2.51, respectively) differed significantly.[12] Moreover, current findings showed that the values of PD, CAL, and BOP in individuals in the Dental Implant Carriers group were comparable with those found in individuals in the Periodontitis group. These data are in accordance with those reported by Baelum & Ellegard,[17] who observed that around 25% of the studied dental implants showed PS > 5 mm, and 70% or more of the implants presented BOP. Another study[19] demonstrated that 23.4% of systemically healthy individuals with dental implants presented BOP and PD > 5 mm. Ferreira et al.[20] reported that 19% of implants had BOP and PD > 4 mm. It is important to remember that the force applied at the time of probing can provoke bleeding. However, the absence of BOP characterizes health in the peri-implant tissues.[21] It is also worth mentioning that the values of PD,

CAL, and BOP are the main parameters in periodontal diagnoses, and they were similar between studied dental implants in comparison with the Periodontitis group. However, the current investigation detected only one individual with peri-implantitis (5%). Despite the sample size, current findings may be aligned with those of other reports, such as that by Astrand et al.,[22] who reported 5% of peri-implantitis in individuals with dental implants. Other investigators have reported peri-implantitis in around 10% of the studied individuals.[16,20] The individuals studied in the Dental Implant Carriers group are relatively young, and the possibility of future destructive disease development cannot be excluded. In fact, aging may be a risk factor in the pathogenesis of peri-implantitis, similar to periodontitis pathogenesis.[23]

The current investigation demonstrated that many individuals with dental implants had periodontal disease. As mentioned previously, treatment of periodontitis in partially edentulous individuals is essential to avoid the establishment of peri-implant infection.[10,11] Therefore, individuals rehabilitated with dental implants should be included in a periodic preventive program, including peri-implant probing and radiographic follow-up.[3] It is likely that the lack of a preventive maintenance program was the main factor that influenced the presence of peri-implant disease in this study. It has been demonstrated that a higher risk for peri-implantitis exists when individuals are not included in a maintenance program,[8] which can be translated to poor plaque control and subsequent increased inflammation.

Limitations of the current investigation that may have influenced the presented results include significantly different ages between healthy individuals and the other two groups, and the presence of smokers in the periodontitis group. Moreover, the limited number of participants may also make it difficult for these results to be compared with those from other investigations.

CONCLUSIONS

The population studied has a relatively high prevalence of peri-implant disease. In addition, it is possible to verify that the clinical characteristics of the peri-implant tissues resembled those of individuals with periodontitis.

ACKNOWLEDGEMENTS

This work was presented as a course conclusion paper at the School of Dentistry, UNIGRANRIO Caxias. It was supported by the Foundation for Research Financial Support in the State of Rio de Janeiro (#E-26/110.357/2014 and #E-26/101.189/2014), FAPERJ (APQ1 and scholarship), Rio de Janeiro, and the National Foundation for the Development of Private Higher Education, FUNADESP, Brasília, Brazil.

REFERENCES

1. Rocha JMOB, Rettore Jr R, Cyrino RM, Costa FO, Cota LOM. [Peri-implant conditions in individuals rehabilitated in the dental implantology specialization course at CEO-IPSEMG]. Braz J Periodontol 2013;23:7-14.

2.Vazquez Alvarez R, Perez Sayans M, Gayoso Diz P, Garcia Garcia A. Factors affecting peri-implant bone loss: a post-five-year retrospective study. Clin Oral Implants Res 2015;26:1006-14.

3.[No authors listed] Peri-implant mucositis and peri-implantitis: a current understanding of their diagnoses and clinical implications. J Periodontol 2013;84:436-43.

4.Renvert S, Persson GR, Pirih FQ, Camargo PM. Peri-implant health, peri-implant mucositis, and peri-implantitis: case definitions and diagnostic considerations. J Clin Periodontol 2018;45 Suppl 20:S278-85.

5.Renvert S, Polyzois I. Treatment of pathologic peri-implant pockets. Periodontol 2000 2018;76:180-90.

6.Derks J, Schaller D, Hakansson J, Wennstrom JL, Tomasi C, Berglundh T. Peri-implantitis - onset and pattern of progression. J Clin Periodontol 2016;43:383-8.

7.Schwarz F, Derks J, Monje A, Wang HL. Peri-implantitis. J Periodontol 2018;89 Suppl 1:S267-90.

8.Dreyer H, Grischke J, Tiede C, Eberhard J, Schweitzer A, Toikkanen SE, Glöckner S, Krause G, Stiesch M. Epidemiology and risk factors of peri-implantitis: a systematic review. J Periodontal Res 2018;53:657-81.

9.Armitage GC. Development of a classification system for periodontal diseases and conditions. Ann Periodontol 1999;4:1-6.

10. Quirynen M, De Soete M, van Steenberghe D. Infectious risks for oral implants: a review of the literature. Clin Oral Implants Res 2002;13:1-19.

11. Quirynen M, Vogels R, Peeters W, van Steenberghe D, Naert I, Haffajee A. Dynamics of initial subgingival colonization of 'pristine' peri-implant pockets. Clin Oral Implants Res 2006;17:25-37.

12. Abreu MH, Bianchini MA, Magini RS, Rosing CK. Clinical and radiographic evaluation of periodontal and peri-implant conditions in patients with implant-supported prosthesis. Acta Odontol Latinoam 2007;20:87-95.

13. Brägger U, Burgin WB, Hämmerle CH, Lang NP. Associations between clinical parameters assessed around implants and teeth. Clin Oral Implants Res 1997;8:412-21.

14. da Silva-Boghossian CM, do Souto RM, Luiz RR, Colombo AP. Association of red complex, *A. actinomycetemcomitans* and non-oral bacteria with periodontal diseases. Arch Oral Biol 2011;56:899-906.

15. Lang NP, Berglundh T, Working Group 4 of Seventh European Workshop on Periodontology. Periimplant diseases: where are we now?—Consensus of the Seventh European Workshop on Periodontology. J Clin Periodontol 2011;38 Suppl 11:178-81.
16. Brägger U, Aeschlimann S, Burgin W, Hämmerle CH, Lang NP. Biological and technical complications and failures with fixed partial dentures (FPD) on implants and teeth after four to five years of function. Clin Oral Implants Res 2001;12:26-34.
17. Baelum V, Ellegaard B. Implant survival in periodontally compromised patients. J Periodontol 2004;75:1404-12.
18. Gruica B, Wang HY, Lang NP, Buser D. Impact of IL-1 genotype and smoking status on the prognosis of osseointegrated implants. Clin Oral Implants Res 2004;15:393-400.
19. Dvorak G, Arnhart C, Heuberer S, Huber CD, Watzek G, Gruber R. Peri-implantitis and late implant failures in postmenopausal women: a cross-sectional study. J Clin Periodontol 2011;38:950-5.
20. Ferreira SD, Silva GL, Cortelli JR, Costa JE, Costa FO. Prevalence and risk variables for peri-implant disease in Brazilian subjects. J Clin Periodontol 2006;33:929-35.
21. Lang NP, Berglundh T, Heitz-Mayfield LJ, Pjetursson BE, Salvi GE, Sanz M. Consensus statements and recommended clinical procedures regarding implant survival and complications. Int J Oral Maxillofac Implants 2004;19 Suppl:150-4.
22. Astrand P, Engquist B, Anzén B, Bergendal T, Hallman M, Karlsson U, Kvint S, Lysell L, Rundcranz T. A three-year follow-up report of a comparative study of ITI Dental Implants and Brånemark System implants in the treatment of the partially edentulous maxilla. Clin Implant Dent Relat Res 2004;6:130-41.
23. Silva-Boghossian CM, Luiz RR, Colombo AP. Periodontal status, sociodemographic, and behavioral indicators in subjects attending a public dental school in Brazil: analysis of clinical attachment loss. J Periodontol 2009;80:1945-54.

GENETIC POLYMORPHISM IN *ESR2* AND RISK OF TOOTH AGENESIS

Guido Artemio **Marañón-Vásquez**[1], Paula Porto **Spada**[2], Marjorie A. **Omori**[3], João **Zielak**[2], José Tarcísio Lima **Ferreira**[3], Mônica Tirre de Souza **Araújo**[1], Mírian Aiko Nakane **Matsumoto**[3], Erika Calvano **Küchler**[2,3*]

[1]Department of Pediatric Dentistry and Orthodontics, School of Dentistry, Federal University of Rio de Janeiro, Rio de Janeiro, RJ, Brazil
[2]Department of Dentistry, Positivo University, Curitiba, PR, Brazil
[3]Department of Pediatric Dentistry, School of Dentistry of Ribeirão Preto, University of São Paulo, Ribeirão Preto, SP, Brazil

Palavras-chave: Polimorfismo de Nucleotídeo Único. Receptor Alpha de Estrogênio. Receptor Beta de Estrogênio. Anodontia. Agenesia Dentária.

RESUMO

Introdução: A agenesia dentária (AD) é a ausência congênita de um ou mais dentes. Vários estudos vêm sugerindo o forte componente genético para essa condição. **Objetivo:** O presente estudo teve como objetivo avaliar se os polimorfismos genéticos nos genes que codificam os receptores de estrógeno (*ESR1* e *ESR2*) estão associados à ocorrrência de AD isolada em uma amostra brasileira. **Métodos:** Radiografias panorâmicas de 142 pacientes ortodônticos foram avaliadas para determinar AD de dentes permanentes (excluindo terceiros molares). O DNA dos pacientes foi extraído das células da mucosa bucal contidas na saliva para avaliar polimorfismos genéticos em *ESR1* (*rs2234693* e *rs9340799*) e *ESR2* (*rs1256049* e *rs4986938*) por genotipagem usando a técnica de PCR em tempo real. Para análises estatísticas, associações entre as distribuições dos alelos e genótipos e a ocorrrência de AD foram avaliadas para cada polimorfismo genético, com um alfa estabelecido de 5%. **Resultados:** Treze pacientes tiveram pelo menos 1 dente congenitamente ausente. O número de dentes congenitamente ausentes variou de 1 a 11. Os polimorfismos genéticos *rs2234693* e *rs9340799* no *ESR1* e *rs1256049* no *ESR2* não foram associados à AD ($p > 0,05$). Para o polimorfismo genético *rs4986938* no *ESR2*, as distribuições dos genótipos e dos alelos foram estatisticamente diferentes entre os pacientes com e sem AD ($p < 0,05$). O genótipo CC e o alelo C estavam super-representados nos pacientes com AD. **Conclusão:** Houve associação entre o polimorfismo genético *rs4986938* no *ESR2* e a ocorrrência de AD.

Keywords: Polymorphism, Single Nucleotide. Estrogen Receptor Alpha. Estrogen Receptor Beta. Anodontia. Tooth Agenesis.

ABSTRACT

Introduction: Tooth agenesis (TA) is the congenital absence of teeth. Several studies have proposed a strong genetic background for this condition. **Aim:** The present cross-sectional study aimed to evaluate whether genetic polymorphisms in the genes that code for estrogen receptors (*ESR1* and *ESR2*) are associated with the presence of isolated TA in a Brazilian sample. **Methods:** Panoramic radiographs of 142 orthodontic patients were assessed to determine TA of permanent teeth (excluding third molars). DNA of patients was extracted from buccal cells from saliva to evaluate genetic polymorphisms in *ESR1* (*rs2234693* and *rs9340799*) and *ESR2* (*rs1256049* and *rs4986938*) by genotyping using the real-time PCR technique. For statistical analyses, associations between the distributions of the alleles and genotypes, and the ocurrence of TA were assessed for each genetic polymorphism, with an established alpha of 5%. **Results:** Thirteen patients had at least 1 congenital missing tooth. The number of congenitally missing teeth ranged from 1 to 11. The genetic polymorphisms *rs2234693* and *rs9340799* in *ESR1* and *rs1256049* in *ESR2* were not associated with TA ($p > 0.05$). For the genetic polymorphism *rs4986938* in *ESR2,* the genotype and allele distributions were significantly different between the patients with and without TA ($p < 0.05$). The CC genotype and the C allele were overrepresented in the TA patients. **Conclusion:** The genetic polymorphism *rs4986938* in *ESR2* was associated with the ocurrence of TA.

Submitted: February 25, 2019
Modification: April 17, 2019.
Accepted: April 22, 2019.

***Correspondence to:**
Erika Calvano Küchler
Address: Department of Pediatric Dentistry, School of Dentistry of Ribeirão Preto, University of São Paulo. Avenida do Café s/n – Campus da USP, Ribeirão Preto, SP, Brazil – Zip code: 14040-904
Telephone number: + 55 (16) 3315-4102
E-mail: erikacalvano@gmail.com

INTRODUCTION

Tooth agenesis (TA) is the congenital absence of one or more primary or permanent teeth. This trait is one of the most common congenital anomalies in humans. Permanent teeth are more usually affected than primary ones.[1] The most common absent teeth are third molars, followed by premolars and upper lateral incisors.[2,3] Reports on the overall prevalence of TA in the permanent dentition vary substantially according to the studied population.[4]

TA can be classified into syndromic and non-syndromic TA. Syndromic TA refers to complex developmental syndromes associated with congenitally missing teeth.[5] More than 60 syndromes catalogued in Online Mendelian Inheritance in Man (OMIM) are associated with TA. Non-syndromic TA includes a congenitally missing tooth (or teeth) in an isolated form, without an association with any other major birth defect.[6] However, several studies have proposed a strong genetic background for isolated TA.[6-12]

Estrogen regulates cell growth, differentiation, and development. Cellular signaling of estrogen is mediated by estrogens receptors (ER), which have two forms: α and ß. The ER α is codified by *ESR1* and ER ß is codified by *ESR2.*[13] Expression of estrogen receptors have been identified in dental tissues.[14-16] Due to the role of estrogen in the differentiation of tooth-forming cells,[17,18] it is possible to hypothesize that genetic polymorphisms in *ESR1* and *ESR2* are involved in the occurrence of TA. The present study aimed to evaluate whether genetic polymorphisms in *ESR1* and *ESR2* genes are associated with isolated TA.

MATERIALS AND METHODS

Sample

The study protocol was reviewed and approved by the Ethics Committee of the School of Dentistry of Ribeirão Preto, University of São Paulo (CAAE 50765715.3.0000. 5419;01451418.3.0000.5419). Informed consent was obtained from all participant or parents/legal guardians during the orthodontic appointment.

Pre-treatment orthodontic records including panoramic radiographs from patients undergoing orthodontic treatment at the School of Dentistry of Ribeirão Preto, University of São Paulo were evaluated.

Patients younger than 6 years old, with craniofacial syndromes, oral clefts, chronic conditions, history of facial trauma or surgery, previous orthodontic treatment, records with missing radiographs, or radiographs with poor quality, were excluded for analyses. The sample consisted of 142 individuals aged 7 to 49 years old.

Determination of the tooth agenesis phenotype

All TA cases were clearly evidenced by assessing of the panoramic radiographs alone. All radiographs were examined following a standardized protocol.[2,3]

The inclusion criterion was having at least one permanent tooth affected, excluding third molars. TA was defined based on the age of subjects and the expected stage of tooth formation in the radiographs.[2,3] Second premolar agenesis was only considered on patients older than 8 years old.[3]

DNA extraction and genotyping

Patients were asked to rinse the mouth with 5 ml saline solution and expectorating the rinse in a propylene tube. DNA was extracted from buccal epithelial cells from this saliva sample.[19] The genetic polymorphisms in *ESR1* (*rs2234693* and *rs9340799*) and *ESR2* (*rs1256049* and *rs4986938*) were genotyping by real-time PCR technique using TaqMan technology (StepOne™ Real-time PCR System, Applied Biosystems, Foster City, USA). The characteristics of the polymorphisms assessed in *ESR1* and *ESR2* are presented in Table 1.

Statistical analysis

Absolute and relative frequencies were used to present the distributions of the genotypes and alleles for each polymorphism assessed. Fisher's exact test was performed to determine the association between these frequencies and the ocurrence of TA. Additionally, the Odds ratio was calculated for each association tested. A chi-square test was used to evaluate the Hardy-Weinberg equilibrium.

All analyses were performed using two-tailed tests on GraphPad Prism 5.0[a] package (Graph-Pad, San Diego, CA, USA) with a significance level of 5%.

RESULTS

Thirteen patients had at least 1 congenital missing tooth (mean age: 12.6 ± 1.56; 10 males, 3 females). The number of congenitally missing teeth ranged from 1 to 11. The characteristics of the TA patients are presented in Table 2. One hundred and twenty nine patients did not present TA (mean age: 15.4 ± 7.6; 58 males, 71 females).

The genotype and allele distributions for the studied genetic polymorphisms according to the ocurrence of TA are presented in Table 3. All the studied genetic polymorphisms were in Hardy-Weinberg equilibrium (Table 3).

The genetic polymorphisms *rs2234693* and *rs9340799* in *ESR1* and *rs1256049* in *ESR2* were not associated with TA ($p > 0.05$). The distribution of genotypes for all the studied genetic polymorphism *rs4986938* in *ESR2,* the genotype and allele distributions were significantly different between the patient with and without TA ($p < 0.05$). The CC genotype and the C allele were overrepresented in the TA patients.

Table 1: *Candidate genes and polymorphisms studied*

Gene	Locus	Genetic polymorphism	Type	MAF*	Base Change
ESR1	6q25.1	*rs2234693*	Intron variant	0.446	C/T
		rs9340799	Intron variant	0.281	A/G
ESR2	14q23.2	*rs1256049*	Intron variant	0.129	C/T
		rs4986938	Intron variant	0.259	C/T

*Note: *MAF: minor allele frequency*

Table 2: *Chraracteristics of the TA patients*

Patient	Age	Gender	Number of congenitally missing teeth	Congenitally missing teeth
1	13	Male	11	14,15,24,25,27,35,36,37,42,45,47
2	14	Female	2	35,37
3	13	Male	1	42
4	13	Male	1	22
5	11	Female	1	11
6	10	Male	9	31,32,33,34,35,36,37,41,42
7	11	Male	2	35,45
8	13	Male	1	45
9	16	Male	1	12
10	12	Male	4	31,41,42,43
11	14	Male	1	35
12	12	Female	1	32
13	12	Male	2	35,45

Table 3: *Distribution of genotypes and alleles according to the ocurrence of TA*

Genotype/Allele	TA n (%)	No TA n (%)	OR (95% CI)	*p* value
ESR1 rs2234693				
CC	2 (15.4)	19 (15.4)	Reference	
CT	5 (38.5)	56 (45.5)	1.18 (0.22-6.40)	>0.999
TT	6 (46.2)	48 (39.0)	0.84 (0.16-3.87)	>0.999
C	9 (34.6)	94 (38.2)		
T	17 (65.4)	152 (61.8)	0.86 (0.35-1.94)	0.833
HWp		0.704		
ESR1 rs9340799				
AA	7 (53.8)	63 (51.2)	*Reference*	
AG	4 (30.8)	50 (40.7)	1.39 (0.41-4.42)	0.755
GG	2 (15.4)	10 (8.1)	0.56 (0.12-2.97)	0.613
A 1	8 (69.2)	176 (71.5)		
G	8 (30.8)	70 (28.5)	0.89 (0.39-2.06)	0.821
HWp	>0.999			
ESR2 rs1256049				
CC	11 (84.6)	121 (93.8)	*Reference*	
CT	2 (15.4)	8 (6.2)	0.36 (0.07-1.89)	0.229
TT	0 (0)	0 (0)	NA	>0.999
C	24 (92.3)	250 (96.9)		
T	2 (7.7)	8 (3.1)	0.38 (0.08-1.89)	0.230
HWp		>0.999		
ESR2 rs4986938				
CC	9 (69.2)	38 (32.2)	*Reference*	
CT	3 (23.1)	62 (52.5)	4.90 (1.38-17.39)	0.027*
TT	1 (7.7)	18 (15.3)	4.26 (0.56-49.11)	0.259
C	21 (80.8)	138 (58.5)		
T	5 (19.2)	98 (41.5)	2.98 (1.14-7.44)	0.034*
HWp		0.450		

*Note: HWp, Hardy-Weinberg p value. * Statistically significant association. NA=not applicable*

DISCUSSION

Some research groups that study dental development have been focused on the understanding of the etiology of TA and other complex conditions that affect the human dentition. In the past few years, much progress has been made in the identification of the developmental basis of odontogenesis and the genes involved in TA.[6-12]

In fact, genetic polymorphisms in many genes, including *MSX1* (msh homeobox 1),[20] *PAX9* (paired box 9),[20] *FGF3* (fibroblast growth factor 3),[7] *FGF10* (fibroblast growth factor 10),[7] *FGFR2* (fibroblast growth factor receptor 2),[7] *FGFR1* (fibroblast growth factor receptor 1),[21] *BMP2* (bone morphogenetic protein 2),[6] *BMP4* (bone morphogenetic protein 4),[10,12] *TGFB1* (transforming growth factor beta 1),[11] *TGFB3* (transforming growth factor beta 3),[10] *IRF6* (interferon regulatory factor 6),[9] *MMP1* (matrix metalloproteinase 1),[22] *MMP20* (matrix metalloproteinase 20),[22] *MMP9* (matrix metalloproteinase 9),[10] *MMP13* (matrix metalloproteinase 13),[10] and *AXIN2* (axin-related protein 2)[20] have been associated with non-syndromic TA. However, to the best of our knowledge, this is the first study evaluating genetic

polymorphisms in estrogen receptors genes - *ESR1* (*rs2234693* and *rs9340799*) and *ESR2* (*rs1256049* and *rs4986938*) – and their involvement in the etiology of TA.

Our results suggested that *ESR2 rs4986938* might be involved in the risk of TA. Analyses evidenced an association between the genotypes frequencies and the ocurrence of TA (p = 0.030) for this polymorphism. Most common homozygotes (CC) showed an increased risk (OR = 4.90; 95% CI: 1.38-17.39) of presenting TA when compared with heterozygotes (CT). Similarly, individuals carrying the C allele presented an increased risk (OR = 2.98; 95% CI: 1.14-7.44) of presenting this phenotype.

A previous report demonstrated the expression of an estrogen receptor-associated protein in tooth germs of human fetuses, suggesting the participation of these on early stages of odontogenesis.[23] Considering that estrogen deficiency can affect the development of teeth,[24] we assume that genetic variations in the gene that encodes the ERβ could alter its function and, consequently, increase the risk of TA by altering the estrogen metabolism. With that point of view, a previous study showed an association between a polymorphism in the ER and dental fluorosis.[25] Despite our results being interesting, they should be evaluated with caution, because due to the small size of the sample, these could be a false positive (type I error).

Oligodontia is a rare genetic condition, which represents the congenital absence of six or more teeth in primary, permanent or both dentitions. In our sample, two patients presented oligodontia. It is possible that some genes are involved in the etiology only of severer TA cases (such as oligodontia), however, our sample size did not allow us to perform a stratified analysis, comparing only patients with oligodontia with control patients (without TA). In fact, mutations in *MSX1,*[26,27] *PAX9*[26] and *AXIN2*[28] were previously associated with oligodontia.

Odontogenesis is an extremely complex process involving the interplay between the oral ectoderm and the ectomesenchymal cells derived from the neural crest.[29] Odontogenesis is under strict molecular control,[30] in which an alteration in different genes/molecules could lead to TA. It is important to emphasize that although we observed a statistical association between *ESR2* and TA, the role of estrogen receptors must still be extensively elucidated. Further studies are necessary to evaluate the expression of ERβ in the early stages of the odontogenesis. Similarly, new studies with a larger sample size are necessary to confirm the association observed in the present study.

CONCLUSION

The genetic polymorphism *rs4986938* in *ESR2* was associated with tooth agenesis in Brazilian individuals.

ACKNOWLEDGMENT

This work was supported by the São Paulo Research Foundation (FAPESP) (funding number: 2015/06866-5) and individual scholarships (FAPESP and CAPES).

REFERENCES

1. De Coster PJ, Marks LA, Martens LC, Huysseune A. Dental agenesis: genetic and clinical perspectives. J Oral Pathol Med. 2009 Jan;38(1):1-17. doi: 10.1111/j.1600-0714.2008.00699.x.
2. Küchler EC, Risso PA, Costa MC, Modesto A, Vieira AR. Assessing the proposed association between tooth agenesis and taurodontism in 975 paediatric subjects. Int J Paediatr Dent. 2008 May;18(3):231–4. doi: 10.1111/j.1365-263X.2007.00876.x.
3. Küchler EC, Risso PA, Costa Mde C, Modesto A, Vieira AR. Studies of dental anomalies in a large group of school children. Arch Oral Biol. 2008 Oct;53(10):941-6. doi: 10.1016/j.archoralbio.2008.04.003.
4. Polder BJ, Van't Hof MA, Van der Linden FP, Kuijpers-Jagtman AM. A meta-analysis of the prevalence of dental agenesis of permanent teeth. Community Dent Oral Epidemiol. 2004 Jun;32(3):217-26.
5. Acevedo AC, Poulter JA, Alves PG, de Lima CL, Castro LC, Yamaguti PM, et. al. Variability of systemic and oro-dental phenotype in two families with non-lethal Raine syndrome with mutations. BMC Med Genet. 2015 Feb;16(1):8. doi: 10.1186/s12881-015-0154-5.
6. Lu Y, Qian Y, Zhang J, Gong M, Wang Y, Gu N, et. al. Genetic variants of BMP2 and their association with the risk of non-syndromic tooth agenesis. PloS One. 2016 Jun;11(6):e0158273. doi: 10.1371/journal.pone.0158273.
7. Küchler EC, Lips A, Tannure PN, Ho B, Costa MC, Granjeiro JM, et al. Tooth agenesis association with self-reported family history of cancer. J Dent Res. 2013 Feb;92(2):149-55. doi: 10.1177/0022034512468750.
8. Vastardis H, Karimbux N, Guthua SW, Seidman JG, Seidman CE. A human MSX1 homeodomain missense mutation causes selective tooth agenesis. Nat Genet. 1996 Aug;13(4):417-21.
9. Vieira AR, Modesto A, Meira R, Barbosa AR, Lidral AC, Murray JC. Interferon regulatory factor 6 (IRF6) and fibroblast growth factor receptor 1 (FGFR1) contribute to human tooth agenesis. Am J Med Genet A. 2007 Mar;143A(6):538-45.
10. Antunes LS, Küchler EC, Tannure PN, Costa MC, Gouvêa CV, Olej B, et al. BMP4 Polymorphism is Associated With Nonsyndromic Oral Cleft in a Brazilian Population. Cleft Palate Craniofac J. 2013 Nov;50(6):633-8. doi: 10.1597/12-048.
11. Zhang W, Qu HC, Zhang Y. Association of MSX1 and TGF-β1 genetic polymorphisms with hypodontia: meta-analysis. Genet Mol Res. 2014 Nov;13(4):10007-16. doi: 10.4238/2014.November.28.5.

12. Gong M, Qian YJ, Gu N, Wang W, Wang H, Ma L, et. al. Association of BMP4 polymorphisms with isolated tooth agenesis in a Chinese Han population: a case-control study. Eur Rev Med Pharmacol Sci. 2015 Jun;19(12):2188-94.
13. Jia M, Dahlman-Wright K, Gustafsson JÅ. Estrogen receptor alpha and beta in health and disease. Best Pract Res Clin Endocrinol Metab. 2015 Aug;29(4):557-68. doi: 10.1016/j.beem.2015.04.008.
14. Alhodhodi A, Alkharobi H, Humphries M, Alkhafaji H, El-Gendy R, Feichtinger G, et al. Oestrogen receptor (ER) regulates osteogenic differentiation of human dental pulp cells. J Steroid Biochem Mol Biol. 2017 Nov;174:296-302. doi: 10.1016/j.jsbmb.2017.10.012.
15. Hietala EL, Larmas M, Salo T. Localization of estrogen-receptor-related antigen in human odontoblasts. J Dent Res. 1998 Jun;77(6):1384-7.
16. Jukic S, Prpic-Mehicic G, Talan-Hranilovc J, Miletic I, Segovic S, Anic I. Estrogen receptors in human pulp tissue. Oral Surg Oral Med Oral Pathol Oral Radiol Endod. 2003 Mar;95(3):340-4.
17. Wang Y, Yan M, Yu Y, Wu J, Yu J, Fan Z. Estrogen deficiency inhibits the odonto/osteogenic differentiation of dental pulp stem cells via activation of the NF-kB pathway. Cell Tissue Res. 2013 Jun;352(3):551-9. doi: 10.1007/s00441-013-1604-z.
18. Ferrer VL, Maeda T, Kawano Y. Characteristic distribution of immunoreaction for estrogen receptor alpha in rat ameloblasts. Anat Rec A Discov Mol Cell Evol Biol. 2005 Jun;284(2):529-36.
19. Kuchler, EC, Tannure, PN, Falagon-Lotsch P, Lopes TS, Granjeiro JM, Amorin LM. Buccal cells DNA extraction to obtain high quality human genomic DNA suitable for polymorphism genotyping by PCR-RFLP and Real-Time PCR. J Appl Oral Sci. 2012 Jul-Aug;20(4):467-71.
20. Haddaji Mastouri M, De Coster P, Zaghabani A, Jammali F, Raouahi N, Ben Salem A, et. al. Genetic study of non-syndromic tooth agenesis through the screening of paired box 9, msh homeobox 1, axin 2, and Wnt family member 10A genes: a case-series. Eur J Oral Sci. 2018 Feb;126(1):24-32. doi: 10.1111/eos.12391.
21. Ruprecht A, Batniji S, Sastry KA, el-Neweihi E. The incidence of dental invagination. J Pedod. 1986 Spring;10(3): 265-72.
22. Küchler EC, da Motta LG, Vieira AR, Granjeiro JM. Side of dental anomalies and taurodontism as potential clinical markers for cleft subphenotypes. Cleft Palate Craniofac J. 2011 Jan;48(1):103-8. doi: 10.1597/09-159.
23. Leonardi R, Barbato E, Paganelli C, Lo Muzio L. Immunolocalization of heat shock protein 27 in developing jaw bones and tooth germs of human fetuses. Calcif Tissue Int. 2004 Dec;75(6):509-16.
24. Xu T, Yan M, Wang Y, Wang Z, Xie L, Tang C, et al. Estrogen deficiency reduces the dentinogenic capacity of rat lower incisors. J Mol Histol. 2014 Feb;45(1):11-9. doi: 10.1007/s10735-013-9533-4.
25. Ba Y, Zhang H, Wang G, Wen S, Yang Y, Zhu J, et al. Association of dental fluorosis with polymorphisms of estrogen receptor gene in Chinese children. Biol Trace Elem Res. 2011 Oct;143(1):87-96. doi: 10.1007/s12011-010-8848-1.
26. Guruprasad R, Nair PP, Hegde K, Singh M. Case report: nonsyndromic oligodontia. JIDA. 2011;3:450-4.
27. Bonczek O, Bielik P, Krejí P, Zeman T, Izakoviová-Hollá L, Šoukalová J, et. al. Next generation sequencing reveals a novel nonsense mutation in MSX1 gene related to oligodontia. PLoS One. 2018 Sep;13(9):e0202989. doi: 10.1371/journal.pone.0202989.
28. Beard C, Purvis R, Winship IM, Macrae FA, Buchanan DD. Phenotypic confirmation of oligodontia, colorectal polyposis and cancer in a family carrying an exon 7 nonsense variant in the AXIN2 gene. Fam Cancer. 2019 Jan. doi: 10.1007/s10689-019-00120-0.
29. Weston JA, Yoshida H, Robinson V, Nishikawa S, Fraser ST, Nishikawa S. Neural crest and the origin of ectomesenchyme, Neural fold heterogeneity suggests an alternative hypothesis. Dev Dyn. 2004 Jan;229(1):118-30.
30. Arte S, Nieminen P, Apajalahti S, Haavikko K, Thesleff I, Pirinen S. Characteristics of incisor-premolar hypodontia in families. J Dent Res. 2001 May;80(5):1445-50.

SEVERITY OF PERIODONTAL DISEASE IN SMOKERS

Gustavo **Feser**[1*], Ivette **Dulong**[2], Esteban **Funosas**[1], Ernesto **Radica**[1], Anabela **Quintero**[1], Maria Virginia **Antuña**[1], Ileana **Boccio**[1], Andres **Barros**[1], Delfina **Bello**[1], Carla **Grimoldi**[3], Nazaret **Basaldella**[3], Emiliana Gonzalez **Rian**o[3], Santiago **Pedrol**[4].

[1] Department of Periodontics, School of Dentistry, National University of Rosario, Argentina.

Palavras-chave: Hábitos de Fumar. Doença Periodontal. Perda do Anexo Clínico Periodontal.

Introdução: O objetivo do presente estudo foi avaliar a gravidade da doença periodontal em uma população de adultos com doença gengival ou periodontal que atende no serviço de periodontia da Faculdade de Odontologia da Universidade Nacional de Rosario. **Métodos**: O estudo avaliou as condições periodontais em fumantes e não fumantes. A amostra foi composta por 400 indivíduos: 268 não fumantes (SN) e 132 fumantes ativos (E). A classificação das doenças gengivais e periodontais foi baseada nos critérios da American Association of Periodontology (2017), recrutando pacientes com diagnóstico de gengivite, estágio II, III e IV de periodontite. Cada uma dessas patologias foi relacionada às diferentes faixas etárias para avaliar os riscos de perda de inserção clínica. As variáveis periodontais estudadas foram: profundidade de sondagem (DP), nível de inserção (AL), número de dentes presentes (TP), índice de higiene bucal (IOH), mobilidade dentária (M) e sangramento à sondagem (BOP). Uma análise multivariada também foi realizada para determinar o grau de responsabilidade dos diferentes fatores de risco, como idade, gênero, ser fumante e os anos de duração desse hábito, em relação à extensão e gravidade da doença periodontal. **Resultados**: Vinte e nove por cento das mulheres e quarenta por cento dos homens eram fumantes. As variáveis periodontais nos grupos de S e NS comportaram-se da seguinte forma: PD para NS 4,19 (± 0,67) e para S 5,37 (± 0,64); AL para NS 3,43 (± 1,28) e para S 4,30 (± 1,43); BOP para NS 41 (± 23,76) e para S 43,28 (± 23,56); OHI para NS 1,75 (± 0,61) e para S 1,82 (± 0,53); TP para NS 21,38 (± 6,13) e para S 21,20 (± 6,60); e M para NS 1,65 (± 0,74) e para S 2,10 (± 0,65). **Conclusão**: Os estágios II e III da periodontite se comportaram de maneira semelhante nos dois grupos, mas quando analisamos o estágio IV da periodontite, esta foi mais prevalente em fumantes, independentemente de sua idade. Quando a população foi estratificada de acordo com a idade dos indivíduos, o estágio IV da periodontite foi mais prevalente em pessoas idosas que não fumavam e em indivíduos jovens com menos de 40 anos que tinham o hábito. As variáveis periodontais PD, CAL e M foram encontradas com valores mais severos no grupo S.

Keywords: Smoking Habbits. Periodontal Disease. Periodontal Clinical Attachment Loss.

ABSTRACT

Introduction: The objective of the present study was to evaluate the severity of periodontal disease in a population of adults with gingival or periodontal disease who assist at the periodontics service of the Faculty of Dentistry of the National University of Rosario. **Methods**: The study evaluated the periodontal conditions in smokers and non smokers. The sample consisted of 400 individuals: 268 non-smokers (NS) and 132 active smokers (S). The classification of gingival and periodontal diseases was based on the criteria of the American Association of Periodontology (2017), recruiting patients with diagnoses of gingivitis, stage II, III and IV of periodontitis. Each one of these pathologies was related to the different age groups to assess the risks of clinical attachment loss. The periodontal variables studied were: probing depth (PD), attachment level (AL), number of teeth present (TP), oral hygiene index (OHI), tooth mobility (M) and bleeding on probing (BOP). A multivariate analysis was also carried out to determine the degree of responsibility of the different risk factors, such as age, gender, being a smoker and the years of that habit duration, in relation to the extent and severity of the periodontal disease**. Results:** Twenty-nine per cent of women and fourty percent of men were smokers. The periodontal variables in the groups of S and NS behaved in the following way: PD for NS 4.19 (± 0.67), and for S 5.37 (±0.64) ; AL for NS 3.43 (±1.28), and for S 4.30 (±1.43); BOP for NS 41 (±23.76), and for S 43.28 (±23.56); OHI for NS 1.75 (±0.61), and for S 1.82 (±0.53); TP for NS 21.38 (±6.13), and for S 21.20 (±6.60) ; and M for NS 1.65 (±0.74), and for S 2.10 (±0.65). **Conclusion:** Stage II and III of periodontitis behaved similarly in both groups, but when we analysed stage IV of periodontitis, it was more prevalent in smokers, regardless of their age. When the population was stratified according to the age of the individuals, stage IV of periodontitis was more prevalent in older people who did not smoke and in young individuals under 40 who had the habit. PD, CAL and M periodontal variables were found with more severe values in the S group.

Submitted: November 28, 2018
Modification: April 23, 2019
Accepted: April 25, 2019

[*]**Correspondence to:**
Gustavo Feser
Address: Periodontics Chair. School of Dentistry. National University of Rosario. Santa Fe 3160, Rosario, Argentina.
Zip code: 2000
Telephone number: + 54 (0341) 4210585
E-mail: g-feser@hotmail.com

INTRODUCTION

The habit of smoking is considered as a risk factor for periodontal disease. [1,2] Tobacco smoke has some 4000 to 5000 toxic substances, some of which are known to be carcinogenic elements for humans. A higher prevalence of periodontal disease has been reported in individuals who smoke.[3,4]

The clinical evidence shows that a greater bone loss occurs in smokers due to the mineral content of the bone being affected and its quality diminished.[5,6] The habit of smoking is strongly associated with the severity of the disease, the number of teeth lost, and refractory and recurrent periodontitis.[7,8,9]

In general, smokers have a lower response to different types of gingival and periodontal therapies, both from the point of view of healing times and in the parameters of final wound healing.[10,11,12,13] Smokers immune system is depleted in terms of response effectiveness, and a plausible explanation is based on the fact that smokers present vascular constriction in their gingiva. This would lead to a minimal presence of cellular defence elements at the critical site of the infection, together with a decrease in the titer and avidity of the antibodies.[14,15,16,17]

The objective of the present study was to determine the severity of the periodontal pathology in a group of patients attending the periodontics service of the Dental School of Rosario and to assess the relationship with other variables that may increase or decrease the severity of periodontal lesions.

MATERIALS AND METHODS

This epidemiological cross-sectional study (number of ethics commitee approval: 17552/269) of a group of patients who attended the periodontics service of the Faculty of Dentistry of Rosario covered a three-month period for collecting information obtained from oral clinical examination. Four hundred patients with periodontal disease not treated were observed. The following variables were taken as an inclusion criterion: the absence of systemic diseases that may be of risk for periodontal diseases, the absence of any type of periodontal gingival therapy in the last year and the patient who had consumed antibiotics of any kind in the last six months. The following were used as exclusion criteria: the presence of removable partial dentures, the use of orthodontic therapies in the last two years, and the regular intake of any type of medication that can modify the immunological and morphological parameters of the gingiva. Passive smoking patients who had regular contact with smoke were excluded from the study.

The variables studied were: probing depth (PD), attachment level (AL), number of teeth present (TP), oral hygiene index (OHI), tooth mobility (M) and bleeding on probing (BOP).

All the variables were performed on mesial and distal sites of the teeth with the exception of the third molars, and the supernumerary teeth were excluded from the examination.

To examine the PD, AL and BOP, the measuring instrument used was the Marquis probe, graduated at 3, 6, 9 and 12 mm, with a tip of 0.5 mm in diameter. The records were taken with two measurements in the mesial and distal faces close to the union with the vestibular and lingual or palatal faces of all the teeth studied. The gingival and periodontal pathologies were classified according to the criteria of the American Association of Periodontology in regard to the severity of the nosological entity in stage II, III and IV of periodontitis and by the extent of the destruction with localised parameters (when it affects up to 30% of sites or dental faces) and generalised (when the level of involvement is more than 30% of the sites).[18,19] For the BOP, we follow the criteria of Van der Velden (1979),[20] with which we determine the faces of positive ones such as those that bled when the probe was removed or within 30 seconds after being removed.

To examine the M, we follow the criteria of Miller (mobility index) a cotton clamp was used and categorised into four ranks: grade 0 without mobility, grade 1 vestibular – lingual or palatal mobility, grade 2 adds mobility towards mesial and distal, and grade 3 adds intrusion.

The oral hygiene examination was determined by visual inspection through a modified Greene and Vermillion index (1964).[21]

Half of the vestibular and lingual faces were not observed so as to avoid incorporating measurement biases into the study due to the presence of gingival recessions that could have been due to traumatic causes and not to infectious causes compatible with the nature of initiation and progression of periodontal diseases.

Smokers were defined as those who smoked cigarettes with pulmonary aspiration of smoke and consumption of blonde cigarettes.

Two different groups – non-smokers and smokers – were formed. Subsequently, the number of cigarettes consumed daily and the accumulated years of the habit were assessed.

The measurements were made by a single calibrated examiner and with the methodology blind regarding knowledge about the presence of smoking.

All individuals were informed about their participation in the epidemiological study and asked to sign a consent from. The study was adapted to the norms of the bioethics committee of the National University of Rosario.

Statistical analysis

The individuals were taken as the unit of analysis. To assess the proportion of smokers within the population, a continuous Goodman confidence interval was used.

For the relationship between the periodontal variables and the independent variable measured (smoking), a Kruskal–Wallis test was used.

A logistic regression analysis was implemented to categorise the different risk predictors and their influence on insertion loss as a gold parameter for measuring the final loss of periodontal support and to categorise the resulting disease.

The predictors studied were: age as an acquired risk factor and unfolded in categories (up to 30 years, from 30 to 40 years, from 40 to 50 years and more than 50 years of age), gender as an innate risk factor, the presence of smoking in three categories (not present, up to 10 cigarettes per day and more than 10 cigarettes per day) and the accumulated time since the habit began (observed as up to 10 years and more than 10 years).

The response variable was also categorised to facilitate the epidemiological analysis in four groups: clinical insertion loss d" 4mm (ICP d" 4mm), clinical insertion loss e" 5mm (ICP e" 5mm), clinical insertion loss in up to 30% of the sites (ICP < 30%), and clinical insertion loss in more than 30% of the sites (ICP > 30%)

All the variables were collected in all the sites (dental faces measured).

In the multivariate model, each predictor was expressed with its influence on the response variable accompanied by its OR and a confidence interval of 95%.

Epidat and Epi Info epidemiological programs (OMS) were used for data management, and SPSS® was used for the calculation of the tests and modelling.

The probability of type I error was set equal to 0.05 to obtain statistical significance.

RESULTS

The sample population consisted of 400 individuals categorised according to gender, with 250 women with an average age of 44.22 (95% CI 41.27–47.17) and 150 men with an average age of 40.36 (95% CI 34.86–42.60).

In reference to those smoking cigarettes, 268 did not smoke (NS) and 132 did (S). Regarding the age of the participants, there were no significant differences between the groups, with an average age of 42.99 (95% CI 38.27–43.69) and an age range between 16 and 73 years for the NS group, and an average age of 40.85 (95% CI 35.46–42.70) and an age range between 15 and 69 years for the S group (Table 1).

Twenty-nine per cent of the women and 40% of the men were smokers. The distribution of the absolute numbers is shown in Table 1.

When we determined the number of cigarettes consumed daily, the average was 13.64 cigarettes (95% CI 10.67–16.60) with a range of consumption of 5 to 50 cigarettes per day. When we observed the years since the smoking habit began, the average was 18.41 years (95% CI 9.65–22.17) with a range of 3 to 50 years. Periodontal variables in the groups of S and NS behaved in the following way: PD for NS 4.19 (± 0.67), and for S 5.37 (0.64), with a p value of 0.005; AL for NS 3.43 (1.28), and for S 4.30 (1.43), with a p value of 0.039; BOP for NS 41 (23.76), and for S 43.28 (23.56), with a p value of 0.545; OHI for NS 1.75 (0.61), and for S 1.82 (0.53), with a p value of 0.463; TP for NS 21.38 (6.13), and for S 21.20 (6.60), with a p value of 0.80; and M for NS 1.65 (0.74), and for S 2.10 (0.65), with a p value of 0.021. The values of PD, AL and M were statistically significant, with an aggravation in the S group (Table 2).

***Table 1**: Distribution of patients (non smokers and smokers) according to gender.*

		Non smokers	Smokers
Women age:44.22 (95CI 41.27-47.17)	N	178	72
	%	71%	29%
Men age: 40.36 (95CI 34.86-42.60)	N	90	60
	%	60%	40%
Total		268	132

Note: Age of Non Smokers 42.99(95CI 38,27-43.69) range from 16 to 73 years, smokers - 40,85 (95CI 35,46-42,70) range from 15 to 69 years.

***Table 2**: Evaluation of the behaviour of the variables in the different groups.*

	Non-smokers	Smokers	*p* value
N	268	132	
Probing depth (n ± SD)	4.19 (±0.67)	5.37 (±0.64)	0.005*
Attachment level (n ± SD)	3.43 (±1.28)	4.30 (±1.43)	0.039*
Bleeding on probing (n ± SD)	41 (±23.76)	43.28 (±23.56)	0.545
Oral hygiene index (n ± SD)	1.75 (±0.61)	1.82 (±0.53)	0.463
Teeth present (n ± SD)	21.38 (±6.13)	21.20 (±6.60)	0.80
Mobility (n ± SD)	1.65 (±0.74)	2.10 (±0.65)	0.021*

*Note: * Mann-Whitney test. Significant difference at the level of significance = p < 0.05. * Significant data.*

Within the cross-sectional design, the prevalence of the different nosological entities was obtained in relation to the presence or absence of the habit, which were expressed in absolute frequencies. Individuals in the NS group had 13% gingivitis associated with plaque, 59.4% stage III of periodontitis, and 27.5% severe periodontitis. Individuals in group S were distributed as 8.3% with plaque-associated gingivitis, 51.7% with stage II and III of periodontitis, and 40% with stage IV of periodontitis (Table 3).

***Table 3**: Relationship between periodontal diagnosis and smoking.*

		Non-smokers N (%)	Smokers N (%)
Periodontal Diagnosis	Gingivitis	35 (13.0%)	11 (8.3%)
	Stage II and III Periodontitis	160 (59.4%)	68 (51.7%)
	Stage IV Periodontitis	73 (27.5%)	53 (40.0%)

When we separated the populations of NS and S according to age (younger or older than 40 years of age), we observed the following: in the NS group, there was a higher prevalence of plaque-associated gingivitis in younger individuals, a slightly higher prevalence of stage II and III of periodontitis in those under 40 and a greater prevalence of stage IV of periodontitis in older individuals (Table 4).

***Table 4**: Relationship between age and diagnosis in the group of non-smokers.*

	Under 40 years of age		Over 40 years of age		Total	
	Smokers	Non smokers	Smokers	Non smokers	Smokers	Non smokers
Gingivitis	11 (17.2%)	33 (26.2%)	0 (0%)	2 (1.4%)	11 (8.3%)	35 (13.0%)
Stage II and III periodontitis	37 (58.6%)	85 (67.7%)	31 (45.2%)	75 (52.1%)	68 (51.7%)	160 (59.4%)
Stage IV periodontitis	16 (24.1%)	8 (6.2%)	37 (54.8%)	65 (46.6%)	53 (40.0%)	73 (27.5%)
Total	64 (48.0%)	126 (47.0%)	68 (52.0%)	142 (53.0%)	132 (100.0%)	268 (100.0%)

For the S group, percentages remained similar except for individuals younger than 40 years, who showed a significant increase in the prevalence of severe periodontitis (Table 4). The logistic regression analysis was carried out through a study of risk predictors, including age (up to 30 years, from 30 to 40 years, from 40 to 50 years and more than 50 years), gender, the presence of smoking (not present, up to 10 cigarettes per day and more than 10 cigarettes per day) and the duration of the habit (up to 10 years and more than 10 years), and crossing them with response variables, “CAL d” 4mm, “CAL e” 5mm, localised CAL < 30% and generalized CAL > 30%). The results of the variables were accompanied by their odds ratio and its corresponding 95% confidence interval (Table 5).

As the ages increases the smoking patients is 2 or 3 more likely to develop periodontal disease in both gender. Patients who smoke more than 10 cigarettes per day have 4 or 5 more chances of developing periodontal disease, this possibility became worse as time passes.

***Table 5**: Predictors and their relation with age, gender and smoking habits.*

PREDICTOR	"CAL d" 4 mm OR CI 95%	"CAL e" 5 mm OR CI 95%	CAL < 30% OR CI 95%	CAL > 30% OR CI 95%
Age				
Up to 30 years	0.99 (0.85–1.20)	0.82 (0.75–1.01)	1.58 (1.06–2.35)	1.25 (0.99–1.89)
From 30 to 40 years	0.97 (0.81–1.19)	0.89 (0.65–1.09)	1.75 (1.02–2.45)	1.45 (1.03–2.03)
40 to 50 years	1.18 (0.95–1.45)	1.21 (1.01–2.34)	2.64 (1.94–3.39)	3.01 (2.45–3.89)
More than 50 years	1.99 (1.20–2.99)	2.28 (1.79–3.21)	3.89 (2.45–4.38)	3.45 (2.68–3.99)
Gender				
Female	0.93 (0.81–1.03)	0.87 (0.78–1.03)	0.89 (0.79–1.04)	0.93 (0.80–1.19)
Male	0.95 (0.78–1.04)	0.85 (0.74–1.04)	1.07 (0.88–1.45)	1.05 (0.85–1.42)
Smoking Habits				
Not present	0.98 (0.75–1.25)	0.88 (0.75–1.02)	0.99 (0.88–1.41)	1.09 (0.87–1.47)
Up to 10 cigarettes per day	2.48 (2.40–4.41)	3.71 (2.48–5.30)	2.99 (2.01–3.89)	3.47 (2.98–4.74)
More than 10 cigarettes per day	3.89 (3.01–4.47)	3.97 (2.99–5.01)	3.88 (2.89–4.57)	4.59 (3.84–6.10)
Habit time				
Up to 10 years	3.57 (2.90–4.84)	3.43 (2.78–4.89)	3.48 (2.78–4.35)	4.49 (2.99–5.84)
More than 10 years	4.20 (2.29–5.89)	4.79 (3.41–5.02)	5.45 (3.53–6.81)	6.08 (5.01–7.89)

DISCUSSION

When we take an epidemiological and descriptive approach to the the population (pacients who assit at the Periodontics Service of the Faculty of Dentistry) in terms of the prevalence of periodontal disease, we observe that there was a higher prevalence of gingivitis in the NS group and in younger individuals. Stage II and III of periodontitis had a similar prevalence in both groups, but when we analysed stage IV of periodontitis, it was more prevalent in smokers, regardless of their age.

When we studied the age of individuals (under and over 40 years old) and crossed it with the variable "smoking", we observed that gingivitis was more prevalent in younger individuals, regardless of habit.

Stage II and III of periodontitis was similarly distributed in the S and NS groups. Severe periodontitis was more prevalent in older individuals who did not smoke, but the most valuable finding was the prevalence of severe periodontitis in young individuals under 40 years old who had the habit, which is a warning sign in terms of the destructive ability of tobacco use on oral tissues and at early ages.

In reference to the relationship between periodontal variables studied and presence of the habit, (PD), (AL) and (M) were found with more severe values in the S group. Other studies also determined a higher rate of CAL and periodontal tissues in smokers.[22,23,24]

The OHI and TP variables remained similar in both groups and even when compared with populations previously studied by our research team,[25,26] and in comparison with other published works.[27,28]

As periodontal disease has a multi-causal aetiological factor, it is not possible to analyse it only from the descriptive epidemiological point of view, and we delve into it more precisely by means of modelling carried out with a multivariate analysis through the logistic regression of the different risk predictors that may influence the severity and extent of CAL.

This analysis was useful for a more specific discrimination of risk indicators that may have greater or lesser weight on the variables studied and to establish precedents in the performance of subsequent analytical epidemiological studies.

The multivariate analysis was accompanied by its odds ratio and its 95% confidence interval.

Analysing the results obtained, we can deduce that the positive influence of age on slight CAL (equal to or less than 4mm) was similar to that on the severe CAL (equal to or greater than 5 mm). It also had similar influence on the extent of localised CAL (in less than 30% of the sites) and on the

generalised CAL (more than 30% of the sites). This indicates that older individuals have a higher probabilities of losing periodontal tissue regardless of whether they are smokers.[6]

Gender was not a determiner of risk for the CAL in this study, which is unlike other studies that suggested the male gender as having a higher risk of CAL.[29,30,31]

The presence of smoking definitely enhanced the extent and severity of periodontal disease, showing that individuals who smoked more than 10 cigarettes per day had the highest probabilitys of the risk estimators, the chances increased almost four times for localizated periodontits, and almost five times for generalized periodontitis; thus determining the dose-dependent nature of smoking with the periodontal pathology previously exposed in the literature.[32]

Finally, the number of years for which the habit persists remained a strong predictor of risk of periodontal tissue loss, demonstrated by high figures of estimators for those who smoked for more than 10 years consecutively.

If we perform a thorough analysis of the variables discussed here, we can observe that regardless of age and gender, smoking more than 10 cigarettes per day and for a time period greater than 10 years considerably aggravates both the extent and the severity of the loss of periodontal insertion.

The descriptive epidemiological analysis of the sample also determines a higher prevalence of loss of periodontal insertion in young individuals under 40 who smoke.

Analytical epidemiological studies are useful to observe the degree of responsibility of these and other risk factors and their relationship with periodontal disease.[33]

CONCLUSIONS

Stage II and III of periodontitis behaved similarly in both groups, but when we analysed stage IV of periodontitis, it was more prevalent in smokers, regardless of their age. When the population was stratified according to the age of the individuals, stage IV of periodontitis was more prevalent in older people who did not smoke and in young individuals under 40 who had the habit. PD, CAL and M periodontal variables were found with more severe values in the S group.

The extent and the severity of the loss of periodontal insertion have a direct association with the quantity of cigarettes (more than 10 cigarettes per day) and time of smoking (more than 10 year) in spite of age and gender.

REFERENCES

1. Page R, Offenbacher S, Schroeder HE, Seymour GJ, Kornman KS. Advances in the pathogenesis of periodontitis. Summary of developments, clinical implications and future directions. Periodontol 2000 1997; 14: 216–246.

2. Have J, Wattles J, Crowley M, Mandell R, Joshipura K, Kent RL. Evidence for cigarette smoking as a major risk factor for periodontitis. J Periodontol 1993 January; 64 (1): 16–23.

3. Rees T. Drugs and oral disorders. Periodontology 2000, 1998; 18: 21–36

4. The tobacco epidemic: A crisis of startling dimensions. www.who.org

5. Arno A, Schein O, Lovdal A, Waerhaug J. Alveolar bone loss as a function of tobacco. Acta Odontol Scand 1959; 17: 3–9.

6. Bergström J, Sören E, Preber H. Cigarette Smoking and Periodontal Bone Loss. J Periodontol 1991; 62: 242–246.

7. J. To I Figueras. Tobacco and cancer: From the Epidemiological Association to molecular evidence. Med Clin (Barc) 1999; 112: 589–594.

8. Ah MKB, Johnson GK, Kaldahl WB, Patil KD, Kalkwarf KL. The effect of smoking on the response to periodontal therapy. J Clin Periodontol 1994; 21: 91–97.

9. Grossi SA, Zambon JJ, Ho AW. Assessment of risk for periodontal disease. 1. Risk indicators for attachment loss. J Periodontol 1994; 65: 260–267.

10. Mandel I. Smoke signals: An alert for oral disease. J Am Dent Assoc 1994; 125: 872–877.

11. Bastiaan R, Reade PC. The effect of tobacco smoking on oral and dental tissues. Aus Dent J 1976; 21: 308.

12. Kristoffersen T. Periodontal condition in Norwegian soldiers. An epidemiological and experimental study. Scand J Dent Res 1970; 8: 34.

13. Sheiham A. Periodontal disease and oral cleanliness in tobacco smokers. J Periodontol 1971; 42: 259–263.

14. Bergström J, Preber H. Tobacco use as a risk factor. J Periodontol 1994; 65: 545–550.

15. MacFarlane G, Herzberg M, Wolff L, Hardie N. Refractory periodontitis associated with abnormal polymorphonuclear leukocyte phagocytosis and cigarette smoking. J Periodontol 1992; 63: 908–913.

16. James J, Sayers N, Drucker D, Hull P. Effects of tobacco products on the attachment and growth of periodontal ligament fibroblast. J Periodontol 1999; 70: 518–525

17. Ratka-Kruger P, Neukranz E, Raetzke P. Guided tissue regeneration procedure with bioresorbable membranes versus conventional flap surgery in the treatment of intrabony periodontal defect. J Clin Periodontol 2000; 27: 120–127.

18. The American Academy of Periodontology. Annals Vol. 4, International Workshop for a Classification of Periodontal Disease and Conditions. Vol. 4 No.1, 1999.

19. The American Academy of Periodontology. Proceedings of the Word Workshop in Clinical Periodontics Chicago: A.A.P. 1989, 1 / 23-24.

20. Van der Velden U. Probing force and the relationship of the probe tip to the periodontal tissues. J Clin Periodontol 1979 Apr; 6 (2): 106–14.

21. Greene JC, Vermillion JR. The simplified oral hygiene index. J Am Dent Assoc 1964 Jan; 68: 7–13.
22. Bolin A, Lavstedt S, Frithiof L, Henrikson CO. Proximal alveolar bone loss in a longitudinal radiographic investigation. IV. Smoking and some other factors influencing the progress in individuals with at least 20 remaining teeth. Acta Odontol Scand 1986; 44: 263–269.
23. Beck JD, Cusmano L, Green-Helms W, Koch GG, Offenbacher S. A 5-year study of attachment loss in community-dwelling older adults: incidence density. J Periodont Res 1997; 32: 506–515.
24. Machtei EE, Dunford R, Hausmann E, et al. Longitudinal study of prognostic factors in established periodontitis patients. J Clin Periodontol 1997; 24: 102– 109.
25. Eficacia de la higiene oral en adultos jóvenes fumadores y no fumadores. Feser G, Funosas E, Marí G, Escovich L. Av. Odontoestomatol 2003; 19-3: 141–148.
26. Dental death rate prevalence in smoker and non smoker adults with periodontal disease. Feser G, Funosas E, Marí G, Escovich L. Med Oral Patol Oral Cir Bucal. 2005 Jul 1;10 Suppl 2:E109-16.
27. Bergström J, Eliasson S, Preber H. Cigarette smoking and periodontal bone loss. J Periodontol 1991; 62: 242–246.
28. Kerdvongbundit V, Wikesjö UME. Effect of smoking on periodontal health in molar teeth. J Periodontol 2000; 71: 433–437.
29 U.S. Public Health Service, National Institute of Dental Research. Oral Health of United States Adults; National Findings. Bethesda, MD: National Institute of Dental Research; 1987. NIH publication number 87-2868.
30. U.S. Public Health Service, National Center for Health Statistics. Periodontal disease in adults, United States 1960-1962. Washington, DC: Government Printing Office; 1965. PHS publication number 1000, Series 11 No. 12.
31. Van der Velden U, Abbas F, Van Steenbergen TJ, et al. Prevalence of periodontal breakdown and presence of Actinobacillus actinomycetemcomitans in subjects with attachment loss. J Periodontol 1989; 60: 604–610.
32. Do LG, Slade GD, Roberts-Thomson KF, Sanders AE. Smoking-attributable periodontal disease in the Australian adult population. J Clin Periodontol 2008; 35: 398–404.
33. Genko RJ, Borgnakke WS. Risk factors for periodontal disease. Periodontol 2000.2013. Jun; 62 (1): 59.94.

SEVERE MALOCCLUSION NEGATIVELY IMPACTS ADOLESCENTS' QUALITY OF LIFE

Yasmin Pissolati Mattos **Bretz**[1], Gabriela Luíza Nunes **Souza**[1], Larissa **Corradi-Dias**[1*], Júnia Maria **Serra-Negra**[1], Saul Martins **Paiva**[1], Lucas Guimarães **Abreu**[1].

[1]Department of Pediatric Dentistry and Orthodontics, Faculty of Dentistry, Universidade Federal de Minas Gerais, Belo Horizonte, MG, Brazil.

Palavras-chaves: Má Oclusão. Adolescente. Qualidade de Vida. Epidemiologia. Saúde Pública.

RESUMO

Objetivo: Avaliar o impacto da má oclusão severa na qualidade de vida relacionada à saúde bucal de adolescentes (OHRQoL). **Métodos:** Este estudo consistiu em uma amostra de 117 adolescentes entre 11 e 12 anos, que responderam à versão brasileira da forma abreviada do Child Perception Questionnaire (CPQ11-14). Este questionário tem 16 itens distribuídos igualmente em quatro domínios: sintomas bucais (SO), limitações funcionais (LF), bem-estar emocional (BE) e bem-estar social (BS). Escores mais altos indicam um impacto negativo maior na OHRQoL. A má oclusão foi avaliada por meio do Índice Estético Dental. Os adolescentes foram alocados nas seguintes categorias: sem má oclusão/má oclusão leve, má oclusão definitiva e má oclusão severa. Análise descritiva, teste de Kruskal Wallis, teste de Dunn, regressão logística univariada e multivariada foram conduzidas. **Resultados:** Indivíduos com má oclusão severa apresentaram escores significativamente mais elevados do que aqueles sem má oclusão/má oclusão leve para o BE (p=0,001), BS (p=0,027) e para o escore total do CPQ11-14 (p=0,015). Adolescentes com má oclusão severa apresentaram 2,63 vezes mais chance de apresentar um impacto negativo alto na OHRQoL do que aqueles sem má oclusão/má oclusão leve, independentemente das variáveis de confusão (IC=1,07-6,45, p=0,035). **Conclusão:** A má oclusão severa afeta negativamente a OHRQoL dos adolescentes.

Keywords: Malocclusion. Adolescent. Quality of life. Epidemiology. Public health.

ABSTRACT

Aim: To assess the impact of severe malocclusion on adolescents' oral health-related quality of life (OHRQoL). **Methods:** This study consisted of a sample of 117 adolescents between 11 and 12 years, who answered the Brazilian version of the short form of the Child Perception Questionnaire (CPQ_{11-14}). This questionnaire has 16 items distributed equally across four domains: oral symptoms (OS), functional limitations (FL), emotional well-being (EW) and social well-being (SW). Higher scores indicate a greater negative impact on OHRQoL. Malocclusion was evaluated using the Dental Aesthetic Index. Adolescents were assigned to the following categories: no or slight malocclusion, defined malocclusion and severe malocclusion. Descriptive analysis, the Kruskal Wallis test, post hoc test, univariate and multivariate logistic regression were conducted. **Results:** Individuals with severe malocclusion presented significantly higher scores than those with no or slight malocclusion for the EW (p=0.001), SW (p=0.027) and for the overall CPQ_{11-14} score (p=0.015). Adolescents with severe malocclusion showed a 2.63 greater chance of presenting a high negative impact on OHRQoL than those with no or slight malocclusion regardless of the confounding variables (CI=1.07–6.45, p=0.035). **Conclusion:** Severe malocclusion negatively impacts adolescents' OHRQoL.

Submitted: February 14, 2019
Modification: April 4, 2019
Accepted: April 5, 2019

***Correspondence to:**
Larissa Corradi Dias
Address: Avenida Antonio Carlos, 6627, Pampulha, Belo Horizonte, MG, Brazil
Minas Gerais, Brazil, Zip code: 31270-901
Telephone number: +55 (31) 3409-2433
E-mail: larissacorradi@gmail.com

INTRODUCTION

The term oral health-related quality of life (OHRQoL) has been acknowledged as the functional and psychosocial repercussions of oral outcomes on people's lives. Studies evaluating OHRQoL have become viable through the use of psychometric quality of life instruments that have been developed to reliably assess such impact.[1] In the past, the focus of dental research was on the evaluation of the effect of oral outcomes on the quality of life of adult individuals. Over the last decade, however, there has been the emergence of many instruments for the assessment of OHRQoL among children and adolescents. These instruments allow researchers to examine the impact of a number of oral conditions on young individuals' quality of life.[2]

Oral health outcomes, such as caries and dental trauma may have a quite significant effect on adolescents' OHRQoL. Adolescent individuals affected by severe dental caries and those with dental fractures involving dentin/pulp show a more deteriorated quality of life than adolescents with no caries and those with no dental trauma or only minor fractures.[3,4] For dental caries, in particular, OHRQoL is very much deteriorated due to the emergence of symptoms, oral functioning impairment and psychosocial issues[5]. The repercussions go far beyond the young individual himself/herself. In the face of serious illness, parents/caregivers may feel regretful because their sons'/daughters' oral health condition. The number of parents/caregivers reporting family conflicts and time during which they need to interrupt their work activities due to dental appointment for their sons'/daughters' to solve oral health problems cannot be ignored.[3]

Other oral health issues, such as tooth misalignment and skeletal discrepancies have also been in the spotlight. Severe alterations may be scrutinized as unattractive by young individuals, leading to episodes of embarrassment and distress depending on ones' parameters.[6] Thus, the aim of this study was to assess the impact of severe malocclusion on adolescents' quality of life using an OHRQoL questionnaire, which evaluates oral symptoms, functional limitations, emotional well-being and social well-being[7] The null hypothesis was that severe malocclusion has no impact on young individuals' ORHQoL.

MATERIALS AND METHODS

Study design, participants, setting and eligibility criteria

A total of 120 adolescents between 11 and 12 years referred to orthodontic treatment at the Dental School of the Federal University of Minas Gerais in Belo Horizonte, Brazil were invited to take part in this study. The inclusion criteria were as follows: literate adolescents who were fluent in the Brazilian Portuguese language. Adolescents with syndromes or craniofacial anomalies were excluded from the study. So were those with dental caries, dental trauma or gingival diseases. Dental caries was diagnosed by means of the World Health Organization (WHO) criteria.[8] Dental trauma was diagnosed by means of the Andreasen criteria.[9] Gingival issues were identified using the guidelines of Löe. [10]

Ethical issues

Approval of the Ethics Committee of the Federal University of Minas Gerais was obtained. The right to refuse to participate in the study was guaranteed to adolescents and their guardians. For those who accepted to participant, written consent was obtained prior to data collection.

Variables

This cross-sectional study assessed the impact of malocclusion (independent variable) on adolescents' OHRQoL (dependent variable), controlling for adolescents' sex and age as well as household income (confounding variables).

OHRQoL assessment

Adolescents' OHRQoL was evaluated by means of the short form of the Child Perceptions Questionnaire (CPQ_{11-14}), which was designed in Canada in the English language[7] and was translated into Brazilian Portuguese and cross-culturally adapted for use on the Brazilian population.[11] The CPQ_{11-14} is made up of 16 questions equally distributed across four domains: oral symptoms (four questions), functional limitations (four questions), emotional well-being (four questions) and social well-being (four questions). The four-factor structure of CPQ_{11-14} has been confirmed by confirmatory factor analysis.[12] The 16 questions have five response options following an ordinal scale: never = 0, once/twice = 1, sometimes = 2, often = 3 and every day/almost every day = 4. Therefore, the overall CPQ_{11-14} score ranges from 0 to 64. A higher score is indicative of a greater negative perception on the part of the adolescent regarding the impact of oral outcomes on his/her quality of life. Scores for the four domains are also attainable.

Malocclusion evaluation

Malocclusion was assessed by means of the Dental Aesthetic Index (DAI).[13] The DAI is composed of 10 occlusal characteristics distributed across three pieces: dentition, crowding/spacing and occlusion.

• Dentition: number of missing teeth (incisors, canines and pre-molars)

• Crowding/spacing: crowding in the anterior teeth, spacing in the anterior teeth and diastema between the upper central incisors, greatest irregularity of the anterior teeth on the maxilla and greatest irregularity of the anterior teeth on the mandible

• Occlusion: maxillary overjet, mandibular overjet, anterior open bite and relationship between permanent upper first molar and permanent lower first molar.

The study's participants were examined and scores for each characteristic were provided. The scores were multiplied by a rounded coefficient, summed and the constant 13 was added to obtain the overall DAI score for each participant. Taking into consideration the overall DAI score, participants could be assigned to four malocclusion categories: DAI ≤ 25 (adolescents with no or slight malocclusion), DAI = 26 – 30 (adolescents with defined malocclusion), DAI = 31 – 35 (adolescents with severe malocclusion) and DAI ≥ 36 (adolescents with very severe malocclusion). In this study, individuals with severe malocclusion were placed along with individuals with very severe malocclusion in the severe malocclusion category. Thus, the participants were categorized as follows: adolescents with DAI ≤ 25 (no or slight malocclusion), adolescents with DAI = 26 – 30 (defined malocclusion) and adolescents with DAI ≥ 31 (severe malocclusion).

The dentist, who conducted the exams for malocclusion evaluation was calibrated by an orthodontist. This training was composed of a theoretical and a practical component. During the first, the orthodontist discussed the theoretical basis of the DAI with the dentist. During the second, 15 adolescents were examined by both assessors and the inter-examiner agreement was calculated. Ten day later, the adolescents were re-evaluated by the dentist and the intra-examiner agreement was calculated. Kappa coefficients were 0.84 for inter-examiner agreement and 0.90 for intra-examiner agreement.

Household income of adolescents' families

The household income of each adolescent's family was measured in terms of the minimum wage in Brazil (MMW), which was equal to US$ 325.00 at the time of the study and was determined as the sum of the income of all family members who accomplished labor activities. Household income was dichotomized, considering the median, as follows: adolescents whose families had a household income lower or equal to three MMWs (≥ 3 MMWs) and adolescents whose families had a household income higher than three MMBs (> 3 MMWs).

Statistical analysis

Data analysis was accomplished using the Statistical Package for the Social Sciences (SPSS for windows, version 22.0. IBM Corporation, North Castle, NY, USA). Descriptive statistics was carried out. Comparisons among the adolescents with different degrees of malocclusion (adolescents with DAI ≤ 25, adolescents with DAI = 26 – 30 and adolescents with DAI ≥ 31) regarding the domains and the overall CPQ_{11-14} score were performed by means of the Kruskal Wallis test (significance level set at $p<0.05$) and multiple comparison post hoc test (significance level set at $p<0.05$). Univariate logistic regression was carried out to evaluate the association of adolescents' overall CPQ_{11-14} score (dependent variable) with adolescents' malocclusion (independent variable), adolescents' sex and age as well as household income (confounding variables). Adolescents' malocclusion and confounding variables with a $p<0.20$ were incorporated into the multivariate logistic regression. For the final model, a $p<0.05$ was considered of statistical significance. For the univariate and the multivariate logistic regression, the participants were divided into two groups (high impact on OHRQOL group and low impact on OHRQoL group). To determine the groups to which the adolescents would belong, the median of the overall CPQ_{11-14} score was calculated. Adolescents with an overall CPQ_{11-14} score higher than the median were assigned to the high impact group. Adolescents with an overall CPQ_{11-14} score lower than the median were assigned to the low impact group.

RESULTS

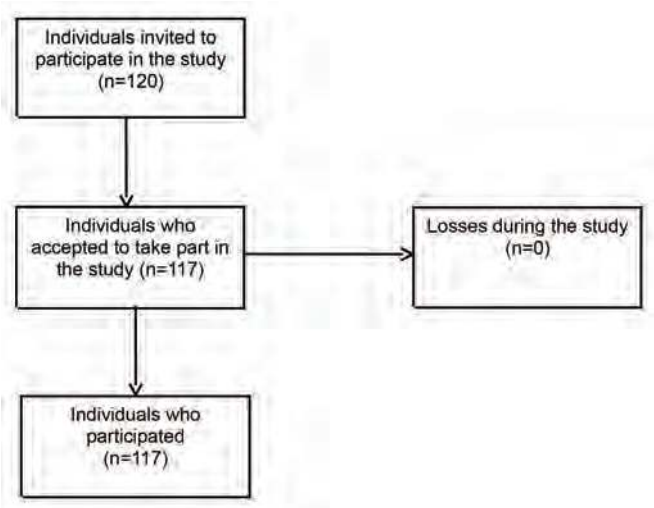

Out of the 120 individuals initially admitted to this study, three provided missing information. Therefore, 117 adolescents participated in this study (response rate = 97.5%). Figure 1 displays the flowchart of the study. The mean age of adolescents was 11.50 years (±0.50). Table 1 and Table 2 display the results of the comparison among adolescents with different degrees of malocclusion regarding the domains and the overall CPQ_{11-14} scores. Differences were observed in

***Table 1**: Comparison of the overall CPQ11-14 score and domain scores among individuals with different degrees of malocclusion*

	DAI ≤ 25Mean (Median) Min – Max	DAI = 26 – 30Mean (Median) Min – Max	DAI ≥ 31Mean (Median) Min – Max	*p* value*
oral symptoms	3.73 (4.00) 0 – 8	4.15 (4.00) 0 – 11	3.98 (4.00) 0 – 10	0.735
functional limitations	2.58 (2.00) 0 – 11	3.30 (3.00) 0 – 14	3.30 (3.00) 0 – 9	0.367
emotional well-being	1.98 (2.00) 0 – 8	2.45 (2.00) 0 – 13	4.14 (4.00) 0 – 15	**0.001**
social well-being	1.80 (1.00) 0 – 8	2.21 (2.00) 0 – 7	3.55 (2.00) 0 – 17	**0.024**
overall score	10.08 (10,00) 2 – 25	12.12 (11.00) 0 – 45	14.75 (13.00) 4 – 38	**0.020**

*Note: *Kruskal Wallis test. Significance level set at p < 0.05. Bold means statistical significance. DAI ≤ 25: no or slight malocclusion, DAI = 26 – 30: defined malocclusion, DAI ≥ 31: severe malocclusion.*

***Table 2**: Comparison of the overall CPQ_{11-14} score and domain scores between pairs of groups of individuals with different degrees of malocclusion*

	Comparison DAI ≤ 25 x DAI= 26 – 30 *p* value*	Comparison DAI ≤ 25 x DAI ≥ 31 *p* value*	Comparison DAI = 26 – 30 x DAI ≥ 31 *p* value*
oral symptoms	0.999	0.999	0.999
functional limitations	0.715	0.628	0.999
emotional well-being	0.999	**0.001**	0.021
social well-being	0.999	**0.027**	0.169
overall score	0.752	**0.015**	0.398

*Note: *Multiple comparison post hoc test. Significance level set at p < 0.05. Bold means statistical significance. DAI ≤ 25: no or slight malocclusion, DAI = 26 – 30: defined malocclusion, DAI ≥ 31: severe malocclusion.*

***Table 3**: Univariate and multivariate analysis evaluating the association of malocclusion and the overall CPQ_{11-14} score*

	High Impact N (%)	Low Impact N (%)	Univariate Analysis OR (95% CI)	*p* value*	Multivariate Analysis OR (95% CI)	*p* value**
Gender						
Male	21 (38.2)	31 (50.0)	1	0.199	1	0.144
Female	34 (61.8)	31 (50.0)	1.61 (0.77 – 3.38)		1.76 (0.82 – 3.78)	
Age						
11 years	26 (47.3)	32 (51.6)	1	0.639	—	—
12 years	29 (52.7)	30 (48.4)	1.18 (0.57 – 2.46)			
Household Income						
≤ 3 MMWs	41 (74.5)	46 (74.2)	1.1 (0.44 – 2.30)	0.965	—	—
> 3 MMWs	14 (25.5)	16 (25.8)	1			
Orthodontic Need - (DAI)						
≤ 25	14 (25.5)	26 (41.9)	1		1	
26 - 30	16 (29.1)	17 (27.4)	1.39 (0.56 – 3.46)	0.469	1.54 (0.61 – 3.89)	0.359
≤ 31	25 (45.5)	19 (30.6)	2.44 (1.01 – 5.91)	0.047	2.63 (1.07 – 6.45)	**0.035**

*Note: N=number; OR=odds ratio; CI=confidence interval. *Values of p < 0.20 were incorporated into the multivariate analysis; **Statistical significance set at p < 0.05. Bold means statistical significance in the multivariate analysis. DAI ≤ 25: no or slight malocclusion, DAI = 26 – 30: defined malocclusion, DAI ≥ 31: severe malocclusion*

the emotional well-being (p=0.001), social well-being (p=0.024) and in the overall CPQ_{11-14} score (p=0.020) (Table 1). Individuals with severe malocclusion (DAI ≥ 31) presented significantly higher scores than those with no or slight malocclusion (DAI ≤ 25) for the emotional well-being (p=0.001), social well-being (p=0.027) and for the overall CPQ_{11-14} score (p=0.015). Individuals with severe (DAI ≥ 31) also presented significantly higher scores than those with defined malocclusion (DAI = 26 – 31) for the emotional well-being (p=0.021) (Table 2).

Table 3 shows the results of the univariate and the multivariate logistic regression. The confounding variable sex had a p<0.20 in the association with the dependent variable adolescents' overall CPQ_{11-14} score and was incorporated along with the independent variable malocclusion into the multivariate analysis. In the multivariate analysis, adolescents with severe malocclusion (DAI ≥ 31) showed a 2.63 greater chance of presenting a high negative impact on OHRQoL than their peers with no or slight malocclusion (DAI ≤ 25) regardless of the confounding variables (CI=1.07 – 6.45, p=0.035).

The sample power calculation was carried out using the Power and Sample Size Calculation Program (PS, version 3.0, Nashville, TN, USA). The study was conducted with 55 adolescents with high impact on OHRQoL and 62 adolescents with low impact on OHRQoL. The difference regarding the overall CPQ_{11-14} score between groups was 11.06. The pooled standard deviation was 7.73. Taking into account the type I error of 0.05, the null hypothesis has been rejected with a power of 95%.

DISCUSSION

The aim of this study was to assess the impact of severe malocclusion on adolescents' quality of life. The null hypothesis that severe malocclusion has no impact on adolescents' ORHQoL has been rejected. Our findings showed that adolescents with severe malocclusion presented a greater negative impact on their quality of life than adolescents with no or slight malocclusion. The major repercussions of this adverse effect were upon individuals' emotional well-being and the social well-being. No significant impact on the oral symptoms and functional limitations domains was observed. Usually, deterioration of symptoms and functional limetations is associated with dental caries.[4]

Adolescence is a transitional phase during which individuals develop their identity and person's individuality as well as begin to have opinions, values and beliefs. At this stage of life, the individual seeks to interact well with peers in groups of friends and, ultimately, be widely recognized by his/her colleagues. Thus, adolescents are extremely concerned about their appearance and the aesthetics of the body itself.[14] Highly exacerbated dentofacial changes, such as severe malocclusion, have an adverse effect on a young individual's emotional well-being[15] because they can cause discomfort for the affected individual, who feels embarrassed in front of his/her colleagues or even afraid of being harassed for having unattractive facial features. In this regard, very exaggerated discrepancies may impair the acceptance of an adolescent by his/her peers,[16] which, in turn, will jeopardize the establishment of interpersonal relationships, negatively affecting the individual's social well-being repercussions on young individual's psychological state and on his/her emotional well-being may also take place.[17]

For instance, among individuals with excessive maxillary growth and/or mandibular deficiency and among those with exaggerated pro-inclination of upper incisors, some studies have shown that the presence of the occlusal discrepancy may increase the risk of teasing by colleagues. In more severe situations, these provocations may evolve into verbal abuse and even physical aggression, which has been acknowledged in the literature as bullying.[18] An adolescent, who is a victim of bullying tends to isolate himself/herself and to avoid having close ties with individuals at the same age. In some extreme cases, the school performance of the young individual may be impaired and this individual may engage in isolation.[19] These negative changes in the emotional state may perpetuate during adulthood, making this adolescent a low self-esteem individual.[20]

The results of this study are important for the clinical practice of the health care provider and for the organization of public health services as a whole. Aware that dentofacial changes may be associated with psychosocial well-being impairment, the dentist in primary care should be concerned in counseling the young individual and his/her parents/caregivers regarding the negative impact that severe occlusal alterations may have on his/her quality of life[21] and the repercussions of malocclusion on the long-term.[22] The clinician should also emphasize the functional and psychosocial benefits of orthodontic treatment and the importance of the young individual undergoes treatment for the correction of malocclusion as early as in the adolescence.[23] The pediatrician, the family physician or the physician in primary care can also have the benefit of the information presented herein. During the physical examination, an uncomplicated assessment of the adolescent may allow the pediatric provider to identify craniofacial issues. Awareness of the psychosocial impairment that occlusal changes may cause to an adolescent will assist the provider in the anticipatory guidance and health education of the young individual and his/her parents/caregivers. The health care provider should be able to recognize malocclusion and to refer the adolescent to the orthodontist, strengthening his/her (of the provider)

advocacy that interceptive and comprehensive orthodontic treatment should take place as early as possible.[24] The dentist in the oral health service, where orthodontic treatment is provided should be concerned in providing counseling for individuals with more severe malocclusion, because the aesthetic impairment and the deterioration of their emotional and social well-beings and their overall quality of life.[25] Thus, the individual with a severe occlusal discrepancy should be under surveillance during the time he/she is waiting for because severe malocclusion may have not only functional repercussions,[26] but also because it implies in psychosocial damage to the adolescent.[27]

Quality of life research provides a comprehensive and data-guided attempt to assess health care routine procedures upon the non-biological and qualitative elements of the impact of oral outcomes, such as malocclusion on individuals' lives. Interdisciplinary quality of life research builds data and provides valuable insight into issues that are related, not only to that specific individual in the circumstances of oriented policies for clinical management, but that can be generalized to the entire population by means of an epidemiological outlook. When data on epidemiology and assessments of quality of life among the prospective recipients of care guide health care policies, ameliorated pathways to the management of health services may become feasible.[28] Public health strategies based on massive information, adequate rapport between the provider, the adolescent and his/her guardians regarding the adverse consequences of malocclusion over the adolescents' well-being, the anticipated referral of the patient and the adoption of preventive measures, to avoid severe occlusal discrepancies should be a priority in the public health system, rather than the delayed supply of therapy targeting malocclusion at a later moment, when the psychosocial consequences of severe malocclusion over the young individual may have already taken place.[29]

Another barrier to adopt epidemiological data, such as data on quality of life to drive public health regards the institutionalized culture that relies on technology and sophisticated treatment modalities as the most appropriate determinant to deal with health issues. In the case of Dentistry and its allied subspecialties, such as Orthodontics the confidence in technology (complex therapeutic techniques and highly advanced diagnostic resources) needs to be mitigated, as public health services must be in motion towards less costly and uncomplicated health care alternatives, providing appropriate counseling about the negative effects of malocclusion and guaranteeing preventive measures to deal with occlusal and skeletal alterations to as many users as possible and as timely as feasible.[30] In this regard, public health policies should be tailored for the appropriate information of the individual regarding malocclusion itself and the repercussions of this outcome on his/her quality of life, appealing to the adolescent and his/her parents/caregivers that they should take part in the process of clinical decision-making, as malocclusion has adverse implications for the young patient and his/her family. The literature urges that healthcare services encourage communication among the provider, the patient and his/her guardians. If it happens otherwise, with epidemiology[28] and the concept of quality of life[30] failing to orient public health initiatives, health care expenditures will rise and public health services may suffer unprecedented challenges.

For further research, more in-depth studies on malocclusion among adolescents and its association with bullying are suggested, since few publications on this topic have been found in the literature. In addition, the benefits of orthodontic treatment could also be evaluated. So could the likelihood of the provision of this type of treatment in reducing episodes of teasing or even bullying among adolescent individuals.[18] Applied research on the qualitative effect of therapies may also assist in the assessment of the amount of resources spent by healthcare systems at different phases of the condition treated. The components in the development and application of health care knowledge and interventions could be improved by quality of life research, including laboratory research and basic science, clinical research and procedures, training of health care providers and adequate practice of public health.[30]

CONCLUSION

Severe malocclusion negatively impacts adolescents' quality of life. Significant repercussions take place on individuals' emotional and social well-being.

ACKNOWLEDGEMENTS

Support from FAPEMIG, CAPES, CNPq and Pro Reitoria de Pesquisa da Universidade Federal de Minas Gerais (PRPq/UFMG) is sincerely recognized.

REFERENCES

1. Sischo L, Broder HL. Oral health-related quality of life: what, why, how, and future implications. *J Dent Res*. 2011;90(11):1264-1270.
2. Gilchrist F, Rodd H, Deery C, Marshman Z. Assessment of the quality of measures of child oral health-related quality of life. *BMC Oral Health*. 2014;14:40.
3. Bendo CB, Paiva SM, Abreu MH, Figueiredo LD, Vale MP. Impact of traumatic dental injuries among adolescents on family's quality of life: a population-based study. *Int J Paediatr Dent*. 2014;24(5):387-396.

4-Martins MT, Sardenberg F, Bendo CB, Abreu MH, Vale MP, Paiva SM, et al. Dental caries remains as the main oral condition with the greatest impact on children's quality of life. *PLoS One*. 2017;12(10):e0185365.

5-Alsumait A, ElSalhy M, Raine K, Cor K, Gokiert R, Al-Mutawa S, et al. Impact of dental health on children's oral health-related quality of life: a cross-sectional study. *Health Qual Life Outcomes*. 2015;13:98.

6. Abreu LG, Melgaço CA, Bastos Lages EM, Paiva SM. Agreement between adolescents and parents/caregivers in rating the impact of malocclusion on adolescents' quality of life. *Angle Orthod*. 2015;85(5):806-811.

7. Jokovic A, Locker D, Guyatt G. Short forms of the Child Perceptions Questionnaire for 11-14-year-old children (CPQ11-14): development and initial evaluation. *Health Qual Life Outcomes*. 2006;4:4.

8. World Health Organization. Oral Health Surveys: Basic Methods. 4th ed. Geneva: World Health Organization; 1997.

9. Andreasen JO, Andreasen FM, Andersson L. Textbook and Color Atlas of Traumatic Injuries to the Teeth. 4th ed. Copenhagen: Munskgaard; 2007.

10. Löe H. The gingival index, the plaque index and the retention index systems. *J Periodontol*. 1967;38(6 Suppl):610-616.

11. Torres CS, Paiva SM, Vale MP, et al. Psychometric properties of the Brazilian version of the Child Perceptions Questionnaire (CPQ11-14) - short forms. *Health Qual Life Outcomes*. 2009;7:43.

12. Lau AW, Wong MC, Lam KF, McGrath C. Confirmatory factor analysis on the health domains of the Child Perceptions Questionnaire. *Community Dent Oral Epidemiol.* 2009;37(2):163-170.

13. Jenny J, Cons NC. Establishing malocclusion severity levels on the Dental Aesthetic Index (DAI) scale. *Aust Dent J*. 1996;41(1):43-46.

14. Sebastian C, Burnett S, Blakemore SJ. Development of the self-concept during adolescence. *Trends Cogn Sci*. 2008;12(11):441-446.

15. Bittencourt JM, Martins LP1, Bendo CB1, Vale MP1, Paiva SM1. Negative effect of malocclusion on the emotional and social well-being of Brazilian adolescents: a population-based study. *Eur J Orthod.* 2017;39(6):628-633.

16-. inn EL. Social meanings of dental appearance. *J Health Hum Behav*. 1966;7(4):289-295.

17. Agou S, Locker D, Muirhead V, Tompson B, Streiner DL. Does psychological well-being influence oral-health-related quality of life reports in children receiving orthodontic treatment? *Am J Orthod Dentofacial Orthop*. 2011;139(3):369-77.

18. Seehra J, Newton JT, Dibiase AT. Interceptive orthodontic treatment in bullied adolescents and its impact on self-esteem and oral-health-related quality of life. *Eur J Orthod*.2013;35(5):615-621.

19. Due P, Holstein BE, Lynch J, Diderichsen F, Gabhain SN, Scheidt P, et al. Health Behaviour in School-Aged Children Bullying Working Group. *Eur J Public Health*. 2005;15(2):128-132.

20. Bond L, Carlin JB, Thomas L, Rubin K, Patton G. Does bullying cause emotional problems? A prospective study of young teenagers. *BMJ*. 2001;323(7311):480-484.

21. Phillips C, Beal KN. Self-concept and the perception of facial appearance in children and adolescents seeking orthodontic treatment. *Angle Orthod*. 2009;79(1):12-16.

22. Lyznicki JM, McCaffree MA, Robinowitz CB. Childhood bullying: implications for pshycians. *Am Fam Physician.* 2004;70(9):1723-1728.

23. Abreu LG, Melgaço CA, Lages EM, Abreu MH, Paiva SM. Effect of year one orthodontic treatment on the quality of life of adolescents, assessed by the short form of the Child Perceptions Questionnaire. *Eur Arch Paediatr Dent*. 2014;15(6):435-441.

24. Lewis CW, Grossman DC, Domoto PK, et al. The role of the pediatrician in the oral health of children: a national survey. *Acad Pediatr*. 2000;106:E84.

25. Abreu LG, Melgaço CA, Abreu MH, Lages EM, Paiva SM. Perception of parents and caregivers regarding the impact of malocclusion on adolescents' quality of life: a cross-sectional study. *Dental Press J Orthod*. 2016;21(6):74-81.

26. Crabb JJ, Rock WP. Orthodontic screening of nine-year-old children. *Br J Orthod*. 1986;13(1):43-47.

27. Abreu LG, Melgaço CA, Bastos Lages EM, Paiva SM. Impacto of malocclusion on adolescents' oral health-related quality of life. *Gen Dent*. 2016;64(6):1-5.

28. McGrath C, Broder H, Wilson-Genderson M. Assessing the impact of oral health on the life quality of children: implications for research and practice. *Community Dent Oral Epidemiol*. 2004;32(2):81-85.

29. Shan ND, Arruda A, Inglehart MR. Pediatric patients' orthodontic treatment need, quality of life, and smiling patterns – an analysis of patient, parent, and provider responses. *J Public Health Dent*. 2011;71(1):62-70.

30. Gellert GA. The importance of quality of life research for health care reform in the USA and the future of public health. *Qual Life Res*. 1993;2(5):357-362.

ORAL HEALTH-RELATED QUALITY OF LIFE OF 8-10 YEAR-OLD CHILDREN WITH TRAUMATIC DENTAL INJURY

Lívia Azeredo Alves **Antunes**[1,2,3*], Eluza **Piassi**[2], Ana Júlia **Milani**[3], Leonardo dos Santos **Antunes**[1,2], Ronir Raggio **Luiz**[4], Anna Thereza Thomé **Leão**[5], Lucianne Cople **Maia**[6]

[1]Department of Specific Formation, School of Dentistry, Health Institute of Nova Friburgo, Universidade Federal Fluminense, Nova Friburgo, RJ, Brazil.
[2] Posgraduate Program in Dentistry, School of Dentistry, Fluminense Federal University, Niterói, Rio de Janeiro, RJ, Brazil.
[3] Posgraduate Program in Dentistry, School of Dentistry, Fluminense Federal University, Nova Friburgo, Rio de Janeiro, Brazil.
[4] Institute of Public Health Studies, Federal University of Rio de Janeiro, Rio de Janeiro, RJ, Brazil.
[5] Department of Dental Clinics, School of Dentistry, Rio de Janeiro Federal University, Rio de Janeiro, RJ, Brazil.
[6] Department of Pediatric Dentistry and Orthodontics, School of Dentistry, Rio de Janeiro Federal University, Rio de Janeiro, RJ, Brazil.

Palavras-chave: Saúde Bucal. Qualidade de Vida. Criança. Traumatismo Dentário.

RESUMO

Introdução: Crianças apresentam alta prevalência de traumatismo dentário (TD). **Objetivo:** Detectar o impacto do TD na qualidade de vida relacionada à saúde bucal (QVRSB) nessa faixa etária. **Métodos:** Um estudo transversal foi realizado com amostra de conveniência recrutando-se crianças de 8-10 anos com TD em dente permanente por um período de 18 meses em clínica pública. Dados sobre a QVRSB foram coletados através da versão brasileira do CPQ_{8-10} ($B\text{-}CPQ_{8-10}$). O TD foi classificado de acordo com os critérios de Andreasen e agrupado de acordo com sua gravidade. As variações nos escores e o impacto do TD na QVRSB, de acordo com idade, gênero e gravidade do TD foram examinados por meio de testes estatísticos não paramétricos (teste de Kruskall-Wallis e Mann-Whitney, $p < 0,05$). **Resultados:** De uma amostra de 255 crianças, 41 crianças saudáveis que sofreram TD em dentes permanentes foram incluídas no estudo. O escore médio do $B\text{-}CPQ_{8-10}$ foi 29,7 (DP 14,3). Os domínios bem-estar emocional e social apresentaram maior impacto negativo com média de 8,8 (DP 5,9) e 9,8 (DP 6,3), respectivamente. A diferença de gênero e a gravidade do TD não apresentaram relação de impacto na QVRSB. Em relação a idade, crianças de 10 anos tiveram maior impacto na escala global da QVRSB ($p < 0,05$) e na subescala de limitação funcional ($p < 0,05$). **Conclusão:** O TD impacta negativamente a QVRSB de crianças de 8 a 10 anos de idade.

Keywords: Oral Health. Quality of Life. Child. Tooth Injuries.

ABSTRACT

Introduction: Children presents high prevalence of traumatic dental injury (TDI). **Objective:** It is very important to detect the impact on oral health related to quality of life (OHRQoL) in this age group. **Methods:** Based on this, a cross sectional study was carried out using a convenience sample. Children from 8-10 years with TDI in permanent teeth were recruited over an 18 month period, from a public University. Data about OHRQoL using the Brazilian version of CPQ_{8-10} ($B\text{-}CPQ_{8-10}$) were collected. TDI were classified according to Andreasen criteria and grouped according to its severity. Variations in the scores and impact of TDI on OHRQoL according to age, gender and TDI severity were examined using nonparametric statistical tests (Kruskall-Wallis and Mann-Whitney test, $p<0.05$). **Results:** From a sample of 255 children, 41 healthy children that suffered TDI in permanent were included in the study. The mean $B\text{-}CPQ_{8-10}$ scores were 29.7 (SD 14.3). Emotional and social wellbeing domais had the highest negative score impact average 8.8 (SD 5.9) and 9.8 (SD 6.3), respectively. Gender or TDI severity did not present relation to impact on OHRQoL. In relation to age, 10-year-old children had more impact on their OHRQoL on the overall scale ($p<0.05$) and for the functional limitation subscale ($p<0.05$). **Conclusion:** TDI impacts negatively on OHRQoL of children aged from 8-10 years old.

Submitted: March 5, 2019
Modification: April 17, 2019
Accepted: April 25, 2019

***Correspondence to:**
Lívia Azeredo Alves Antunes
Address: Rua Doutor Silvio Henrique Braune, 22 – Centro, Nova Friburgo – RJ, Brazil. Zip code: 28625-650
Telephone number: + 55 (22) 25287168
E-mail: liviaazeredo@gmail.com

INTRODUCTION

Traumatic dental injury (TDI) represents an acute transmission of energy to the tooth and supporting structures, which results in fracture and/or displacement of the tooth and/ or separation or crushing of the supporting tissues or tooth loss. These sequels are not associated only with biological factors, they are also associated with socio-economic conditions, psychological and behavioral factors[1] which can significantly affect the quality of life of parents and child alike[2,3]. Questionnaires designed to assess the impact of oral health related to quality of life (OHRQoL) have various interesting and important uses including research, and policies for public health clinics.[4]

According to WHO, TDIs are a public health problem.[5] The prevalence of TDI in Brazilian schoolchildren is high.[6] However, there are many studies that exist already documenting quality of life and impacts experienced by children with various dental problems, but reports of the TDI impact on quality of life in children aged from 8 to 10 years old are scarce.[2,7]

The Child Perceptions Questionnaires (CPQs) are a group of questionnaires developed to measure the functional and psychosocial outcomes of orofacial condition. The CPQs have been translated into several languages including Portuguese.[8-10] Each CPQ has been developed to measure children's perceptions regarding the impact of oral health on their quality of life (QoL) in terms of their cognitive, emotional and social feelings. The age is a key factor when choosing among the four recommended instruments for schoolchildren and adolescents.[11] The CPQ_{8-10} has been shown to be an appropriate index for children aged from 8 to 10 years old.[12] In the literature, there is no specific instrument for assessing TDI[13] and therefore instruments already tested to assess the QHRQoL of children should be used.

Therefore, the aim of this study is to assess the impact of traumatic dental injury on oral health related to the quality of life of children aged 8-10 years old.

MATERIALS AND METHODS

Ethical approval was obtained from the local Human Ethics Committee (Protocol n. 824/09). Informed consent was obtained from all parents/legal guardians.

Type of Study and sampling

This crossectional study was composed by a convenience sample of children, aged from 8 to 10 years old. All children those search for treatment was recruited over an 18-month period (2011-2012) from a dental trauma center in a Public University in Rio de Janeiro-Brazil.

We included children that suffered TDI in permanent teeth until four weeks before the questionnaire application Children that did not who speak ûuent Brazilian Portuguese, with dental caries, malocclusions, undergoing orthodontic treatment, children with special needs (i.e. motor and mental disabilities or some type of syndrome) or with systemic disease were excluded.

Data collection

1) Non clinical data

The following data were obtained: child's age and gender; TDI history (when, where, and how the trauma occurred; which tooth and dentition were affected; tissue affected and type of the more prevalent TDI).

OHRQoL was measured using the Brazilian version of the CPQ_{8-10} which has 25 items distributed into 4 health domains (subscales): oral symptoms -OS (five items); functional limitations -FM (five items); emotional well-being -EWB (five items); and social well-being-SWB (10 items). The items addressed the frequency of events over the 4 previous weeks. The items have five response options: 'never = 0', 'once or twice =1', 'sometimes = 2', 'often = 3', 'every day or almost every day = 4'. CPQ_{8-10} scores are calculated by summing all the item scores, giving a total score ranging from 0 (no impact) to 100 (maximal impact); higher scores indicate that the oral conditions have a greater negative impact on the child's OHRQoL. The questionnaire also contains two questions on the child's personal information (gender and age) and two global indicators concerning the child's oral health and the extent to which his/her orofacial condition affects his/her overall wellbeing.[10]

Before apply the OHRQoL questionaire a pretest study was conducted to detect reliability of the questionnaire in the population that we pretended to use and to detect the necessity to remove some question. A new convenience sample (not part of the study population) of parents/ caregivers and their children was recruited. The test-retest reliability analysis requires individuals' conditions remain stable between the two administrations of the questionnaire. The second questionnaire application, two weeks later, was done after asking parents/caregivers if the child's condition had no change since recruitment. All children answered the questionnaire by interview.

2) Clinical data (TDI diagnostic and severity)

The child's oral examination was by carried out by two previously calibrated examiners (LAA and EP). The

Table 1: *Mean, standard deviation and median of B-CPQ$_{8-10}$ scores, according to type of TDI and its severity*

Type of TDI (n=41)	TDI Severity	B-CPQ8-10 Overall Scores		B-CPQ8-10 Domain Scores							
				Oral Symptoms		Functional Limitations		Emotional Well-being		Social Well-being	
		Mean (SD)	Median	Mean (SD)	Median	Mean (SD)	Median	Mean (SD)	Median	Mean (SD)	Median
Support tissue injury without dislocation (n=1)	UC	12.0 (-)	12.0	4.0 (-)	4.0	6.0 (-)	6.0	0	0.0	2.0 (-)	2.0
Support tissue injury without dislocation (n=7)	C	30.2 (18.7)	22.0	4.5 (2.9)	3.0	7.1 (3.8)	6.0	9.0 (6.92)	10.0	9.5 (8.3)	7.0
Fracture without pulp exposure (n=20)	UC	31.3 (13.0)	33.5	5.2 (3.2)	5.0	6.0 (3.7)	6.0	10.4 (5.6)	12.5	9.7 (6.0)	10.0
Fracture with pulp exposure (n=1)	C	18.0 (-)	18.0	0	0.0	0	0.0	15.0 (-)	15.0	3.0 (-)	3.0
Support tissue injury without dislocation / Fracture without pulp exposure (n=5)	UC	28.0 (18.1)	26.0	4.0 (3.2)	4.0	5.8 (6.0)	4.0	7.2 (5.8)	10.0	10.6(6.4)	10.0
Support tissue injury with dislocation / Fracture without pulp exposure (n=7)	C	30.2 (13.0)	27.0	4.5 (3.6)	3.0	7.4 (3.9)	6.0	6.0 (5.1)	4.0	12.2 (5.0)	12.0

Note: UC=uncomplicated; C= complicated. Support tissue injury without dislocation (concussion and subluxation); Support tissue injury with dislocation (lateral luxation, intruse luxation, extrusive luxation and avulsion).

training exercise for TDI was performed using images of different clinical situations and the calibration was carried out with an oral examination of 20 children (not part of this study) on two separate occasions, with a 2-week interval between sessions. Intra- and inter-examiner reliability was assessed by kappa statistics. Intra- and inter-examiner results were between good to excellent; weighted kappa scores were between 0.66 and 1.00 for intra-examiner reliability (0.68-0.89 for support tissue; 0.66-1.00 for dental tissue) and between 0.77 and 0.89 for inter-examiner reliability (0.84-0.89 for support tissue; 0.77-0.88 for dental tissue).

The TDI classification/diagnostic was carried out following Andreasen's criteria as described by Jesus *et al*.[6] The clinical data were collected in dental equipment. Biosafety standards were obeyed.

The extent of TDI was classified into levels of severity according to Glendor *et al*.[14] as 'uncomplicated' (those in which the pulpal tissue was not exposed and the tooth was not dislocated) or 'complicated' (those involving exposure of the pulpal tissue and/or tooth dislocation). One or more diagnoses could be included, the classification on the individual level being determined by the most complicated diagnosis.

Data management and statistical analysis

Statistical analysis was performed using the Statistical Package for Social Sciences (version 16.0; SPSS Inc., Chicago, IL, USA). The level of statistical significance was set at $p < 0.05$.

The socio-dental indicator psychometric properties were assessed through internal consistency and test-retest reliability. Internal consistency reliability was assessed by means of Cronbach's Alpha and test-retest reliability by means of the intraclass correlation coefficient (ICC). The construct validity was evaluated by means of associations between scale scores and the two global indicators of health status (general and oral) and well-being (the impact of dental trauma) using Spearman rank correlation coefficient.

The Kolmogorov-Smirnov test was used in order to check distribution of the values. It was observed that the values did not had normal distribution and non-parametric statistical procedures were used. Means and medians were obtained for items overall and subscale scores.

Variations in the scores and impact of TDI on OHRQoL according to age and gender and TDI severity were examined using statistical tests (Kruskall-Wallis and Mann-Whitney test).

***Table 2**: B-CPQ$_{8-10}$ scores by categories of clinical data.*

	B-CPQ8-10 Overall Scores			B-CPQ8-10 Domain Scores											
				Oral Symptoms			Functional Limitations			Emotional Well-being			Social Well-being		
	Mean(SD)	Median	p-value	Mean (SD)	Median	p-value	Mean (SD)	Median	p-value	Mean (SD)	Median	p-value	Mean (SD)	Median	p-value
Gender*															
Male(n=23)	27.0(12.9)	26.0	ns	4.5(3.1)	4.0	ns	5.47(3.78)	5.0	ns	7.9(5.6)	7.0	ns	9.1(4.7)	10.0	ns
Female (n=18)	33.1(15.5)	34.5		4.9(3.2)	4.5		7.27 (4.26)	7.5		10.1(6.1)	11.5		10.8(7.9)	10.5	
Age**															
8 years (n=11)	25.4(16.7)	23.0	p<0.05	3.6(2.2)	4.0	ns	4.9(3.7)	4.0	p<0.05	9.0(6.8)	10.0	ns	7.8(7.3)	5.0	ns
9 years (n=16)	25.2(10.2)	24.0		4.7(3.2)	4.0		4.3(2.9)	4.0		7.4(5.8)	4.5		8.6(4.9)	9.0	
10 years (n=14)	38.2(13.2)	39.0		5.5(3.5)	4.5		9.5(3.5)	10.0		10.3(5.2)	11.0		12.8(6.1)	13.0	
TDI severity*															
C (n=15)	29.4(15.2)	22.0	ns	4.2(3.3)	3.0	ns	6.8(4.0)	6.0	ns	6.8(4.0)	6.0	ns	10.4(6.8)	11.0	0.7
UC (n=26)	29.9(14.0)	33.0		5.0(3.1)	4.5		5.9(4.0)	5.5		9.3 (5.8)	10.5		9.5(6.0)	10.0	

Note: C = complicated UC= uncomplicated

RESULTS

From a sample of 255 children, 41 children that suffered TDI in permanent teeth until four weeks before the questionnaire application achieved the elegibilty criteria and presented from 8 to 10 years were included. The reasons for loss of sample were due to the specific elegibility criteria designed.

The B-CPQ$_{8-10}$ psychometric properties for this population reported a satisfactory reliability with 0.82 for Cronbach's alpha. The test-retest reliability was satisfactory (ICC 0.98). When the scores of the B-CPQ8-10 were correlated to global indicators there was no statistical relationship to oral and general health. The TDI well-being showed satisfactory construct validity evaluated by means Spearman correlation for the total scale (rho: 0.58, $p < 0.01$) and for subscales ($p< 0.01$; rhoOS: 0,40; rhoFF: 0.53; rhoEWB: 0.40; rhoSWB: 0.57).

The mean B-CPQ$_{8-10}$ scores were 29.7 (SD 14.3), while the median scores were 30.0. When the subscales (OS, FL, EWB, SWB) were analyzed in the present study, EWB and SWB had the highest score impact: mean 8.8 (SD 5.9) median 9.0 and mean 9.8 (SD 6.3) median 10.0, respectively. OS presented mean 4.7 (SD3.1) and 4.0 median. FL presented mean 6.2 (SD 4.0) and median 6.0.

Table I shows the mean B-CPQ$_{8-10}$ scores (overall and domains) according to type of TDI and its severity. Variations in the scores and impact of TDI on OHRQoL according to age, gender and TDI severity were analyzed (Table II). There was no statistical significance for gender and type of TDI severity. In relation to the age there was statistical significance. The children aged 10 years had more impact on their ORHQoL on overall scale ($p<0.05$) and for the functional limitation subscale ($p<0.05$).

DISCUSSION

Dental trauma has epidemiological importance in the context of public health, since it occurs in 2 out of every 3 children before adulthood. However, the publication about TDI theme is less than 1% which is completely out of proportion to the size of the problem.[15] According to Antunes *et al*.,[13] the number of papers that evaluate the impact of dental trauma in pediatric patients is even much lower. A better understanding and detection of the impact of dental trauma on children's OHRQoL for different age groups (with different cognitive behaviors) is of paramount importance and is needed to develop measures that address not only preventive actions and how to deal with them, but also to emphasize the psychological care and social impact caused to the parents, family and the child.

The CPQ$_{8-10}$ instrument[8] used in this study has been validated in Portuguese[7] and in other languages.[16-18] It is a descriptive measure able to discriminate between groups with different levels of oral health problems. Instruments for specific conditions, symptoms, or treatments need further research on metric properties.[11] This study confirmed the validity and the reliability of this instrument. Thus it corroborates the aforementioned works and supports the Brazilian version of CPQ$_{8-10}$ and the scores that are shown to be satisfactory to detect the impact on OHRQoL in populations with TDI. Consequently, we suggest the use of this instrument on other Brazilian children with TDI to detect the impact of this injury on their OHRQoL.

The studies dealing with CPQ$_{8-10}$ instruments are applied on validation studies [10,12,16-19] or studies about: specific oral conditions (dental caries, fluorosis; malocclusion; temporomandibular; oral habits); disorder or disorders such as cleft lip/cleft palate; or in a group of childhood cancer survivors[20-27] ; and also in a population that has suffered dental trauma.[2,7,28,29]

In the present study, TDI has a significant impact on child's OHRQoL, which was supported by previous studies.[2,7] Schuch *et al*.[7] observed that children aged from 8 to 10 years old with TDI had significantly more negative impact on their OHRQoL than those without TDI. In our study, the overall score of the CPQ$_{8-10}$ (29.7) was similar to findings in previous study (31.2),[2] but higher than found by Schuch's *et al*. study (16.8).[7] A possible explanation would be that our study and Berger's *et al*. study[2] were performed at a dental trauma reference center and Schuch's *et al*. study[7] was at schools.

Identifying the factors that affect the OHRQoL of a population, allows clinicians to prioritize action and interventions as soon as possible. It also allows not only to act on the disease, but also on the psychosocial aspect that the affection of the mouth may be causing. Thus, the present study becomes extremely relevant in the evaluation of the negative impact of TD in the OHRQoL of young children and their families, supporting pediatric dentistry and health professionals in the planning and decision making process

Comparing the scores of children with TDI with children with other dental conditions that were obtained from other studies using CPQ$_{8-10.}$ [10,12,16-23] we observed that trauma had a greater impact on OHRQoL: our study (overall score 29.7), Berger's *et al*.study[2] (overall score 31.2), as well as Schuch's *et al*. study[7] (overall score 16.8). These scores are just below the scores for some oral conditions in Barbosa's *et al*. study.[22] However, these findings demonstrate that dental trauma is one of the oral conditions that generate the worst impact on OHRQoL, so it deserves more attention from the clinician when it happens[3].

As in previous TDI studies, using other QoL instruments, we could detect the impact of TDI on children's OHRQoL.[2,3,30-34] We opted to analyses by gender and age to confirm the hypothesis that women complain more than men; as well to detect the variability of perceptions by the age. This study found that the interference of TDI on the OHRQoL of children aged from 8 to 10 years of age mainly affected the emotional (EWB) and social (SWB) relations. In this study the TDI had a greater impact on the OHRQoL of 10-year-old children; however this was not affected by gender or TDI severity.

Regardless of the fact that the severity of child TDI shows a high impact on OHRQoL, the absence of statistical significance may be justified because the majority of the population studied showed fractures of enamel or enamel / dentin (52.2%). These injuries are not considered complicated; however, they present significant interference with the aesthetic dentofacial and contribute to affect the children's emotional and social relationships.

Considering the sample size, we opted to take a consecutive sample over a set period (18 months) at a dental trauma and pediatric center. This study consisted of a sample of convenience, as characterized by there is a concern with the design of a particular sampling plan. Considering the potential selection bias, the purpose was not to generalize findings. So we aimed to describe the main characteristics of the study group. To solve this limitation we agree that larger, population-based studies on representative groups of children should be needed to confirm or refute our findings.

Generalizing our results, which confirm that the trauma affects the quality of life for children aged 8 to 10 years, it is not enough to treat their physical signs and symptoms. We should also consider issues beyond oral symptoms, functional limitations and especially the emotional and social well-being factors. According to Schuch *et al*.[7] the effect of behavioral and psychosocial characteristics on oral health perception should be taken into consideration. Thus the applicability of this study is to extrapolate the results to the population studied in order to generate the development of health strategies to include not only the clinical treatment of traumatic injuries, but with a holistic view of the patient's treatment plan covering the psychosocial context. The results also confirm that the B-CPQ$_{8-10}$ can be used on Brazilian populations with TDI and that the score impact detected in the present study can be used to compare with other studies.

CONCLUSION

TDI impacts negatively on the OHRQoL of children aged 8 to 10 years old. The TDI impact was not influenced by gender but 10 year-old children were more affected. The type of TDI severity did not influenced the impact on OHRQoL

Acknowledgements:

We are indebted to Sarah Vinski that revised the text for grammar and style.

REFERENCES

1. Nicolau B, Marcenes W, Sheiham A. The relationship between traumatic dental injuries and adolescents' development along the life course. Community Dent Oral Epidemiol. 2003 Aug;31(4):306-13.

2. Berger TD, Kenny DJ, Casas MJ, Barrett EJ, Lawrence HP. Effects of severe dentoalveolar trauma on the quality-of-life of children and parents. Dent Traumatol. 2009 Oct;25(5):462-9.

3. Antunes LA, Luiz RR, Leao AT, Maia LC. Initial assessment of responsiveness of the P-CPQ (Brazilian Version) to describe the changes in quality of life after treatment for traumatic dental injury. Dent Traumatol. 2012 Aug;28(4):256-262.

4. Jokovic A, Locker D, Stephens M, Kenny D, Tompson B, Guyatt G. Validity and reliability of a questionnaire for measuring child oral-health-related quality of life. J Dent Res. 2002 Jul;81(7):459-63.

5. Petersen PE, Bourgeois D, Ogawa H, Estupinan-Day S, Ndiaye C. The global burden of oral diseases and risks to oral health. Bull World Health Organ. 2005 Sep;83(9):661-9.

6. Jesus MA, Antunes LA, Risso Pde A, Freire MV, Maia LC. Epidemiologic survey of traumatic dental injuries in children seen at the Federal University of Rio de Janeiro, Brazil. Braz Oral Res. 2010 Jan-Mar;24(1):89-94.

7. Schuch HS, Costa FS, Torriani DD, Demarco FF, Goettems ML. Oral health-related quality of life of schoolchildren: impact of clinical and psychosocial variables. Int J Paediatr Dent. 2015 Sep;25(5):358-65.

8. Goursand D, Paiva SM, Zarzar PM, Ramos-Jorge ML, Cornacchia GM, Pordeus IA, et al. Cross-cultural adaptation of the Child Perceptions Questionnaire 11-14 (CPQ11-14) for the Brazilian Portuguese language. Health Qual Life Outcomes. 2008:6:2.

9. Torres CS, Paiva SM, Vale MP, Pordeus IA, Ramos-Jorge ML, Oliveira AC, et al. Psychometric properties of the Brazilian version of the Child Perceptions Questionnaire (CPQ11-14) - short forms. Health Qual Life Outcomes. 2009:7:43.

10. Martins MT, Ferreira FM, Oliveira AC, Paiva SM, Vale MP, Allison PJ, et al. Preliminary validation of the Brazilian version of the Child Perceptions Questionnaire 8-10. Eur J Paediatr Dent. 2009 Sep;10(3):135-40.

11. Zaror C, Pardo Y, Espinoza-Espinoza G, Pont À, Muñoz-Millán P, Martínez-Zapata MJ, Vilagut G, Forero CG, Garin O, Alonso J, Ferrer M. Assessing oral health-related quality of life in children and adolescents: a systematic review and standardized comparison of available instruments. Clin Oral Investig. 2019 Jan;23(1):65-79.

12. Jokovic A, Locker D, Tompson B, Guyatt G. Questionnaire for measuring oral health-related quality of life in eight- to ten-year-old children. Pediatr Dent. 2004 Nov-Dec;26(6):512-8.

13. Antunes LAA, Leão AT, Maia LC. Impacto do traumatismo dentário na qualidade de vida de crianças e adolescentes: revisão crítica e instrumentos de medida. Cienc Saude Colet. 2012 Dec:17(12):3417-24.

14. Glendor U, Halling A, Andersson L, Eilert-Petersson E. Incidence of traumatic tooth injuries in children and adolescents in the county of Vastmanland, Sweden. Swed Dent J. 1996;20(1-2):15-28.

15. Andreasen JO, Lauridsen E, Daugaard-Jensen J. Dental traumatology: an orphan in pediatric dentistry? Pediatr Dent. 2009 Mar-Apr;31(2):153-6.

16. Del Carmen Aguilar-Diaz F, Irigoyen-Camacho ME. Validation of the CPQ8-10ESP in Mexican school children in urban areas. Med Oral Patol Oral Cir Bucal. 2011 May;16(3):e430-5.

17. Humphris G, Freeman R, Gibson B, Simpson K, Whelton H. Oral health-related quality of life for 8-10-year-old children: an assessment of a new measure. Community Dent Oral Epidemiol. 2005 Oct;33(5):326-32.

18. Wogelius P, Gjorup H, Haubek D, Lopez R, Poulsen S. Development of Danish version of child oral-health-related quality of life questionnaires (CPQ8-10 and CPQ11-14). BMC Oral Health. 2009;9:11.

19. Boy-Lefèvre ML, Razanamihaja N, Azogui-Lévy S, Vigneron A, Jordan L, Berdal A, de la Dure-Molla M. Translation and validation of the French version of the Child Perceptions Questionnaire for children aged from 8 to 10 years old (CPQ 8-10). Health Qual Life Outcomes. 2018 May 3;16(1):86.

20. Do LG, Spencer AJ. Evaluation of oral health-related quality of life questionnaires in a general child population. Community Dent Health. 2008 Dec;25(4):205-10.

21. Wogelius P, Rosthoj S, Dahllof G, Poulsen S. Oral health-related quality of life among survivors of childhood cancer. Int J Paediatr Dent. 2011 Nov; 21(6):465-7.

22. Barbosa TS, Leme MS, Castelo PM, Gaviao MB. Evaluating oral health-related quality of life measure for children and preadolescents with temporomandibular disorder. Health Qual Life Outcomes. 2011:9:32.

23. Aguilar-Diaz FC, Irigoyen-Camacho ME, Borges-Yanez SA. Oral-health-related quality of life in schoolchildren in an endemic fluorosis area of Mexico. Qual Life Res. 2011 Dec;20(10):1699-706.

24. Paula JS, Tôrres LHN, Ambrosano GMB, Mialhe FL. Association between oral health-related quality of life and atraumatic restorative treatment in school children: an exploratory study. Indian J Dent Res. 2012 Nov-Dec; 23(6):738-41

25. Barbosa TS, Tureli MCM, Nobre-dos-Santos M, Puppin-Rontani RM, Gavião MBD. The relationship between oral conditions, masticatory performance and oral health-related quality of life in children. Arch Oral Biol. 2013 Sep;58(9):1070-7.

26. Leme MS, Barbosa TS, Gavião MBD. Relationship among oral habits, orofacial function and oral health-related quality of life in children. Braz Oral Res. 2013 May-Jun;27(3):272-8.

27. Shin HS, Han DH, Shin MS, Lee HJ, Kim MS, Kim HD. Korean version of child perceptions questionnaire and dental caries among Korean children. PLoS One. 2015 Feb;10(2):1-13.

28. Magno MB, Jural LA, Nogueira ADV, Lenzi MM, Pithon MM, Maia LC. Impact of crown fracture treatment on oral health-related quality of life of children, adolescents, and their families: A prospective clinical study. Int J Paediatr Dent. 2019 Jan;29(1):86-93.

29. Soares JP, Barasuol JC, Torres FM, Giacomin A, Gonçalves BM, Klein D, Borgatto AF, Ramos-Jorge ML, Cardoso M, Bolan M. The impact of crown fracture in the permanent dentition on children's quality of life. Dent Traumatol. 2018 Jun;34(3):158-163.

30. Cortes MI, Marcenes W, Sheiham A. Impact of traumatic injuries to the permanent teeth on the oral health-related quality of life in 12-14-year-old children. Community Dent Oral Epidemiol. 2002 Jun;30(3):193-8.

31. Ramos-Jorge ML, Bosco VL, Peres MA, Nunes AC. The impact of treatment of dental trauma on the quality of life of adolescents - a case-control study in southern Brazil. Dent Traumatol. 2007 Apr;23(2):114-9.

32. Fakhruddin KS, Lawrence HP, Kenny DJ, Locker D. Impact of treated and untreated dental injuries on the quality of life of Ontario school children. Dent Traumatol. 2008 Jun;24(3):309-13.

33. Bendo CB, Paiva SM, Torres CS, Oliveira AC, Goursand D, Pordeus IA, et al. Association between treated/untreated traumatic dental injuries and impact on quality of life of Brazilian schoolchildren. Health Qual Life Outcomes. 2010;8:114.

34.Porritt JM, Rodd HD, Ruth Baker S. Quality of life impacts following childhood dento-alveolar trauma. Dent Traumatol. 2011 Feb;27(1):2-9.

ORAL HEALTH CONDITION AND INTERPERSONAL RELATIONSHIP OF SCHOLARS OF A PUBLIC INSTITUTION

Maria Cardoso de Castro **Berry**[1], Sylvia **Tristão**[1], Luciana **Pomarico**[1*], Ivete Pomarico Ribeiro de **Souza**[1]

[1]Departamento de Odontopediatria e Ortodontia, Faculdade de Odontologia, Universidade Federal do Rio de Janeiro, RJ, Brazil.

Palavras-chave: Percepção. Saúde Bucal. Criança.

RESUMO

Objetivo: O objetivo desse trabalho foi avaliar a condição de saúde bucal e analisar a autopercepção do impacto da saúde bucal no relacionamento interpessoal de escolares de uma instituição da rede pública municipal do Rio de Janeiro, Brasil. **Método:** A amostra foi do tipo não probabilística, sendo composta por 260 crianças e adolescentes, de 8 a 15 anos. A condição bucal foi verificada através de exame clínico de acordo com os critérios da Organização Mundial da Saúde. A percepção dos escolares em relação a própria condição bucal foi avaliada através de entrevista, cujo instrumento foi desenvolvido a partir da Pesquisa Nacional de Saúde do Escolar, 2012 e do *Child Perception Questionnaire (*CPQ).[11-14] Os testes qui-quadrado e Exato de Fisher foram utilizados com nível de significância de 5% (p<0,05). **Resultados:** 51,5% da amostra apresentou CPOD zero. A análise do questionário mostrou que a maioria está feliz com o próprio sorriso (88,1%). Porém, 35,8% relatou já ter evitado sorrir e 18,5% já deixou de realizar alguma atividade por causa dos dentes. **Conclusão:** Embora a metade dos escolares se apresente livre de cárie e a maioria goste do próprio sorriso, uma parcela considerável demonstra sentimentos como chateação e vergonha, podendo interferir no relacionamento com seus pares.

Keywords: Perception. Oral Health. Child.

ABSTRACT

Objective: The aim of this study was to evaluate the oral health status and to analyze the self-perception of the impact of oral health statuson the interpersonal relationship of students from a local school in Rio de Janeiro, Brazil.

Methods: A non-probabilistic sample was used, consisting of 260 children and adolescents aged 8 to 15 years. Oral health status was evaluated by clinical examination according to the World Health Organization criteria. The perception of the students of their oral health status was assessed by interview using a questionnaire developed from PeNSE (Brazilian National School Health survey) and CPQ[11-14] (Child Perception Questionnaire). Chi-square and Fisher's exact test were used, with level of significance of 5% (p< 0.05). **Results:** A DMFT index equal to 0 was observed in 51.5% of the participants. The questionnaire revealed that most students were happy about their own smile (88.1%). However, 35.8% had already avoided smiling and 18.5% had refrained from some daily activities because of the appearance of their teeth. **Conclusion:** Although half of the students were free of dental caries and most were satisfied with their smile, a sizable number felt upset and embarrassed about their teeth, which may interfere in the relationship with their peers.

Submitted: November 15, 2018
Modification: December 21, 2018
Accepted: January 4 , 2019

***Correspondence to:**
Dra Luciana Pomarico. Departamento de Odontopediatria e Ortodontia - Faculdade de Odontologia da Universidade Federal do Rio de Janeiro. Rua Prof. Rodolpho Paulo Rocco, 325, Cidade Universitária – RJ, Brazil. CEP: 21941-617
Telephone Number: 55 21 3938-2098.
E-mail: lupomarico@gmail.com

INTRODUCTION

Oral health is an integral and essential part of general health and it is influenced by social and behavioral factors, playing a key role in quality of life.[1]

Oral esthetics is closely related to emotional aspects and to some oral problems such as early loss of deciduous teeth, which may have a negative impact on the development of children and adolescents, causing changes in their behavior, such as irritability and low self-esteem.[2] In adolescence, development of social relations is initially associated with

physical attraction, and facial esthetics becomes of further relevance.[3]

Thus, dental problems, like malocclusion, anterior traumatic tooth, tooth loss and untreated decay, can have a direct impact on the development of relationships, on self-esteem, and on quality of life.[3,4,5]

Given the importance of this topic, the aim of this study was to evaluate the oral health status and analyze the self-perception on the impact of oral health on the interpersonal relationship of students from a local public school in Rio de Janeiro.

MATERIALS AND METHODS

Ethical aspects

This study was approved by the Research Ethics Committee of Clementino Fraga Filho Teaching Hospital – UFRJ (process 46637315.4.0000.5257, report no. 1 165.807).

Study design and sample characteristics

This is a cross-sectional, descriptive, observational, and quantitative study conducted for 8 months at an Integrated Public Education Center in the Caju neighborhood, in Rio de Janeiro, Brazil. Convenience sampling was used for the selection of study participants.

A total of 760 free informed consent forms were handed out to children and adolescents aged 8 to 15 years enrolled in the school, and 260 were returned. The inclusion criteria were the signed consent form, absence of neurological impairment, and free participation by the child or adolescent.

Pilot study

A pilot study was carried out to assess the questionnaire proposed for the interview. The study included children and adolescents in the same age bracket selected by convenience sampling at the Pediatric Outpatient Clinics affiliated with the Dental School of UFRJ. Four children (three girls and one boy) were assessed and the mean age was 10 years.

The questionnaire was based on the Brazilian National Student Health survey,[6] and Child Perception Questionnaire (CPQ).[11-14,7] The questions and answers were elaborated to verify the students' perception of their oral health, based on the block "hygiene and oral health" of the questionnaire of the National School Health Survey[6] and some questions from the Child Perception Questionnaire.[11-14 7] Regarding the answers, it was possible to mark more than one option on some questions and open answers, that were categorized for analysis. The adaptations were made with the aim of grouping and simplifying the answers.

Data collection

Interview

The interviews were performed in the place and time designated by the school and the students were scheduled by class. The questions were asked directly to the children or adolescents aiming to understand the perception of their smile. Both the interview and the report were made by the same researcher (MCCB).

Clinical oral examination

The oral health examination was performed after the interview, in the same room, under ambient lighting using personal protective equipment (gloves, mask, cap, and goggles), mouth mirror, and millimeter-graduated probe for epidemiological examination in order to assess the oral status of the children and adolescents and check for the presence of dental caries. Presence of trauma was assessed by evidence or not of anterior tooth fracture.

The examination and notetaking were performed by the same researcher (SKPCT), previously trained and calibrated (Kappa 0.716), and classified according to the World Health Organization.[8] Those patients in need of treatment were referred to the health unit in charge of school health. The referral was previously planned with dentists from the referral unit.

Statistical analysis

Percentage values were used for the descriptive analysis and the chi-square test was used for comparison of categorical variables. If necessary, Fisher's exact test was utilized. The results are shown in the tables and the level of significance was set at 5% ($p < 0.05$). The data were described and analyzed by SPSS version 20.0 (Chicago, IL, USA).

RESULTS

Among the 260 participants, 137 (52.7%) were male and 123 (47.3%) were female, with a mean age of 10.5 years (Table 1). Most students self-identified as dark-skinned (52.3%) and whites (29.6%).

A DMFT index equal to zero was observed in 134 (51.5%) students, and when the DMFT index was compared between sexes, the difference was not statistically significant. Forty students (15.5%) had dental caries with a DMFT index greater than 3. Anterior tooth trauma was observed in 10 students, accounting for 3.8% of the total sample. Most students (173 or 66.5%) said they had not seen a dentist in the past year, being significant the difference in relation to those (Table 2).

Table 1: *Sample distribution according to age and sex (n=260)*

Age	Sex		
	Female	Male	Total
8 years	16	9	25
9 years	26	23	49
10 years	25	30	55
11 years	29	33	62
12 years	16	24	40
13 years	7	6	13
14 years	4	9	13
15 years	0	3	3
Total	123	137	260

Table 2: *Students' oral health status (n=260) according to the past visit to a dentist.*

Variable	Female		Male		Total		*p* value
Did you see a dentist in the past year?	n	%	n	%	n	%	
No	81	31.2	92	35.4	173	66.5	
Yes	42	16.2	45	17.3	87	33.5	$p = 0.04$*
DMFT index							
0	56	21.5	78	30	134	51.5	
1	21	8.1	16	6.2	37	14.2	
2	13	5	19	7.3	32	12.3	
3	10	3.8	7	2.7	17	6.5	
>3	23	8.5	17	6.6	40	15.5	$p = 0.37$
dmft index							
0	75	28.8	88	33.8	163	62.7	
1	17	6.5	14	5.4	31	11.9	
2	10	3.8	13	5	23	8.8	
3	8	3.1	7	2.7	15	5.8	
>3	13	5.1	15	5.8	28	10.7	$p = 0.4$
Trauma							
No	120	46.2	130	50	250	96.2	
Yes	03	1.1	7	2.7	10	3.8	$p = 0.21$
Total	123	47.3	137	52.7	260	100.00	

***Table 3**: Self-perception of the impact of oral health status on daily life (n=260)*

Variable	Female		Male		Total		*p* value
	n	%	n	%	n	%	
Do you like your own smile?							
Yes	102	39.2	127	48.8	229	88.1	
No	21	8.1	10	3.8	31	11.9	$p = 0.19$
Is there anything you don't like about your own smile?							
Nothing	50	19.4	87	33.2	137	52.6	
Position	21	8.1	18	6.9	39	15	
Color	18	6.9	06	2.3	24	9.2	
Size	17	6.5	12	4.6	29	11.2	
Other	17	6.4	14	5.6	31	12	$p = 0.23$
Have you ever felt upset about your teeth?							
Never	81	31.2	101	38.8	182	70	
Few times	29	11.2	32	12.3	61	23.5	
Many times	13	5	04	1.5	17	6.5	$p = 0.39$
Have you ever felt embarrassed about your teeth?							
Never	76	29.2	96	36.9	172	66.2	
Few times	25	9.6	31	11.9	56	21.5	
Many times	22	8.5	9	3.5	31	11.9	
Did not answer	0	0	1	0.4	1	0.4	$p = 0.21$
Have you ever avoided smiling because of your teeth?							
Never	77	29.6	90	34.6	167	64.2	
Many times	24	9.2	21	8.1	45	17.3	
Few times	22	8.5	26	10	48	18.5	$p = 0.684$
Have you ever been given a nickname because of your teeth?							
No	92	35.4	114	43.8	206	79.2	
Yes	31	11.9	23	8.8	54	20.8	$p = 0.65$
What have you avoided doing because of dental problems?							
Nothing	96	36.9	116	44.6	212	81.5	
Playing	7	2.7	15	5.8	22	8.5	
Going to school	7	2.7	4	1.5	11	4.2	
Going out with friends	5	1.9	1	0.4	6	2.3	
Other	8	3.1	1	0.4	9	3.5	$p = 0.07$
What's a beautiful smile for you?							
Clean teeth	33	12.7	41	15.8	74	28.5	
White teeth	25	9.6	33	12.7	58	22.3	
Feeling of happiness (happy smile)	16	6.2	14	5.4	30	11.5	
Well-positioned teeth	16	6.2	9	3.5	25	9.6	
Don't know	5	1.9	16	6.2	21	8.1	
Clean + white teeth	4	1.5	6	2.3	10	3.8	
White teeth + position	4	1.5	6	2.3	10	3.8	
Clean teeth + correct position	5	1.9	2	1.5	7	2.7	
White teeth + feeling of happiness	1	0.4	1	0.4	2	0.8	
Other	14	5.4	9	3.5	23	8.8	$p = 0.19$
TOTAL	123	47.3	137	52.7	260	100.00	

The level of satisfaction with one's smile was high, as 229 (88.1%) students said they liked their smile; and when they were asked "What's a beautiful smile for you?," 74 (28.5%) and 58 (22.3%) students mentioned clean and white teeth, respectively, as the main characteristics of a beautiful smile. When asked whether they had already felt upset or embarrassed about their teeth, 182 (70%) said they had never felt upset and 172 (66.2%) answered they had never felt embarrassed. However, 93 (35.7%) mentioned they had already avoided smiling because of the appearance of their teeth and 54 (20.8%) said they had already been given nicknames for that reason. When these questions were compared between sexes, embarrassment was more predominant among girls, but without any statistical significance (Table 3).

DISCUSSION

Sex distribution in the sample was balanced relative to the total number of students, and the most frequent age was 11 years. At any age, regardless of sex, oral health and esthetics are considered to be important for self-image and normal social interaction.[9]

The negative answer of students to the question about whether they had seen a dentist in the past year indicates better results than those obtained from PeNSE 2012,[6] in which 40% of the interviewees in Rio de Janeiro gave a negative answer. This should be further investigated to verify whether there is a shortage of dental care services in the region or whether the behavior is specific to that community. Notably, the region where the school is located has one of the lowest human development index (HDI) and social development index (SDI) at the local level.[10,11]

Limitations of the study were the difficult access and compliance of a considerable share of the population, since only 34.2% of consent forms were returned. This is one of the major problems with research that involves students, so it is important to conduct investigations into methods for obtaining informed consent.[12] This low rate underscores the importance of communication between the school and the parents/legal guardians for the development of strategies that include students.

By comparing the dental caries rate obtained in our study with the data published by SB Brasil[13] in 2010, there was some similarity in the results found for 12-year-olds, with 52.5% of students with a DMFT index equal to zero, in line with those data gathered by SB Brasil for Rio de Janeiro. Nevertheless, from the total sample (48.5%) with a DMFT index greater than zero, 15.5% had a DMFT index greater than 3, which indicates a high prevalence of dental caries, i.e., predominance of the disease in a given group. Similar results have been reported in the literature,[14,15] showing that, even though the strategies for control of the disease and public policies for oral health promotion have been favorable, control strategies and oral health promotion actions should always be encouraged, because the coverage of dental care is not similar across different population groups.

Regarding the frequency of dental trauma, according to data published by SB Brasil,[13] the prevalence of dental trauma was observed in one fifth of the population, and upper incisors were the most commonly affected teeth. Comparing this with the data obtained by the study, the prevalence is a lot lower, which, to some extent, was unexpected, as children and adolescents at such an age are more exposed to situations that lead to dental trauma.[16]

The analysis of satisfaction of students with their teeth and smile showed that most of them liked their teeth and smile, but such an answer was more frequent among male students than among female ones. In this sense, although a significant difference was not disclosed in the analysis of the results, it suggested a higher trend of satisfaction among male students. It is possible to say that girls, from a very young age, demand more from themselves and have a higher level of dissatisfaction with their esthetics.[17,18] Those who said they liked their teeth were asked whether there was anything that they disliked about them, and in their answers they mentioned position, size, and color. Among the factors that make up someone's beauty, smile is regarded as one of the most important ones.

When asked what they considered to be a beautiful smile and what they thought was important for a relationship with their peers, the biggest concern turned out to be "having clean teeth." If we group the answers related to the question about dental esthetics, almost 50% of the sample showed this concern. In the study by Perin et al.,[19] this answer about esthetics was also frequent.

While most students did not indicate a direct impact of oral status on the development of daily relationships, one fifth of the sample had been given nicknames because of their smile. Some studies demonstrate that nicknames may characterize bullying at school, which could interfere with the students' self-esteem and with the relationship with their peers.[20]

Based on the results obtained, we suggest studies that evaluate the relationship between oral health status and possible bullying or situations that could interfere with the students' psychosocial development.

Most students like their own smile and are satisfied with their teeth, and that half of them are free of dental caries and that a sizable number feel upset and embarrassed about their teeth, which may affect the self-esteem and, consequently, the quality of life of these students.

CONCLUSION

It may be concluded that although half of the students were free of dental caries and most were satisfied with their smile, a sizable number felt upset and embarrassed about their teeth, which may interfere in the relationship with their peers.

ACKNOWLEDGMENTS

Acknowledgments to the Municipal Health Department, the Municipal Education Department of Rio de Janeiro, the principals of the school children, parents and guardians and schoolchildren, the main reason for the development of this research.

REFERENCES

1. World Health Organization. The World Oral Health Report 2003 Continuous improvement of oral health in the 21st century – the approach of the WHO Global Oral Health Programme, 2003. http://www.who.int/oral_health/media/en/orh_report03_en.pdf
2. Damasceno LM, Marassi CS, Ramos MEB, Souza IPRS. Alterações no comportamento infantil decorrente da perda de dentes anteriores: relato de caso. Rev Bras Odontol. 2002 mai-jun; 59(3):193-6.
3. Kaur P, Singh S, Mathur A, Makkar DK, Aggarwal VP, Batra M, et al. Impact of dental disorders and its influence on self esteem levels among adolescents. J Clin Diagn Res. 2017 Apr; 11(4):ZC05-8.
4. Aimeé NR, Van Wijr AJ, Maltz M, Varjão MM, Mestrinho MD, Carvalho JC. Dental caries, fluorosis, oral health determinants and quality of life in adolescents. Clin Oral Investig. 2017; 21(5): 1811-20.
5. Feldens CA, Ardenghi TM, Dos Santos Dullius AI, Vargas-Ferreira F, Hernandez PA, Kramer PF. Clarifying the impact of untreated and treated dental caries on oral health-related quality of life among adolescents. Caries Res. 2016; 50(4): 414-21.
6. Brasil. Ministério da Saúde. Ministério do Planejamento, Orçamento e Gestão. Instituto Brasileiro de Geografia e Estatística. Pesquisa Nacional de Saúde do Escolar (PeNSE 2012). Rio de Janeiro (RJ); 2013.
7. Torres CS, Paiva SM, Vale MP, Pordeus IA, Ramos-Jorge ML, Oliveira AC, et al. Psychometric properties of the Brazilian version of the Child Perceptions Questionnaire (CPQ11-14) - short forms. Health Qual Life Outocomes. 2009; 7:43.
8. Organização Mundial da Saúde (OMS). Levantamento epidemiológico básico de saúde bucal: manual de instruções. 3ª ed. São Paulo: Editora Santos; 1991.
9. Elias MS, Cano MAT, Mestriner JR.W, Ferriani MGC. A importância da saúde bucal para adolescentes de diferentes estratos sociais do município de Ribeirão Preto. Revista Latino-Americana de Enfermagem, Ribeirão Preto. 2001 jan; 9(1): 88-95.
10. Atlas do Desenvolvimento Humano no Brasil. Região Metropolitana. Rio de Janeiro. Em www.atlasbrasil.org.br/2013/pt/perfil_m/rio-de-janeiro_rjlocalidade. Acesso em 29/08/18
11. Prefeitura da Cidade do Rio de Janeiro. Instituto Pereira Passos. Armazém de Dados. Índice de Desenvolvimento Social (IDS) por Áreas de Planejamento (AP), Regiões Administrativas (RA), Bairros e Favelas do Município do Rio deJaneiro,2010.www.data.rio/datasets?content=document&q=ids&source=Prefeitura%20da%20Cidade%20do%20Rio%20de%20Janeiro. Acesso em 02/07/2018.
12. Pereira ACS, Williams LCA, Bem FP. Consentimento dos pais em pesquisas com escolares e a legislação brasileira. Interação Psicológica, 16(1) 51-61, 2012
13. Ministério da Saúde. Secretaria de Atenção à Saúde. Pesquisa Nacional de Saúde Bucal, SB Brasil 2010. Brasília (DF); 2010.
14. Hoffmann HS, Cypriano S, Sousa MLR, Fagiani JEM. Padrão Epidemiológico da Cárie Dentária e Necessidades de Tratamento em um Município com Prevalência Moderada de Cárie Dentária. R. Fac. Odontol. Porto Alegre, 2006 abr, 47(1): 34-8.
15. Leão MM, Garbin ACS, Moimaz SAS, Rovida TAS. Saúde bucal e qualidade de vida: um estudo epidemiológico de adolescentes de assentamento no Pontal do Paranapanema/SP, Brasil. Ciência & Saúde Coletiva. 2015; 20(11):3365-74.
16. Andreasen FM, Andreasen JO. Treatment of traumatic dental injuries. Shift in strategy. International J Technol Assess Health Care. 1990; 6 : 588-602.
17. Peres KG, Barros AJD, Anselmi L, Peres MA, Barros FC. Does malocclusion influence the adolescent´s satisfaction with appearance? A cross-sectional study nested in Brazilian birth cohort. Community dent oral epidemiology, 2008; 36: 137-43.
18. Marques LS, Barbosa CC, Ramos-Jorge ML, Pordeus IA, Paiva SM. Prevalência de maloclusão e necessidade de tratamento ortodôntico em escolares de 10 a 14 anos de idade em Belo Horizonte, Minas Grais, Brasil enfoque psicossocial. Cadernos de Saúde Pública, Rio de Janeiro, 2005 jul-ago; 21 (4): 1099-106.
19. Perin PCP, Garbin AJ, Perin LF, Pereira MA, Abreu KC. Percepção da condição de saúde bucal em crianças numa instituição na cidade de Lins/SP. Rev. Fac. Odontol. Lins, Piracicaba, 2004; 16 (2): 33-8.
20. Shaw WC, Meek SC, Jones DS. Nicknames, teasing, harassment and the salience of dental features among school children. Br J Orthod. 1980; 7(2), 75-80.

IN VIVO EVALUATION OF INFLAMMATION AND MATRIX METALLOPROTEINASE EXPRESSION IN DENTAL PULP INDUCED BY LUTING AGENTS IN DOGS

Alexandra Mussolino de **Queiroz**[1], Thais Helena Andreoli do **Amaral**[1], Paôla Caroline da Silva **Mira**[1], Francisco Wanderley Garcia **Paula-Silva**[1], Paulo **Nelson-Filho**[1], Raquel Assed Bezerra da **Silva**[1], Léa Assed Bezerra da **Silva**[1]*

[1]Department of Children's Clinic of the School of Dentistry of Ribeirão Preto-USP, Ribeirão Preto, SP, Brazil.

Palavras-chave: Agentes Cimentantes. Cimento Resinoso. Cimento de Ionômero de Vidro. Capeamento Pulpar Indireto. Metaloproteinases de Matriz.

RESUMO

Objetivo: Avaliar a resposta tecidual inflamatória e a expressão de metaloproteinase de matriz (MMP) -2 e -9 no complexo polpa-dentina em resposta aos cimentos RelyX™ Unicem (RU) e Ketac Cem™ Easymix (KC). **Métodos**: Cavidades classe V foram preparadas em 56 dentes de seis cães, e capeamento pulpar indireto foi realizado com cimento de RU (n = 20), KC (n = 20), óxido de zinco e eugenol (controle, n = 16). Aos 7 e 70 dias após o capeamento pulpar indireto, os animais foram eutanasiados, e os tecidos foram removidos para avaliação histológica. A distância entre o assoalho da cavidade e a camada odontoblástica foi medida, e os números de células inflamatórias, fibroblastos e odontoblastos foram contados no tecido pulpar. Os níveis de expressão de MMP-2 e -9 foram avaliados por imuno-histoquímica. Análises estatísticas foram realizadas para todos os experimentos (nível de significância = 5%). **Resultados**: A espessura da dentina remanescente entre o assoalho da cavidade e a câmara pulpar foi semelhante para todos os materiais, variando de 469 a 739 µm (p> 0,05). Aos 7 dias, KC e RU induziram uma pequena resposta inflamatória no complexo polpa-dentina, semelhante ao controle (p> 0,05). Aos 70 dias, a RU induziu uma resposta tecidual caracterizada por menos odontoblastos e mais células mononucleares (p <0,05), enquanto o KC induziu uma resposta semelhante ao controle (p> 0,05). Os agentes cimentantes induziram baixos níveis de expressão de MMP-2 e MMP-9, semelhantes ao controle (p> 0,05). **Conclusão**: Os agentes cimentantes KC e RU são materiais compatíveis para uso em cavidades profundas próximas ao tecido da polpa dentária, embora a UR tenha levado a uma população odontoblástica levemente diminuída, com maior porcentagem de células mononucleares.

Keywords: Luting Agents. Resin Cements. Glass Ionomer Cement. Indirect Pulp Capping. Matrix Metalloproteinases.

ABSTRACT

Objectives: To evaluate the inflammatory tissue response and matrix metalloproteinase (MMP)-2 and -9 expression in the pulp-dentin complex in response to RelyX™ Unicem (RU) and Ketac Cem™ Easymix (KC) cements. **Methods**: Class V cavities were prepared in 56 teeth from six dogs, and indirect pulp capping was performed using RU (n=20), KC (n=20), zinc oxide, and eugenol cement (control, n=16). At 7 and 70 days following indirect pulp capping, the animals were euthanized, and tissues were removed for histological evaluation. The distance from the cavity floor to the odontoblastic layer was measured, and the numbers of inflammatory cells, fibroblasts, and odontoblasts were counted in pulp tissue. MMP-2 and -9 expression levels were immunohistochemically assessed. Statistical analyses were performed for all experiments (significance level=5%). **Results**: The dentin remnant thickness between the cavity floor and the pulp chamber was similar for all materials, ranging from 469 to 739 µm (p>0.05). At 7 days, KC and RU induced a small inflammatory response in the pulp-dentin complex, similar to the control (p>0.05). At 70 days, RU induced a tissue response characterized by fewer odontoblasts and more mononuclear cells (p<0.05), whereas KC induced a response similar to the control (p>0.05). Luting agents induced low levels of MMP-2 and MMP-9 expression, similar to the control (p>0.05). **Conclusion**: KC and RU luting agents are compatible materials for use in deep cavities close to dental pulp tissue, although RU led to a slightly diminished odontoblastic population with a higher percentage of mononuclear cells.

Submitted: December 13, 2018
Modification: January 26, 2019
Accepted: April 1, 2019

***Correspondence to:**
Léa Assed Bezerra da Silva
Address: Faculdade de Odontologia de Ribeirão Preto da Universidade de São Paulo. Avenida do Café, s/n. Ribeirão Preto, SP, Brazil. Zip Code: 14040-904.
Telephone Number: 55 16 3315-3984. Fax: 55 16 3315-4102.
E-mail: lea@forp.usp.br

INTRODUCTION

Cementation is a clinical procedure performed to fix one or more indirect restorations to a prepared tooth support (crown or root portion) by means of a luting agent.[1,2] Ketac™ Cem Easymix glass-ionomer cement (KC) is a conventional glass ionomer cement that presents adequate adhesive strength, low moisture sensitivity, low solubility, radiopacity, good marginal sealing, and fluoride release and is indicated for the cementation of metal and metal-ceramic crowns, orthodontic bands, and intraradicular posts.[3,4] Resin cements have also become popular in light of advancements in their physical and mechanical properties, including wear resistance, chemical adherence to tooth structures, resins, and porcelains, and favorable aesthetic appearance, especially for use in nonmetal restorations or those with visible edges.[3,5] RelyX™ Unicem (RU) is a resin cement that has dual polymerization, adhesive capacity, low moisture sensitivity, low linear expansion, fluoride release, superior marginal integrity, and good aesthetic properties and is indicated for cementation of ceramic, resin, or metal crowns and intraradicular posts and cores. In addition, it does not require any pretreatment of tooth tissues prior to cementation.[5]

The mechanical, chemical and biological properties of KC and RU have been investigated previously.[4,6,7,8,9,10,11,12,13,14,15,16] Because most teeth that require prosthetic treatment exhibit extensive coronal damage, investigations of the biological tissue response induced by luting agents on teeth with pulp vitality are relevant to understand the mechanisms of inflammatory reactions.

Matrix metalloproteinases (MMPs) are enzymes present in the dentin matrix that are involved in tissue remodeling.[17,18,19] High levels of MMP-9 are found in teeth with pulpitis,[20,21] whereas MMP-2 levels may be reduced.[20] Self-etching dentin adhesives are able to increase collagenolytic activity in the dentin-pulp complex by activating MMPs *in vitro*,[22,23,24] while zinc oxide and eugenol cement inhibit MMP expression *ex vivo*.[25] The effect of glass ionomer luting cements and resin cements on *in vitro* or *in vivo* MMP expression in dental pulp has not been investigated, albeit we have previously demonstrated that MMP synthesis is augmented when those cements are applied to subcutaneous connective tissue.[16]

Therefore, the aim of this study was to histopathologically evaluate the inflammatory tissue response to KC, a glass ionomer cement, and RU, a resin-based cement, as well as the expression of MMP-2 and -9 in dog dentin-pulp complexes.

MATERIALS AND METHODS

All animal procedures were performed according to the protocols reviewed and approved by the Animal Care Committee of the University of Sao Paulo in compliance with the applicable ethical guidelines and regulations of the international guiding principles for biomedical research involving animals (#11.1.540.53.9).

Indirect pulp capping in deep cavities

The second and third maxillary premolars and the second, third, and fourth mandibular premolars of six mongrel dogs of both genders, aged 12-18 months and weighing 10 kg, were used. Initially, the animals were preanesthetized with an endovenous injection of Neozine (1 mg/kg; Aventis Pharma, São Paulo, SP, Brazil) 15 minutes before the procedure. Next, anesthesia was induced with endovenous administration of Zoletil® 50 (0.1 ml/kg; Virbac do Brasil Ind. e Com., São Paulo, SP, Brazil). After endotracheal intubation, anesthesia was maintained with isoflurane (Abbott Laboratórios do Brasil Ltda., Rio de Janeiro, RJ, Brazil) administered with an inhalation device (Takaoka KT-20, São Paulo, SP, Brazil). During the entire procedure, the animals received an isotonic solution of 0.9% sodium chloride (Glicolabor Indústria Farmacêutica Ltda., Ribeirão Preto, SP, Brazil). Standardized radiographs of the teeth to be treated were taken using custom-made film-holding devices and size 2 periapical films (Ultraspeed; Eastman Kodak Co., Rochester, NY, USA). An exposure time of 1 second was used, and the X-ray equipment (Heliodent; Siemens Medical Systems, Iselin, NJ, USA) was set to 60 kVp and 10 mA. The exposed films were processed using the time/temperature method.

After the dental arch was isolated with a rubber dam, the operative field was cleaned with 3% hydrogen peroxide and 1.0% chlorhexidine gluconate. Class V cavities extending mesiodistally were prepared on the buccal surface of each tooth using a #1015 diamond bur (S.S.White Artigos Dentários Ltda, Rio de Janeiro, RJ, Brazil) in a high-speed turbine under refrigeration with water until a deep cavity was created. The depth was standardized by the length of the active area of the bur (3 mm).[4] After every four cavity preparations, a new diamond bur was used to ensure cutting effectiveness and to prevent overheating. The cavities were well irrigated with sterilized physiological saline solution (Glicolabor Indústria Farmacêutica Ltda.) to remove enamel and dentine debris and dried with cotton pellets.

Then, the pulpal wall was coated with the material corresponding to each of the groups (1, 2, and 3) according to the manufacturer's instructions. A total of 56 teeth were randomly assigned to three groups. **Group 1** (experimental) included 20 teeth treated with a glass ionomer cement (Ketac™ Cem Easymix, 3M ESPE, Seefeld, Germany); **Group 2** (experimental) included 20 teeth treated with a resin cement

(RelyX™ Unicem *clicker*-type packaging, 3M ESPE, Seefeld, Germany) that was photopolymerized for 20 seconds at 450 mW/cm^2(as measured with a curing radiometer); and **Group 3** (control) included 16 teeth treated with standard cavity filling cement (zinc oxide and eugenol cement, S.S.White Artigos Dentários Ltda, Rio de Janeiro, Brazil). All variables were tested in the same animal because each hemiarch was treated with different experimental protocols on a rotation system. Sample size was determined as recommended by ISO 7405:2008.[26] After placing each material on the pulpal wall, the cavities were filled with silver amalgam (Velvalloy™, S.S White Artigos Dentários Ltda, Rio de Janeiro, Brazil).

The animals were observed for possible dietary changes, inflammation, or tissue suppuration over the course of the experiment.

After the recommended experimental periods of 7 and 70 days after the procedures, the teeth of each group were submitted to standard radiographic examination, and the animals were submitted to euthanasia by anesthetic overdose. For this, the animals received injectable Neozine (Aventis) at a dosage of 1 mg/kg weight, which was slowly injected. Euthanasia was then induced with 20% potassium chloride (100 mg/kg), which was slowly, intravenously injected.

After that, teeth were removed with bone and adjacent tissue in a single block using a diamond disc under constant water cooling and then subjected to fixation in 10% formaldehyde solution for 72 hours. At the end of this period, demineralization was carried out using ethylene diamine tetra acetic acid (EDTA; Merck, Darmstadt, Germany) with pH 7.4, adjusted with sodium hydroxide (Chem. Ind. e Com. Ltda., Diadema, Brazil).

Histological evaluation

The demineralization process was activated by using a microwave oven (Sharp Carousel, São Paulo, Brazil) at 30°C at medium/maximum power to avoid tissue changes. The pieces were irradiated in glass vessels containing water and ice every 10 minutes for a period of 4 hours/day, with intervals of 5 minutes between irradiations. Complete demineralization of the samples, evidenced by means of radiographs of the pieces, was achieved in approximately 20 days. After demineralization, the pieces were washed in running water for 24 hours, dehydrated in increasing concentrations of alcohol, diaphanized in xylol and embedded in paraffin. The blocks were sectioned into 5-µm-thick semiserial cuts. For histopathological analysis, the slides were stained by hematoxylin and eosin (HE), and intermediate slides of each series were stained by the Brown & Brenn method.

The specimens were examined by an examiner who was blinded to the treatment groups using a Zeiss Axio Imager M1 binocular light microscope (Carl Zeiss AG Light Microscopy, Göttingen, Germany). The intra-examiner calibration showed a kappa value = 0.83.The thickness of the remaining dentin between the cavity floor and the pulp chamber was measured in µm using images obtained from three sections per specimen (5×) in three regions (half the length of the cavity floor and two equidistant regions from the first measurement and the lateral wall, to the right and to the left). The numbers of inflammatory cells (mononuclear and polymorphonuclear–PMNs), fibroblasts, and odontoblasts were estimated in three regions of the interface between the dentin layer in contact with the material and the pulp tissue (63×), using the *cell counter* tool of ImageJ version 1.42q software (NIH, Bethesda, MD, USA), in conjunction with the Axio Cam MRc5 video camera (Carl Zeiss AG Light Microscopy).Dichotomous data were analyzed with Fisher's exact test. Continuous data were analyzed with two-way analysis of variance followed by Bonferroni post hoc tests for multiple comparisons (significance level= 5%).

Immunohistochemistry

The slides were deparaffinized in xylol (3 immersions of 5 minutes each) and hydrated in a decreasing series of alcohol (2 immersion in 100% alcohol, followed by immersion in 95% alcohol and 1 immersion in 80% alcohol for 2 minutes each passage). They were then placed in distilled water for 5 minutes and kept in phosphate buffered saline (PSB) for another 5 minutes.

The Goat ImmunoCruz™ system (Santa Cruz Biotechnology Inc., Santa Cruz, CA,USA) was used for immunohistochemical experiments. Briefly, tissue sections were quenched in peroxidase buffer for 5 minutes, and antigen retrieval was performed by incubation with 0.05% Proteinase K obtained from *Engyodontium album* at 37°C for 15 minutes (Sigma-Aldrich, St. Louis, MO, USA). Nonspecific binding was blocked by treating sections with donkey serum blocker for 30 minutes, and then, sections were incubated for 1 hour with primary polyclonal goat antibodies for MMP-2 (5.0 µg/ml; Santa Cruz Biotechnology Inc., sc-8835) and MMP-9 (5.0 µg/ml; Santa Cruz Biotechnology Inc., sc-6840). Then, sections were incubated with anti-goat secondary antibody for 30 minutes, followed by horseradish peroxidase-streptavidin for 20 minutes, and the enzyme substrate 3,3'-diaminobenzidine for 5 minutes. Tissues were counterstained with Harris's hematoxylin and mounted using standard protocols. Negative controls were included in which the primary antibody was replaced with goat immunoglobulin G (IgG). Blinded microscopic analysis was performed using a Zeiss Axio Imager M1 binocular light microscope (Carl Zeiss AG Light Microscopy) at 10, 20, 40, 63,and 100× magnification.

RESULTS

Histopathological evaluation

No specimen was lost during the histopathological procedure; therefore, analysis was performed on all 56 teeth. The thickness of dentin remnants between the cavity floor and the pulp chamber was similar for the three materials at both time points, with medians varying from 469 to 739 µm (Figure 1), with no significant differences among groups (p>0.05).

At 7 days, the cellular response induced by RU, KC, and zinc oxide and eugenol (control) was not different (p>0.05). However, at 70 days, KC induced a cellular response comparable to that elicited by control cement with respect to all evaluated cell types (p>0.05). In contrast, RU caused a cellular response characterized by a lower percentage of odontoblasts and a higher percentage of mononuclear cells than the control condition (p<0.05); however, the percentages of fibroblasts and PMNs were similar(p>0.05) (Figures 1and 2). No bacteria were observed in any group at either time point.

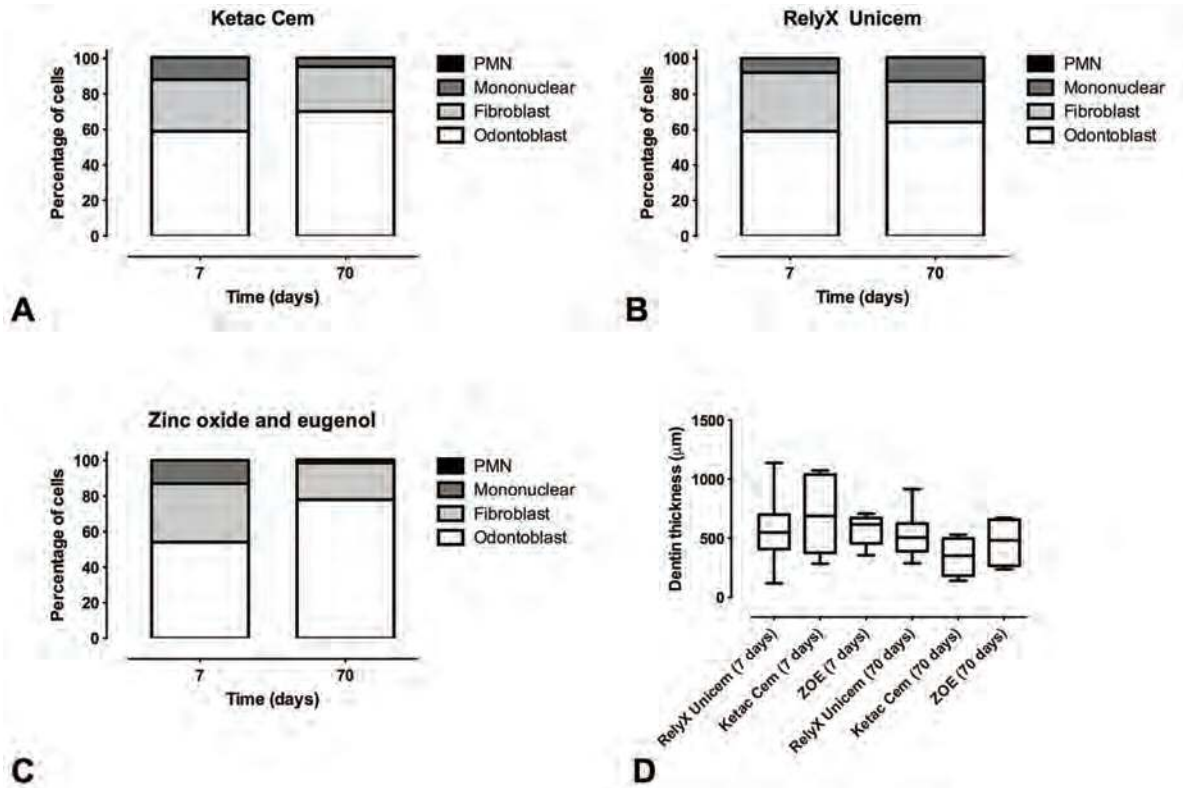

Figure 1: *Percentages of odontoblasts, fibroblasts, mononuclear cells, and polymorphonuclear (PMN) cells at 7 and 70 days.**A**- KC, **B**- RU, **C**- control. **D**- Dentin thickness (µm) in the different groups (KC, RU, and control) at 7 and 70 days. The middle bar represents the average dentin thickness for each group.*

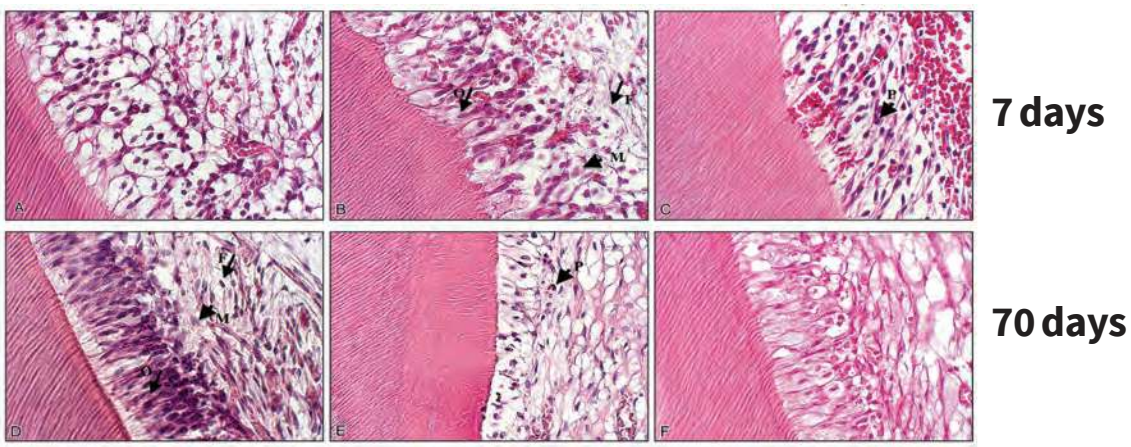

Figure 2: *Representative photomicrographs of the dentin-pulp complex of dog teeth immediately below the cavity floor at 7 (**A, B, C**) and 70 days (**D, E, F**) after indirect pulp capping with KC (**A, D**), RU (**B, E**), zinc oxide and eugenol (control; **C, F**), showing the integrity of pulp tissue. At 70 days, there was a lower density of odontoblasts in the RU group than in the KC and control groups. **O** stands for odontoblast, **F** stands for fibroblast, **M** stands for mononuclear inflammatory infiltrate, **P** stands for polymorphonuclear inflammatory infiltrate. Original magnification 40× (**E**), 63× (**A**-**D**, **F**)*

Immunohistochemical evaluation

No specimen was lost during the histopathological procedure; therefore, analysis was performed on all 56 teeth.

MMP-2 expression

KC (Figure 3)

At 7 days, predentin and odontoblasts were clearly stained, and a subset of mononuclear cells was also stained, particularly around the cellular membrane. Fibroblasts were stained weakly for MMP-2.

At 70 days, predentin was weakly stained, with no clear distinction from the remaining dentin. Positive cytoplasmic and perinuclear staining was observed in both odontoblasts and mononuclear cells. Fibroblasts were poorly stained.

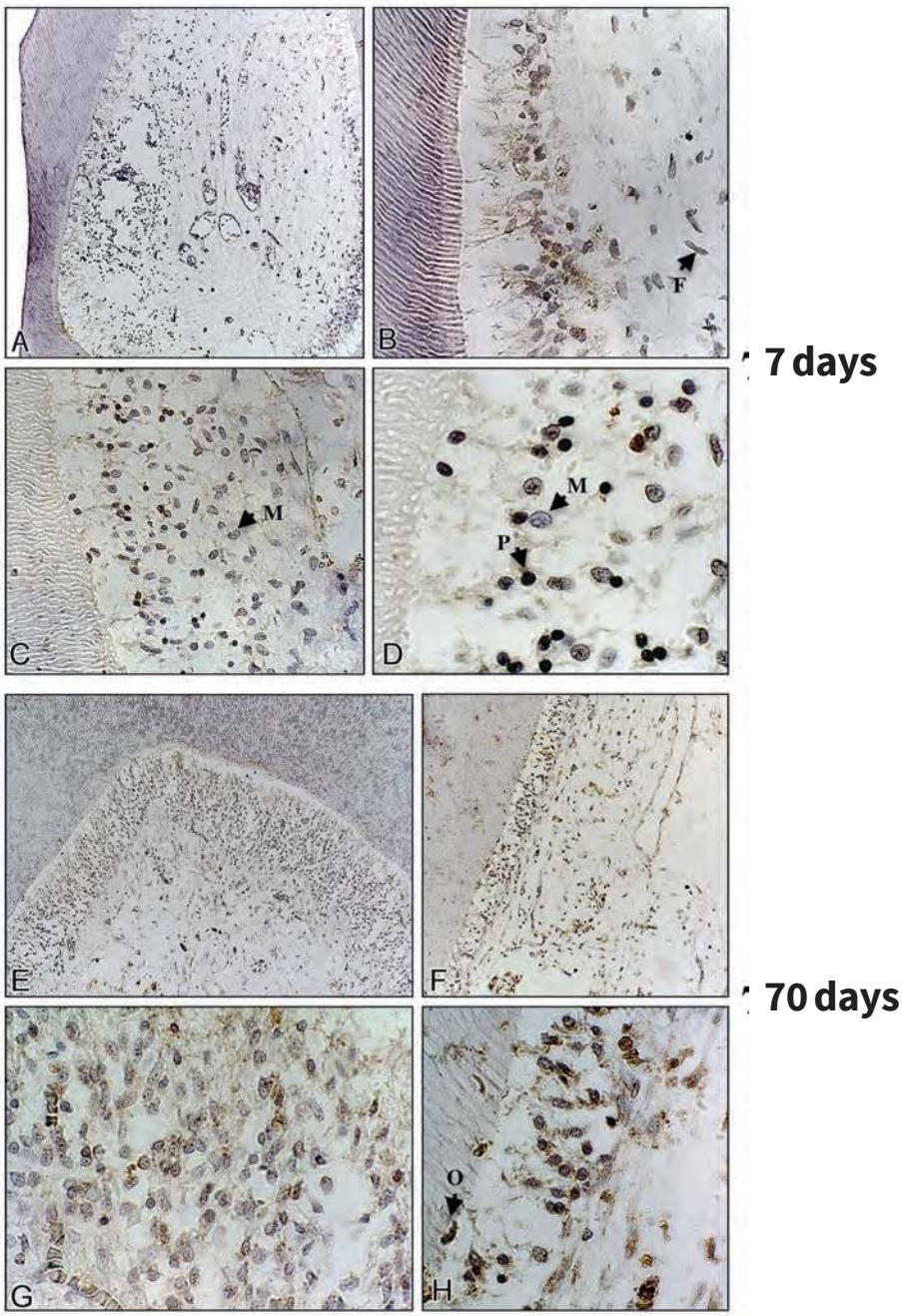

Figure 3: *MMP-2 immunohistochemistry in the dentin-pulp complex at 7 and 70 days after indirect pulp capping with KC. At 7 and 70 days, odontoblasts were clearly stained, but fibroblasts were not. Some mononuclear cells were also positive for MMP-2.* ***O*** *stands for odontoblast,* ***F*** *stands for fibroblast,* ***M*** *stands for mononuclear inflammatory infiltrate,* ***P*** *stands for polymorphonuclear inflammatory infiltrate. Original magnification 10× (**A, F**), 20× (**E**), 40× (**C**), 63× (**B, G, H**), 100× (**D**).*

RU (Figure 4)

Predentin was weakly stained at 7 days. Odontoblasts, mononuclear cells, and fibroblasts showed well-defined cytoplasmic and perinuclear staining.

At 70 days, predentin was weakly stained, and there was no clear distinction from the remaining dentin. Positive cytoplasmic and pericellular staining was observed in some odontoblasts and mononuclear cells. Fibroblasts were negative for MMP-2.

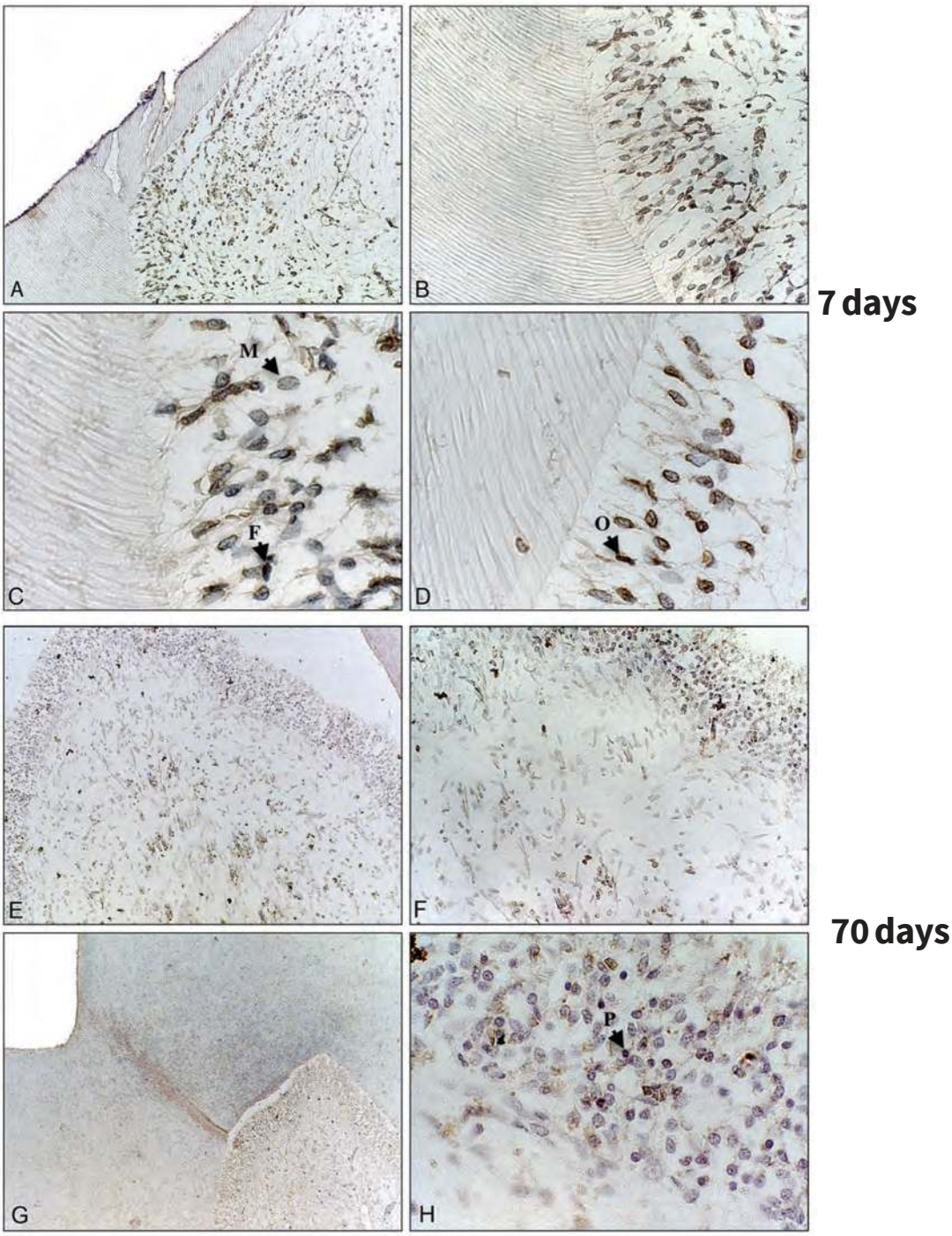

Figure 4: *MMP-2 immunohistochemistry in the dentin-pulp complex at 7 and 70 days after indirect pulp capping with RU.At 7 days, odontoblasts, mononuclear cells, and fibroblasts showed well-defined cytoplasmic and pericellular staining, and at 70 days, positive cytoplasmic and pericellular staining was observed in some odontoblasts and mononuclear cells. Fibroblasts were not positive for MMP-2.* ***O*** *stands for odontoblast,* ***F*** *stands for fibroblast,* ***M*** *stands for mononuclear inflammatory infiltrate,* ***P*** *stands for polymorphonuclear inflammatory infiltrate. Original magnification 5× (**G**), 10× (**A, E**), 20× (**F**), 40× (**B**), 63× (**H**), 100× (**C, D**).*

Zinc oxide and eugenol (control; Figure 5)

At 7 days, predentin was weakly stained. Some mononuclear cells and odontoblasts were stained. The stained mononuclear cells showed positivity around the membrane and occasional perinuclear staining. Fibroblasts were negative for MMP-2.

At 70 days, predentin was even more weakly stained for MMP-2, and a clear distinction with the remaining dentin was not observed. Positive cytoplasmic and perinuclear staining was observed in odontoblasts and mononuclear cells. Fibroblasts were not stained.

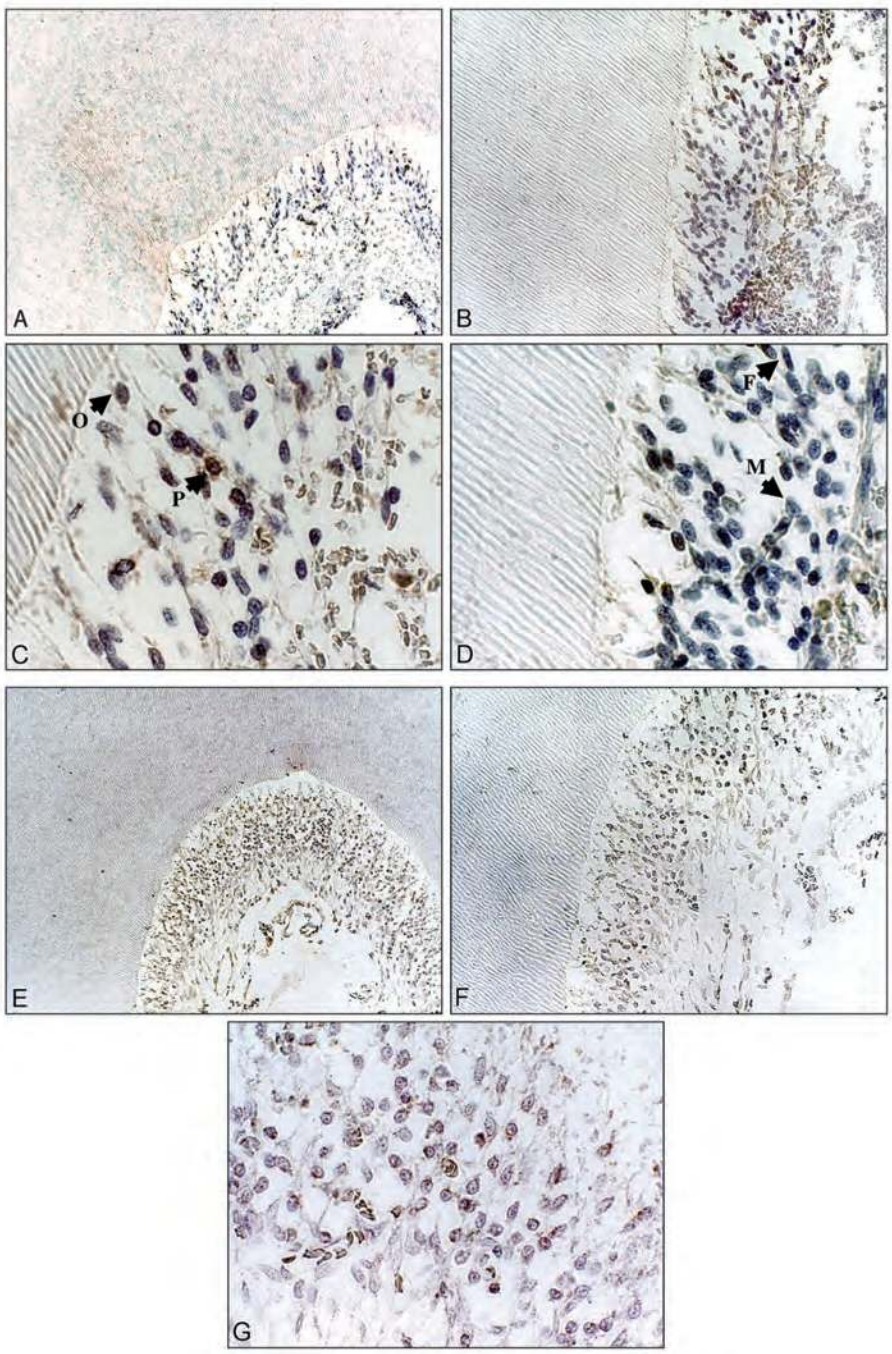

Figure 5: *MMP-2 immunohistochemistry in the dentin-pulp complex at 7 and 70 days after indirect pulp capping with zinc oxide and eugenol. At 7 days, predentin, odontoblasts and mononuclear cells were poorly stained, and positive staining was not evident in fibroblasts.* ***O*** *stands for odontoblast,* ***F*** *stands for fibroblast,* ***M*** *stands for mononuclear inflammatory infiltrate,* ***P*** *stands for polymorphonuclear inflammatory infiltrate. Original magnification 10× (**A**, **E**), 20× (**F**), 40× (**B**), 63× (**G**), 100× (**C**, **D**).*

MMP-9 expression

KC (Figure 6)

At 7 days, predentin was negative. Only a few odontoblasts and mononuclear cells were weakly stained, and there was no evidence of positive staining in fibroblasts.

At 70 days, predentin was not stained. Only a small sub set of odontoblasts and mononuclear cells were positive for MMP-9. Fibroblasts were not stained.

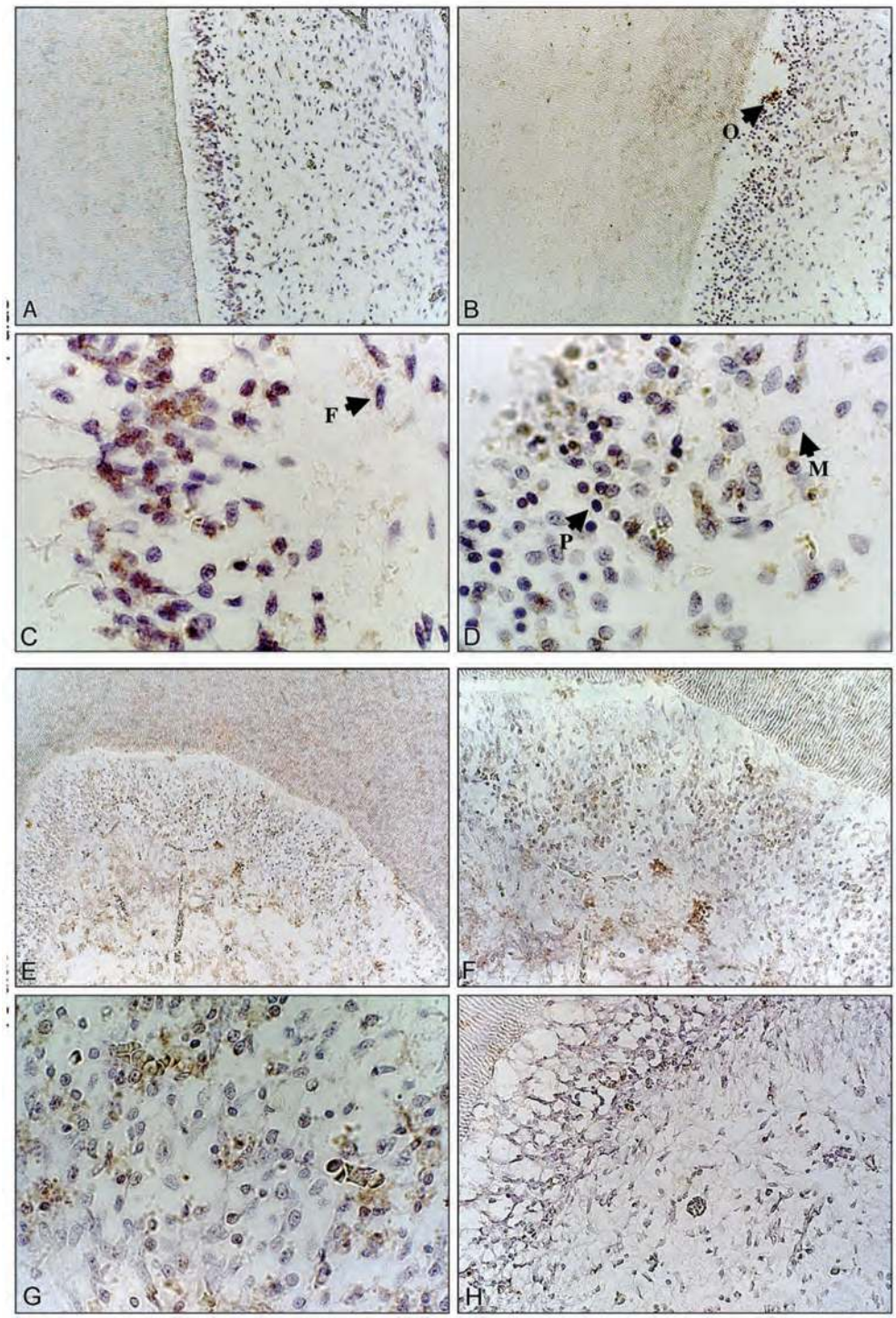

Figure 6: *MMP-9 immunohistochemistry in the dentin-pulp complex at 7 and 70 days after indirect pulp capping with KC. At 7 days, only a few odontoblasts and mononuclear cells were stained, with no evidence of positive staining in fibroblasts. MMP-9 staining decreased over time.* ***O*** *stands for odontoblast,* ***F*** *stands for fibroblast,* ***M*** *stands for mononuclear inflammatory infiltrate,* ***P*** *stands for polymorphonuclear inflammatory infiltrate. Original magnification 10× (****E****), 20× (****A****, ****B****), 40× (****F****, ****H****), 63× (****G****), 100× (****C****, ****D****).*

RU (Figure 7)

At 7 days, predentin, odontoblasts, and mononuclear cells were slightly stained. There was no significant positive staining in fibroblasts.

At 70 days, predentin was negative for MMP-9. Most odontoblasts were also negative. Some mononuclear cells showed perinuclear staining, but most did not. Fibroblasts were not stained.

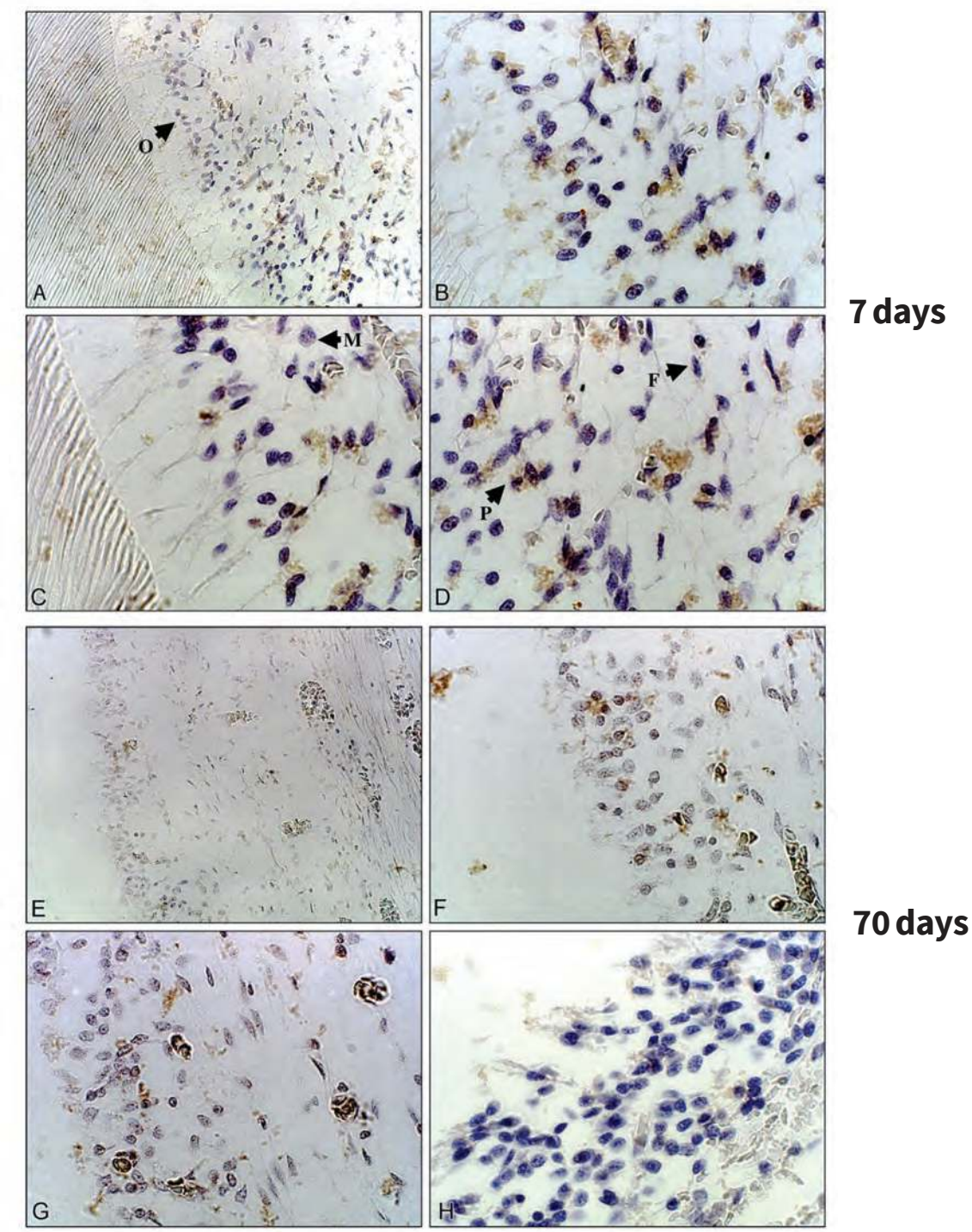

Figure 7: *MMP-9 immunohistochemistry in the dentin-pulp complex at 7 and 70 days after indirect pulp capping with RU. At 7 days, only a few odontoblasts and mononuclear cells were stained, with no evidence of positive staining in fibroblasts. MMP-9 staining decreased over time. Negative control: IgG.* ***O*** *stands for odontoblast,* ***F*** *stands for fibroblast,* ***M*** *stands for mononuclear inflammatory infiltrate,* ***P*** *stands for polymorphonuclear inflammatory infiltrate. Original magnification 40× (**A**,**E**), 63× (**F, G**), 100× (**B, C, D, H**).*

Zinc oxide and eugenol (control; Figure 8)

At 7 days, predentin, odontoblasts and mononuclear cells were poorly stained, and positive staining was not evident in fibroblasts.

At 70 days, predentin, mononuclear cells, and fibroblasts were negative for MMP-9, while some odontoblasts were weakly stained.

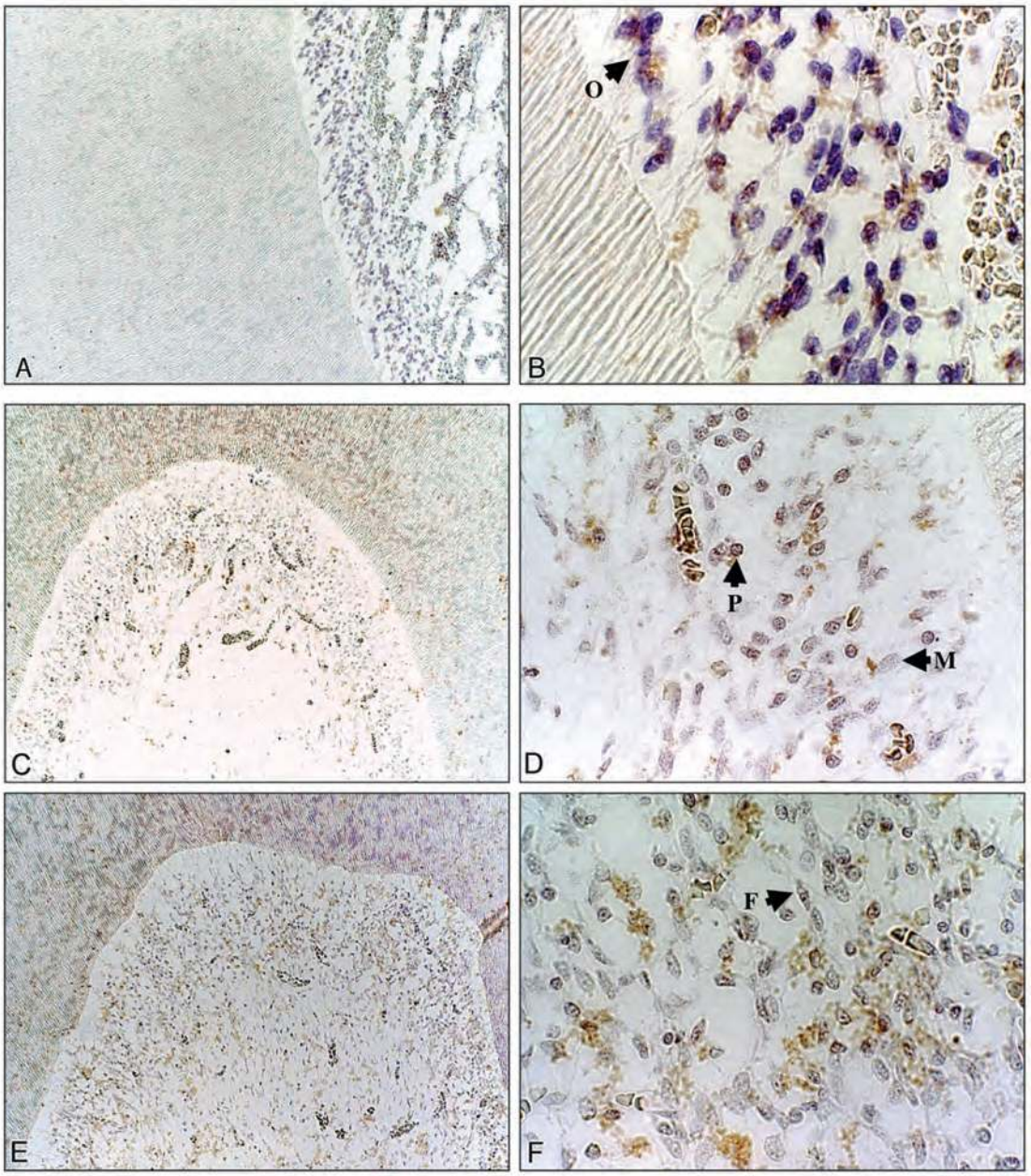

Figure 8: *MMP-9 immunohistochemistry in the dentin-pulp complex at 7 and 70 days after indirect pulp capping with zinc oxide and eugenol. At 70 days, predentin, mononuclear cells, and fibroblasts were negative for MMP-9, while some odontoblasts were weakly stained.* ***O*** *stands for odontoblast,* ***F*** *stands for fibroblast,* ***M*** *stands for mononuclear inflammatory infiltrate,* ***P*** *stands for polymorphonuclear inflammatory infiltrate. Original magnification 20× (****A****,* ***C****,* ***E****), 100× (****B****,* ***D****,* ***F****).*

DISCUSSION

In KC-treated teeth, higher percentages of odontoblasts and fibroblasts were observed 7 and 70 days after indirect pulp capping. Only a small percentage of mononuclear cells was observed at 7 days, and this value decreased over time. These results corroborate those of previous studies that KC has a low potential to cause cytotoxic and genotoxic effects[6,27,28] or induce inflammation *in vivo.*[15]

With respect to RU, fewer odontoblasts and greater numbers of mononuclear cells were observed compared with control and KC-treated teeth. However, there were no unsatisfactory pulp reactions with tissue damage at either time point, and odontoblasts and fibroblasts were the most prevalent cell types. These results corroborate those of a previous study, which reported minimal inflammatory response and tissue disruption at 7 and 60 days after indirect pulp capping of human teeth. However, a severe inflammatory response was observed when pulp was accidentally exposed.[14]

Several variables modulate RU cytotoxicity, depending, among other factors, on the curing strategy.[9] In the present study, the compatibility of RU after indirect pulp capping in deep cavities demonstrates that the remaining dentin, even if it is thin, can act as a barrier against the diffusion of possibly harmful chemical components in the material, thus avoiding direct contact of these components with the underlying connective pulp tissue and attenuating possible toxic effects.[29] Our findings support a previous *in vitro* investigation that used dentin disks to investigate the cytotoxicity of RU and found that more than 80% of cells remain viable after 24 hours or 7 days of indirect contact with the cement.[30] As recommended by ISO 7405:2008,[26] the cavities prepared in this study had a remaining dentin thickness ranging from 469 to 739 µm, with no difference between groups, and this may have limited the irritant effects of the cement on the pulp tissue.

Intense MMP-2 staining in the predentin area was only observed in KC-treated mice at 7 days, which appeared to be similar to dentin positivity at 70 days. For the RU,zinc oxide and eugenol cements, predentin was weakly stained for MMP-2 at 7 and 70 days. The increased expression of MMP-2 in the initial period after KC treatment can be attributed to its low initial pH. MMP-9 is an inflammatory marker in teeth with pulpitis,[20,21] and the low level of MMP-9 expression and minimal tissue inflammation observed in this study demonstrate that KC and RU are compatible with the dentin-pulp complex.

Weak acids are capable of activating dentin MMPs, which have collagenolytic and gelatinolytic activities.[23] The increase in MMP-2 expression at 7 days after using KC can be explained by its low initial pH.[31,32] MMP expression levels in the RU group were low and similar to the control group. This effect might be due to the material's pH, which increases from 2.0 to 4.0 during the first 60 minutes and to 7.0 after 24-48 hours.[33] Because it is not acidic after a day, it would not be likely to stimulate MMP activity.

From a clinical perspective, we believe that in adhesive restorations, a main issue is degradation of the hybrid layer. Currently, deterioration can be explained by the activation of endogenous enzymes such as MMPs present in the dentin, most likely due to the acidic properties of the adhesive systems.[34,35] Furthermore, we believe that, in general, the cementing agents used in the present study should not be used directly on the exposed pulp tissue. Although KC can be applied in deep dentin, RU should be preceded by the use of a protective agent on the pulp wall prior to cementation.

CONCLUSION

After indirect pulp capping of deep cavities in dog teeth, KC exhibited tissue compatibility similar to that of the control, whereas RU triggered a cellular response characterized by higher and lower percentages of mononuclear cells and odontoblasts, respectively. The luting agents induced low MMP-2 and-9 expression levels at 7 days and 70 days after indirect pulp capping.

ACKNOWLEDGEMENTS

The authors wish to thank Fundação de Amparo à Pesquisa do Estado de São Paulo (FAPESP #2009/54573-6 to LABS and #2005/57988-1 to THAA) and Conselho Nacional de Desenvolvimento Científico e Tecnológico (CNPq) for financial support. The authors do not report any conflicts of interest.

REFERENCES

1.Costa CAS, Giro EMA, Nascimento AB, Teixeira HM, Hebling J. Short-term evaluation of the pulpo-dentin complex response to a resin-modified glass-ionomer cement and a bonding agent applied in deep cavities. Dent Mater 2003; 19:739-746.

2.Jivraj SA, Kim TH, Donovan TE. Selection of luting agents:part 1. J Calif Dent Assoc 2006;34:149-60.

3.de la Macorra JC,Pradíes G. Conventional and adhesive luting cements. Clin Oral Investig 2002;6:198-204.

4.Manso AG, González-Lopez S, Bolaños-Carmona V, Maurício PJ, Félix SA, Carvalho PA. Regional bond strength to lateral walls in class I and II ceramic inlays luted with four resin cements and glass-ionomer luting agent. J Adhes Dent 2011;13:455-465.

5.Ferracane JL, Stansbury JW, Burke FJ. Self-adhesive resin cements - chemistry, properties and clinical considerations. J Oral Rehabil 2011;38:295-314.

6.Bakopoulou A, Mourelatos D, Tsiftsoglou AS, Giassin NP, Mioglou E, Garefis P. Genotoxic and cytotoxic effects of different types of dental cement on normal cultured human lymphocytes. Mutat Res 2009; 672:103-112.
7.Bitter K, Perdigão J, Hartwig C, Neumann K,Kielbassa AM. Nanoleakage of luting agents for bonding fiber posts after thermomechanical fatigue.J Adhes Dent 2011;13:61-69.
8.Mazzitelli C, Monticelli F, Toledano M, Ferrari M,Osorio R. Dentin treatment effects on the bonding performance of self-adhesive resin cements.Eur J Oral Sci 2010;118:80-86.
9.Monteiro GQ, Souza FB, Pedrosa RF, Sales GC, Castro CM, Fraga SN, et al. In vitro biological response to a self-adhesive resin cement under different curing strategies. Biomed Mater Res B Appl Biomater 2010;92:317-321.
10.Nakamura T, Wakabayashi K, Kinuta S, Nishida H, Miyamae M,Yatani H. Mechanical properties of new self-adhesive resin-based cement.J Prosthodont Res 2010;54:59-64.
11.Santos RL, Moura MF, Carvalho FG, Guênes GM, Alves PM, Pithon MM. Histological analysis of biocompatibility of ionomer cements with an acid-base reaction.Braz Oral Res 2014;28:1-7.
12.Schenke F, Federlin M, Hiller KA, Moder D,Schmalz G. Controlled, prospective, randomized, clinical evaluation of partial ceramic crowns inserted with RelyX Unicem with or without selective enamel etching: results after 2 years.Clin Oral Investig 2012;16:451-461.
13.Schmid-Schwap M, Franz A, König F, Bristela M, Lucas T, Piehslinger E, et al. Cytotoxicity of four categories of dental cements. Dent Mater 2009;25:360-368.
14.Souza Costa CA, Hebling J, Randall RC. Human pulp response to resin cements used to bond inlay restorations. Dent Mater 2006;22:954-962.
15.de Queiroz AM, Amaral THA, Paula-Silva FWG, Nelson-Filho P, Silva RAB, Gaton-Hernádez PM, et al. Luting agents differentially modulate inflammation and matrix metalloproteinases in connective tissue. Rev Cient CRO-RJ (Rio de Janeiro Dental Journal) 2018; 3:18-15.
16.Ulker HE, Sengun A. Cytotoxicity evaluation of self adhesive composite resin cements by dentin barrier test on 3D pulp cells. Eur J Dent 2009;3:120-6.
17.Krane SM, Inada M. Matrix metalloproteinases and bone. Bone 2008;43:7-18.
18.Martin-De Las Heras S, Valenzuela A, Overall CM. The matrix metalloproteinase gelatinase A in human dentine. Arch Oral Biol 2000;45:757-765.
19.Mazzoni A, Mannello F, Tay FR, Tonti GA, Papa S, Mazzotti G, Di Lenarda R, Pashley DH and Breschi L. Zymographic analysis and characterization of MMP-2 and -9 forms in human sound dentin. J Dent Res, 2007; 86: 436-440.
20.Gusman H, Santana RB, Zehnder M. Matrix metalloproteinase levels and gelatinolytic activity in clinically healthy and inflamed human dental pulps. Eur J Oral Sci 2002;110:353-357.
21.Tsai CH, Chen YJ, Huang FM, Su YF, Chang YC. The up regulation of matrix metalloproteinase-9 in inflamed human dental pulps. J Endod 2005;31:860-862.
22.Lehmann N, Debret R, Roméas A, Magloire H, Degrange M, Bleicher F, et al. Self-etching increases matrix metalloproteinase expression in the dentin-pulp complex. J Dent Res 2009;88:77-82.
23.Nishitani Y, Yoshiyama M, Wadgaonkar B, Breschi L, Mannello F, Mazzoni A, et al. Activation of gelatinolytic/collagenolytic activity in dentin by self-etching adhesives. Eur J Oral Sci 2006;114:160-166.
24.Tay FR, Pashley DH, Loushine RJ, Weller RN, Monticelli F, Osorio R. Self-etching adhesives increase collagenolytic activity in radicular dentin. J Endod 2006;32:862-868.
25.Santos MC, de Souza AP, Gerlach RF, Trevilatto PC, Scarel-Caminaga RM, Line SR. Inhibition of human pulpal gelatinases (MMP-2 and MMP-9) by zinc oxide cements. J Oral Rehabil 200;31:660-664.
26.International Standard Organization (ISO 7405:2008). Dentistry - Preclinical evaluation of biocompatibility of medical devices used in dentistry. Geneve, 2008.
27.Ribeiro DA, Marques ME, Salvadori DM. Biocompatibility of glass-ionomer cements using mouse lymphoma cells in vitro. J Oral Rehabil 2006;33:912-917.
28.Ribeiro DA, Marques ME, Salvadori DM. Genotoxicity and cytotoxicity of glass ionomer cements on Chinese hamster ovary (CHO) cells. J Mater Sci Mater Med 2006;17:495-500.
29.Stanley HR. Local and systemic responses to dental composites and glass ionomers. Adv Dent Res 1992;6:55-64.
30.Soares DG, Brito CA, Tavares da Silva RHB, Ribeiro APD, Hebling J, de Souza Costa CA. Cytocompatibility of HEMA–free resin–based luting cements according to application protocols on dentine surfaces. Int Endod J 2016;49:551-60.
31.Bapna MS, Mueller HJ. Leaching from glass ionomer cements. J Oral Rehabil 1994;21(5):577-83.
32.Perotti R, Perotti M. Variation, over time, in the pH of the materials used for pulpal-dentinal protection. A new measurement method. Minerva Stomatol;44(5):241-3.
33.3M ESPE. Technical product profile: Rely X Unicem. Germany (Seefeld): 3M ESPE Dental Products; 2007. 60p.
34.Altinci P, Mutluay M, Seseogullari-Dirihan R, Pashley D, Tjäderhane L, Tezvergil-Mutluay A. NaF Inhibits Matrix-Bound Cathepsin-Mediated Dentin Matrix Degradation. Caries Res. 2016;50(2):124-32.
35.Tjäderhane L, Nascimento FD, Breschi L, Mazzoni A, Tersariol ILS, Geraldeli S, Tezvergil-Mutluay A, Carrilho M, Carvalho RM, Tay FR, Pashley DH. Strategies to prevent hydrolytic degradation of the hybrid layer - A review. Dent Mater 2013;29(10):999-1011.

ODONTOMETRIC STUDY OF PREMOLARS FOR SEX DETERMINATION

Rodrigo da Silva **Andrade**[1], Larissa Chaves Cardoso **Fernandes**[2*], Maria Izabel Cardoso **Bento**[1], Kenio Costa de **Lima**[3], Patrícia Moreira **Rabello**[1], Bianca Marques **Santiago**[1]

[1]Department of Clinical and Social Dentistry, Federal University of Paraíba, Univesity city, João Pessoa, PB, Brazil.
[2]Department of Social Dentistry, Division of Forensic Dentistry,University of Campinas, Piracicaba, SP, Brazil.
[3]Department of Dentistry, Public Health, Federal University of Rio Grande do Norte, Natal, RN, Brazil.

Palavras-chave: Dentre Pré-molar. Odontometria. Caracteres Sexuais. Odontologia Legal. Antropologia Forense.

RESUMO

Objetivo: Este estudo cego e transversal objetivou verificar diferenças nas medidas odontométricas dos pré-molares de acordo com o sexo. **Métodos:** Os tamanhos dos dentes foram estabelecidos para os sexos masculino e feminino com base em uma amostra de 100 pares de modelos de gesso (50 de cada sexo) de estudantes de Odontologia da Universidade Federal da Paraíba. Os primeiro e segundo pré-molares, superiores e inferiores, esquerdo e direito, foram examinados em relação às suas medidas mésio-distal, vestíbulo-lingual e à distância entre os pré-molares homólogos em cada quadrante. Testes paramétricos foram utilizados com significância de 5%. O intervalo de confiança de 95% foi determinado para avaliar o poder de diferenciação de cada dente. **Resultados:** Houve diferenças estatisticamente significantes em todas as medidas entre os segundos pré-molares, com maiores valores nos homens (p<0,05). Entre os primeiros pré-molares, o dimorfismo sexual foi encontrado nos dentes 24 (comprimento mésio-distal) e 34 e 44 (comprimento vestíbulo-lingual). Quanto aos dentes homólogos, houve diferença significativa entre os pré-molares superiores e inferiores (p<0,001), sem distinção entre os lados direito e esquerdo. O intervalo de confiança 95% não mostrou valores de sobreposição, indicando dimorfismo sexual na medida mésio-distal do dente 15 e na medida vestíbulo-lingual dos dentes 15 e 34. **Conclusão:** Nós concluímos que o dente 15 tem o maior potencial de dimorfismo sexual, podendo ser utilizado para identificação humana na determinação do sexo com base nas medições mésio-distal (feminino: 6,40 a 6,63; masculino: 6,64-6,89) e vestíbulo-lingual (feminino: 9,28-9,54; masculino: 9,56-9,88).

Keywords: Bicuspid. Odontometry. Sex Characteristics. Forensic Dentistry. Forensic Anthropology.

ABSTRACT

Objective: This cross-sectional blind study aimed to verify differences in odontometric measurements of premolars according to sex. **Methods:** Teeth size values were established for males and females based on a sample of 100 pairs of plaster models (50 from each sex) from dental students. Upper and lower, left and right, first and second premolars were examined with regard to their mesiodistal and buccolingual measurements and the distance between homologous premolars in each quadrant. Parametric tests were used with a 5% significance. The 95% confidence interval was determined to assess the differentiation power of each tooth. **Results:** There were statistically significant differences in all measures among the second premolars, with higher values in men (p<0.05). Among the first premolars, sexual dimorphism was found in the teeth 24 (mesiodistal length) and 34 and 44 (buccolingual length). As for homologous teeth, there was a significant difference between upper and lower premolars (p <0.001), with no distinction between right and left sides. The 95% confidence interval showed no overlapping values, thus indicating sex dimorphism in the mesiodistal measure of tooth 15 and in the buccolingual measure of teeth 15 and 34. **Conclusion:** We conclude that the tooth 15 has the greatest potential for sex dimorphism, which could be utilized for human identification in sex determination based on mesiodistal (females: 6.40 to 6.63; males: 6.64 to 6.89) and buccolingual (females: 9.28 to 9.54; males: 9.56 to 9.88) measurements.

Submitted: March 27, 2019
Modification: May 6, 2019
Accepted: May 7, 2019

***Correspondence to:**
Larissa Chaves Cardoso Fernandes
Address: Avenida Presidente Epitácio Pessoa, 4050 (ap.1701), Miramar, João Pessoa, PB, Brazil. Zip code: 58.032-000
Telephone number: + 55 (83) 988876360
E-mail: larissaccfernandes@gmail.com

INTRODUCTION

Forensic dentistry, combined with the knowledge from the fields of Dentistry and Law, may provide evidence to subsidize the Court of Justice's decisions. Forensic dentistry can be defined as a specialty that aims to identify psychic, physical, chemical and biological processes that can affect or have affected a human, either alive, dead or bones, and even fragments or traces, resulting in partial or total damage, reversible or irreversible.[1]

Among several areas of expertise, specialists in forensic dentistry have an important role in human identification, which aims to determine the identity of someone or something, i.e., a set of physical, functional and/or psychological features that make one person different from the other and only identical to themselves. With this purpose, a set of procedures is performed by comparing pre and post-fact evidence so that to match possible concordance and discrepancy of present and remote data. The access of the experts to relevant records and their scientific knowledge are critical during the identification process.[1-3]

Body recognition of a deceased individual is a common procedure carried out by relatives or friends who claim to have known or lived with the individual. It is worth noting that such technique is limited as it is usually performed by lay people and may involve emotional conditions of the missing person's relatives. In addition, in most cases only the individual's bones are found, rendering the recognition approach impossible to be accomplished. Therefore, it becomes crucial to investigate the pieces of evidence with a focus on the features that link the body to the missing subject.[1,4-7]

As for human bones, the skull corresponds to one of the body parts providing the most relevant information. It is possible that all bones belonging to a subject are not found in the archaeological and forensic excavation scenes. In these cases, the skull and teeth remain the major resource for human identification.[8]

A very important step in the identification process refers to sex determination. This information alone reduces by half the likelihood of a given hypothesis. A number of quantitative and qualitative features related to sex dimorphism can be found in the skull, which are broadly reported in the literature.[1,5,7]

The increased incidence of mass disasters has highlighted the importance of Forensic Dentistry, given that bodies are frequently found in decomposed, carbonized or fragmented conditions. For instance, in cases of fires or plane crashes it is common to find dental arches as the only preserved structures, thereby making it possible to identify the corpses.[2] This is possible because teeth are the most resistant, hard and stable structures of the human body and also because individuals do not have identical dental features.[9]

Although smaller in size, premolars are posterior teeth presenting functions similar to those of molars. These teeth have a favorable position which usually prevents their displacement in case of trauma. As sex determination is a critical step in human identification and teeth are considered relevant resources,[6,10-13] this study aimed to assess the degree of sex dimorphism in the upper and lower, left and right premolars by odontometric analysis, as well as to establish the size range of premolars in men and women.

MATERIALS AND METHODS

This was an observational, cross-sectional, blind study. An intensive direct observation procedure was performed using maxillary and mandibular plaster casts. This study received prior approval by the Research Ethics Committee of the Center for Health Sciences at Federal University of Paraíba (CAAE: 17488213.3.0000.5188).

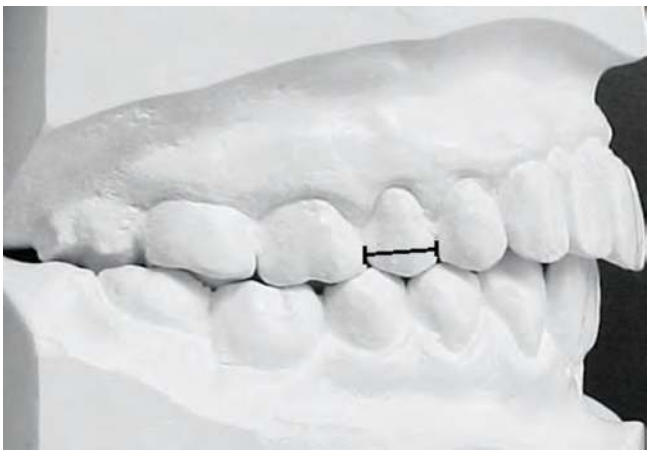

***Figure 1**: Mesiodistal distance in a second upper premolar. Source: current research.*

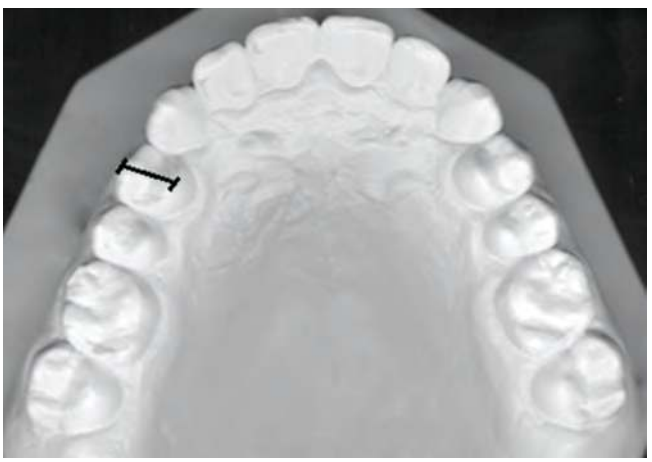

***Figure 2**: Buccolingual ou BuccoPalatal distance in first lower premolar. Source: current research.*

The study universe was composed of upper and lower plaster casts from undergraduate dental students of Federal University of Paraíba, João Pessoa, PB, Brazil. The casts were guarded by the Occlusion discipline for research purposes. The sample consisted of 100 pairs of plaster casts (50 from males and 50 from females) of individuals aged 20 to 31 years.

First, the plaster casts were catalogued and all information concerning the respective individuals was tabulated into a worksheet. In order to perform a blind analysis, we used a coding system so that the examiner did not have access to the students' names. With the aid of a digital caliper (Stainless® - 150mm/6, Mainland, China) the examiner measured the mesiodistal (MD) (Figure 1) and buccolingual (BL) (Figure 2) length of the crowns of the upper and lower, first and second premolars. In addition, the distance between the lingual cusps of corresponding (homologous) premolars in each quadrant (Figure 3) was measured using a string and a millimeter ruler.

The MD measure corresponds to the maximum distance between the proximal surfaces of premolars. It is measured with a caliper in a way so to follow the inclination of the triturating slopes of the buccal cusp. The BL measure is the distance between the extreme points of the buccal and lingual surfaces of the premolar crowns. The lingual-lingual distance between the lingual cusps of the premolars was measured using a string, which was transferred to a millimeter ruler in order to obtain a numerical value. In our study, the distances were measured considering the homologous teeth in each side (quadrant) of the same arch.

A pilot study was previously performed to train the examiner. Sixteen plaster casts were selected and examined using a digital caliper. All measurements were registered into a worksheet. After eight days, the casts were re-evaluated under the same conditions, in order to compare the results and check for intra-examiner agreement. The data were analyzed by intraclass correlation coefficient. Overall, good reproducibility rates were found for the MD (0.717 to 0.962), BL (0.732 to 0.920) and lingual-lingual (0.927, 0.906 and 0.900) measurements. The distance between the teeth 34 and 44 showed an agreement value of 0.624, which is still considered acceptable. Given that no changes and/or adjustments in the pilot study were necessary, all 16 pairs of plaster casts were also included in the final sample.

The collected data were entered into a database created in the Statistical Package for Social Sciences (SPSS) program, version 20.0. The data were analyzed descriptively and by statistical tests, with a 5% significance level. The hypothesis that quantitative variables obtained by odontometric measurement had a normal distribution was confirmed by the Kolmogorov-Smirnov test. The Levene's F test was used to check the data for equal variances. The other comparative analyses were carried out using the Student's t test and repeated-measures analysis of variance (ANOVA) with Bonferroni post-hoc test. The 95% confidence interval (95% CI) was calculated to identify the teeth showing the most significant sex dimorphism. In addition, we also check whether there was an overlap between the values in males and females. In cases where no overlap was detected, the 95% CI was used as a range to characterize such measures in men and women.

RESULTS

As shown in Table 1, as regards the mesiodistal length only the tooth 24 showed difference between sexes ($p=0.029$), with higher values found in males (7.06±0.46) than in females (6.86±0.40). As to the BL length, the teeth 34 and 44 showed difference between sexes ($p=0.001$ and $p=0.037$, respectively), with higher values in males. Upper teeth, in general, were found to show significant sex-related difference in relation to lower teeth ($p<0.001$).

All measurements of second premolars showed statistically significant differences between sexes, with higher values found in males. When comparing upper and lower teeth, no difference was observed in the MD length. The highest BL length values were found in the teeth 14 and 24, while the highest MD length values were observed in lower teeth, 35 and 45. There was no difference between sexes concerning the distance between the premolar cusps ($p>0.005$). However, significant differences were observed when the measurements of upper and lower teeth were compared.

As seen in Table 2, the tooth 15 may be used to discriminate between sexes as the 95% CI range did not overlap when comparing males and females. The teeth 24, 25, 35 and 45 also showed differences between sexes, with lower degree of discrimination though, as some CI values were found to overlap. These findings suggest that it is possible to determine the subject's sex based on the tooth 15, with some degree of uncertainty. The other tooth, however, did not show satisfactory degree of discrimination.

Table 3 shows that the teeth 15 and 34 discriminated between sexes, as the 95% CI values did not overlap. The other teeth (25, 35, and 45) also differed between sexes, although with a lower degree as some values overlapped. The data shown in Table 4 indicate that none of the distances between homologous premolars differed between sexes, as all 95% CI values overlapped.

***Table 1**: Means and standard-deviations of the mesiodistal, buccolingual and lingual-lingual distances in premolars (14, 24, 34, 44, 15, 25, 35 and 45) according to sex. João Pessoa, PB, Brazil, 2017.*

Measure		Sex				
		Female		Male		
	Tooth	Mean	Standard-deviation	Mean	Standard-deviation	p-value[1]
Mesiodistal (MD)	14	6.94[a]	0.43	7.06[a]	0.41	0.179
	24	6.86[a]	0.40	7.06[a]	0.46	0.029*
	34	6.88[a]	0.41	7.04[a]	0.45	0.072
	44	6.82[a]	0.42	6.87[a]	0.44	0.609
p-value[2]		0.591		0.075		
Buccolingual (BL)	14	9.40[a]	0.42	9.58[a]	0.55	0.070
	24	9.32[a]	0.43	9.48[a]	0.58	0.114
	34	7.71[b]	0.52	8.08[b]	0.53	0.001*
	44	7.73[b]	0.52	7.95[b]	0.50	0.037*
p-value[2]		<0.001*		<0.001*		
Mesiodistal (MD)	15	6.52[a]	0.41	6.77[a]	0.44	0.004*
	25	6.54[a]	0.52	6.79[a]	0.44	0.009*
	35	6.94[b]	0.45	7.18[b]	0.50	0.013*
	45	6.95[b]	0.39	7.16[b]	0.49	0.021*
p-valor[2]		<0.001*		<0.001*		
Buccolingual (BL)	15	9.42[a]	0.46	9.73[a]	0.57	0.004*
	25	9.42[a]	0.49	9.71[a]	0.56	0.007*
	35	8.41[b]	0.48	8.67[b]	0.53	0.012*
	45	8.45[b]	0.49	8.70[b]	0.45	0.011*
p-value[2]		<0.001*		<0.001*		
Distance	14 to 24	31.18	3.58	31.42	2.94	0.715
	34 to 44	36.08	3.09	36.16	3.68	0.907
p-value[2]		<0.001*		<0.001*		
Distance	15 to 25	27.44	2.29	27.52	2.29	0.862
	35 to 45	31.26	2.48	31.90	2.18	0.174
p-value[2]		<0.001*		<0.001*		

*Note: *Statistically significant difference (p-value<0.05). [1]Student's t test for equal variances. [2]Repeated-measures ANOVA. Different superscript letters indicate statistically significant difference between homologous teeth according to Bonferroni's multiple (pairwise) comparison test.*

Table 2: *Confidence intervals (CI) (95%) of the mesiodistal measurements of premolars according to sex in undergraduate dental students. João Pessoa, PB, Brazil, 2017.*

Tooth	Sex	
	Female	Male
14	6.82 – 7.06	6.93 – 7.17
15	6.40 – 6.63	6.64 – 6.89
24	6.75 – 6.98	6.92 – 7.18
25	6.38 – 6.68	6.66 – 6.91
34	6.76 – 7.00	6.91 – 7.16
35	6.81 – 7.06	7.03 – 7.32
44	6.70 – 6.94	6.74 – 6.99
45	6.84 – 7.06	7.02 – 7.30

Table 3: *Confidence intervals (CI) (95%) of the buccolingual measurements of premolars according to sex in undergraduate dental students. João Pessoa, PB, Brazil, 2017.*

Tooth	Sex	
	Female	Male
14	9.27 – 9.51	9.42 – 9.73
15	9.28 – 9.54	9.56 – 9.88
24	9.19 – 9.44	9.32 – 9.64
25	9.28 – 9.55	9.55 – 9.87
34	7.56 – 7.85	7.92 – 8.23
35	8.27 – 8.54	8.51 – 8.81
44	7.57 – 7.87	7.80 – 8.08
45	8.31 – 8.59	8.56 – 8.82

DISCUSSION

With regards to the relationship between tooth and sex, our findings showed that in all measurements premolars in men are bigger than in women. This is in agreement with studies conducted with other populations.[11,13-16] Nevertheless, Acharya and Mainali[17] found the MD length of lower second premolars to be higher in women than in men. The authors called this phenomenon reverse dimorphism, which could be explained by the diversity among populations.

As for the MD length, our study showed that only the upper left first premolar presented sex dimorphism, whereas for the BL length both lower first premolars showed differences between sexes. These findings are in disagreement with the reports by Zorba, Moraitis and Manolis,[13] in which higher levels of sex dimorphism were found in the upper and lower first premolars, followed by canines. A total of four measures were examined, which were found to be statistically different between sexes.

Overall, significant differences were found in the MD and BL measurements of second premolars, which suggests a potential use of this tooth for sex determination. In line with that, the study by Khan[16] reported that second premolars were the teeth presenting most dimorphic features.

The findings presented herein corroborate those reported by Costa, Lima and Rabello,[10] who carried out an analysis of canines in undergraduate dental students. The authors observed statistically significant sex dimorphism of the MD and BL dimensions in the canines, while in our study we observed sex dimorphism in the second premolars.

The lingual-lingual distance, which refers to the distance between the lingual cusps of homologous premolars in different quadrants, did not differ between sexes. Performing a similar odontometric calculation, Rastogi et al[19] measured the distance between the lower premolars by drawing a straight line between the occlusal grooves of the teeth. Their results revealed a sex-related difference, which is in disagreement with the data observed herein.

We used repeated-measures analysis of variance (ANOVA) with Bonferroni test to perform a comparative analysis of the left and right teeth. No difference was found between them, which suggests that there is no difference in the dimensions of the crowns of homologous teeth, as confirmed by other reports in the literature.[11,18] Nevertheless, we found significant differences when comparing the upper and lower teeth with regard to the study variables.

Given the presence of sex dimorphism in the examined teeth, our findings suggest that second premolars may be

applied as a resource to estimate sex, particularly the tooth 15. The 95% CI values did not overlap in the MD and BL measurements, which may be useful in sex determination. The CI values in the tooth 34 did not overlap concerning the BL length but did for the MD length. Hence, the tooth 34 was not found to be as much dimorphic as the tooth 15.

Due to the positioning of premolars in the dental arch, we found some difficulty in positioning the digital caliper for measurement. However, the findings of this study can be considered significant and satisfactory as the more instruments are available the more reliable and accurate human identification becomes. Accordingly, these tools may speed up the investigational process while providing more efficient responses to support the Court of Justice. Further studies are needed to ensure the validity of these measures for sex differentiation.

It may be concluded that male premolars presented bigger dimensions than female ones. Upper and lower second premolars were found to have significant sex dimorphism when compared to first premolars. The tooth 15 has the greatest potential for sex dimorphism, which could be utilized for human identification in sex determination based on MD (females: 6.40 to 6.63; males: 6.64 to 6.89) and BL (females: 9.28 to 9.54; males: 9.56 to 9.88) measurement.

ACKNOWLEDGMENTS

The authors would like to thank the Coordination for the Improvement of Higher Education Personnel (CAPES) for financial support.

REFERENCES

1. Vanrell J. Legal dentistry and forensic anthropology. 1ª ed. Rio de Janeiro: Guanabara Koogan S.A. 2009.
2. Tornavoi DC, Silva RHA. Palatal rugae and applicability in human identification in forensic dentistry: literature review. Saúde, Ética & Justiça. 2010 Feb 15(1):28-34. doi: http://dx.doi.org/10.11606/issn.2317-2770.v15i1p28-34
3. Terada ASSD, Leite NLP, Silveira RCP, Secchieri JM, Guimarães MA, Silva RHA. Human identification in forensic dentistry from a photographic record of smile: a case report. Rev Odontol UNESP Araraquara. 2011 Jul/Aug 40(4):199-202.
4. França GV. Legal Medicine. 11ª ed. Rio de Janeiro: Guanabara Koogan S.A. 2017.
5. Lima LNC, Oliveira OF, Sassi C, Picapedra A, Francesquini Júnior L, Daruge Júnior E. Sex determination by linear measurements of palatal bones and skull base. J Forensic Odontostomatol. 2012 Jul 30(1):38-44.
6. Sassi C, Picapedra A, Lima LNC, Francesquini Júnior L, Daruge E, Daruge Júnior E. Sex determination in Uruguayans by odontometric analysis. Braz J Oral Sci. 2012 Jul/Sep 11(3):381-386.
7. Daruge E, Daruge Júnior E, Francesquini Júnior L. Treaty of Legal Dentistry and Deontology. 1ª ed. Rio de Janeiro: Guanabara Koogan. 2017.
8. Vodanovic M, Demo } ´, Njemirovskij V, Keros J, Brkic H. Odontometrics: A useful method for sex determination in an archaeological skeletal population?. J Archaeol Sci. 2007 Jun 34(6):905–13. doi: https://doi.org/10.1016/j.jas.2006.09.004.
9. Kapila K, Nagesh KS, Iyengar AR, Mehkri S. Sexual Dimorphism in Human Mandibular Canines: A Radiomorphometric Study in South Indian Population. J Dent Res Dent Clin Dent Prospect. 2011 Jun 5(2):51-54. doi: 10.5681/joddd.2011.011
10. Costa YTF, Lima LNC, Rabello PM. Analysis of canine dimorphism in the estimation of sex. Braz J Oral Sci. 2012 Jul/Sep 11(3):406-410.
11. Rastogi P, Jain A, Kotian S, Rastogi S. Sexual Dimorphism - An Odontometric Approach. Anthropol. 2013 1(2):1-4. doi: 10.4172/2332-0915.1000104
12. Shankar S, Anuthama K, Kruthika M, Kumar VS, Ramesh K, Jaheerdeen A, et al. Identifying sexual dimorphism in a paediatric South Indian population using stepwise discriminant function analysis. J Forensic Leg Med. 2013 Aug 20(6):752-756. doi: 10.1016/j.jflm.2013.04.009
13. Zorba E, Moraitis K, Manolis SK. Sexual dimorphism in permanent teeth of modern Greeks. Forensic Sci Int. 2011 Jul 210(1-3):74–81. doi: 10.1016/j.forsciint.2011.02.001
14. Hattab F, Khateeb S, Sultan I. Mesiodistal crown diameters of permanent teeth in Jordanians. Arch Oral Biol. 1996 Jul 41(7):641–645.
15. Lund H, Mornstad H. Gender determination by odontometrics in a Swedish population. J Forensic Odontostomatol. 1999 Dec 17(2):30–34.
16. Khan SH, Hassan GS, Rafique T, Hasan N, Russell SH. Mesiodistal Crown Dimensions of Permanent Teeth in Bangladeshi Population. BSMMU J. 2011 4(2):81-87. doi: https://doi.org/10.3329/bsmmuj.v4i2.8635.
17. Acharya AB, Mainali S. Univariate sex dimorphism in the Nepalese dentition and the use of discriminant functions in gender assessment. Forensic Sci Int. 2007 Nov 173(1):47–56. doi: 10.1016/j.forsciint.2007.01.024
18. Garn SM, Lewis AB, Swindler DR, Kerewsky RS. Genetic Control of Sexual Dimorphism in Tooth Size. J Dent Res. 1967 Sep/Oct 46(5):963-972.

INFLUENCE OF THREE TREATMENT PROTOCOLS FOR DENTAL FLUOROSIS IN THE ENAMEL SURFACE: AN IN VITRO STUDY

Rodrigo Barros Esteves **Lins**[1], Ana Karina Maciel de **Andrade**[2], Rosângela Marques **Duarte**[2], Sônia Saeger **Meireles**[2]*

[1]Department of Restorative Dentistry, Piracicaba Dental School, University of Campinas, Piracicaba, SP, Brazil.
[2]Department of Restorative Dentistry, Federal University of Paraíba, João Pessoa, PB, Brazil.

Palavras-chave: Fluorose Dentária. Esmalte Dentário. Clareamento Dental.

RESUMO

Introdução: A fluorose dentária é uma alteração do esmalte caracterizada por manchas opacas causadas pela alta exposição aos íons fluoreto durante o desenvolvimento dentário. **Objetivo**: Este estudo *in vitro* objetivou avaliar mudanças na superfície do esmalte em dentes humanos hígidos após três protocolos de tratamento para a fluorose dentária: microabrasão com ácido fosfórico a 37% e pedra-pomes, clareamento caseiro com peróxido de carbamida a 10% e a associação destas técnicas. **Métodos**: Trinta e oito espécimes (5×5×2 mm) com superfície em esmalte foram obtidos a partir de 19 terceiros molares, sendo que dois não receberam tratamento e, trinta e seis foram randomizados em três grupos (n= 12): MAB- microabrasão do esmalte; CP10- clareamento caseiro; e MAB+CP10- associação destas técnicas. A rugosidade superficial e microdureza foram realizadas antes e após os protocolos de tratamento. Dois espécimes representativos de cada grupo foram avaliados por microscopia eletrônica de varredura (MEV). A análise de variância e teste de Tukey foram utilizados para análise dos resultados (p< 0,05). **Resultados**: Todos os protocolos de tratamento promoveram um aumento da rugosidade superficial do esmalte (p< 0,02). MAB e MAB+CP10 mostraram um aumento significativo da microdureza do esmalte (p< 0,04), enquanto que CP10 mostrou uma menor microdureza comparado ao MAB e ao MAB+CP10 (p< 0,05). As imagens de MEV demonstraram uma superfície mais lisa do MAB e MAB+CP10 e um padrão irregular do esmalte erodido para o CP10. **Conclusão**: Os protocolos testados para tratamento da fluorose dentária testados modificaram significativamente a rugosidade, microdureza e micromorfologia do esmalte.

Keywords: Dental Fluorosis. Dental Enamel. Tooth Bleaching.

ABSTRACT

Introduction: Dental fluorosis is an enamel alteration characterized with opaque stains caused by high exposures to fluoride during the dentition development. **Aim**: This *in vitro* study aimed to evaluate changes in the enamel surface of sound human teeth after three treatment protocols for dental fluorosis: microabrasion with 37% phosphoric acid and pumice, home bleaching with 10% carbamide peroxide, and a combination of these techniques. **Methods**: Thirty-eight specimens (5×5×2 mm) with enamel surface were obtained from 19 third molars. Thirty six specimens were randomized into three treatment groups (n= 12): MAB- enamel microabrasion; CP10- home bleaching; MAB+CP10- a combination of these techniques and two specimens not received treatment. Surface roughness and microhardness analyses were performed before and after treatment protocols. Two representative specimens from each group were evaluated by scanning electron microscopy (SEM). Analysis of variance and Tukey's tests were used for data analysis (p< 0.05). **Results**: All treatment protocols promoted an increased in enamel surface roughness (p< 0.02). MAB and MAB+CP10 showed a significant increase in the enamel microhardness (p< 0.04), while CP10 showed a microhardness lower than MAB and MAB+CP10 (p< 0.05). SEM images demonstrated a smoother surface from MAB and MAB+CP10 and, an irregular pattern of enamel erosion from CP10. **Conclusions**: The treatment protocols for dental fluorosis tested significantly changed the enamel roughness, microhardness and micromorphology.

Submitted: February 11, 2019
Modification: April 17, 2019
Accepted: April 22, 2019

***Correspondence to:**
Sônia Saeger Meireles
Address: Department of Restorative Dentistry, Federal University of Paraíba, Campus I, Castelo Branco, Zip code: 58059-900, João Pessoa, Paraíba, Brazil
Telephone number: +55 (83) 3216-7250
E-mail: soniasaeger@hotmail.com

INTRODUCTION

Dental fluorosis is an enamel alteration caused by successive exposures to high concentrations of fluoride during the period of permanent dentition development.[1,2] The severity of fluorosis varies according to the quantity of fluoride intake, time of exposure, and the stage of the amelogenesis, as well as being related to lifestyle.[3] Clinically, fluorosis is characterized by the presence of bilateral, diffuse, white and opaque stains that run horizontally across the enamel.[4] Another characteristic of this pathology is the presence of symmetry; homologous teeth tend to be affected.[3,5]

The occurrence of severe dental fluorosis compromises the appearance and aesthetics of teeth, causing embarrassment and difficulties to smile.[4] In addition, facial harmony plays important social and psychological roles in the individual's quality of life and social relationships.[4] This intrinsic condition can be treated by conservative methods, such as polishing, enamel microabrasion, dental bleaching, or the combination of these techniques. However, more invasive methods are also used, such as veneers in composite resin or porcelain, or ceramic crowns in the most severe cases.[6,7]

The microabrasion technique was first presented by Croll and Cavanaugh[8] (1986), who successfully removed opaque white stains from enamel using 18% hydrochloric acid and pumice under pressure with a wooden spatula.[6] Mondelli et al[9]. (1995) proposed a modified microabrasive technique, replacing the 18% hydrochloric acid from 37% phosphoric acid and pumice.[10] This technique is an aesthetic and conservative procedure for removal a thin layer of stains or defects localized in enamel surface by the action of abrasive agents, mechanical abrasion and, the acid penetration in the organic portion of tooth enamel. Other advantages of this technique is the availability of phosphoric acid in dental offices due to its common use in adhesive procedures and the reduced risks of accidental exposure compared to hydrochloric acid.[2,11,12]

Tooth bleaching techniques can be performed at home, where the patient uses low concentrations of carbamide (10–22%) or hydrogen peroxide (up to 14%) in custom trays or, in dental offices, where a professional can apply higher concentrations of hydrogen (15–38%) or carbamide peroxide (30–37%)[13] in the teeth surface. Additionally, 10% carbamide peroxide is the only bleaching gel considered safe, and that has received the American Dental Association (ADA) seal of approval.[14]

The treatment for dental fluorosis frequently associate tooth bleaching to enamel microabrasion in order to promote whiter and more uniform teeth, as well as reducing the contrast between the white stain lesions and the tooth surface around the stains.[15] This associated technique with 10% carbamide peroxide supervised home bleaching is the choice for treating white stains caused by fluorosis, showing excellent aesthetic results through a conservative treatment.[6,16] Thus, the aim of this *in vitro* study was to evaluate the changes in the roughness, microhardness, and micromorphology of the human enamel surface submitted to three treatment protocols for dental fluorosis: microabrasion with 37% phosphoric acid and pumice, home bleaching with 10% carbamide peroxide or the association of these techniques.

MATERIALS AND METHODS

Ethical considerations

This study was approved by the local Ethics and Research Committee of the Federal University of Paraíba, Brazil under protocol number 446/10 and Certificate of Ethics Appraisal (CAAE) number 0371.0.126.000-10.

Selection and preparation of specimens

Nineteen third molars donated by the Human Teeth Bank from Federal University of Paraíba (UFPB) were used. Teeth were examined under 40x amplification to detect cracks or defects and, those without structural defects were used in this study. Teeth were stored in 0.5% thymol solution (pH 7.0) at 4°C until beginning the experiment.

Roots were sectioned at cemento-enamel junction using a double-face diamond disc (EXTEC Corp., Enfield, CT, USA) and crowns were longitudinally sectioned into two equal enamel blocks using a low-speed diamond-edge saw under refrigeration (Labcut 1010, EXTEC Corp., Enfield, CT, USA). Thirty eight enamel blocks were obtained and the dimensions of each of them (5x5x2 mm) were measured with a digital calliper (resolution 0.01mm) (500-144B, Mitutoyo Corp., Japan). The enamel blocks were embedded in acrylic resin such that the enamel surface faced upward.

The enamel surface of the specimens were ground flat using water-cooled abrasive well in a sequence of 600 and 1200- grit silicon carbide papers in order to obtain a flat surface. Polishing was finalized with medium-grain diamond paste (Diamondac I, FGM Dental Products, Joinville, SC, Brazil) associated with felt discs (Diamond, FGM Dental Products, Joinville, SC, Brazil). Specimens were stored in distilled water at 37°C until beginning the treatments.

Randomization and treatment

Thirty-six enamel blocks were randomized into three treatment groups (n= 12): enamel microabrasion-(MAB); tooth bleaching with 10% carbamide peroxide-(CP10) and the association of both techniques- (MAB+CP10). Two

specimens were not treated and were used as a control group for scanning electron microscopy.

Specimens from MAB performed the microabrasion technique using a layer of microabrasive paste (approximately 2.0 mm) with equal parts of 37% phosphoric acid (Condac 37%, FGM Dental Products, Joinville, SC, Brazil) and ultrafine pumice (SS White LTDA; Rio de Janeiro, RJ, Brazil). A rubber cup (Microdont, KG Sorensen, Cotia, SP, Brazil) mounted on a slow-speed handpiece with a 10:1 gear reduction was used to abrade lightly the specimen surface. Paste excess was removed with sterile gauze and the specimens were rinsed for 20 s. This procedure was repeated 12 times, 10 s each, in a single treatment session. After applications, the abraded surface was polished with felt discs (Diamond, FGM Dental products, Joinville, SC, Brazil) and diamond paste (Diamond Excel, FGM Dental products, Joinville, SC, Brazil). Then, the treated specimens were rinsed, dried and stored in artificial saliva solution at 37°C (Phosphate potassium dibasic 4.35 g/L, Phosphate potassium monobasic 3.2 g/L, 70% Sorbitol, Sodium fluoride 0.044g/L, Potassium fluoride 0.62 g/L, Sodium chloride 5.85 g/L, Magnesium chloride 0.14 g/L, Calcium chloride 0.16 g/L, Sodium benzoate 5.0 g/L, Carboxymethycellulose 5.0 g/L in 1000 mL distilled water, pH 7.0)[17] during a week until start the surface roughness and microhardness tests.

Specimens from CP10 performed home bleaching with 10% carbamide peroxide (Whiteness Perfect 10%, FGM Dental products, Joinville, SC, Brazil). Custom trays were fabricated for each specimen using a 1-mm thick acetate plaque (FGM Dental products, Joinville, SC, Brazil) and a vacuum-formed process (Plastvac P7, Bioart, São Carlos, SP, Brazil). Bleaching agent was maintained in contact with specimen surface 4h/day during two weeks. After each time of application, bleaching gel was removed with air water spray for 30 s, cleaned, polished with felt discs, and polishing paste. The specimens were stored in artificial saliva at 37°C until next application.

The MAB+CP10 group performed both treatment techniques. However, home bleaching starts a week after the end of enamel microabrasion. The application of microabrasive paste with phosphoric acid and ultrafine pumice was performed during 10 seconds and repeated 12 times in a single treatment session; then the specimens were rinsed, polished with felt discs and diamond paste and stored in artificial saliva solution at 37°C for a week with daily exchanges. One week, after this procedure the bleaching treatment was performed with 10% carbamide peroxide during two weeks. At the end of the treatment protocols, specimens were stored in artificial saliva at 37°C during a week until beginning experimental tests. Three bleaching agent tubes and the phosphoric acid and pumice used in this study were randomly chosen for pH measurements with a digital pHmeter (Hanna Instruments, Woonsocket, RI, USA) (Table 1). Product specifications are listed in Table 2.

***Table 1**: Means and standard deviations for pH of different treatment groups.*

Product	pH
10% Carbamide peroxide	5.82 (0.03)[A]
37% Phosphoric acid	-0.74 (0.03)[B]
37% Phosphoric acid + Pumice	-0.07 (0.07)[B]

*Note:*Different uppercase letters in the same column represent significant difference between treatment groups (p< 0.05).*

***Table 2**: Composition and manufacturers.*

Product	Composition	Manufacturer
Condac 37%	37% Phosphoric acid, thickener, pigment and deionized water	FGM Dental products, Joinville, SC, Brazil
Extra fine Pumice	Pumice	SSWhite, São Cristovão, RJ, Brazil
Whiteness Perfect 10%	10% Carbamide peroxide, neutralized carbopol, glycol and deionized water	FGM Dental products, Joinville, SC, Brazil
Diamond Excel	Micronized diamond (2-4µm), lubricant base, thickener and emulsifier	FGM Dental products, Joinville, SC, Brazil

Surface Roughness Test

Surface Roughness (Ra) was measured using a profilometer (SJ 301 Mitutoyo, Kanagawa, Japan). Before starting the measurements, the profilometer was calibrated in a reference block (2.94 ± 0.10 µm).[11,18] For each specimen, three measurements in different directions (0h, 3h and 6h) were performed with a cutoff value of 0.25 mm and speed of 0.5 mm/s. The measurements were performed before and after treatments, obtaining the initial (Ra1) and final (Ra2) roughness means for each specimen.

Microhardness Tests

Microhardness measurements were performed with a Knoop diamond under a load of 50 g for 10 s using a microhardness tester (HMV-2, Shimadzu, Tokyo, Japan) before (T0) and after (T1) each treatment protocol. The distance from the first indentation to enamel block edge was approximately 500 µm.[19] Three indents were made on the enamel surface of each specimen at intervals of approximately 300 µm in a parallel direction and, means were transformed in Knoop Hardness Number (KHN).

Surface Morphology Analysis

Eight specimens were separated from Scanning Electron Microscope (SEM) analysis (JEOL-JSM 5600LV, Tokyo, Japan): two non-treated specimens and two from each treatment group. After gradual dehydration with ethanol (25%, 50% and 75% for 20 minutes; 95% for 30 minutes and 100% for 60 minutes), each specimen was mounted on an aluminium stub, sputter-coated with gold-palladium (BAL-TEC SCD 050, Balzers, Fürstentum, Liechtenstein) and photomicrographs of representative areas were taken at 2.000X magnifications.

Statistical Analysis

Data were statistically analyzed by paired T-test for comparison within the same treatment group and by the one-way analysis of variance (ANOVA) followed by Tukey´s *post-hoc* test for comparisons between independent groups to determine significant differences in the different periods of evaluation regarding enamel roughness surface, microhardness, and pH. Differences were considered statistically significant when $p < 0.05$.

RESULTS

Surface Roughness, Microhardness and pH assessments

The mean values for surface roughness are shown in Table 3. All treatment groups showed an increase in the enamel surface roughness after treatment protocols employed ($p < 0.03$). However, there were no significant differences for roughness between groups at baseline and one week after treatment ($p > 0.05$).

At baseline, there were no significant differences for means of microhardness between groups ($p > 0.05$). One week after treatment, while MAB and MAB+CP10 shown an increase of enamel microhardness ($p < 0.04$), it was observed a decrease of microhardness for CP10 ($p = 0.001$). Additionally, one week after treatment the values for microhardness were significantly higher from MAB and MAB+CP10 than CP10 ($p < 0.05$) (Table 4).

The means values for pH are shown in Table 1. All materials tested showed low pH and, the pH values were significantly lower from 37% phosphoric acid and the paste of 37% phosphoric acid with pumice than CP10 ($p < 0.05$).

Scanning Electron Microscopy

SEM images demonstrated different conditioning patterns of enamel surface. The enamel surface of the control samples appeared smooth in general, with some scattered clear scrapes due to the polishing procedure (Figure 1). Groups MAB and MAB+CP10 showed a smoother enamel surface, where prism endings were more (MAB) or less (MAB+CP10) evident (Figures 2 and 3). Bleaching with CP10 resulted an irregular pattern of enamel erosion, which resemble a type I acid-etching pattern (Figure 4).

***Table 3**: Mean and standard deviations of surface roughness (µm).*

Treatment Group (n= 12)	Surface Roughness		p within group
	Baseline	After treatment	
I- Microabrasion	0.14 (0.03)^{A}	0.19 (0.07)^{A}	0.02
II- Home bleaching	0.13 (0.02)^{A}	0.18 (0.05)^{A}	0.02
III- Associated techniques	0.12 (0.03)^{A}	0.15 (0.04)^{A}	0.03

**Different uppercase letters in the same column represent significant difference between treatment groups ($p < 0.05$).*

***Table 4**: Mean and standard deviations of microhardness (KHN).*

Treatment Group (n= 12)	Microhardness		p within group
	Baseline	After treatment	
I- Microabrasion	274.5 (43.6)[A]	337.5 (28.1)[A]	0.002
II- Home bleaching	267.0 (49.7)[A]	166.3 (51.1)[B]	0.001
III- Associated techniques	270.8 (66.8)[A]	328.8 (21.6)[A]	0.04

*Note: *Different uppercase letters in the same column represent significant difference between treatment groups (p< 0.05).*



***Figure 1**: Enamel surface without treatment (control group) (2000x).*



***Figure 2:** Enamel surface treated with microabrasion with 37% phosphoric acid and pumice (2000x).*



***Figure 3:** Enamel surface treated with microabrasion associated to home bleaching (2000x).*



***Figure 4:** Enamel surface treated with home bleaching with 10% carbamide peroxide (2000x).*

DISCUSSION

Microabrasive procedures are considered conservative options for treating dental fluorosis, removing a thin layer of the enamel surface.[6,11,12,20] A microabrasive paste with 37% phosphoric acid and pumice has become a popular procedure due to its low cost, availability in dental offices, and lower aggressiveness compared to hydrochloric acid.[11,12] Studies have reported that this paste is effective in reducing fluorosis stains with minimal dental structure damage.[20-22] However, once that microabrasion removes enamel structure, causing teeth to become yellowish, the association of this technique with tooth bleaching is indicated to promote uniformity of teeth color.[22] A randomized clinical trial that evaluated the acceptability and efficacy of two treatment protocols for dental fluorosis reported that both

microabrasion (37% phosphoric acid and pumice) or the association of this technique with home bleaching (10% carbamide peroxide) were effective in reducing fluorosis stains, but in the associated technique the patients reported a major satisfaction with dental appearance.[6]

All treatment protocols performed in this study resulted in increase of enamel surface roughness.[11,12,23] The increase of roughness after microabrasion with phosphoric acid and pumice may be associated to the selective pattern of conditioning induced by the acid, which promotes a lower decalcification, leaving a surface more granular and irregular.[12] The microabrasive paste application promotes the compaction of mineralized tissue inside the organic area of the enamel due to simultaneous action of abrasion and acid erosion over prims.[10] Additionally, studies reported that some materials used for polishing the enamel as silicone tip (40µm) or aluminum oxide discs (14 µm-5 µm) reduce the surface roughness that was previously increased by microabrasion and it may be associated to the type of microabrasive used.[10,12,24] In this study, the use of 37% phosphoric acid with pumice promote a greater depth of demineralization and possibly the granulation of the diamond paste (2-4µm) used for polishing enamel was not able to reduce the extensive area demineralized by acid.

Studies have reported that bleaching gels with low concentrations of carbamide peroxide caused a significant increase in enamel surface roughness.[13,25,26] One reason for this may be the increasing of contact time of low concentrated bleaching gels with tooth surface, which promoted surface changes in concentration of ions calcium and phosphate, degradation of organic matrix, erosion, porosities, and depressions.[25,27] The gel used in this study was maintained in contact with enamel surface 4 hours/ day during two weeks. Additionally, the gel contains carbopol as thickening agent which has been suggested that can also adversely affect dental enamel.[25] Other studies did not detect alterations in the enamel surface roughness after treatments with 10% carbamide or 3.6%, 7.5% and 38% hydrogen peroxide.[17,28-30] A study that evaluated the effects of 7.5 and 13.5% hydrogen peroxide (HP) and 35% carbamide peroxide (CP) on the enamel surface reported that the exposition to an acidic CP bleaching agent (pH= 4.9) resulted in higher surface roughness compared to a mild (pH= 6.1) or alkaline (pH= 10.8) HP bleaching agents.[26] Furthermore, the topical application of fluoride on the enamel surface after bleaching with 35% HP prevented the increase of tooth enamel roughness.[31]

Groups treated with microabrasion or the associated technique with home bleaching showed an increase of enamel microhardness. The superficial abrasion of enamel after microabrasive treatments causes compression of mineralized tissue whitin the organic region´s of enamel, replacing the outer region free of prisms. Thus, the acidic and abrasive action of microabrasive compound probably modify the enamel prismatic structures, allowing the compressed mineral products to stay on the periphery, promoting the increase of microhardness.[23] Addictionaly, after microabrasive procedure, specimens were polished with felt discs and diamond paste and, studies reported that the increasing of microhardness after polishing occurs due to the compation of micronized diamond present in the diamond paste.[10,23] These findings are in agreement with our SEM data, where we could observe an enamel surface with a smoother and dense aspect after enamel microabrasion or with the associated technique. However, studies reported that topical application of fluoride after bleaching or microabrasive procedures can promote remineralisation due to calcium-phospate precipitation inside the porous enamel and increase the enamel hardness.[12,31,32]

The group treated with 10% carbamide peroxide showed a decrease of enamel microhardness. Several aspects related to bleaching agents might influence the enamel surface microhardness, such as peroxide concentration, time of application, pH or the incorporation of fluoride in bleaching agents.[25,32-35] The bleaching agent used has a pH of 5.8 and this pH could not have contributed significantly to enamel demineralization. One possible factor that may have contributed to the reduction of enamel microhardness was the contact time of fluoride free bleaching gel with enamel surface which may have disrupted the balance between demineralization caused by the bleaching agent and the remineralization caused by artificial saliva.[27,33,34] These findings are in agreement with our SEM analyses, where was observed an irregular surface with depressions, porosity, and increased depth of enamel grooves.[13] Other studies also observed these alterations and the enamel microhardness decrease when low carbamide peroxide (10 or 15%) concentrations were used for long treatment times.[25,27,33,34] Additionally, the *in situ* effects of low concentrated bleaching agents on human enamel surface demonstrated no morphologic or chemical changes. This may be attributed to the protective effects of saliva, which provided dilution, buffering capacity, and supply Ca and P ions for tooth remineralization.[13,30] However, when the specimens were stored in artificial saliva after bleaching with 38% hydrogen peroxide, the remineralization was not sufficient to restore tooth enamel microhardness.[17]

Within the clinical significance of this study was the evidence that the enamel microhardness and surface roughness were altered when protocols for treat dental

fluorosis were used. Thus, it is necessary to performed further *in vitro* or *in situ* studies using teeth with dental fluorosis in order to compare the surface properties of fluorotic enamel after microabrasive procedures. Addicitonaly, randomized clinical trials are necessary to compare the efficacy, safety and the remineralization effect of human saliva in the techniques available for dental fluorosis treatment.

CONCLUSIONS

Within the limitations of this *in vitro* study, it was concluded that the treatment protocols for dental fluorosis tested significantly changed the enamel roughness, microhardness and micromorphology.

REFERENCES

1.Moimaz SA, Saliba O, Marques LB, Garbin CA, Saliba NA. Dental fluorosis and its influence on children's life. Braz Oral Res. 2015;29. pii: S1806-83242015000100214. doi: 10.1590/1807-3107BOR-2015.vol29.0014.

2.Bassir MM, Rezvani MB, Ghomsheh ET, Hosseini ZM. Effect of Different Surface Treatments on Microtensile Bond Strength of Composite Resin to Normal and Fluorotic Enamel After Microabrasion. J Dent (Tehran). 2016 Nov;13(6):431-437.

3.García-Pérez Á, Irigoyen-Camacho ME, Borges-Yáñez SA, Zepeda-Zepeda MA, Bolona-Gallardo I, Maupomé G. Impact of caries and dental fluorosis on oral health-related quality of life: a cross-sectional study in schoolchildren receiving water naturally fluoridated at above-optimal levels. Clin Oral Investig. 2017 Mar 1. doi: 10.1007/s00784-017-2079-1.

4.Molina-Frechero N, Nevarez-Rascón M, Nevarez-Rascón A, González-González R, Irigoyen-Camacho ME, Sánchez-Pérez L, et al. Impact of Dental Fluorosis, Socioeconomic Status and Self-Perception in Adolescents Exposed to a High Level of Fluoride in Water. Int J Environ Res Public Health. 2017 Jan 12;14(1). pii: E73. doi: 10.3390/ijerph14010073.

5.Joshi N, Palaskar J, Joshi M, Kathariya R. Complete oral rehabilitation in a case with severe dental fluorosis. World J Clin Cases. 2014 Dec 16;2(12):938-42. doi: 10.12998/wjcc.v2.i12.938.

6.Castro KS, Ferreira AC, Duarte RM, Sampaio FC, Meireles SS. Acceptability, efficacy and safety of two treatment protocols for dental fluorosis: a randomized clinical trial. J Dent. 2014 Aug;42(8):938-44. doi: 10.1016/j.jdent.2014.01.011.

7.Bezerra-Júnior DM, Silva LM, Martins L de M, Cohen-Carneiro F, Pontes DG. Esthetic rehabilitation with tooth bleaching, enamel microabrasion, and direct adhesive restorations. Gen Dent. 2016 Mar-Apr;64(2):60-4.

8.Croll TP, Cavanaugh RR. Enamel color modification by controlled hydrochloric acid-pumice abrasion. I. technique and examples. Quintessence Int. 1986 Feb;17(2):81-7.

9.Mondelli, J, Mondelli RFL, Bastos MTAA, Franco EB. Microabrasão com ácido fosfórico. Rev Bras Odontol. 1995 mai./jun; 52(3): 20-22.

10.Bertoldo C, Lima D, Fragoso L, Ambrosano G, Aguiar F, Lovadino J. Evaluation of the effect of different methods of microabrasion and polishing on surface roughness of dental enamel. Indian J Dent Res. 2014 May-Jun;25(3):290-3. doi: 10.4103/0970-9290.138308.

11.Meireles SS, Andre Dde A, Leida FL, Bocangel JS, Demarco FF. Surface roughness and enamel loss with two microabrasion techniques. J Contemp Dent Pract. 2009 Jan 1;10(1):58-65.

12.Pini NI, Sundfeld-Neto D, Aguiar FH, Sundfeld RH, Martins LR, Locadino JR, et al. Enamel microabrasion: An overview of clinical and scientific considerations. World J Clin Cases. 2015 Jan 16;3(1):34-41. doi: 10.12998/wjcc.v3.i1.34. Review.

13.Alqahtani MQ. Tooth-bleaching procedures and their controversial effects: A literature review. Saudi Dent J. 2014 Apr;26(2):33-46. doi: 10.1016/j.sdentj.2014.02.002.

14.American Dental Association (ADA). Consumer products with the ADA Seal of Acceptance. Available in: <http://www.ada.org/ada/seal/adaseal_consumer_shopping.pdf2016>. Access in: 29 mar. 2017.

15.Bertassoni LE, Martin JM, Torno V, Vieira S, Rached RN, Mazur RF. In-office dental bleaching and enamel microabrasion for fluorosis treatment. J Clin Pediatr Dent. 2008 Spring;32(3):185-7.

16.Yildiz G, Celik EU. A minimally invasive technique for the management of severely fluorosed teeth: A two-year follow-up. Eur J Dent. 2013 Oct;7(4):504-8. doi: 10.4103/1305-7456.120661.

17.Franco LM, Machado LS, Salomão FM, Dos Santos PH, Briso AL, Sundfeld RH. Surface effects after a combination of dental bleaching and enamel microabrasion: An in vitro and in situ study. Dent Mater J. 2016;35(1):13-20. doi: 10.4012/dmj.2014-334.

18.Pachaly R, Pozzobon RT. Analysis of surface roughness of human enamel exposed to bleaching agent and submitted to brushing. Acta Odontol Latinoam. 2012;25(1):59-66.

19.Pinto CF, Oliveira Rd, Cavalli V, Giannini M. Peroxide bleaching agent effects on enamel surface microhardness, roughness and morphology. Braz Oral Res. 2004 Oct-Dec;18(4):306-11.

20.Ahmadi Zenouz G, Ezoji F, Enderami SA, Khafri S. Effect of Fluoride, Casein Phosphopeptide-Amorphous Calcium Phosphate and Casein Phosphopeptide-Amorphous Calcium Phosphate Fluoride on Enamel Surface Microhardness After Microabrasion: An in Vitro Study. J Dent (Tehran). 2015 Oct;12(10):705-11.

21.Celik EU, Y1´ld1´z G, Yazkan B. Comparison of enamel

microabrasion with a combined approach to the esthetic management of fluorosed teeth. Oper Dent. 2013 Sep-Oct;38(5):E134-43. doi: 10.2341/12-317-C. Epub 2013 Feb 7.

22.Higashi C, Dall'Agnol AL, Hirata R, Loguercio AD, Reis A. Association of enamel microabrasion and bleaching: a case report. Gen Dent. 2008 May;56(3):244-9.

23.Fragoso LS, Lima DA, de Alexandre RS, Bertoldo CE, Aguiar FH, Lovadino JR. Evaluation of physical properties of enamel after microabrasion, polishing, and storage in artificial saliva. Biomed Mater. 2011 Jun;6(3):035001. doi: 10.1088/1748-6041/6/3/035001.

24.Rodrigues MC, Mondelli RF, Oliveira GU, Franco EB, Baseggio W, Wang L. Minimal alterations on the enamel surface by micro-abrasion: in vitro roughness and wear assessments. J Appl Oral Sci. 2013 Mar-Apr;21(2):112-7. doi: 10.1590/1678-7757201302117.

25.Melo CF, Manfroi FB, Spohr AM. Microhardness and roughness of enamel bleached with 10% carbamide peroxide and brushed with different toothpastes: an in situ study. J Int Oral Health. 2014 Jul;6(4):18-24.

26.Azrak B, Callaway A, Kurth P, Willershausen B. Influence of bleaching agents on surface roughness of sound or eroded dental enamel specimens. J Esthet Restor Dent. 2010 Dec;22(6):391-9. doi: 10.1111/j.1708-8240.2010.00372.x.

27.Cvikl B, Lussi A, Moritz A, Flury S. Enamel Surface Changes After Exposure to Bleaching Gels Containing Carbamide Peroxide or Hydrogen Peroxide. Oper Dent. 2016 Jan-Feb;41(1):E39-47. doi: 10.2341/15-010-L.

28.Abouassi T, Wolkewitz M, Hahn P. Effect of carbamide peroxide and hydrogen peroxide on enamel surface: an in vitro study. Clin Oral Investig. 2011 Oct;15(5):673-80. doi: 10.1007/s00784-010-0439-1.

29.Smidt A, Feuerstein O, Topel M. Mechanical, morphologic, and chemical effects of carbamide peroxide bleaching agents on human enamel in situ. Quintessence Int. 2011 May 42(5): 407–12.

30.Nascimento WC, Gomes Ydo S, Alexandrino LD, Costi HT, Silva JO Jr, Silva CM. Influence of fluoride concentration and pH Value of 35% hydrogen peroxide on the hardness, roughness and morphology of bovine enamel. J Contemp Dent Pract. 2014 Jul 1;15(4):392-8.

31.Dionysopoulos D, Koliniotou-Koumpia E, Tolidis K, Gerasimou P. Effect of fluoride treatments on bleached enamel microhardness and surface morphology. Oral Health Prev Dent. 2017;15(2):169-175. doi: 10.3290/j.ohpd.a37929.

32.George L, Baby A, Dhanapal TP, Charlie KM, Joseph A, Varghese AA. Evaluation and comparison of the microhardness of enamel after bleaching with fluoride free and fluoride containing carbamide peroxide bleaching agents and post bleaching anticay application: An in vitro study. Contemp Clin Dent. 2015 Sep;6(Suppl 1):S163-6. doi: 10.4103/0976-237X.166835.

33.Moosavi H, Darvishzadeh F. The Influence of Post Bleaching Treatments in Stain Absorption and Microhardness. Open Dent J. 2016 Mar 25;10:69-78. doi: 10.2174/1874210616021000069.

34.Araujo NC, da Costa Soares MU, Nery MM, Sales WS, Gerbi ME. Effect of pH values of two bleaching gels on enamel microhardness. Gen Dent. 2013 Jul;61(4):55-8.

SURFACE MICROHARDNESS OF DIFFERENT RESTORATIVE MATERIALS EXPOSED TO CANDIDA ALBICANS BIOFILM ISOLATED FROM THE ORAL CAVITY OF HIV-INFECTED CHILDREN

Leandro **Costa**[1], Larissa Soares-**Silva**[1], Paulini Malfei de C. **Costa**[2], Adrielle **Mangabeira**[3], Maristela **Portela**[4], Gloria Fernanda **Castro**[1*]

[1]Department of Pediatric Dentistry and Orthodontics College of dentistry at Universidade Federal do Rio de Janeiro, Rio de Janeiro, RJ, Brazil.
[2]Department of Social Dentistry at Faculdades São José, Rio de Janeiro, RJ, Brazil.
[3]Assistant Professor of Pediatric Dentistry at the União Metropolitana da Educação e Cultura (UNIME), Salvador, Bahia, Brazil.
[4]Department of clinic and pediatric dentistry at the dentistry school at Universidade Federal Fluminense, Niteroi, RJ, Brazil.

Palavras- Chave: Candida Albicans. Biofilme. HIV.

RESUMO

Introdução: A *Candida albicans* é um dos microorganismos que mais frequentemente colonizam a cavidade bucal de crianças HIV+. Este fungo excreta ácidos, proporcionando uma diminuição do pH em um ambiente já altamente acidificado, como cavidade bucal dessas crianças devido sua dieta hipercalórica, uso de medicamentos açucarados e higiene oral deficiente. Considerando a elevada freqüência de restaurações dentárias em função da alta prevalência de cárie, todos esses fatores, incluindo o metabolismo da *C. albicans,* podem provocar alterações na superfície de materiais restauradores usados nesses pacientes. **Objetivo**: O objetivo do estudo foi avaliar, in vitro, a ação da *C. albicans,* isolada de uma criança HIV+, sobre a superfície de materiais restauradores utlizados na prática odontopediátrica. **Material e método**: Confeccionou-se 44 blocos de diferentes materiais (2 resinas, 1 compômero e 1 cimento ionomérico de Vidro) separados em 4 grupos (n=11) Todos os blocos foram submetidos a microdureza superfícial inicial (MDI). Posteriormente, foram expostos ao biofilme de *C. albicans* formado a partir de 1mL de uma suspensão padronizada contendo 10^5 cels/mL, durante 07 dias. Após, os blocos foram limpos e mantidos sob refrigeração (4ºC) e submetidos à mensuração da microdureza final (MDF). Foram utilizados o Teste de Mann-Whitney para comparação intra grupo entre os valores de MDI e MDF; os valores de perda percentual de microdureza (%PMD) foram comparados com o Teste de Kruskall-Wallis (95% IC). **Resultados**: Os valores de MDI variaram de 63,54±11,41 a 77,92±10,91, sem diferença entre os grupos (p=0,076). Após exposição ao biofilme, não foram observadas variações significativas na microdureza (MDI X MDF) exceto para o grupo 3 (compômero Vitremer™), cujo valor de MDF foi 40,45±7,57 (p=0,001) . O %PMD do compômero (grupo 3) foi significativamente maior (41,16%) que o dos outros materiais (5,35% grupo 1; 7,02% grupo 2; e 9,57% grupo 3) (p=0,036. **Conclusão:** Conclui-se que a *C. albicans* isolada do biofilme dental de criança HIV+ pode causar, in vitro, diminuição significante na microdureza superficial do compômero em comparação aos demais.

Keywords: Candida Albicans. Biofilm. HIV.

ABSTRACT

Introduction: *Candida albicans* is one of the microrganisms that most often colonizes the oral cavity of HIV-infected children. This fungus secretes organic acids, which decrease the pH of the oral cavity; an environment that is already particularly acidic in HIV-Infected children because of their hypercaloric diets, use of sugary medicines, and poor oral hygiene. Considering the large number of dental restorations and the high prevalence of caries in this population, these conditions, including the metabolism of *C. albicans*, can potentially cause problems in terms of the surface of restorative materials. **Objective**: Therefore, the aim of this study was to evaluate, *in vitro*, the potential of *C. albicans* isolated from the dental biofilm of HIV-infected children to cause surface demineralization of the restorative materials used in pediatric dentistry. **Material and method**: Forty-four blocks of four different materials (2 resins, 1 compomer, and 1 glass ionomer cement) were made and separated into four groups (n = 11). All blocks were submitted to initial surface microhardness (ISM) analysis. Subsequently, each block was exposed to *C. albicans* biofilm, formed from a 1 mL standard suspension containing 10^5 yeasts/mL, over seven days. The blocks were then cleaned and kept at 4 °C until being submitted for measurement of the final surface microhardness (FSM). The Mann-Whitney test was used for intragroup comparisons between ISM and FSM values. **Results**: The percentage of microhardness loss (% MHL) values between the four groups were compared using the Kruskall-Wallis test (95% CI). The ISM values ranged from 63.54 ± 11.41 to 77.92 ± 10.91, with no statistical differences being found (p = 0.76). After exposure to biofilm, no significant changes in surface microhardness were observed when comparing the values of ISM and FSM, except for group 3 (compomer Vitremer™), which had an FSM value of 40.45 ± 7.57 (p = 0.001). The % MHL of the compomer (group 3) was significantly higher (41.16%) than the other groups (5.35% group 1; 7.02% group 2; and 9.57% group 3) (p = 0.036). **Conclusion**: It can be concluded that, *in vitro*, *C. albicans* isolated from the dental biofilms of HIV-infected children can cause significant reduction in the surface microhardness of compomer compared with other materials.

Submitted: February 6, 2019
Modification: April 16, 2019
Accepted: April 18, 2019

***Correspondence to:**
Gloria Fernanda Barbosa de Araújo Castro
Address: Rua Rodolpho Paulo Rocco 325, Cidade Universitária, Rio de Janeiro
Caixa Postal: 68066 – Cidade Universitária - CCS- Rio de Janeiro – RJ – Brasil
Zip code: 21941-971
Telephone number: +55 (21) 39382101
E-mail: gfbacastro@yahoo.com.br

INTRODUCTION

Oral candidiasis (OC) is the most common oral lesion observed in HIV-infected children and may be the first clinically visible manifestation of the disease. It features three distinct clinical variations, each recognized as being associated with HIV infection: erythematous, pseudomembranous, and angular cheilitis.[1] The prevalence of OC varies from 6 to 45%, and has recently decreased because of the use of multiple anti-retrovirals in the treatment of HIV infection, such as highly active antiretroviral treatment (HAART).[2,3] The oral cavity colonization by *Candida albicans*, the main etiologic agent of OC, in Brazilian HIV-infected children treated with HAART is still very high, despite reports of a low prevalence (6.7%) of OC in these children.[4]

C. albicans excretes various organic acids, some of which are stronger than lactic acid, thus causing a decrease in the pH of the oral cavity,[5] an environment that is already particularly acidic in HIV-infected children because of their hypercaloric diets, use of sugary medicines, and poor oral hygiene.[6] Also, this fungus is a frequent constituent of dental biofilms in HIV patients, and the authors speculate that it is a supporting factor in the etiology and development of caries in such children.[7] Various studies have reported the ability of *C. albicas* biofilm to cause erosion and abrasion to dental surfaces, as a result of the loss of microhardness;[8,9] therefore, it is likely that restorative materials also suffer loss of microhardness because of the action of these microorganisms. According to Belduz et al. (2017),[10] dental restorative materials are a potential source of fungal infections and in general, *C. albicans* biofilms adhere firmly to composite and glass ionomer cements. However, fewer studies have been carried out on these materials and any little research into the effect of *Candida* biofilms on dental material surfaces is present in the literature.

Considering the high prevalence of *C. albicans* in HIV-infected children, its ability to produce a cariogenic environment associated with a high rate of caries, leading to the extensive use of restorative procedures in this population, the objective of this study was to evaluate changes to the surface microhardness of restorative materials after exposure to *Candida albicans* biofilm isolated from an HIV-infected patient.

MATERIALS AND METHODS

This *in vitro* study evaluated the potential of *C. albicans* biofilm, isolated from an HIV-infected patient, to demineralize the surface of restorative materials commonly used in pediatric dentistry. The present study was characterized as a descriptive, analytical, and laboratorial. Four restorative materials were used; two composites, one compomer, and one glass ionomer cement:

- Group 1 (composite): resin, low voltage nanofilled material, Filtek Z350 XT™, color A2D (3M Company, Minnesota, USA).
- Group 2 (composite): resin, low voltage, FiltekBulkFill™, color A2 (3M Company, Minnesota, USA).
- Group 3 (compomer): glass Ionomer resin, Vitremer™, color A3 (3M Company, Minnesota, USA).
- Group 4 (glass Ionomer cement): conventional glass ionomer, Ketac Molar Easymix® ™, color A3 (3M Company, Minnesota, USA).

Sample Preparation and Determination of Initial Surface Microhardness

A single operator made 60 blocks (15 blocks of each material) using a circular 3 x 5 mm radio device (Tabela 1). The blocks of restorative materials were prepared according to the manufacturers' recommendations. For the Z350™ and BulkFill™ composites, and the compomer Vitemer™, the same light was used for curing (DEMI, Kerr® number 910770). Later, the blocks were secured in a polypropylene device with sticky wax (Kota™ Indústria Com. Ltda., São Paulo, SP) and adapted in a metallographic polishing machine with 1200 grit sandpaper (Extec™, Connecticuti, USA), under refrigerated conditions, resulting in a glassy surface that allowed the measurement of the initial surface microhardness (ISM). At the end of the polishing stage, the specimens were immersed for in deionized water 10 minutes under the action of ultrasound (Ultrasonic Cleaner Mod USC 750™, Unique Ind. Com. Ltda Electronics, São Paulo, SP) to remove the grains produced by the polishing process.

Next, 44 blocks were chosen for further experiments and divided into 4 groups of 11 blocks each. The blocks were submitted for initial surface microhardness (ISM) analysis. Three indentations, positioned 100 µm from each other, were made at the center of the block using a diamond-tipped microdurometer Vickers under a static load of 50 g, applied for 15 seconds.[11] After this phase, the blocks were set in 24-well cell culture plates and subjected to sterilization using UV light.[12]

Exposure to *Candida albicans* Biofilm

One isolate of *C. albicans* from the dental biofilm of an HIV-infected child was randomly selected from the collection of isolates from the Paulo de Góes Microbiology Institute of the Universidade Federal do Rio de Janeiro (UFRJ), previously identified and stocked in Sabouraud medium at 4°C. Each well contained the restorative material blocks previously sterilized and 1 mL of inoculum standard cell suspension containing 10^5 yeasts/mL of *C. albicans*.[9] Prior to this, growth of the clinical isolates was induced in brain heart

infusion (BHI) liquid (BD Difco™®, Maryland, USA), while being mixed, for 48 hours at 37 °C, with the standardized cells and in BHI medium (BD Difco™®, Maryland, USA) supplemented with 20% sucrose. After the development of the biofilm, the blocks, which were already laid down in the wells, were kept for 7 days at 37 °C without agitation. During the seven days of the experiment, the medium was replaced every 48 hours, after the full seven days, the blocks were immediately cleaned with cotton and 10% formaldehyde and kept at approximately 4 °C until further evaluation.

Determination of Final Surface Microhardness

For each block of restorative material, the— same researcher who conducted the ISM readings also did the final FSM readings. Three spaced indentations were held 100 µm from the baseline.[13] The percentage of surface microhardness loss (% MHL) for all samples was calculated using the following equation:

% MHL = ISM - FSM / ISM x 100

Statistical Analyses

A database was created and data were analyzed using the statistical program SPSS, version 20.0. The Mann-Whitney test was used for comparing ISM and FSM values in each group (intragroup). The Kruskall-Wallis test was used to measure correlations between the groups by comparing % MHL. Data were considered statistically significant if analysis resulted in $p < 0.05$ at 95% CI.

RESULTS

The ISM and FSM values in Table 1 show that the ISM values were similar between groups ($p = 0.76$). After exposure to the *C. albicans* biofilm, no significant intragroup variations were observed when comparing the ISM values with the FSM values, except for the compomer (Group 3, $p = 0.00$).

Considering only the samples that exhibited mircohardness loss after exposure to *C. albicans* biofilm, there was significantly greater mircohardness loss (41.16%) of the compomer Vitremer™ (Group 3, $p = 0.036$). The other materials also presented with mircohardness loss after exposure to the C. *albicans* biofilm. The % MHL values found for Groups 1 (Z250™), 2 (BulckFill™), and 4 (KetacMolar™) were 5.35%, 9.57%, and 7.02%, respectively (Figure 1).

***Table 1**: Average of microhardness of different restorative materials before exposure (ISM) and after (FSM) exposure to the biofilm of* Candida albicans *isolated from HIV +.*

Groups (N =11)	ISM(mean ± SD)	FSM(mean ± SD)	P value Mann-Whitney
Z350™	70.29 ± 17.42	70.98 ± 13.71	NS
BulkFill™	63.54 ± 11.41	60.16 ± 9.42	NS
Vitremer™	68.83 ± 9.33 *	40.45 ± 7.57 *	**0.01**
Ketac Molar™	77.92 ± 10.84	79.43 ± 18.36	NS
P valor(Kruskall Wallis)	0.76	**0.026**	—

Note: NS = not significant; ISM = initial surface microhardness; FSM = final surface microhardness.

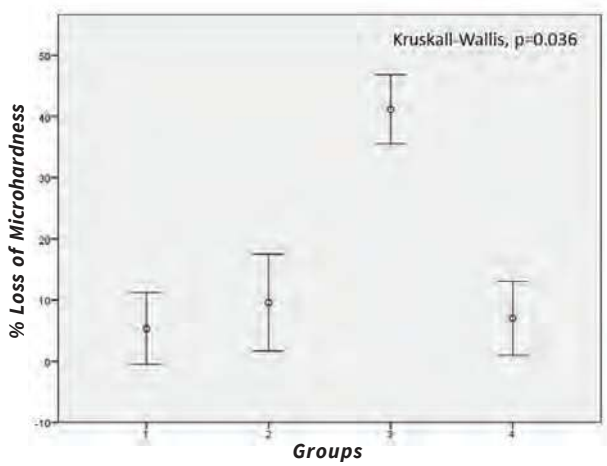

Note: Groups: 1= Z250™; 2= Bulk Fill™; 3 Vitremer™; 4= Ketac Molar™

***Figure 1**: Surface hardness loss ratio (average percentage) between the different types of restorative materials after exposure to biofilm of Candida albicans isolated from HIV+.*

DISCUSSION

The literature shows that *C. albicans* is the most common species found in the oral cavity of HIV-infected patients with a prevalence of up to 65%, whereas other species of the genus *Candida* account for less than 35% of total isolates.[4,14] Considering the role of *C. albicans* in dental caries, Oliveira et al. (2016)[7] observed a significant positive correlation between the number of early caries lesions in enamel and the number of *C. albicans* colonies in the dental biofilm of HIV-infected children. This suggests that these fungi are not only associated with the development of oral candidiasis, but also with caries disease in HIV-infected children.

Some *in vitro* studies have verified that *C. albicans* has a high cariogenic potential that gives it the ability to

dissolve hydroxyapatite and challenges the enamel surface.[8,9] Studies in mice, conducted by Klinke et al. (2011)[15] showed that *C. albicans* is able to increase the incidence of caries when added to a mixed microbiota. Considering these results, we considered it important to investigate the action of the biofilm formed by isolates of *C. albicans* from the dental biofilm of HIV-infected children on the surface of the restorative materials most commonly used in patient procedures. Since the prevalence of caries and restorations required in HIV positive patients are high,[6] the number of dental restorations that can undergo this microorganism's destructive action is significant in these patients, which is the reason for this research.

Four different materials frequently used in pediatric dentistry were selected to observe challenges in microhardness after exposure to *C. albicans* biofilm. The majority of the studies in the literature regarding *Candida* and restorative materials focus on its ability to form biofilms[10] and/or antifungal activity,[16] making this study the first to evaluate the capacity of *C. albicans* isolated from oral cavity of an HIV infected children to cause alterations in the surface of restorative materials which are most used in children.

Our results showed that *C. albicans* is able to cause microhardness loss in all the restorative materials tested in this study. However, this loss was only significant for the compomer, with the resins and the glass ionomer cement (GIC) being the best at withstanding the effects of the fungi biofilm. The resins are load restorative dental materials, which gives them greater resistance,[17] and can probably explain the low variation in microhardness loss after the fungal challenge.

With regard to the GIC, it is important to note that this material undergoes syneresis within the first 24 h after preparation. Therefore, immediately after manipulation, its surface must be protected with liquid vaseline to ensure the physical properties of the material.[18] Also, although conventional GIC has been reported to have some negative features (low wear resistance, susceptibility to breakage, structure sensitivity to moisture contamination during hardening, e.t.c),[19] its performance in our study was very good, showing reduced values of microhardness loss. Unlike the resins, the GICs are not loaded materials but they do have antimicrobial properties, which may have been an advantage during the experiment. Cosgun et al. (2019)[20] observed in a recent study, using a different glass ionomer, that when cultured with $1x10^2$ cfu/mL of micoorganisms all the restorative materials inhibited bacterial and fungal growth. It is worth noting that the compomer material has neither the same resistance of a resin nor the antimicrobial activity of conventional GICs, which may have contributed to the results found in our study, showing lower values of final superficial microhardness after *Candida* biofilm exposure. Although one study carried out by Franciscone et al. (2008)[21] observed a decrease in the surface challenges of different restorative materials after being subjected to an erosive challenge, it is interesting to note that the same restorative compomer (resinous glass ionomer Vitremer™) had the worst performance compared to the other materials (Resin Z350™, Ketac Molar™, and Resin BulkFill™). These results corroborate with the Bonifácio et al. (2009)[22] observation that surface hardness is known to negatively correlate with wear on the surface of restorative materials, with lower hardness leading to higher wear.

Regarding the limitations of this study, it was an *in vitro* study, conducted with only one isolate of *C. albicans,* with a limited number of materials, and observing only one parameter, the microhardness. Therefore, their results should be evaluated with caution because they may not fully represent true conditions. Nevertheless, they are interesting results for some observations of clinical applicability regarding the restorative treatment of children infected with HIV.

As we have shown, restorative materials of the resin and GIC types can be susceptible to the action of *Candida* spp, which may increase their chance of wear and failure, although this was mainly observed with the compomer. We may also consider that because GICs potentially reduce microleakage by attaching to the tooth structure, they also inhibit the growth of oral microorganisms that result from caries and neutralize the acids produced by these microorganism through ion release.[23,24] Therefore, the use of this material could be the best recommendation for HIV-infected children because of its beneficial antimicrobial effects in cases where protection against caries is necessary.

We conclude and point out the importance of controlling the colonization of *C. albicans* in the oral cavity of HIV-infected children, not only for the prevention of oral candidiasis, but also to control the development of caries disease and reduce the need for invasive restorative procedures To achieve this, it is necessary for patients to maintain their oral hygiene, thereby minimizing the potential for colonization of these microorganisms in the oral cavity.

REFERENCES

1. Pinheiro RS, França TT, Ribeiro CMB, Leão JC, Souza IPR de, Castro GF. Oral manifestations in human immunodeficiency virus infected children in highly active antiretroviral therapy era. J Oral Path Med 2009; 38: 613-22.
2. Leggott, PJ. Oral manifestations of HIV infection in children. Oral Surg Oral Med Oral Path and Oral Rad 1992; 73 (2): 187-92.

3. Ramos-Gomez, FJ, Hilton JF, Canchola AJ, Greenspan D, Greenspan JS, Maldonado YA. Risk factors for HIV-related orofacial soft-tissue manifestations in children. Pediatr Dent 1996; 18 (2): 121-26.
4. Cerqueira, DF, Portela MB, Pomarico L, Soares RM, de Souza IP, Castro GF. Examining dentinal carious lesions as a predisposing factor for the oral prevalence of Candida spp in HIV-infected children. J Dent Child 2007; 74 (2): 98-103.
5. Cavazana TP, Pessan JP, Hosida TY, Monteiro DR, Botazzo Delbem AC. pH changes of mixed biofilms of Streptococcus mutans and Candida albicans after exposure to sucrose solutions in vitro. Arch Oral Biol. 2018 Jun; 90: 9-12. doi: 10.1016/j.archoralbio.2018.02.019.
6. Castro GF, Souza IP, Lopes S, Stashenko P, Teles RP. Salivary IgA to cariogenic bacteria in HIV-positive children and its correlation with caries prevalence and levels of cariogenic microorganisms. Oral Microbiol Immunol. 2004 Oct; 19 (5): 281-8.
7. Rosa Oliveira CA, Charone S, de Araújo Soares RM, Portela MB, de Aráujo Castro GF. Association of *Candida* Species Isolated From the Dental Plaque of HIV-infected Children and Prevalence of Early Carious Lesions. J Dent Child (Chic). 2016 Sep; 83 (3): 139-45.
8. Charone S, Portela MB, das Chagas MS, de Araújo Soares RM, de Araújo Castro GF. Biofilm of Candida albicans from oral cavity of an HIV-infected child: challenge on enamel microhardness. Oral Surg Oral Med Oral Pathol Oral Radiol. 2013 Apr; 115 (4): 500-4. doi: 10.1016/j.oooo.2012.11.003.
9. Charone S, Portela MB, Martins KO, Soares RM, Castro GF. Role of Candida species from HIV infected children in enamel caries lesions: an in vitro study. J Appl Oral Sci. 2017 Jan-Feb; 25 (1): 53-60. doi: 10.1590/1678-77572016-0021.
10. Belduz N, Kamburoglu A, Yilmaz Y, Tosun I, Belduz M, Kara C. Evaluation of *Candida albicans* biofilm formation on various dental restorative material surfaces. Niger J Clin Pract. 2017; 20: 355-60.
11. Jafarzadeh TS, Erfan M, Behroozibakhsh M, Fatemi M, Masaeli R, Rezaei Y et al. Evaluation of Polymerization Efficacy in Composite Resins via FT-IR Spectroscopy and Vickers Microhardness Test. J Dent Res Dent Clin Dent Prospects. 2015; 9 (4): 226-32. doi: 10.15171/joddd.2015.041

MAXILLARY EXPANSION, CONSTRICTION AND PROTRACTION THROUGH FACIAL MASK TO CORRECT ANTERIOR CROSSBITE: CASE REPORT

Nayara Priscilla Pereira **Lemos**[1*], Livia Helena Lourenço Leal **Amoroso**[1], Erika Josgrilberg **Guimarães**[1], Natália Pereira de **Oliveira**[1] e Renata Pilli **Jóias**[1].

[1]Methodist University of São Paulo - Faculty of Medical Sciences and Health, SãoPaulo, SP, Brazil.

Palavras-chave: Má Oclusão. Expansão Maxilar. Mordida Cruzada.

RESUMO

Introdução: A protração maxilar associado ou não à expansão rápida da maxila (ERM) apresenta-se como terapia de escolha de maloclusão de Classe III esquelética por deficiência maxilar numa fase precoce da vida. **Objetivo:** Relatar caso clínico de expansão e constrição rápida da maxila com protração maxilar em indivíduo Classe III esquelética com dentição mista. **Relato:** Paciente com 9 anos e 3 meses de idade, maloclusão de Classe III esquelética e mordida cruzada anterior de -3mm foi tratado com expansor do tipo Hyrax, usando protocolo de expansão e constrição da maxila associada a tração reversa com máscara facial de Petit. Durante 4 dias foram realizadas expansão do disjuntor em 2/4 de volta pela manhã e constrição de 2/4 de volta pela noite. Após esse período o paciente utilizou a máscara facial com força de 500N por um período de 14 horas por dia, durante 3 meses. Alcançada a sobrecorreção a máscara foi utilizada durante o período noturno com força de 300N. **Resultados:** Observou-se sobressaliência de 2,5mm, boa relação transversal interarcos e bom perfil facial. **Conclusão:** O protocolo de expansão e constrição maxilar seguido de tração reversa com máscara de Petit foi eficaz na correção da mordida cruzada anterior de indivíduo com maloclusão de Classe III esquelética precoce por deficiência antero-posterior da maxila.

Keywords: Malocclusion. Palatal Expansion Technique. Crossbite.

ABSTRACT

Introduction: Maxillary protraction with or without rapid maxillary expansion (RME) is the therapy of choice for early skeletal Class III malocclusion caused by maxillary deficiency. **Objective:** To report a clinical case of rapid maxillary expansion and constriction with maxillary protraction in boy with skeletal Class III at mixed dentition. **Report:** A boy aged 9 years and 3 months, with skeletal Class III malocclusion and anterior crossbite of -3mm was treated with a protocol of maxillary expansion and constriction by Hyrax expander associated with maxillary protraction by Petit facial mask. For 4 days, the expander was opened by 2/4 turn in the morning and closed by 2/4 turn in the evening. Elapsed that period, the boy wore the face mask delivering 500N force, for 14 hours per day, for 3 months. After overcorrection, the mask was used during the night delivering a 300N force. **Results:** The treatment achieved a 2.5mm overjet, with good maxilla-mandible transversal relationship and good facial profile. **Conclusion:** The protocol of maxillary expansion and constriction followed by maxillary protraction with Petit mask was effective to correct the anterior crossbite and the early skeletal Class III malocclusion caused by anterior-posterior maxillary deficiency.

Submitted: May 5, 2018
Modification: December 17, 2018
Accepted:January 8, 2019

***Correspondence to**:
Nayara Priscilla Pereira Lemos
Address: Rua Braga, 201, casa 24. Vila Lusitânia, São Bernardo do Campo, SP, Brazil.
Telephone Number: +55 (11) 96727-5341.
E-mail: nayarapereira.lemos@gmail.com

INTRODUCTION

Skeletal Class III malocclusion results of the lack of simultaneous sagittal growth between the maxilla and mandible. Thus, skeletal Class III malocclusion can be characterized by maxillary retrognathism, mandibular prognathism, or both, regardless of the sagittal relation between dental arches.[1-5] Individuals with skeletal Class III malocclusion have concave profile caused by facial medium third deficiency, lack of zygomatic prominence, and excess of the facial lower third. Moreover, maxillary atresia, lower lip protrusion, and anterior crossbite may be present.[4,6]

About 3% of Brazilian children at mixed dentition have posterior crossbite[7]. Because of greater orthopedic than orthodontic effects, Class III malocclusion must be diagnosed and treated at deciduous or mixed dentition due to better prognosis before the pubertal growth spurt between 4 and 12 years-old, with differences between boys and girls.[1-2,5-6,8] The literature reports that rapid maxillary expansion RME with or without maxillary protraction is the best early treatment for growing individuals with short-term good outcomes.[2-5,9,12-13]

The facial mask is used to achieve maxillary protraction and anterior displacement, delivering directed and constant orthopedic forces.[2-4,14] The literature reports different types of facial masks as follows: Delaire, Petit, Turley, Sky Hook, among others.[1-3,8-10] The magnitude, vector direction of the applied force, and number of hours used during the day are extremely important for treatment success.[1-3,6,8,10,14,15]

Early treatment advantage is the easy palatal disjunction, which may eliminate or decrease the possibility of further surgical intervention.[2,8] The protocol of maxillary expansion and constriction consists of alternating movements of rapid expansion and constriction of the maxilla, mainly aiming at greater maxillary expansion, enabling greater maxillary protraction, because the protraction effectiveness depending on the opening of the surrounding maxillary sutures.[5]

Taking into consideration the successful orthopedic treatment of the skeletal Class III malocclusion by maxillary protraction and the different protocols for the prior adjustment of the transversal maxillary dimension, no consensus exists on RME effect on the maxillary repositioning. Therefore, this study aimed to report the maxillary expansion and constriction with maxillary protraction in a boy with skeletal Class III at mixed dentition.

CASE REPORT

Patient G.C.C., male, aged 9 years and 3 months, sought the Clinics of Orthodontics of the Methodist University of Sao Paulo, with main complaint of "very forward lower teeth". At extraoral examination, we observed a concave profile with lower lip protrusion, lack of zygomatic prominence, and deeper nasolabial groove at smile (Figure 1B). At intraoral examination, the boy was at the second transitional period of mixed dentition, with Angle's Class III malocclusion, overjet of -3mm, overbite of 6mm, anterior-inferior crowding of 2.1mm, no dental rotations, and no posterior crossbite (Figures 2A, B, C, D, and E).

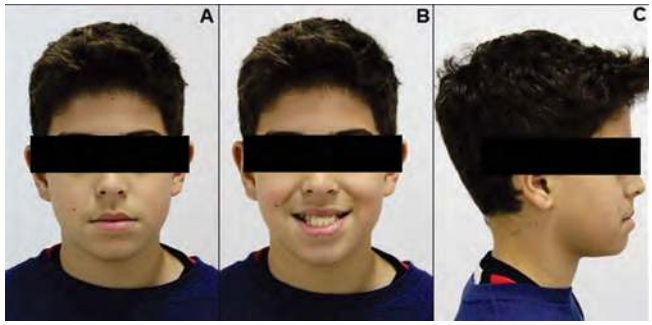

***Figure 1**: Initial extraoral photographs: A) frontal view; B) smile view; C) lateral view.*

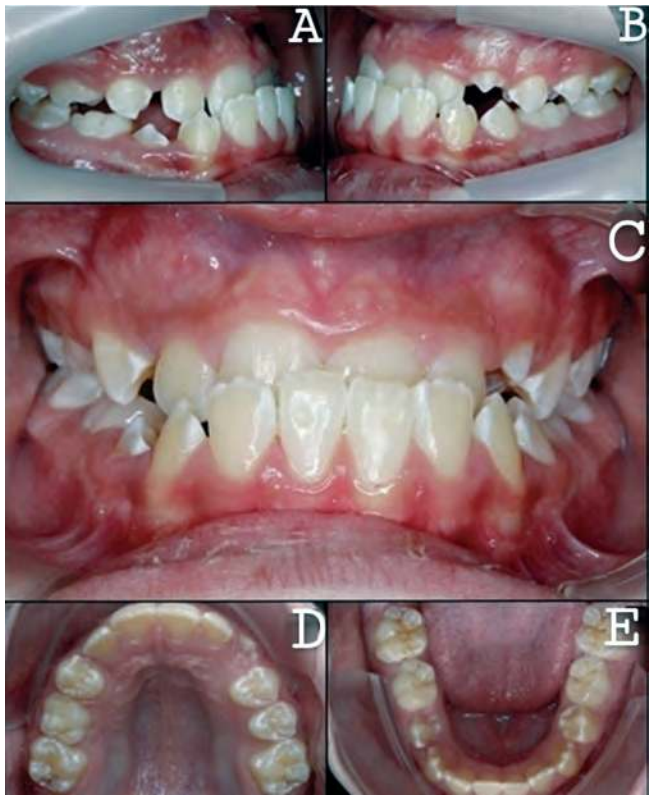

***Figure 2**: Initial intraoral photographs: A) right; B) left; C) frontal view; D) maxillary occlusal view; E) mandibular occlusal view.*

The panoramic radiograph revealed the presence of the mandibular premolar buds (Figure 3B). The pre-treatment lateral cephalogram (T0) showed biprotrusion (SNA=87.5°, SNB=88.0°, A-N Perp=3.0 mm, Pog Perp=6.0 mm), skeletal Class III (NB=1.30), severe brachyfacial pattern (VERT=1.03), and neutral growth direction (Jaraback's quotient=60.6%). The maxillary incisors were shifted to palatal direction (1.NA=20°) and retruded (1-NA=4mm); the

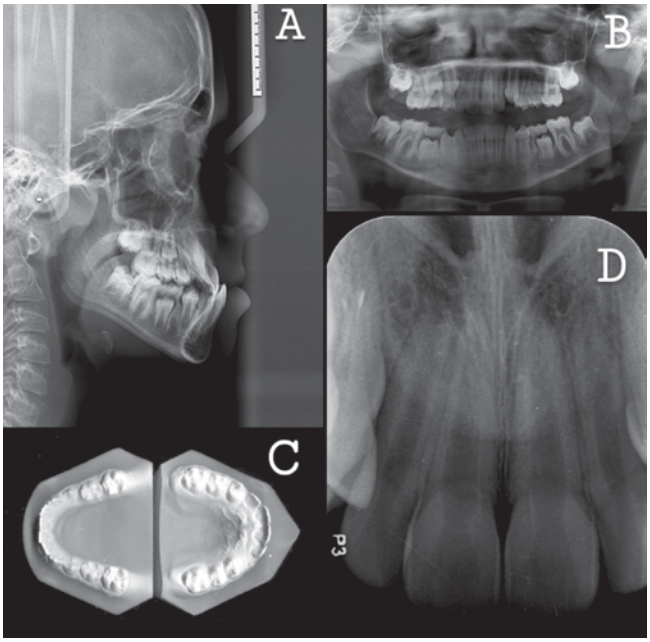

***Figure 3**: Pre-treatment files: A) Lateral cephalogram; B) Panoramic radiograph; C) Study casts; D) Periapical radiograph before palatal sutute disjunction.*

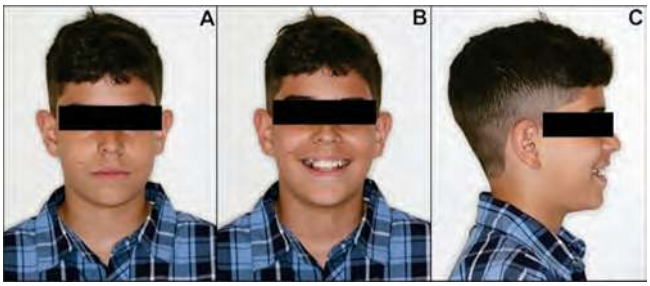

***Figure 4**: Post-treatment extraoral photographs: A) frontal view; B) smile view; C) lateral view.*

mandibular incisors were at normal position (1.NB=25.89°), slightly lingualized (IMPA=81.51°), and protruded. The anterior skull base/mandibular length proportion was smaller than 1:1, because the anterior skull base (S-N) had 66mm and the mandibular body length (Go-Me) 75mm.

The treatment approach and execution were explained to the boy and his parents. The parents signed a free and clarified consent form and agreed with the participation in this case report. The proposed treatment was the expansion and constriction of the maxilla associated with the maxillary protraction with facial mask.

A Hyrax expander was installed, and the expander thread was opened 2/4 turn in the morning and closed 2/4 turn in the night for 4 days. Elapsed that time, after the disjunction of the palatal suture (Figures 3D and 6B), the Petit facial mask was installed, delivering a force of 500N. The boy was instructed to use the mask for 14 hours/day, for 3 months. After that, the boy used the facial mask only during the night (20 p.m. to 7 a.m.), delivering a force of 300N to 350N, on each side. The treatment length was 9 months (Figures 4 and 5). After treatment (T1), the lateral cephalogram (Figure 6A) showed the improvement of the profile. Dental casts were obtained to measure the clinical parameters (Table 1).

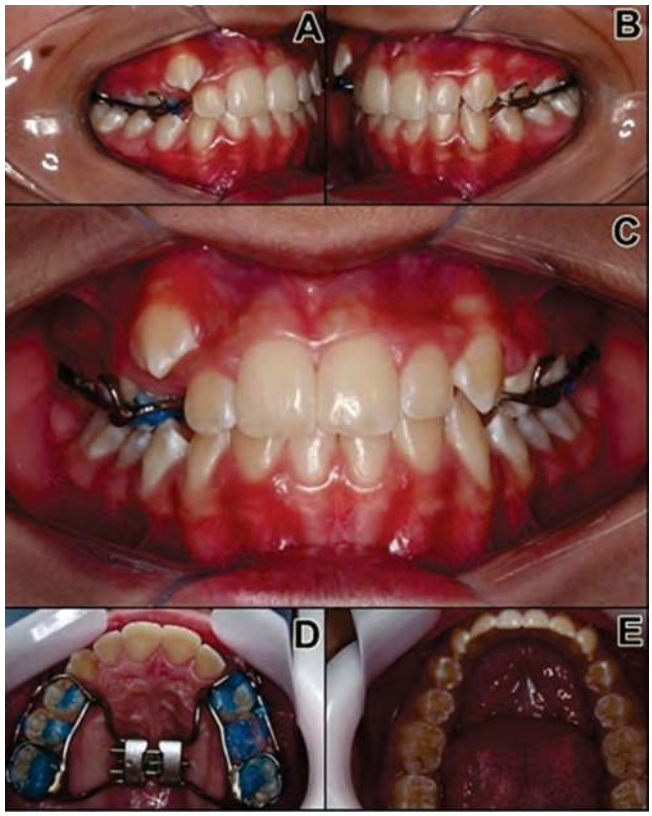

***Figure 5**: Post-treatment extraoral photographs: A) right; B) left; C) frontal view; D) maxillary occlusal view; E) mandibular occlusal view.*

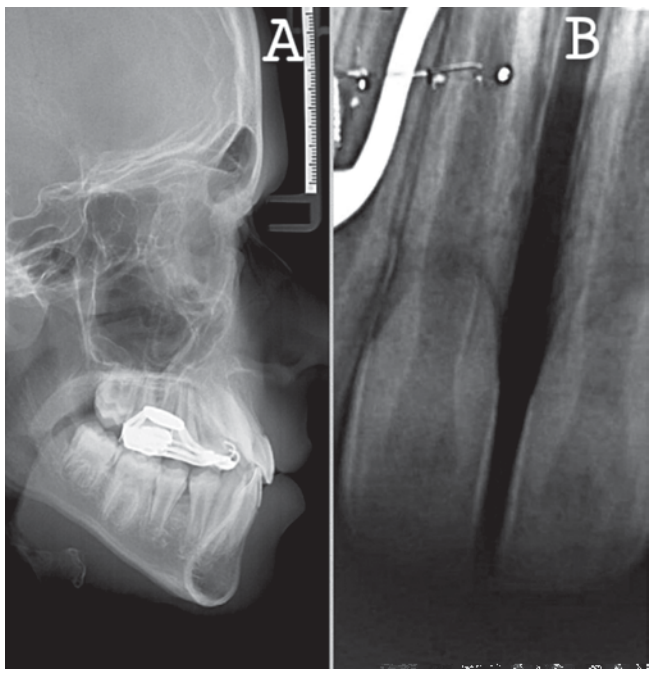

***Figure 6**: Post-treatment files: A) Lateral cephalogram; B) Periapical radiograph after the palatal suture disjunction.*

***Table 1**: Clinical and radiographic parameters between T0 and T1.*

	T0	T1
SNA	87,5°	93,0°
zSNB	88,0°	91,0°
A-N Perp	3,0 mm	3,0 mm
P-N Perp	6,0 mm	4,0 mm
1.NA	20,0°	25,0°
1-NA	4,0 mm	5,5 mm
AFAI (Ena-Me)	62,0 mm	64,0 mm
NAP	0,0°	4,0°
A-B Ocl	-11,0 mm	-6,0 mm
Sobremordida	6 mm	5 mm
Sobresaliência	- 3 mm	2,5 mm

DISCUSSION

The proposed treatment consisting of maxillary expansion and constriction followed by maxillary protraction with facial mask resulted in satisfactory skeletal, dental, and facial parameters, which agreed with the literature.[2,5,9,13] The comparison of pre-and post-treatment cephalogram revealed the overjet increasing of 5.5 mm, evidenced by the anterior crossbite correction and good sagittal relation. Before treatment, the boy had a concave facial profile that changed to a straight profile after treatment. Moreover, the zygomatic volume of the maxilla increased. The sagittal discrepancy between the maxilla and mandible decreased 5 mm. At the ending of the treatment, the boy exhibited Angle's Class I relation.

The literature recommends that Class III treatment should be provided as soon as possible, at deciduous or mixed dentition. A better prognosis occur before the pubertal growth spurt, i.e., between 4 and 12 years-old.[1-2,6-8,9-11] It is worth noting that atresic dental arches should be treated by slow expansion, while skeletal atresia by RME.[16]

Despite several early Class III treatment approaches, RME with or without maxillary protraction is the most used treatment for growing individuals.[2-4,11] Other alternative is Liou protocol consisting of the maxillary expansion and constriction aiming to achieve greater maxillary expansion, enabling greater and more effective protraction, thus depending on the opening of the surrounding maxillary sutures.[5,17] Liou protocol lasts 7 weeks and comprises the expander opening for one week followed by similar expander closure in the next week, repeated for 6 weeks; in the last week the expander is opened.[4-5,17] The minimum recommended daily use of the facial mask is 12 to 14 hours per day.[1-3,7,15] Studies report statistically significant differences favoring Liou protocol, but further longitudinal studies are necessary.[4-5,11-13,17]

This case report exhibited the treatment with a modified Liou protocol with favorable outcomes. The one-week expansion followed by one-week constriction of Liou protocol may damage the periodontium leading to gingival recession. The modified protocol used in this case report – opening and closure of the expander thread at the same day – would prevent periodontal damage[16]. The literature reveals similar effects on soft profile, such as lip, with both protocols[4]. Clinical studies not only show the maxillary displacement downwards and forwards, but also the clockwise rotation of the mandible, as well as the increasing of the anterior-inferior facial height, increasing of the facial convexity, anterior displacement of the maxillary dental arch, and lingualization of the mandibular incisors.[1-2,8,14]

The most used orthopedic appliance for RME is Haas expander, a tooth-tissue-borne appliance. Tooth-borne appliances, such as Hyrax and McNamara, are similarly effective.[1-2,4,6-8,9-11,13] The active RME phase begins 24 hours after the expander installation, by opening 2/4 turn in the morning and 2/4 turn in the evening.[16] RME aims at the palatal suture disjunction to increase the protraction results, as well as the increase of the transversal dimension, which would favor the correction of Class III discrepancy.[10] The associated protocol and patient's compliance is mandatory for treatment success.

In this case report, the protocol of maxillary expansion and constriction associated with maxillary protraction was effective to correct the anterior crossbite in a boy with skeletal Class III, suggesting that RME potentializes and influences positively on the maxillary repositioning. Further studies with longer following-up periods are still necessary.

REFERENCES

1. Rodrigues LRL, Baddredine FR, Jr. MC, França NM. Protração maxilar associada à disjunção maxilar ortopédica. Rev. Clin. Ortodon. Dental Press. 2007 jun-jul; 6(3).

2. Thiesen G, Fontes JOL, Zastrow MD, Lima MH, Nuernberg N. Tração reversa da maxila associada à mecânica intermaxilar no tratamento precoce do Padrão III: relato de caso. Rev. Clín. Ortodon. Dental Press. 2009 ago-set; 8(4).

3. Perrone APR, Mucha JN. O tratamento da Classe III - revisão sistemática - Parte I. Magnitude, direção e duração das forças na protração maxilar. R Dental Press Ortodon Ortop Facial. 2009 set-out; 14(5).

4. Gourgues LJ. Avaliação de Pacientes Classe III submetidos à expansão e protração maxilar através de dois difetentes protocolos de expansão – Controle de 12 meses. Porto Alegre. 2012.

5. Pithon MM, Santos NL, Santos CRB, Baião FCS, Pinheiro MCR, Matos Neto M, et al. Is alternate rapid maxillary expansion and constriction an effective protocol in the treatment of Class III malocclusion? A systematic review. Dental Press J Orthod. 2016 Nov-Dec; 21(6):34-42.

6. Oltramari Navarro PVP, de Almeida R, Ferreira Conti ACdC, Navarro RdL, de Almeida MR, Ferreira Parron Fernandes LS. Early Treatment Protocol for Skeletal Classe III Malocclusion. Braz Dent J. 2013;24(2).7. Brasil. Ministério da Saúde. Projeto SB Brasil 2010: pesquisa nacional de saúde buccal - resultados principais. Brasília: Ministério da Saúde; 2012.

8. Primo BT, Eidt VS, Gregianin JA, Primo NA, Faraco Junior IM. Terapia da tração reversa maxilar com máscara facial de Petit - relato de caso. RFO, Passo Fundo. 2010 maio-ago;15(2).

9. Vedovello SAS, Valdrighi H, Manhães FR, Vedovello Filho M, Santamaria Junior M. Tratamento precoce de má oclusão de Classe III com máscara de protração maxilar associada a elástico intrabucal. Rev Clín Ortodon Dental Press. 2012 jun-jul:11(3):90-7.

10. Penhavel RA, Saravia SAN, Bandeca AG, Freitas KMS, Valarelli FP, Cançado RH. Tratamento precoce de má oclusão de Classe III associando ERM e protração maxilar: relato de caso. Rev Clín Ortod Dental Press. 2016 Fev Mar; 15(1):55-67.

11. Camargo CK. Protração maxilar após dois protocolos de expansão: existe diferença? V Mostra de Pesquisa da Pós Graduação - PUCRS. 2010.

12. Canturk H, Celikoglu M. Comparison of the effects of face mask treatment started simultaneously ad after the completion of the alternate rapid maxillary expansion and constriction procedure. Angle Orthod. 2015 July; 85(2).

13. Liu W, Zhou Y, Wang X, Liu D, Zhou S. Effect of maxillary protraction with alternating rapid palatal expansion anda constriction vs expansion alone in maxillary retrusive patients: A single-center, randomized controlled trial. Am J Orthod Dentofacial Orthop. 2015 October; 148(4).14 Zhang W, Qu HC, Yu M, Zhang Y. The Effects of Maxillary Protraction with or without Rapid Maxillary Expansion and Age Factors in Treating Class III Malocclusion: A Meta-Analysis. PLOS ONE. 2015 June; 11.

15. Cordasco G, Mataese G, Rustico L, Fastuca S, Caprioglio A, Lindauer SJ, et al. Efficacy of orthopedic treatment with protraction facemasck on skeletal Class III malocclusion: a systematic review and meta-analysis. Orthod Craniofac Res. 2014 March; 17.

16. Filho LC, Filho OGS. Expansão Rápida da Maxila: Considerações Gerais e Aplicação Clínica. Parte I. R Dental Press Ortodon Ortop Maxilar. 1997 maio-jun; 2(3)

17. Liou EJW, Tsai WC. A New Protocol for Maxillary Protraction in Cleft Patients: Repetitive Weekly Protocol of Alternative Rapid Maxillary Expansions and Constrictions. The Cleft Palate-Craniofacial Journal, 42(2), 121–127.

AESTHETIC SOLUTION FOR CERAMIC RESTORATION ON CAST METAL CORE

Isabel Ferreira **Barbosa**[1*], Ericles **Otávio**[2], Livia Rodrigues **Menezes**[3], Fernanda Signorelli **Callazans**[4], Mauro Sayão **Miranda**[4]

[1]Department of Restorative Dentistry, Piracicaba Dental School, University of Campinas, Piracicaba, SP, Brazil.
[2]Department of Dental Clinic, Federal University of Rio de Janeiro, Rio de Janeiro, RJ, Brazil.
[3]Institute of Macromolecules Eloisa Mano, Federal University of Rio de Janeiro, Rio de Janeiro, RJ, Brazil.
[4]Department of Dentistry, Pontifical Catholic University (PUC) of Rio de Janeiro, Rio de Janeiro, RJ, Brazil.

Palavras-chave: Cerâmica. Pinos Dentários. Coroa Dentária. Estética Dentária.

RESUMO

Introdução: A fim de satisfazer os anseios estéticos, da população, por mascarar as restaurações houve a busca pela evolução dos materiais restauradores possibilitando a introdução de materiais livres de metais. Porém trabalhos prévios que foram confeccionados com estruturas metálicas muitas vezes não podem ser removidos e, portanto, necessitam de artifícios para que possam ser mascarados, pois não há o desejo de uma total passagem de luz evitando a reflexão desses fundos escurecidos. Para estas situações, é necessário optar por um sistema cerâmico que apresente um grau de opacidade, sem perda de suas características de translucidez, refletância e saturação. **Relato do caso:** A paciente possuía uma coroa metalo-cerâmica sobre núcleo fundido no elemento 21, constatou-se radiograficamente que o núcleo não podia ser retirado, pois traria risco de fratura ao dente. Optou-se por utilizar uma cerâmica mais opaca de arcabouço para evitar a passagem de luz sobre o metal escurecido. O material de escolha foi à cerâmica de zircônia por apresentar alta resistência à flexão, permitindo que funcione como arcabouço para coroas unitárias. **Conclusão:** Com a correta aplicação de cerâmicas de cobertura sobre o casquete observou-se que é possível mascarar a cor acinzentada do metal através dos conhecimentos ópticos do material, a correta utilização dessas propriedades, opacidade e translucides, e um estreito contato entre dentista e protético.

Keywords: Ceramics. Post and Core Technique. Esthetics Dental.

ABSTRACT

Introduction: In order to satisfy the aesthetic desires of the population, by masking the restorations was the search for the evolution of restorative materials enabling the introduction of metal-free materials. But previous studies that have been made with metal structures often cannot be removed and therefore require devices that can be masked, because there is no desire for a total passage of light avoiding dim reflection of these funds. For these situations, you must opt for a ceramic system to provide a degree of opacity, without losing its characteristics of light transmission, reflectance and saturation. **Case report:** In case the patient had clinical a metal ceramic crown on the molten core element 21, it was confirmed radiographically the core could not be removed because it would fracture risk to the tooth. We chose to use an opaquer ceramic framework to prevent the passage of light over dark metal. The material of choice was zirconia ceramic by high flexural strength, allowing it to function as a framework for crowns. **Conclusion:** With the correct application of ceramic coverage on Caquetá noted that it is possible to mask the gray color of the metal through the knowledge of the optical material, the correct use of these properties, opacity and translucidus, and a close contact between dentists and prosthetic.

Submitted: June 12, 2018
Modification: December 27, 2018
Accepted:January 4, 2019

***Correspondence to:**
Isabel Ferreira Barbosa
Address: Rua Joaquim Nabuco, 87/201, Copacabana, RJ, Rio de Janeiro, Brazil. CEP: 22080-030
Telephone number: +55 (21) 98866-5381
E-mail: barbosa.isabelferreira@gmail.com

INTRODUCTION

Patients are increasingly searching for restorations with more natural and harmonious appearance, which has reflected directly in both the improvement of restorative clinical procedures and the quality of materials and techniques applied, allowing the use of metal-free ceramic systems for producing crowns and fixed dental prostheses.[1,2]

However, intraradicular metal posts are used to this day and may be found in a great number of patients who opted for them because of the low cost. Hence, it is worth noting that these elements often do not need to be removed or that it is preferable not to remove them because of the risks associated, such as root fracture. With this is mind, dental ceramics become a good alternative to mask the color of posts with significant aesthetic disadvantages. These ceramics are characterized by the refractory nature, toughness, biocompatibility, and light transmission similar to the tissues composing the tooth structure.[3] Thus, using such systems allows providing patients with proper aesthetics associated with resistance and low wear rates.[4]

According to Yamamoto,[5] a constant complaint regarding metal-ceramic procedures regards to the opaque aspect of such restorations. This is because the depth of translucency is rather inferior to the natural tooth.[5] When used in metal cores or in elements with darkened dentin, the complete passage of light is not desired, preventing the reflection of such darkened background, which would result in loss of final aesthetic quality.[1,6] Then, a ceramic system with a degree of opacity is selected, without losing translucency, reflectance, and brightness (saturation) characteristics.[1,6]

The Lava All-Ceramic system™ (3M ESPE™) consists of zirconia crystals and uses CAD/CAM technology. It presents high flexural strength and may be indicated as a framework for both single crowns and fixed partial prostheses.[1,7] However, these ceramics are more opaque, which may be a disadvantage for anterior restorations with higher translucency.

Cementation requires a primer specific for zirconia, which is based on methacrylate. According to the manufacturer, such primer consists of acrylate phosphonic acid and reticulation agents. The resin cement systems that either use primer or are composed of phosphate monomers produce higher bond strength to zirconia.[8]

Therefore, the present study aims to present a clinical case of an aesthetic procedure on a cast metal core, performed so that the substrate color would not interfere negatively with the final color, obtaining good results and patient satisfaction.

CASE REPORT

Female patient, 40 years old, attended the Cosmetic Dentistry specialization clinic of the Pontifical Catholic University of Rio de Janeiro, RJ, Brazil, complaining of the color and aesthetics of the upper left central incisor (element 21). The clinical examination showed that the element was proclinated and presented a metal-ceramic crown on a cast metal core. Radiographs allowed verifying that the metal core presented correct adaptation and root portion of high caliber. Hence, it was decided not to remove the metal core because it could fracture the dental element (Figure 1).

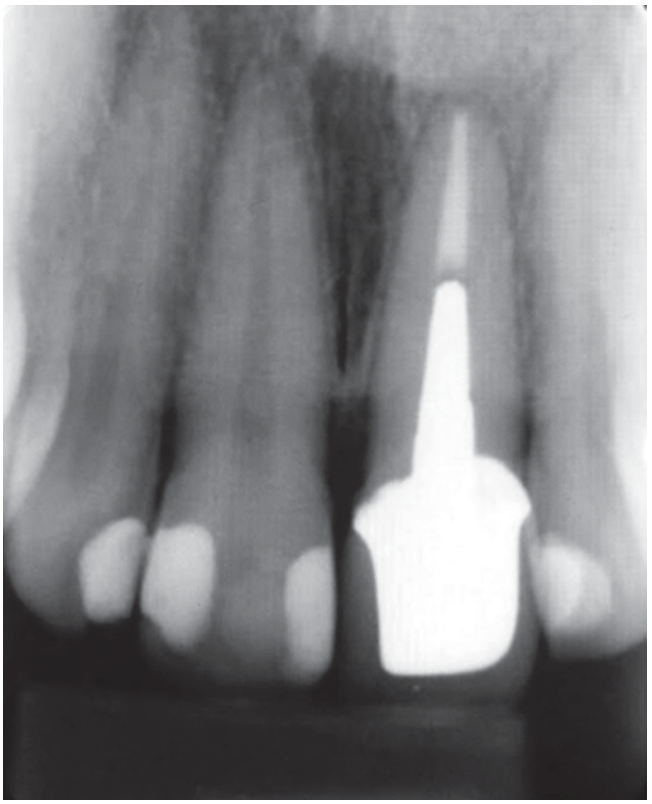

***Figure 1**: Radiograph showing the NMF installed in the root canal.*

Initially, at-home bleaching was performed before replacing the crown in question. The initial color was A3.5 for canines and A2 for the other teeth, based on the VITA classic scale (Figure 2).

Bleaching was performed with 16% carbamide peroxide (FGM Produtos Odontológicos), which was used at night for four weeks. Consequently, the color turned into A2 for canines and A1 for the other teeth.

The cast metal core was prepared to obtain an adequate buccal inclination and to allow determining a more defined chamfered finishing. Therefore, the 3131 diamond bur (KG Sorense) was used, obtaining a preparation with minimum thickness of 1.5 mm. Due to the inclination of the

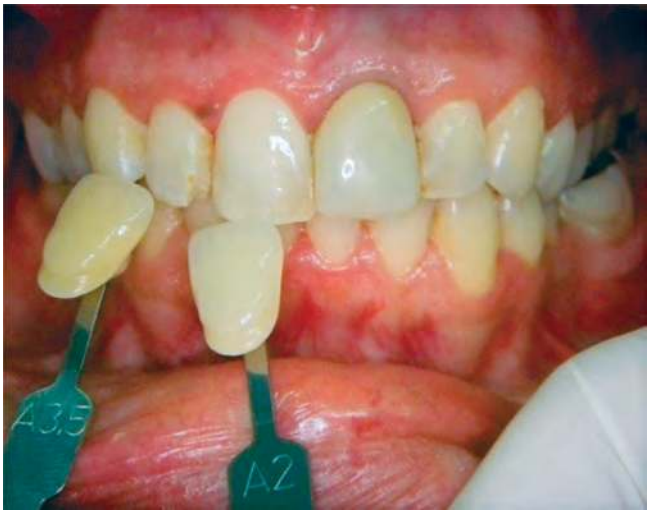

***Figure 2**: Initial image of the patient with the stains A3,5 and A2.*



***Figure 3**: Preparation done with chamfer finish.*

metal core, the wear was greater than the diameter of the diamond bur, resulting in a wear thickness of 2.0 mm. In the palate, in addition to the former, the 3168 diamond bur (KG Sorense) was used to produce the concave part of the preparation. Lastly, the preparation was refined with 3131F and 3168F burs (KG Sorense).

Molding was performed with addition silicone (3M ESPE™) in one step. The double wire (Ultradent Products, Inc) (numbers 0 to 000 with astringent) technique was used for gingival separation and the correct molding of the dental emergence profile. The antagonist was molded with alginate (Dentsply Ind. Com. LTDA) and the bite guide was produced with Occlufast registration silicone (Zhermack). All these information were sent to the laboratory for producing an individual tray in zirconia by the Lava system.

For color selection, the visual technique was applied aided by photographs. First, the color of the tooth base was selected using the VITA scale (Ivoclar Vivadent LTDA) (B1), but black and white photographs showed that tooth values did not match the color selected. Hence, the scale of bleached teeth (Ivoclar Vivadent LTDA) was used, selecting the 040 color palette.

Next, the scale of enamel shades was applied, in which translucency is selected first. At this moment, it was decided the element presented translucency OE1 in some parts and OE2 in others. In addition to both of these, which correspond to the largest part of the tooth, the shade was more violet in certain aspects, corresponding to OEV. In a small amount, OE5 was also found. The tooth body showed a caramel color corresponding to CTY, which was diluted to reach the pigmentation matching the tooth. In this case, only 2% of this pigment was used. Lastly, a small amount of SIY was placed in the tooth cervical. Considering all these choices of value, translucency, and color, a map was created of the dental element to produce a crown as similar as possible to the surrounding teeth.

Because ceramics are extremely fragile, the ceramic proof was performed carefully before cementation. After verifying adaptation and color with satisfactory results for both, the prosthetic product was cemented with adhesive cementation. The Multilink cement (Ivoclar Vivadent LTDA) was selected for having a primer based on methacrylate, which bonds better to zirconia. Hence, the piece was pre-etched with 10% hydrofluoric acid (Condac - FGM), washed,



***Figure 4**: Final photo with newly cemented crown and visible cervical term due to the initial gingival retraction.*



***Figure 5**: Final photo, after 5 years.*

and air-dried. The metal/zirconia primer (Ivoclar Vivadent LTDA) was applied for 180 seconds. The tooth was washed with water and air-dried. The Mix Multilink Primer A+B was mixed at the ratio of 1:1, applied on the tooth for 15 seconds, and air-dried. For the cement, a ratio of 1:1 of Mix Multilink was used, manipulating and placing it on the ceramic crown, which was then positioned in the tooth. Excesses were removed and 120 seconds were waited for the chemical polymerization of the cement, so the patient could be released. Figure 4 shows the success of the technique, considering that optimal aesthetic color results were obtained, despite the dark substrate. Figure 5 shows the result of the procedure five years later.

DISCUSSION

For a long time, cast metal cores were the preferred choice to obtain higher retention in endodontically treated teeth.[9] However, the high rates of root fracture associated with aesthetic problems, which include potential darkening of root and tooth cervical and the obstacle of light passage, reduced their use significantly.[9,10] In cases of hindered removal of pre-existing cast metal cores, the use of ceramics with different degrees of translucency, such as those with zirconia infrastructure, may represent a valuable aesthetic resource.[1,2]

Although metal-ceramic restorations present an extensive history of clinical successes, their substitutions with more aesthetic resources was encouraged. The appearance of adhesive dentistry and reinforced ceramics enabled the production of metal-free ceramic restorations, which are more resistant to feldspathic ceramics, therefore allowing the production of single elements due to the increased resistance along with the maintenance of optical and aesthetic properties.[2,5,11]

The ceramic systems may currently be classified in two groups: translucent and opaque/resistant.[12] The latter presents high fracture strength, but in order to obtain adequate aesthetics, a cover layer is used to hide the opacity and produce similar nuances of a natural tooth.[12]

Choosing the correct tooth color includes a subjective assessment and the use of photographs, color guide, and various light incidences. Even with all these resources, it will always be difficult to produce a restoration with identical optical performance to the natural dentition.[13] Touati et al.[14] considered translucency one of the hardest parameters for correct quantification and reproduction. However, this aspect should not be neglected, because it is an optical property with a decisive role in the light transmission phenomenon and it is essential for the natural appearance of the restoration.[14]

Another important factor for allowing this color mimicry is obtaining a preparation with adequate thickness for the different types of ceramics.[15] When reaching a minimum thickness of 2.0 mm for the ceramics, any material may be masked and the color difference is perceptible only with the use of specific devices.[15]

CONCLUSION

Adequately using more opaque or translucent ceramics, associated with the characteristics of color and shape reproduction obtained by the proper communication between dentist and prosthetist, generates satisfactory aesthetic solutions with predictable and lasting results.

REFERENCES

1. Gomes, EA; Assuncao, W.G.; Rocha, E.P.; *et al.* Cerâmicas odontológicas: o estado atual. *Cerâmica* [online]. vol.54, n.331, pp.319-325. ISSN 0366-6913. http://dx.doi.org/10.1590/S0366-69132008000300008, 2008

2. Valee, Al.; Martins, LM.; Chidiak-Tawil.; *et al*. Sistemas cerâmicos atuais: Revisao de literatura. Revista Dental Press de Estética, Vol.7 (1), p.106-118, 2010.

3. Bohjalian, A.; Froner, E.E.; Zanetti, A.l.; *et al*. Resistência à fratura dos sistemas cerâmicos Empress I, II e In-Ceram: estudos sobre fatores envolvidos nos testes. *Revista Gaucha Odontológica*, v. 54, n. 2, p. 185-190, 2006.

4. Gehrke, S.A.; Dos Santos, P.C.V.; Carvalho, N.t.a.; *et al.* Abutment cerâmico para prótese individual metalfree sobre implante: parafusada ou cimentada - demonstração laboratorial e clínica. FULL Dentistry in Science; 1(3), 2010.

5. Yamamoto, M. Metal-ceramics principles and methods of Makoto Yamamoto. *Chicago: Quintessence*, p.219-347, 1985.

6. Augusto, J.C.D. Avaliação in vitro da translucidez de dois sistemas cerâmicos metal-free: In-Ceram x Empress 2. *Araraquara*, 2004.

7. Roque, J.C.S. Propriedades óticas de sistemas cerâmicos de alta resistência: estudo laboratorial. [Tese de Doutorado em Ciências e Tecnologias da Saúde]. Lisboa. Universidade de Lisboa, 2015.

8. Nothdurft , F.P.; Motter, P.J.;, Pospiech, P.R. Effect of surface treatments on the initial bond strength of different luting cements to zirconium oxide ceramic. *Clinica. Oral Invest*, n.13, p. 229-235, 2009.

9. Louro, R.l.; Vieira, I.M.; Firme, C.T. Uso do núcleo metálico fundido na reconstrução de dentes tratados endodonticamente: relato de caso clínico. UFES Rev Odontol; 10(2):69-75, 2008.

10. Moro, M.; Agostinho, A.M.; Matsumoto, W. Núcleos Metálicos Fundidos X Pinos Pré-Fabricados. PCL - Revista Ibero-americana de Prótese Clínica e Laboratorial; 7(36):167-72, 2005.

11. Spear, F.; Holloway, J. Which all-ceramic system is optimal for anterior esthetics? JADA, N.139, p.19–24, 2008.

12. Mclean, J.W. The science and art of dental ceramics: aesthetics of dental porcelains. Monograph III. *New Orleans: Louisiana State University School of Dentistry;* p. 1-41, 1986.

13. Touati, B.; Miara, P.; Nathanson, D. Odontologia Estética e Restaurações Cerâmicas. *São Paulo: Santos*, 2000.

14. Vichi, A.; Ferrari, M.; Davidson, C.l. Influence of ceramic and cement thickness on the masking of various types of opaque posts. *Journal* Prosthetic Dentistry,v.83, p412-417, 2000.

15. Blatz, M.b.; Sadan, A.; Martin, J. *et al.* In vitro evaluation of shear bond strengths of resin to densely-sintered highpurity zirconium-oxide ceramic after long-term storage and thermal cycling. *Journal of Prosthetic Dentistry*; v.92, p.356–362, 2004.

IDIOPATHIC EXOSTOSIS: RARITY ON MAXILLARY SINUS

Vanessa de Araújo **Faria**[1]*, Felipe Pinheiro **Vilela**[2], Gabriel Campos **Wendich**[2], Marlivia Gonçalves de Carvalho **Watanabe**[3], Juliano Abreu **Pacheco**[4] , Helena de Freitas Oliveira **Paranhos**[4], Elza Maria Carneiro Mendes Ferreira **Santos**[5], Plauto Christopher Aranha **Watanabe**[3]

[1]Master in Oral Diagnosis at the Oral Diagnosis Course, Dentistry College of São Paulo, University of São Paulo, SP, Brazil.
[2]Undergraduate student of Dentistry at the School of Dentistry of Ribeirão Preto - University of São Paulo, SP, Brazil.
[3]Department of Stomatology, Collective Health and Legal Dentistry of the School of Dentistry of Ribeirão Preto, University of São Paulo, SP, Brazil.
[4]Department of Dental Materials and Prosthodontics of the School of Dentistry of Ribeirão Preto, University of São Paulo, SP, Brazil.
[5]Radiologist, Master's degree in Image Science and Medical Physics of Ribeirão Preto Medical School at the University of São Paulo, SP, Brazil.

Palavras-chave: Exostose. Radiografia Panorâmica

RESUMO

Introdução: Exostoses nos seios paranasais têm sido muito mais relatados na literatura radiológica odontológica, apesar da extensa citação na literatura otorrinolaringológica. **Objetivo:** Neste relato de caso, encontramos uma exostose idiopática rara, que cresceu no seio maxilar. **Relato de caso:** Paciente negra de 68 anos, BGS, acompanhada pelo Serviço de Odontologia do Hospital do Câncer para tratamento de lesões orais (mucosite) e outras condições decorrentes da radioterapia e terapia hormonal (Tamoxifeno), apresentou neoplasia maligna da mama direita em 2015. Não foi realizada biopsia da exostose, pois a paciente está em tratamento e está sendo acompanhada pelo serviço do hospital. Realizaram-se radiografia panorâmica e exame clínico. Ao examinar os exames, foi possível notar uma imagem com dupla radiodensidade, mais radiopaca numa parte externa e menos radiopaca na parte interna, com aspecto de osso trabecular, circunscrito, unilocular, na região do pré-molar pediculado, no interior do seio maxilar esquerdo. Para melhor avaliação e hipótese diagnóstica, foi realizada uma tomografia computadorizada, aplicou-se uma ferramenta para mensuração da densidade do perfil da lesão, evidenciando-se que a suposta lesão invagina para o interior do seio maxilar e tinha densidade óssea semelhante ao osso da crista alveolar. **Conclusão:** Simultaneamente a outras lesões, as exostoses são lesões benignas, apresentam baixa agressividade e rara sintomatologia, sendo indicada exérese somente quando acomete a função, ou por motivos estéticos, ou quando não é possível a confecção de próteses. Muitos dos casos são diagnosticados de modo incidental e a partir de exames radiográficos de rotina em consultórios médicos ou odontológicos e devem ser acompanhados para análise e verificação de seu crescimento.

Keywords: Exostosis. Panoramic Radiography.

ABSTRACT

Introduction: Exostoses in the paranasal sinuses have been reported in a greater number in the dental radiological literature, despite the extensive citation in the otorhinolaryngology literature. **Objective:** This case report was a rare idiopathic expression that grew in the maxillary sinus. **Case report:** A 68-year-old black patient, BGS, followed up by the Odontology Service of Cancer Hospital for treating oral lesions (Mucositis) and other conditions resulting from radiation therapy and hormone therapy (Tamoxifen), presented malignant neoplasm at the right breast in 2015; an exostosis biopsy was not performed, since the patient is being treated and followed up by the hospital service. Panoramic radiography and clinical examination were performed. By analyzing the tests, it was possible to notice an image with double radiodensity, more radiopaque in the external portion and less radiopaque in the internal portion, with an aspect of trabecular bone, circumscribed, unilocular, in the region of pedunculated premolar, inside the left maxillary sinus. In order to have a better assessment and diagnostic hypothesis of the case, a CT scan was performed, a tool was applied to measure the density of the profile of the lesion, thus evidencing that the supposed injury invaginates to the interior of the maxillary sinus and had bone density similar to the alveolar crest bone. **Conclusion:** Simultaneously to other lesions, exostoses are benign lesions, present low aggression and rare symptomatology; exeresis is indicated only when it prevents functioning, or for aesthetics reasons, or when it is not possible to make prostheses. Many cases are incidentally diagnosed from routine radiographic review in medical or dental offices and should be followed up for analysis and verification of their growth.

Submitted: August 28, 2018
Modification: Mach 20, 2019
Accepted: April 10, 2019

***Correspondence to:**
Vanessa de Araujo Faria
Address: University of Sao Paulo .
Avenue of Coffe s/n, Ribeirao Preto, Sao Paulo, SP, Brazil.
Zip code : 14040904
Telephone Number: +55 (16)33153993
E-mail: nessaforp78@yahoo.com.br

INTRODUCTION

Despite the extensive citation in otorhinolaryngology literature, exostoses in the paranasal sinuses have been very few described in dental radiological literature. Exostoses are benign growths, which affect 20% to 25% of native bones, what is called torus, and 5% to 29% of long bones. Although they may appear in any bone of the human skeleton, they rarely appear in facial bones, except for the mandible and maxilla.[4] These bone changes are most often found in adulthood. Within the age group of subjects who are 60 years old or more, the rate is 21.5%; in comparison with a group of subjects aged 13 to 19 years old, the rate is 7.8%. The other age groups—20 to 29 years old, 30 to 39 years old, 40 to 49 years old, and 50 to 59 years old—have demonstrated a similar frequency. When it comes to sex, prevalence is higher among men.[22] Some authors have reported cases of exostoses in patients undergoing nasal irrigation therapy, thus correlating a cold temperature with a possible onset of exostosis.[23]

The etiology and mechanisms of oral exostoses are unclear and there is no consensus among the investigators. Various authors have suggested several etiological factors such as genetic traits, en- vironmental factors, mastication and occlusal stress, inflammation, systemic diseases, and the post- menopausal period. Some authors emphasized a possible autosomal dominant inheritance with a lower penetrance, whereas other authors have reported a correlation between oral exostoses and bruxism, temporomandibular dysfunction and inflammation of gingival tissue.[19]

The need for diagnostic evaluation is essential because exostosis becomes, depending on the clinical planning of the case, a limiting and impeding factor, such as for the preparation of a prosthesis or implant. It is important to make the differential diagnosis of exostosis with osteoma and bone sclerosis.[2,3,5,6,]

A panoramic radiography is the main resource to obtain a view of the entire mouth, including the maxilla and mandible, as well as the surrounding bone structures. It is quite often the first-choice test to evaluate the maxillary sinuses, as it enables one to evaluate the size, pneumatization and findings inside them.[7,28] Despite its importance as a diagnostic aid, radiographic examination must not be indistinctly performed for all individuals, only when the patient's history or their signs and symptoms suggest this need and when the information it offers is of great use.[9,13,14] However, a three-dimensional image may be necessary, such as CBCT obtained in axial sections (the interval between the cuts is variable), in order to increase the accuracy of the images, enabling better diagnosis and planning.[11,14,15,30]

With the use of panoramic radiography in the daily dental practice, many alterations are incidentally discovered (radiographic findings), especially the silent ones. This raises the diagnostic hypothesis wherefrom it is necessary to further research the patient's history, performing complementary tests, such as volumetric tomography which will show size, the relation with adjacent structures, and limits in the three axial, coronal and sagittal projections. This leads to a more accurate planning, and a better assessment of the need for a biopsy, in order to interfere or not in the clinical planning of the case. This article aims at describing an idiopathic and rare case of bilateral exostosis obtained by cone beam computed tomography—CBCT.[1,12,23,24,25]

CASE REPORT

A black 68-year-old female patient, BGS, followed up by the Dentistry Service of Cancer Hospital to treat oral lesions (mucositis) and other conditions resulting from radiotherapy and hormone therapy (Tamoxifeno), presented malignant right-breast neoplasm in 2015. Surgery for tumor removal and axillary lymph nodes dissection was performed in 2016, followed by 12 sessions of radiotherapy, which were finished in January, 2017. The patient takes Tamoxifeno (initiated after the surgical treatment of the second tumor), Diazepam, Haldol, lithium, captropil, and insulin; she does not perform nasal irrigation, presents diabetes mellitus, depression, psychotic episodes, bipolar disorder, and hypertension; she has a complete upper denture and presents teeth 33, 32, 31, 41, 42, and 43 with indication of tooth extraction; the presence of mucositis in the palate was verified after a clinical examination.

As a treatment protocol, patients who will undergo cancer treatment at Cancer Hospital have a panoramic radiography performed, in order to care for their oral health and evaluate the general conditions of their teeth and maxillomandibular complex. This is done to preventively suggest a dental treatment that will improve their oral conditions to continue radiotherapy. After the panoramic radiographic examination (Fig. 1), it was possible to notice an image with a double radiodensity, more radiopaque in the external portion and less radiopaque in the internal portion, with an aspect of trabecular bone, circumscribed, unilocular, in the region of pedunculated premolar, inside the left maxillary sinus. The diagnostic hypotheses included: A dental element inside the sinus—it could simply be a residual root; calcified masses present in the paranasal sinuses, usually found in the maxillary or nasal cavities and often surrounded by inflamed mucosa,[19] it was also possible that the origin was endogenous, such as bone sequestration; and it could yet be blood products, such as thrombus and teeth; or exogenous, such as foreign bodies, benign and asymptomatic;[16] there was also the possibility of exostosis. To better define the diagnosis, a cone beam computed tomography (CBCT) was performed.

This raises the diagnostic hypothesis wherefrom it is necessary to collect further information on the patient's history, performing complementary tests, such as volumetric tomography to visualize size, the relation with adjacent structures and boundaries on all three axial, coronal and

sagittal projections, in order to plan more accurately and assess for the need of a biopsy. This may or may not interfere with in the clinical planning of the case.

Antral exostoses generally do not require surgical approaches. A biopsy examination is not usually suggested, unless the antral exostosis causes clinical symptoms and leads to sinonasal ob- struction. However, a biopsy could be useful in some patients with an inconsistent history or noncharacteristic-appearing lesions.[12]

Radiographic Interpretation in CBCT



Figure 1: *Panoramic radiograph in centric occlusion, occlusal plane parallel to the ground, and median line* ***upright*** *to the occlusal plane, where the pedunculated image is observed inside the left maxillary sinus.*

Three-dimensional CBCT reveals an aspect of bone trabeculation inside the pedicle, not different from the other aspects of the bone tissue of the region, wrapped in a supposed cortical bone (hyperdense sign). This image was seen in parasagittal sections (Figure 2), and axial, coronal and 3D sections (Figure 3). Imaging Studio - Anne Solutions Version 3.401.

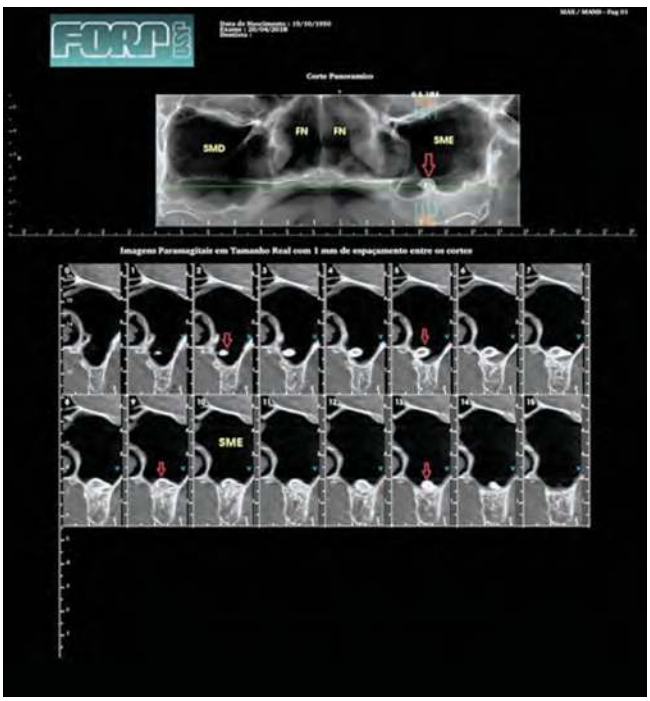

Figure 2*: Tomography - Panoramic and Parasagittal Section and it is possible to see the pedunculated situation of the lesion.*

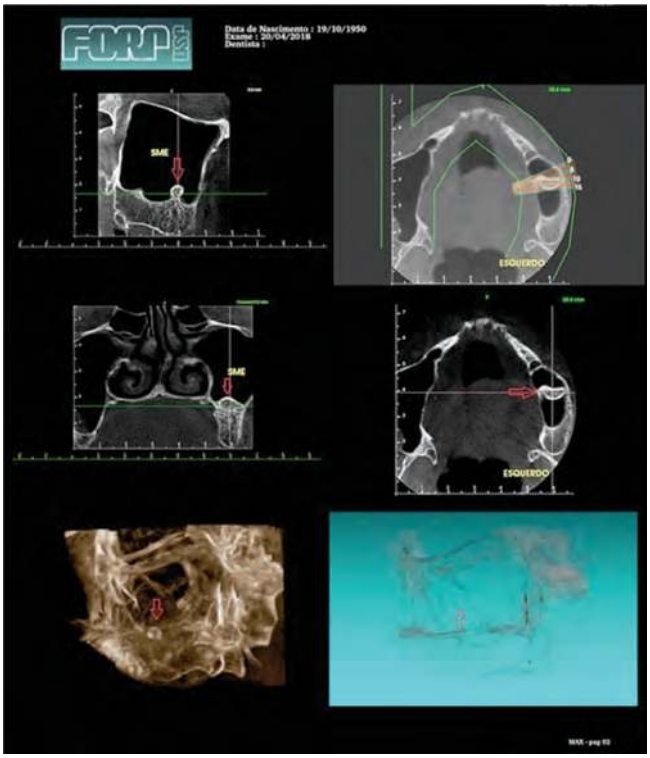

Figure 3 : *Tomography - Axial, coronal and 3D sections and 3D images CTBC - axial section, coronal section and 3D section. Jaw, left side. CTCB - panoramic section and sagittal section, spaced 1mm between sections. Jaw, left side.*

The coronal tomographic section was obtained using an Imaging Studio software – Anne Solutions Version 3.401 profile line tool under a longitudinal axis, covering from the thickened cortex of the maxillary sinus to the alveolar cortical bone; wherefrom we selected 4 points, from 1 to 4, as described below (Figure 4), evidencing that the supposed injury, which invaginates to the interior of the maxillary sinus, had bone density similar to the bone of the alveolar ridge:

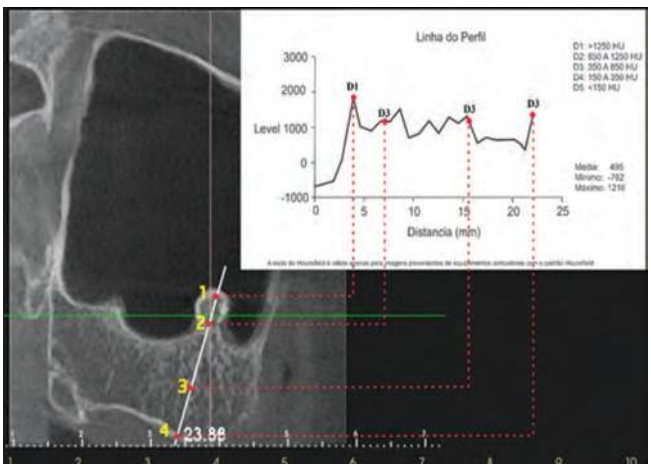

Figure 4*: Tomography - Coronal Section – It is possible to see a tool to measure the density profile of the lesion, which evidences that the supposed injury, which invaginates to the interior of the maxillary sinus, had bone density similar to the bone of the alveolar ridge.*

Tomography OP300. Voxel 0.16. FOV11x11. Imaging Studio – Anne Solutions Version 3.401. Profile Line tool

1. Density in the cortical region of the pedicle;
2. Density in the region of the interior of the pedicle;
3. Density in the bone trabecular region, premolar region;
4. Density in the cortical alveolar bone region.

DISCUSSION

Currently, the use of panoramic radiographic shots enables the discovery of radiographic findings and reveals the need for complementary tests. Volumetric tomography appears as the first choice after the panoramic radiography, showing anatomical aspects and assisting in the planning and outcome of the case. The different dental specialties already benefit from the CBCT method in the diagnostic routine, such as endodontics, surgery and implantology, oral diagnosis, surgery and orthodontics.[10]

Among maxillary sinuses inflammatory / infectious diseases, 10 to 12% are of dental origin[18] and the majority is associated with pulp necrosis,[3] periapical disease, advanced periodontal disease and bucco-sinusal communications.[17] In this clinical case, we believe that exostosis is related to environmental factors, such as climate and nutrition, surgical sequelae, and masticatory tension.[21]

A panoramic radiography was initially performed to evaluate the dental and bone conditions of the maxillomandibular complex. Analyzing the test, it was possible to see that there was a change in the maxillary sinus. The radiographic presentation suggested the presence of a possible dental element, or even residual root. These are the most frequent possible conditions; therefore, they are proposed as a complementary examination to CBCT. In the parasagittal sections (Figure 2, sections 9-12) and coronal sections (Figure 3), the connection / bound of the lesion to the bone tissue of the left maxillary alveolar ridge is evident, where it is possible to verify the absence of the inferior cortex of the maxillary sinus (sections 9 to 12), exactly in the lesion pedicle. This has also defined the lesion as exostosis.

There are procedures performed by dental surgeons that may carry foreign bodies into the maxillary sinuses, resulting in infectious and inflammatory conditions, such as the extrusion of endodontic filling materials, endodontic irrigation, implants incidentally displaced to the sinuses, among others. These infections must be properly interpreted and investigated. It has been stated that it is important to identify and X-ray this condition to avoid unnecessary surgical procedures. It is difficult to clinically diagnose them, because of the asymptomatic nature of this condition, unless the approach is through the endoscope.[20] Although there is little information on antral exostoses, some characteristics have been described by Ohba et al. The mean size reported by these authors (4.7 mm × 7.4 mm) was clearly lower than the individual exostoses, surpassing even the highest measurement of the presented cases (2 mm x 1 mm). In this case, surgical removal will not be necessary, because the dimensions are small, there is no impairment of the function of the maxillary sinus or its aesthetics. It should be followed, though, for some possibility of bone growth, which could compromise this sinus structure of the face.

In view of the clinical similarity of osteomata and exostoses, it is important to note that osteoma, as a benign neoplasm, tends to grow continuously. Thus, it may be suggested that such biological behavior differs from that presented by exostosis, which, because it is an anomaly of development, grows during a certain period and then becomes inactive.[6]

Exostoses are benign lesions that appear simultaneously with other lesions, present low aggressiveness and rare symptomatology. Surgical removal is indicated only when it affects the function or due to aesthetic reasons, or when it is not possible to make dentures. They are commonly found in the maxilla or mandible. Many of the cases are diagnosed incidentally and from routine radiographic examinations in medical or dental offices. They should be monitored for analysis and verification of their growth.

CONCLUSION

CBCT is able to identify exostosis through radiopacity. It is important that the image be monitored, in order to aid in the decision making of performing or not any surgical procedure.

REFERENCES

1. Adelson RT, Kennedy DW. Paranasal sinus exostoses: possible correlation with 191 cold temperature nasal irrigation after endoscopic sinus surgery. Laryngoscope 192 2013;123:24–7. 193.

2. Araujo S.E, Kalil K.R, Bertoni F., Park Y.K, Tumors and tumor-like lesions of bone for surgical pathologists orthopedic surgeons and radiologists. Springer 1988.

3. Bell G.W, Joshi B.B, Macleod, R.I. Maxxilary sinus disease: diagnosis and treatment. Br. Dent. J. 2011. Feb; 210(3): 113-8.doi: 10.1038/sj.bdj.2011.47

4. Bernaba JM. Morphology and incidence of torus palatinus and mandibularis in Brasilian Indians. J Dent Res. 1977 May;56(5):499-501.

5. Bolger WE, Butzin CA, Parsons DS. Paranasal sinus bony anatomic variations and 205 mucosal abnormalities: CT analysis for endoscopic sinus surgery. Laryngoscope 206 1991;101:56–64.207.

6. Boros LF, Carneiro MIS, Boros LH, Boros LF, Boros PAS. Osteoma Compacto Central de Mandiìbula: relato de caso cliìnico. Odontologia Cliìn. Cientiìf. Recife, 10(1): 89-93, 2011
7. De Moraes PH, Costa VO, Olate S, Caria PHF, Barbosa JRA. Estudio morfométrico del seno maxilar mediante tomografías computadorizadas. Evaluación de la reconstrucción total del piso sinusal. Int J Morphol 2012;30:592–8.
8. Eggen S. Torus mandibularis: an estimation of the degree of genetic determination. Acta Odontol Scand.1989; 47(6):409-415.
9. DENTAL RADIOGRAPHIC EXAMINATIONS: RECOMMENDATIONS FOR PATIENT SELECTION AND LIMITING RADIATION EXPOSURE. AMERICAN DENTAL ASSOCIATION - Council on Scientific Affairs. REVISED: 2012.
10.Garib, D.G, et al. Tomografia computadorizada de feixe co□nico (Cone beam): entendendo este novo meìtodo de diagnoìstico por imagem com promissora aplicabilidade na Ortodontia.R Dental Press Ortodon Ortop Facial 139 Maringaì, v. 12, n. 2, p. 139-156, mar./abr. 2007
11.Gracco A, Incerti Parenti S, Ioele C, Alessandri Bonetti G, Stellini E. Prevalence 201 of incidental maxillary sinus findings in Italian orthodontic patients: a retro- 202 spective cone-beam computed tomography study. Korean J Orthod 2012;42: 203 329–34. 204.
12. Haffey T, Woodard T, Sindwani R. Paranasal sinus exostoses: an unusual com- 186 plication of topical drug delivery using cold nasal irrigations. Laryngoscope 187 2012;122:1893–7. 188.
13. Hahnel S, Ertl-Wagner B, Tasman AJ, Forsting M, Jansen O. Relative value of MR 208 imaging as compared with CT in the diagnosis of inflammatory paranasal sinus 209 disease. Radiology 1999;210:171–6. 210.
14. Lana JP, Carneiro PM, Machado VdeC, de Souza PE, Manzi FR, Horta MC. 178 Anatomic variations and lesions of the maxillary sinus detected in cone beam 179 computed tomography for dental implants. Clin Oral Implants Res 2012;23: 180 1398–403. 181
15. Lofthag-Hansen S, Huumonen S, Grondahl K, Grondahl HG. Limited cone-beam 196 CT and intraoral radiography for the diagnosis of periapical pathology. Oral Surg 197 Oral Med Oral Pathol Oral Radiol Endod 2007;103:114–9. 198.
16. Madani G, Beale T.J. Differential diagnosis in sinonasal disease. Semin Ultrasound CT MR. 2009. Feb; 30 (1): 39-45. Doi: 10.1053/j.sult.2008.10.014.
17. Mafee M.F, Tran B.H, Chapa A.R.Imaging of rhino sinusitis and its complications: plain film, CT, and MRI. Clin.Rev Allergy Immune.2006. Jun;30(3): 165-86.doi:10.1385/CRIAI:30:3:165. 238-43.doi: 10.1007/s11882-009-0035-0.
18. Mehra P, Jeong D. Maxillary sinusitis od odontogenic origin. Curr Allergy Asthma Rep 2009. May:9(3):
19. Mossa-Basha M, Blitz A.M. Imaging of the paranasal sinuses. Semin Roentgenol.2013.Jan:48(1): 14-34. doi: 10.1053/j.ro.21012.09.006
20. Ohba T, Langlias RP, Langland OE. Antral exostosis in panoramic radiographs. 182 Oral Surg Oral Med Oral Pathol 1993;76:530–3. 183.
21. Ossenberg, N. S. Mandibular torus: a synthesis of new and previously recorded data and a discussion of its cause. In: CYBULSKI, J. S. Contribution to physical antropology, 1978/1980. Ottawa: National Museum of Canada, 1981, p. 52.
22. Pynn BR1, Kurys-Kos NS, Walker DA, Mayhall JT. Tori mandibularis: a case report and review of the literature. J Can Dent Assoc. 1995 Dec;61(12):1057-8, 1063-6.
23. Ramakrisshnan JB, Pirron JA, Perepletchikov A, Fergusson BJ. Exostoses of the paranasal sinuses . Laryngoscope 2010;120:2532-4.
24. Ramakrishnan JB, Pirron JA, Perepletchikov A, Ferguson BJ. Exostoses of the 184 paranasal sinuses. Laryngoscope 2010;120:2532–4. 185.
25. Ritter L, Lutz J, Neugebauer J, Scheer M, Dreiseidler T, Zinser MJ, et al. Preva- lence of pathologic findings in the maxillary sinus in cone-beam computerized tomography. Oral Surg Oral Med Oral Pathol Oral Radiol Endod 2011;111:634–40.
26. Schwartz K, Eckel L, Black D, Lehman V, Diehn F, Hunt C, et al. Irrigation nose: 189 CT findings of paranasal sinus exostoses. Open Neuroimag J 2012;6:90–1. 190.
27. Shah RK, Dhingra JK, Carter BL, Rebeiz EE. Paranasal sinus development: a radio- 199 graphic study. Laryngoscope 2003;113:205–9. 200.
28. Siegel WM, Pappas JR. Development of exostoses following skin graft vestibuloplasty: report of a case. J Oral Maxillofac Surg. 1986 Jun;44(6):483-4.
29. Torres, I. A. et al; Pseudotoro Mandibular e Toros Mandibulares. v.18, n.1, p.47, 1999.
30. Vallo J, Suominen-Taipale L, Huumonen S, Soikkonen K, Norblad A. Prevalence 211 of mucosal abnormalities of the maxillary sinus and their relationship to dental 212 disease in panoramic radiography: results from the Health 2000 Health Exam- 213 ination Survey. Oral Surg Oral Med Oral Pathol Oral Radiol Endod 2010;109: 214 e 80–7.
31. Watanabe PCA, Arita ES. Imaginologia e Radiologia Odontológica. 1st ed. Rio de 194 Janeiro: Elsevier; 2012. p. 45–54. 195.

DENTAL IMPLANTS PLACED BUCCALLY TO THE MANDIBULAR CANAL IN MOLAR REGIONS WITH SEVERE VERTICAL BONE LOSS: CASE REPORTS

Nilo Guliberto Martins **Chavarry**[1]*

[1]Department of Dental Clinic, Division of Periodontics, Dental School, Universidade Federal do Rio de Janeiro, Rio de Janeiro, RJ, Brazil

Palavras-chave: Nervo Mandibular. Implantes Dentários. Perda do Osso Alveolar. Perda do dente .

RESUMO

Introdução: A perda óssea alveolar severa em região posterior de mandíbula é um sério fator limitante para instalação de implantes dentários osseointegráveis. Novas técnicas cirúrgicas são necessárias visando contornar a falta de osso vertical. **Objetivo:** O objetivo deste estudo foi apresentar uma técnica alternativa de inserção de implante dentário na região posterior lateral da mandíbula em pacientes com atrofia vertical severa de rebordo alveolar. **Relatos de casos**: Foram selecionados 4 pacientes com características anatômicas específicas que atendiam aos requisitos da técnica. Seis implantes foram instalados lateralmente ao canal mandibular por vestibular e foram restaurados após o tempo de cicatrização de pelo menos dois meses. A média da avaliação de seguimento do implante foi de 3 anos. Nenhum implante foi perdido e todos eles atenderam às exigências estéticas e funcionais da oclusão, estando em ótimas condições clínicas. **Conclusão:** A técnica mostrou-se minimamente invasiva, segura, conservadora e eficaz como alternativa de tratamento para reabilitação dentária em regiões posteriores de mandíbula com atrofia óssea severa. Entretanto, ela requer experiência, preparo e habilidade do profissional que visa não lesionar o nervo alveolar inferior e, ao mesmo tempo, instalar corretamente o implante em uma posição que permita sua restauração funcional e estética.

Keywords: Inferior Alveolar Nerve. Dental Implant. Alveolar Bone Loss. Tooth Loss.

ABSTRACT

Introduction: Alveolar bone loss in posterior regions of the mandible is a serious limiting factor for the installation of osseointegrated dental implants. New surgical procedures are needed to circumvent the lack of vertical bone. **Objective:** The objective of this study was to present an alternative technique for dental implants in the lateral posterior region of the mandible in patients with severe vertical ridge atrophy **Case Reports:** Four patients with the specific anatomical characteristics that met the requirements of the technique were selected. Six implants were inserted buccally to the mandibular canal and were restored after at least two months of healing time. The mean follow up period of the implants was 3 years. No implant was lost during this time. All of them remained in excellent clinical condition and met the aesthetic criteria and functional demands of occlusion. **Conclusion:** The technique presented here proved to be minimally invasive, safe, conservative and effective as an alternative treatment option for dental rehabilitation in mandibular posterior regions with severe bone atrophy. However, it requires experience, preparation and skill of the professional in order not to damage the inferior alveolar nerve and at the same time install the implant in the correct position, thus allowing its functional and aesthetic rehabilitation.

Submitted: January 29, 2019
Modification: April 12, 2019
Accepted: April 17, 2019

***Correspondence to:**
Nilo Guliberto Martins Chavarry
Address: Av. Visconde de Pirajá - Ipanema, Rio de Janeiro - RJ, Rio de Janeiro-RJ, Zip code: 22410-920
Telephone Number: +55 21 988959113
Email: nilochavarry@gmail.com

INTRODUCTION

The placement of dental implants in the mandible posterior region (MPR) is always a challenge for dental surgeons when there is severe bone atrophy due to dental losses.[1] The reduced vertical distance (VD) between the crest of the alveolar ridge and the roof of mandibular canal (MC) makes this area unsuitable for the use of standard implants above the inferior alveolar nerve (IAN).[2] Therefore, in order to have a safety margin and not injure the IAN on drilling into the bone, it is recommended to decrease the VD by 2 millimeters to be used as the appropriate implant length in the MPR.[3] The shortest implant available in size is 4mm and so, following this rule, it requires a VD of at least 6mm to insert an implant. Several techniques of vertical ridge augmentation have been proposed in the literature to counteract this bone loss (BL). [4,5] However, there have also been many complications regarding these approaches, such as pain, edema, suture dehiscence, infection, loss of sensation and graft failure.[6] In addition, bone graft surgeries increase costs, patient morbidity and extend dental treatment. Therefore, these procedures should be avoided whenever possible. [3] One study described a 3 D topography model of the mandibular canal and the trajectory of the inferior alveolar nerve in histological sections. These authors found that in 70% of the cases these structures follow a bucco-lingual location very close to the lingual bone cortical plate, both in the ramus and in the body of the mandible. [7] According to another study that used cone beam computed tomography images (CBCT) from 500 mandibular canals, the variation of the horizontal distance (HD) between the buccal cortical plate and the mandibular canal was up to 7mm in the molar region.[8] This area may be considered suitable for dental implants.[9] The present work aimed to use this bone region to insert implants and to offer dental surgeons a simple and safe alternative to overcome difficult cases with severe posterior ridge atrophy.

CASE REPORTS

Treatment Technique

A virtual surgery was carried out beforehand on a computer, using specific Software (DentalSlice, Copyright 2015) to manipulate the dental implant using cone beam tomography. The CBTC delimits the horizontal distance precisely from the outer edge of the mandible to the canal. Based on this distance and with the aid of diagnostic waxing, the point of entry of the implant into the bone is established respecting a safety margin of nearly 1 mm from the vestibular edge and 2 mm from the MC. The inclination of the implant, in turn, is defined by the position of the opposing tooth (Figure 1E). Often, a lingual slope of approximately 25 to 30 degrees is necessary to achieve optimal occlusion. From the 3D surgical planning, a guide can be made by prototyping. It provides precise references for the transoperative procedures that allow greater accuracy in the final positioning of the implant. However, the surgical guide was not used in any of the cases in this study. But, for a less experienced professional, it can be an extremely useful device. The preoperative, transoperative and postoperative procedures were based on standard guidelines for implant placement. Blockage of the inferior alveolar nerve, lingual nerve and buccal nerve was carried out through local anesthesia with infiltrative injections. A central incision in the edentulous alveolar ridge was performed and the mucoperiosteal flap was elevated and one relaxing incision at the posterior extremity was also made. A wide lateral view of the mandible is essential to guide the preparation of the implant bed. The mandible lateral border is a major reference for implant placement without damaging the IAN. The drill was mounted at a contra-angle of 1:21 at 55,000 rpm, with a torque of 50 Ncm and with an irrigation of 50 mL/minute. The drilling usually started in the center of HD, but eventually an even more lateral approach is needed. In brief, at least, 1 mm of vestibular cortical bone must be left to assure implant integrity. Also, the depth gauges must be checked constantly as the drill penetrates into the bone to ensure the inclination of the implant aligned with the opposing tooth. The implant was then placed, and the final position checked. At the reentry surgery, the transmucosal abutment was placed, followed by a healing period of 30 days. A single and experienced operator (NGMC) performed all the surgeries and restorative procedures.

Case 1

A 60 year-old female patient with the absence of her lower posterior right teeth 29, 30, 31 and 32 complained of masticatory difficulties. No periodontal disease was detected in the remaining teeth assessed by Clinical Attachment Loss (CAL), Periodontal Pocket Depth (PPD) and Bleeding on Probing (BOP). One dentist had tried an autogenous bone block for vertical ridge augmentation (Figure 1A). The whole graft was lost due to infection (Figure 1B). A preoperative CBCT detected a VD < 5 mm and a HD of 7mm at position 31 (Figure 1C). The patient received oral hygiene instructions at two consecutive weekly sessions to lower the Plaque Index (PI) to <20% of the dental surfaces. Six months after the bone block failure, two implants were planned and inserted in the region of teeth 31 and 30 maintaining a safe distance from the mental nerve (Figure 1D). The most posterior implant in 31

position, [3.3mm diameter (D) x 10mm length (L)], whose VD was less than 5mm, was installed buccally to the MC at a 7mm HD (Figure 1E). The prosthetic planning consisted of a partially fixed metal ceramic bridge with 3 elements including the 29 in cantilever (Figure 1F,G, H). The prosthesis has been in place for 8 years and there has been no BL and no gingival inflammation around the implants. The patient reports that her chewing has returned to normal and is comfortable.

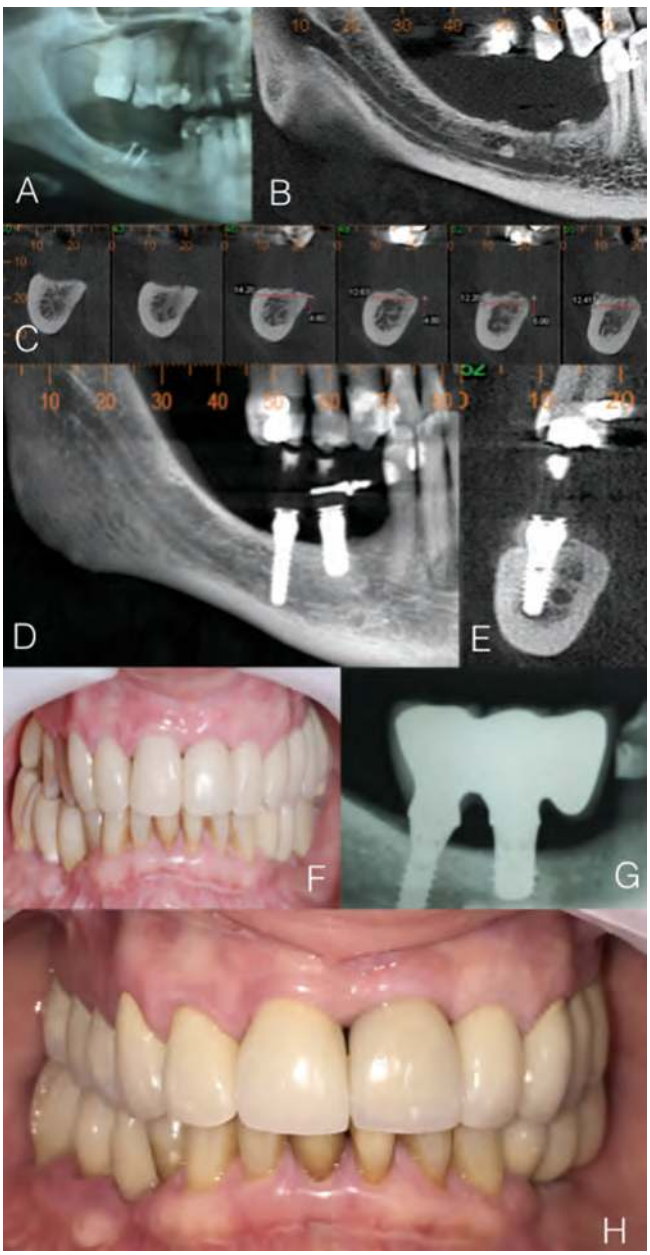

Figure 1: *[A] Bone block graft fixation screws. An attempt at vertical gain that did not work; [B,C] Panoramic and transaxial CBCT images of the mandibular canal (MC) before the implants ; [D] Implant 31 appears to have transfixed the IAN; [E] The implant 31 passes buccally to the MC; [F] Fixed Provisional Restorations (FPR). [G] X-ray of Metal-Ceramic bridge; [H] Definitive restorations.*

Case 2

A 55-year-old woman complained of having serious problems with her lower removable partial denture. At the clinic she reported she was willing to have implants in order to improve her chewing capacity. The clinical assessment showed severe BL in the MPR on both sides (Figure 2A). Tooth 26 had a mobility grade 3, with more than 50% loss of periodontal bone support (Figure 2B) probably in part because it served as a retainer and support for the removable dental prosthesis. An initial CBCT of the region of the teeth 30 and 31 showed a VD of less than 5mm (Figure 2C). Consequently, four implants were proposed to restore occlusion in the fourth quadrant (Figure 2 D,E). The two most posterior implants, [3.3mm (D) x 10mm (L)], were placed buccally to the MC (Figure 2F). Fixed Provisional Restorations (FPR) improved the chewing, swallowing and aesthetics (Figure 2G). Tooth 26 has become firm and healthy. After 4 years of follow-up the four implants are in excellent clinical condition with no signs of inflammation and no BL around the implants.

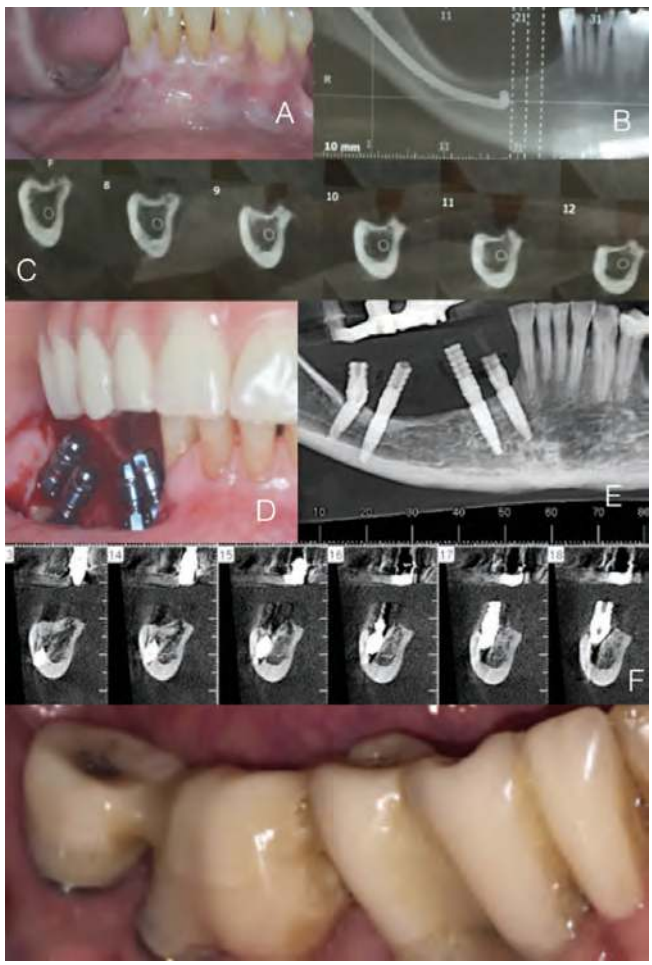

Figure 2: [A] Severe BL in the MPR; [B,C] CBCT images show the proximity of the MC to the ridge crest (VD ≤ 5mm); [D] Implants are in a good occlusal relationship with their antagonists; [E,F] The implants 30 and 31 pass buccally to the MC and are anchored in the inferior cortical of the mandible; [G] FPR.

Case 3

A 57-year-old male with a severely resorbed MPR complained of pain due to his lower removable prosthesis. The cause of the problem was his prosthesis compressing the IAN, onto the surface of the ridge due to insufficient bone above the MC (VD<1mm) (Figure 3 A,B). Two of the three implants, [3.3 (D) x 10mm (L)], that were made were anchored buccally to MC in the basilar of the mandible in positions of teeth 18 and 19 (Figure 3 C,D,E,F). The third one was installed conventionally next to the canine (Figure 3 G). The patients chewing improved considerably and after the FPR (Figure 3 H,I) he did not have any more pain. The implants have been followed up for more than a year and they are in a very good clinical and tomographic condition.

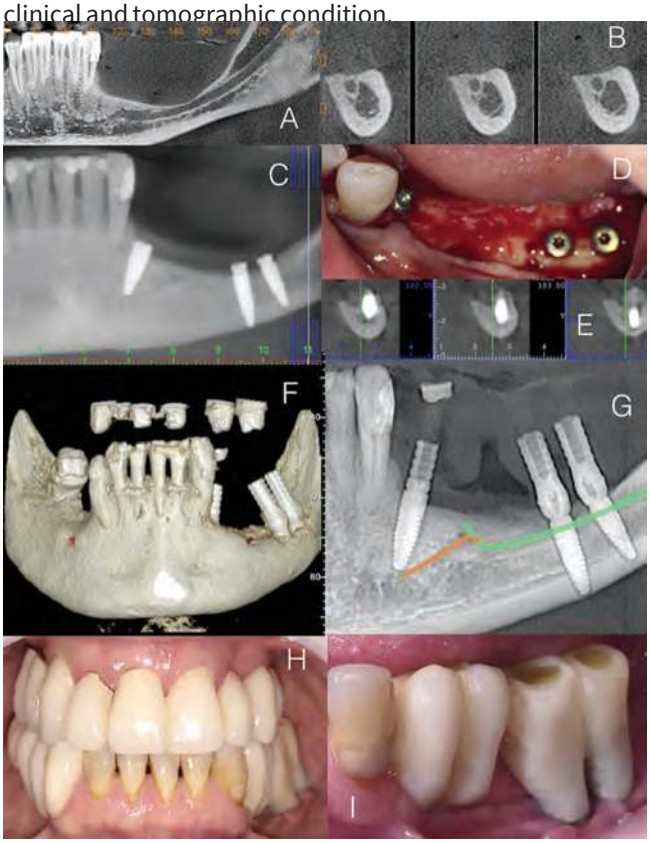

***Figure 3**: [A] Severe BL in the MPR ; [B] The Preoperative CBCT shows no bone above the canal; [C] Implants anchored in the basilar of the mandible;[D] Surgical approach; [E] The Postoperative CBCT shows the implants 18 and 19 passing alongside the nerve; [F] Mandible 3D view of the implants 18 and 19 in the extreme lateral position; [G] Panoramic view of the implants and its titanium provisional abutments; [H] Front and [I] lateral view of FPR.*

Case 4

Another case in which CBCT showed a VD < 6mm (Figure 4 A,C) was a 68-year-old female patient who came to the dental clinic using a complete removable upper prosthesis. All posterior teeth in the inferior arch were absent with the exception of tooth 28. The periodontal status assessed by CAL, PPD, PI and BOP, revealed active periodontal disease with bone loss and anterior migration of lower teeth. She underwent a nonsurgical periodontal treatment which included supra and subgingival scaling and root planning together with instructions of oral hygiene. After recovering her periodontal health (no site with PPD e" 4mm, less than 20% of sites with visible plaque and less than 30% of sites with BOP), two implants were installed in order to restore this quadrant prosthetically (Figure 4B). The most posterior implant, [3.3 (D) x 10mm (L)], was positioned BMC (Figure 4D). Despite the divergence between the angulations of the two implants (Fig. 4E), the bolted fixed prosthesis had a passive seating (Figure F). The patient reported comfort in chewing after 7 months of using her FPR. The clinical and tomographic aspects of the implants are absolutely normal and the lower anterior teeth improved their stability and clinical periodontal parameters.

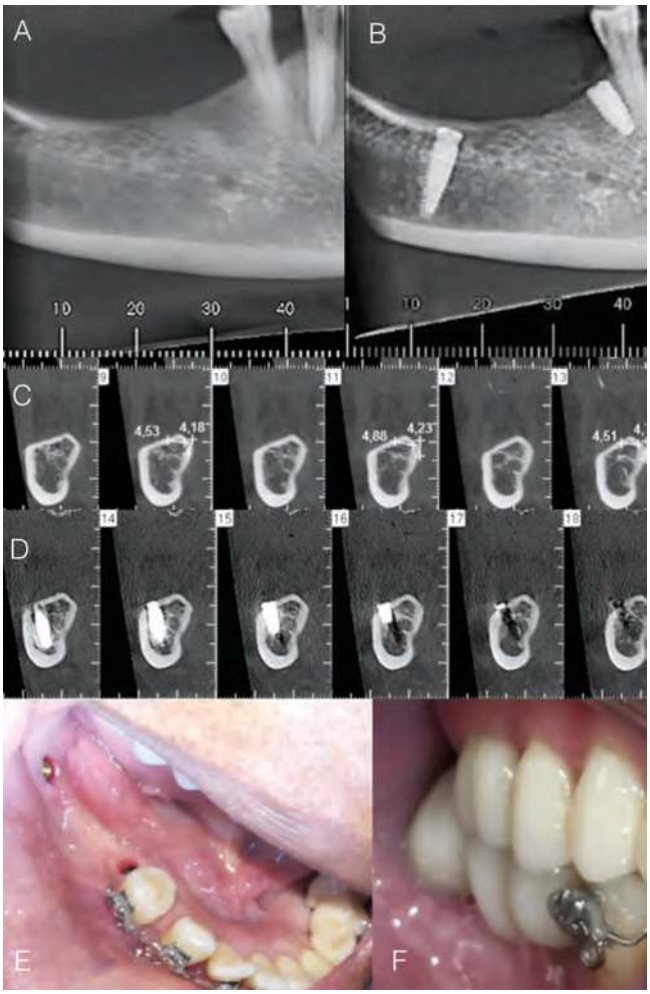

***Figure 4**: [A] Pre and [B] postoperative panoramic view; [C] Pre and [B] postoperative transaxial CBCT of the MPR ; [E] Clinical view of the Implants 31 and 29; [F] FPR in good relationship with their antagonists.*

DISCUSSION

The present study demonstrated that the six implants installed buccally to the mandibular canal had an excellent osseointegration and all of them were restored satisfactorily. No bone loss was detected by CBCT and no clinical gingival inflammation, assessed by BOP, was found around the implants during the mean follow-up time of 3 years. The absence of gingival bleeding after probing (BOP) is an important indicator of periodontal stability with a high prognostic value. Support Periodontal Therapy (SPT) was provided for all patients on a quarterly basis. Motivation and instruction of oral hygiene with interdental brushes, compact tuft and super floss every three months contributed to the excellent quality of the gingival tissue, especially around the implants. PI with less than 20% remained stable, for everyone, at each SPT session. No systemic diseases, such as diabetes mellitus, osteoporosis, arterial hypertension or smoking habits were detected during the anamnesis interview. All participants informed that they were not taking any type of therapeutic drug at baseline. Patients reported improvements in oral functions especially in their chewing and biting capacity, self-esteem, and social relationships. One patient experienced a light paresthesia that ceased spontaneously after 30 days. These results are in accordance with the results of a study that evaluated the clinical outcome of implants positioned lateral to MC over 10 years. [2] The authors reported high cumulative survival rates for implants installed alongside the IAN, and stated that this technique is conservative and predictable, [2,10] although little disseminated among implant dentists. The study reported on 135 implants, and only six were lost. Many morphometric studies regarding the course and position of the IAN have shown that there is sufficient bone available buccally to it for a dental implant, [7,8,9] but prospective clinical assessments of implants using this approach are very scarce in the literature. On the other hand, bone graft surgeries with stem-cell growth factors are gaining space in order to overcome difficulties of the vertical bone augmentation of the ridge in the MPR ,[11] but this technique increases costs, risk of failure and extend treatment time. Likewise, indications for extractions of the lower anterior teeth increase in posterior mandibular edentulous patients, especially for those professionals who opt to follow the Branemark protocol. [12,28] In fact, the peculiar anatomy of the lateral region of the mandible requires careful analysis and accurate planning to make this region possible to receive implants that must be restored with harmony for occlusal. Despite the outermost position of the implants in the arch, and due to the technique itself the biomechanical aspects in posterior occlusion must be respected. The clinician should circumvent this atypical position to obtain an optimal occlusal plane, an acceptable crown to implant ratio and establish a mutually protected occlusion to achieve a successful outcome. As soon as the mandible moves in any direction, none of the posterior teeth should be in the occlusion position. To achieve these criteria, for the six implants inserted buccally to the MC presented here, five needed 30° tilted abutments (Figure 3G) to direct the lower buccal cusp tip of the prosthetic crowns in centric relation against their antagonists and in one case only, a straight one was used (Figure 1E). The three-dimensional position of the implant in the arch is the key to the success of a restoration. Is it worth having bone, if the implant cannot be restored due to its bad position? Is it worth having an implant if it does not remain fixed in the mouth for a long time due to excessive occlusal forces? However, this lateral mandible region with a thick cortical layer surrounding the trabecular bone and this anatomical characteristic potentiates the osseointegration force of the implant. Moreover, this bone has a high mineral density, greater hardness and greater resistance to fracture compared to the posterior superior region. Another important aspect of this technique is that, unlike the ultra-short implants (4mm), or short implant (6 - 8mm) modals, longer implants of 10 to 12 mm or more can be inserted. According to some authors, implants of 6 and 8mm tested in the MPR submitted to vertical forces, presented a similar survival rate to standard-length implants and also a similar bone resorption rate. These authors concluded that increasing implant length does not increase its capacity to support loads. [13] However, horizontal forces provide greater deformations in the cortical bone than vertical forces. [14] Furthermore, the performance of the ultra-short implants has not been tested with severe BL and increased interocclusal space. [15] Incidentally, implants of 4 and 6 mm in length are not available in the narrow version and this therefore precludes their use in thin bony crests. In contrast to previous studies cited, short implants failed more than longer implants due to their reduced anchorage and lower load-bearing capacity. [10] In all the cases presented here, there was no bone height above the mandibular canal to install even the smallest implant available. Even though short implants are a viable alternative, the use of long implants, in these cases, should be the first therapeutic choice. [16] Even more stability and rigidity can be achieved if the implants are splinted in fixed multiunit reconstructions. This strategy reduces bone stress and the bending forces of the tilted implants. [17] In addition, to increase the resistance to bone fatigue and fracture even more, the basilar of the mandible can be used as an anchorage for implants to achieve a bicorticalization insertion. Also, the vertical soft and hard tissue losses due to

tooth loss present on severe ridge atrophies are compensated by the increase in the height of the prosthetic teeth, which constitutes, in fact, the crowbar that sometimes pushes the implant to the limit. Until recently, there was no reference to the maximum acceptable crown to implant ratio. The empiricism of this relationship revealed proportions much higher than the maximum recommended for crown to root ratio (which is 1). Fortunately, implants support crowns greater than their length better than natural roots do. The 5th EAO Consensus Conference 2018 states that the use of singletooth restorations with crown to implant ratio between 0.9 and 2.2 is not expected to increase BL or failure rates and therefore it is a viable treatment option.[15] Due to the limited amount of bone buccally to MC and to preserve IAN integrity, the use of small diameter implants (SDI) is almost always recommended. All the implants inserted in this case report had a 3.3mm diameter, exactly the same diameter as all 135 implants installed lateral to the MC in the retrospective study, mentioned previously. [2] This could be considered a shortcoming of this technique, if it were not for the resistance of the material, used to make the dental implants, against fracture. Binary titanium-zirconium (TiZr) alloys were used in all six implants (SDI) reported in this study, and they demonstrated strengths of up to 40% greater than conventional grade IV titanium implants.[18] Although specific indication for SDI has been primarily for the incisor region, some studies have demonstrated high success rates in selected MPRs.[19] Another aspect to mention concerning the buccal approach is the lack of keratinized tissue (KT) in this region. This can be considered a weak point of the technique that must be overcome by respecting all the periodontal biological principles that should be applied by analogy to dental implants. Among them are the precise adaptation of the restorations and the manufacturing of the correct emergent profile, which must allow easy access to clean all the prosthetic surfaces, especially the interproximal areas. The patient should be included in a strict periodontal maintenance program, with frequent visits to the dentist, in order to have healthy long-life implants, even in areas with little or lacking masticatory mucosa. [20] Finally, it is worth emphasizing that this technique may be a simple option to reconstruct the posterior teeth in severe atrophic mandibles such as Kennedy class 1 cases and then carry out the maintenance of the anterior teeth in the mouth instead of extracting them to install a Branemark protocol.[15] The preservation of natural teeth with their mechanoreceptors in the periodontal ligament constitutes a protective factor for the maintenance of healthy implants over the years as well as for better control of the occlusal overload on peri-implant tissue. Prospective randomized long-term studies should be performed aimed at comparing the implants placed buccally to the mandibular canal with implants placed above the IAN after bone augmentation procedures.

CONCLUSION

The implants inserted buccally to the mandibular canal in the first and second molar regions may be considered effective and as an alternative technique for the rehabilitation of posterior atrophic ridges with severe vertical bone loss.

ACKNOWLEDGMENTS

I would like to thank Professor Eduardo Jorge Feres-Filho for teaching me the first steps in implantology.

REFERENCES

1. Stellingsma C, Vissink A, Meijer HJA, Kuiper C, Raghoebar GM. Implantology and the Severely Resorbed Edentulous Mandible. Crit Rev Oral Biol Med. 2004;15(4):240–8.
2. Cruz M, Cruz G, Cruz F, Morales-Vadillo R, Cruz-Pierce S. Lateral Approach to the Maxillary Sinus and Mandibular Canal in Severely Atrophied Posterior Alveolar Bone. Int J Oral Maxillofac Implants. 2018;33(2):412–8.
3. Bolle C, Felice P, Barausse C, Pistilli V, Trullenque-Eriksson A, Esposito M. 4 mm long vs longer implants in augmented bone in posterior atrophic jaws: 1-year post-loading results from a multicentre randomised controlled trial. Eur J Oral Implantol. 2018;11(1):31–47.
4. Louis PJ. Vertical Ridge Augmentation Using Titanium Mesh. Oral Maxillofac Surg Clin North Am. 2010;22(3):353–68.
5. Felice P, Marchetti C, Iezzi G, Piattelli A, Worthington H, Pellegrino G, et al. Vertical ridge augmentation of the atrophic posterior mandible with interpositional bloc grafts: bone from the iliac crest vs. bovine anorganic bone. Clinical and histological results up to one year after loading from a randomized-controlled clinical trial. Clin Oral Implants Res. 2009;20(12):1386–93.
6. Kaing L, Grubor D, Chandu A. Assessment of bone grafts placed within an oral and maxillofacial training programme for implant rehabilitation. Aust Dent J. 2011 Dec;56(4):406–11.
7. Kim ST, Hu K-S, Song W-C, Kang M-K, Park H-D, Kim H-J. Location of the mandibular canal and the topography of its neurovascular structures. J Craniofac Surg. 2009 May;20(3):936–9.
8. Leite GMF, Lana JP, de Carvalho Machado V, Manzi FR, Souza PEA, Horta MCR. Anatomic variations and lesions of the mandibular canal detected by cone beam computed tomography. Surg Radiol Anat. 2014 Oct;36(8):795–804.
9. Daróz SR, Cardoso ES, Manso MC, Vidigal GM Jr. Evaluation

of bone width lateral to the mandibular canal as an alternative approach for implant installation. Implant Dent. 2013 Feb;22(1):97–101.
10. Krekmanov L. Placement of posterior mandibular and maxillary implants in patients with severe bone deficiency: a clinical report of procedure. Int J Oral Maxillofac Implants. 2000 Sep;15(5):722–30.
11. Gjerde C, Mustafa K, Hellem S, Rojewski M, Gjengedal H, Yassin MA, et al. Cell therapy induced regeneration of severely atrophied mandibular bone in a clinical trial. Stem Cell Res Ther [Internet]. 2018;9(1). Available from: http://dx.doi.org/10.1186/s13287-018-0951-9
12. Brånemark P-I, Zarb GA, Albrektsson T. Tissue-integrated prostheses: osseointegration in clinical dentistry. Quintessence Pub Co; 1985. 350 p.
13. Scarano A, Mortellaro C, Brucoli M, Lucchina AG, Assenza B, Lorusso F. Short Implants: Analysis of 69 Implants Loaded in Mandible Compared With Longer Implants. J Craniofac Surg [Internet]. 2018 Apr 4; Available from: http://dx.doi.org/10.1097/SCS.0000000000004518
14. Cozzolino F, Apicella D, Wang G, Apicella A, Sorrentino R. Implant-to-bone force transmission: a pilot study for in vivo strain gauge measurement technique. J Mech Behav Biomed Mater. 2018 Oct 15;90:173–81.
15. Hämmerle CHF, Cordaro L, Apaza Alccayhuaman KA, Botticelli D, Esposito M, Colomina LE, et al. Biomechanical aspects: Summary and consensus statements of group 4. The 5th EAO Consensus Conference 2018. Clin Oral Implants Res. 2018;29:326–31.
16. Renouard F, Nisand D. Impact of implant length and diameter on survival rates. Clin Oral Implants Res. 2006 Oct;17 Suppl 2:35–51.
17. Krekmanov L, Kahn M, Rangert B, Lindström H. Tilting of posterior mandibular and maxillary implants for improved prosthesis support. Int J Oral Maxillofac Implants. 2000 May;15(3):405–14.
18. Grandin HM, Michelle Grandin H, Berner S, Dard M. A Review of Titanium Zirconium (TiZr) Alloys for Use in Endosseous Dental Implants. Materials . 2012;5(8):1348–60.
19. Jackson BJ. Small-Diameter Implants: A 7-Year Retrospective Study. J Oral Implantol. 2017 Apr;43(2):125–9.
20. Wennström JL, Bengazi F, Lekholm U. The influence of the masticatory mucosa on the peri-implant soft tissue condition. Clin Oral Implants Res. 1994 Mar;5(1):1–8.

DIRECT BONDED SPACE MAINTAINER: AN ALTERNATIVE IN CLINICAL PRACTICE AFTER UNILATERAL PREMATURE LOSS OF POSTERIOR PRIMARY TOOTH

Camila Silva de **Amorim**[1], Gabriella Fernandes **Rodrigues**[1], Rafael dos Reis **Moraes**[1], Lucianne Cople **Maia**[1], Matheus Melo **Pithon** [2*]

[1]Department of Pediatric Dentistry and Orthodontics, Universidade Federal do Rio de Janeiro (UFRJ), Rio de Janeiro, RJ, Brazil.
[2]Department of Healthy I, Southwest Bahia State University (UESB), Jequié, BA, Brazil and Department of Pediatric Dentistry and Orthodontics, Universidade Federal do Rio de Janeiro (UFRJ), Rio de Janeiro, RJ, Brazil.

Palavras-chave: Mantenedor de Espaço. Dente Decíduo. Resina Composta. Má Oclusão.

RESUMO

Introdução: A dentição decídua é de extrema importância, pois exerce função mastigatória, atua como guia de erupção para os dentes permanentes, estimula o crescimento ósseo e auxilia na digestão e fonação. Em casos de perda prematura de algum dente, é necessário que o profissional faça um planejamento adequado para manutenção do espaço, de forma que este não seja perdido até a erupção do sucessor permanente, evitando assim o estabelecimento de más-oclusões. **Objetivo:** Descrever as etapas clínicas para confecção e instalação do aparelho mantenedor de espaço adesivo, bem como o acompanhamento até a erupção do sucessor. **Relato do caso:** Menina, 8 anos, apresentou fístula adjacente ao segundo molar inferior direito decíduo. Após avaliação clínica e radiográfica, foi indicada a exodontia do dente, devido à impossibilidade de realizar o tratamento endodôntico. Confeccionou-se e instalou-se o aparelho mantenedor de espaço adesivo, como uma alternativa ao banda-alça, comumente utilizado nesses casos de perda unilateral. **Conclusão:** O mantenedor de espaço colado foi uma boa opção para o caso apresentado, pois foi capaz de cumprir sua função até a erupção do dente sucessor, constituindo-se uma boa alternativa na prática clínica, devido à otimização do tempo e economia de material que proporciona.

Keywords: Space Maintenance. Deciduous Tooth. Composite Resins. Malocclusion.

ABSTRACT

Introduction: The primary dentition is extremely important, because besides the importance during chewing, acts as a guide to eruption for permanent teeth, stimulates the bone growth and helps in digestion and phonation. In cases of premature loss, it is necessary that the professional make adequate planning to space maintenance, so that it is not lost until the eruption of the permanent successor, thus avoiding the establishment of malocclusions. **Objective:** To describe the clinical steps for preparation and placement of a direct bonded space maintainer, as well as the follow-up until the eruption of the successor tooth. **Case report:** Girl, eight years old, presented an adjacent fistula to the primary mandibular right second molar. After clinical and radiographic evaluation, tooth extraction was indicated, due to the impossibility of performing the endodontic treatment. A direct bonded space maintainer was made and installed as an alternative to the band and loop, commonly used in these cases of unilateral loss. **Conclusion:** The direct bonded space maintainer was a good option for the case presented, as it was able to fulfill its function until the eruption of the successor tooth. It is a good alternative in clinical practice due to the time optimization and material savings it provides.

Submitted: Febuary 14, 2019
Modification: March 20, 2019
Accepted: March 25, 2019

***Correspondence to**:
Matheus Melo Pithon
Address: Av. Otávio Santos, 395, sala 705, Centro Odontomédico Dr. Altamirando da Costa Lima, Recreio, CEP 45020-750 – Vitória da Conquista – Bahia, Brazil
Telephone Number:
E-mail: matheuspithon@gmail.com

INTRODUCTION

The primary dentition is very important because besides the importance during chewing, acts as a guide for the eruption of permanent teeth, stimulates the bone growth and aids in digestion and phonation.[1] Therefore, premature loss of primary teeth can result in some negative consequences in both dentitions and cause an imbalance in the normal development of the stomatognathic system.[1]

Some of the main reasons that lead to premature extraction of deciduous teeth are pulpal pathology and alveolar bone abscess due to carious lesions or trauma.[2, 3] The loss of primary teeth before normal physiological exfoliation might result in the collapse of vertical and horizontal occlusal relationships in primary and permanent dentitions.[4] In this way, the placement of space maintainers becomes necessary after premature loss of primary teeth to preserve the integrity of the dental arch.[5]

Although the literature is divergent on the indication of space maintainers, it is generally considered important for children during the mixed dentition stage,[3] being important to consider the child's stage of dental development, the dental arch involved and what primary tooth is missed [6]. One of the most commonly used space maintainers in pediatric dentistry is the band and loop,[7] which is indicated for the premature loss of single, unilateral or bilateral, maxillary or mandibular primary molars.[4]

Some complications related to the use of the band and loop space maintainer include, caries as a result of cement loss, loop fracture with the wire embedded into the gingival tissues, an inability to control for rotations or tipping of the supporting teeth, and gingival inflammation.[8] There are also financial disadvantages related to the lab cost and the chair time for the two appointments associated with preparation of the device and delivery. [3] These disadvantages have led to the development of space maintainers using new designs and materials, such as the use of direct bonded space maintainers.[8]

Therefore, the aim of this case report is to describe the clinical steps for preparation and placement of a direct bonded space maintainer, as well as the follow-up until the eruption of the successor tooth.

CASE REPORT

Girl, eight years old, attended at Pediatric Dentistry Dental Clinic at School of Dentistry – Universidade Federal do Rio de Janeiro with a chief complain of swelling of the right side of the mouth, near the tooth. Medical history revealed no systemic abnormalities. At the oral examination, the child was in the mixed dentition, and presented palate atresia, Angle class II molars, convex profile, 5 mm overjet and anterior open bite associated had mouth breathing. A Composite Resin restoration was found in primary mandibular left first molar, a Glass Ionomer restoration was found in the primary mandibular right second molar (Figure 1A) with adjacent fistula (Figure 1B) and absence of active carious lesions in the remaining teeth.

At the radiographic examination of the primary mandibular right second molar, radiopaque restorative material was observed in half of the dentin extension, with an underlying radiolucent area (Figure 2A). In the panoramic radiography previously requested to aid in orthodontic planning, it was observed the root of the deciduous tooth had more than 2/3 rhizolyze and the permanent successor was in Nölla's stage 7 (Figure 2B). Due to the clinical and radiographic characteristics, the extraction of the primary mandibular right second molar and the placement of a direct bonded space maintainer were indicated. To avoid contamination of the conditioned enamel with blood, the bonding of the maintainer was performed before the extraction. The child was cooperative and all the clinical procedure was performed in a single appointment, without the need of previous molding to make the maintainer.

To begin, the referring space to the tooth which would be extracted was measured using a millimeter ruler (Maquira, Maringa, PR, Brazil). The measurement was transferred for the stainless steel wire 0,9mm, 036" (Morelli, Sorocaba, SP, Brazil) with aid a pen (Pilot, São Paulo, SP, Brazil) (Figure 3A). Straight folds (Figure 3BC) with loopings at its ends (Figure 3D) to increase retention of composite resin were made with the help of bird beak pliers #139 (Starlet, São Paulo, SP, Brazil). The supporting teeth used for the placement of the maintainer were the permanent mandibular right first molar and mandibular right first premolar.

The bonding was performed after the teeth prophylaxis with a paste of pumice stone (SS White, São Paulo, SP, Brazil) and water, with the aid of a rubber cup (Microdont, São Paulo, SP, Brazil) in low-speed motor. Enamel conditioning was performed with 37% phosphoric acid (Condac 37, FGM, Joinville, SC, Brazil), for thirty seconds, washing with water for twice the time, adhesive system application (Prime & Bond 2.1, Dentsply, Petrópolis, RJ, Brazil) and bonding the wire to the teeth with composite resin (Z100, 3M ESPE, Saint Paul, MN, USA), following the manufacturer's instructions.

The tooth extraction was performed after drying the mucosa, topical (Benzotop 200mg/g, Rio de Janeiro, RJ, Brazil) and local anesthesia of the inferior alveolar and lingual nerves, with complementation in vestibular papilla, using lidocaine 2% with epinephrine 1: 100.000 (Alphacaine 100,

DFL, Rio de Janeiro, Brazil). The tooth was detached and dislocated with the aid of a Molt detacher (Duflex/ SS White, São Paulo, SP, Brazil) and child forceps # 21 (Quinelato, São Carlos, SP, Brazil).

After hemostasis of the region, both the child and the parents were instructed that food should be liquid/pasty and cold on the first two days. To facilitate clot formation in the alveolus, it was advised that the child should rest during the day, after the extraction, in a way that the head would be higher in relation to the body. In addition, it was informed that the anesthesia would last for a few hours and that they should be aware of the child's behavior during this period, preventing her from biting the cheek/lips and consequently a soft tissue trauma.

Instructions on care after placement of the device were also passed. The oral hygiene instructions were reinforced, encouraging flossing daily and brushing with fluoride dentifrice, supervised by parents at least at night. Furthermore, it was advised to avoid chewing hard and/or sticky foods on the device. Besides that, if any failure occurred, especially the wire fracture or adhesive failure in one or both supporting teeth, parents and patient were instructed to make contact with the professionals responsible for the treatment. The child was asked to return in seven days for healing follow-up.

Every twenty-seven days, a follow-up was done to check the adherence of the maintainer or any situations that were out of the expected. Approximately three months after, in the appointments performed during interceptive orthodontic treatment, the eruption of the successor tooth was observed (Figure 4). In this way, the direct bonded space maintainer was removed and the remaining composite resin was removed with multilayer drills in low-speed. The occlusion was checked and the enamel of the supporting teeth was polished.



Figure 1: *A - Composite resin restoration in primary mandibular left first molar, Glass Ionomer restoration in primary mandibular right second molar. B - Dental fistula adjacent to the primary mandibular right second molar.*

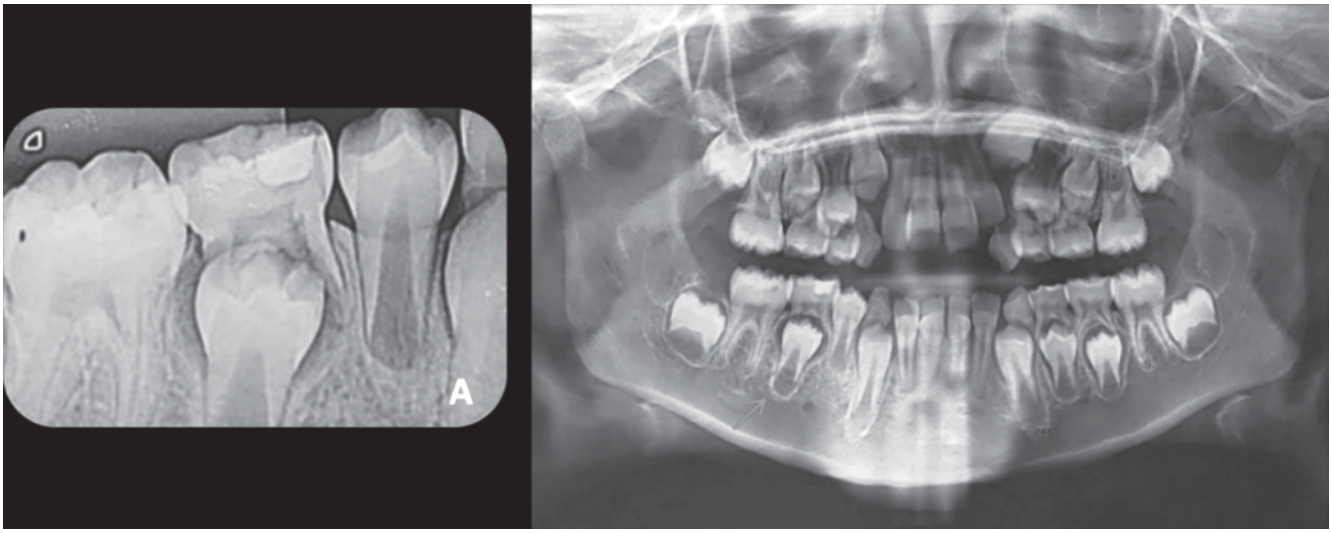

Figure 2*: A - Periapical radiograph showing radiopaque restorative material in half of the dentin extension, with an underlying radiolucent area. B - Panoramic radiograph showing the root of the deciduous tooth had more than 2/3 rhizolyte and the permanent successor was in Nölla's stage 7.*

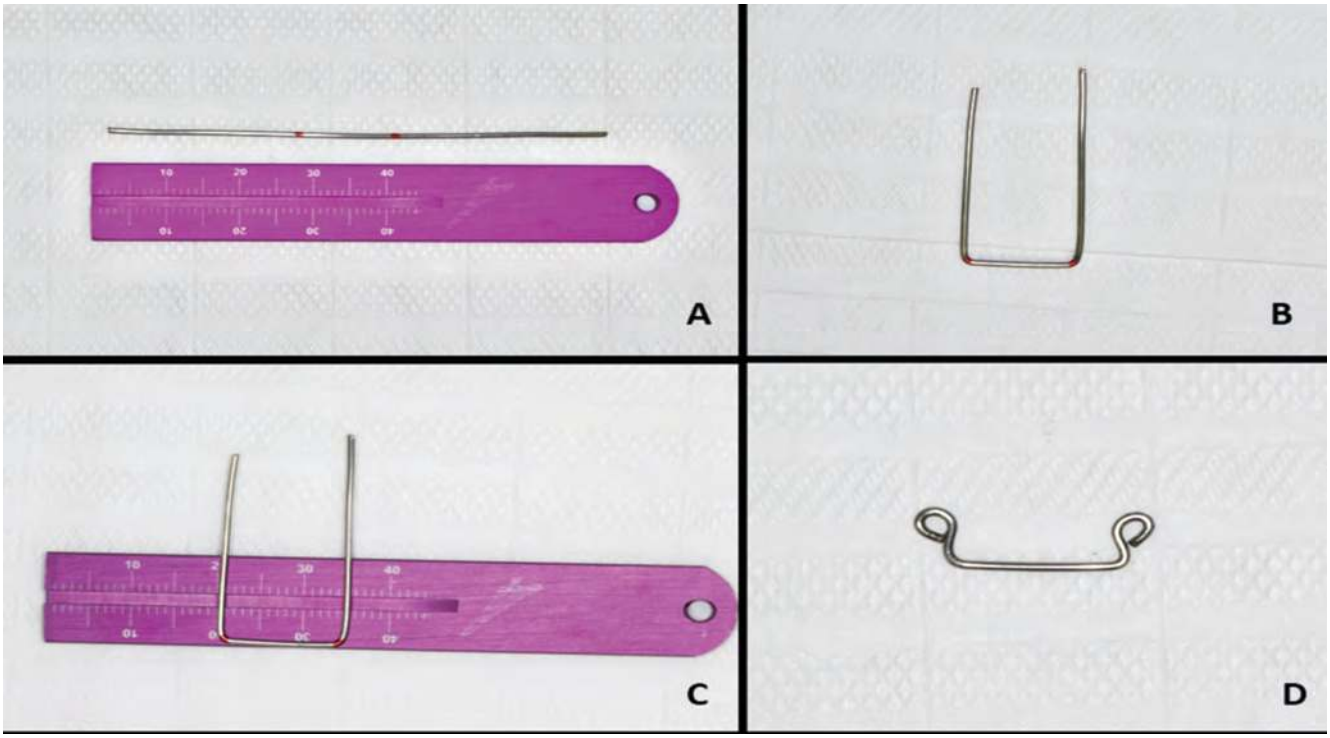

***Figure 3**: A - Transfer of space from the tooth to the wire. B- Straight folds over pen markings. C - Check of space measurement after wire fold. D - Maintainer completed after the looping realization at the ends that would be bonded on the teeth.*

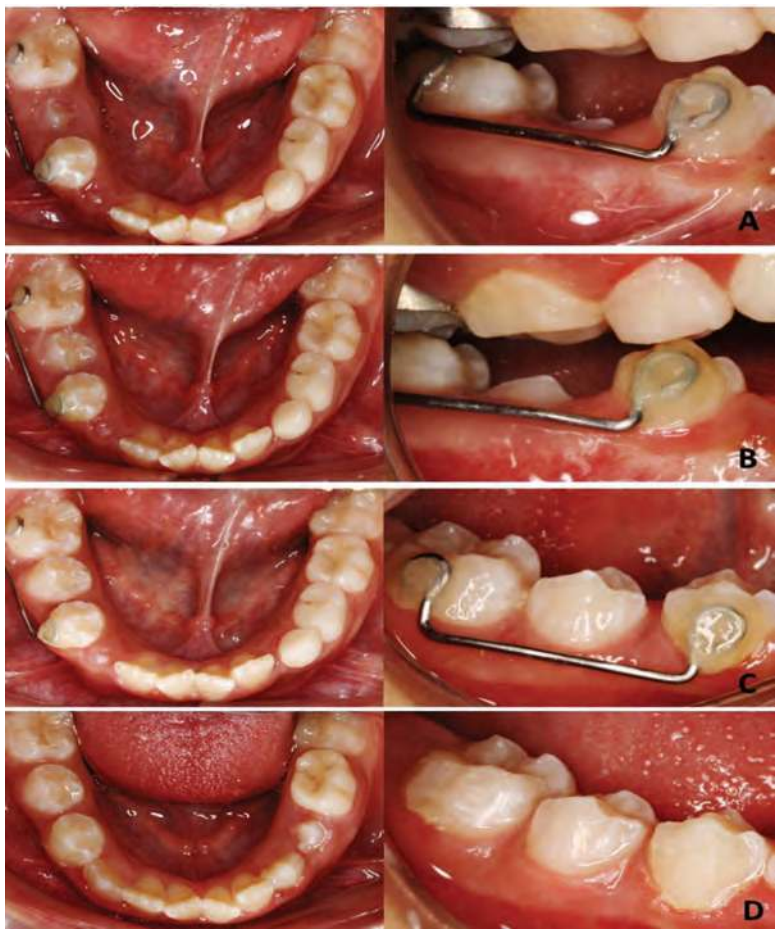

***Figure 4**: Clinical follow-up of the direct bonded space maintainer and sucessor eruption. A - Twenty-seven days later. B - Fifty-four days later. C - Eighty one days later. D - Clinical appearance after the removal of the device.*

DISCUSSION

As described in the case report, the primary mandibular right second molar had a dental fistula and the extraction was indicated due to advanced rhizolysis and impossibility of endodontic treatment. According to the literature, tooth loss after Nölla's stage 6, causes acceleration of eruption of the successor tooth, however if it occurs before Nölla's stage 8, it is indicated the placement of the space maintainer.[9] As the child's tooth was still in Nölla's stage 7, it was chosen by the direct bonded space maintainer, whose effectiveness in preserving the space loss has been proven in previous studies.[10-12]

This type of space maintainer can easily be prepared by the professional during the dentist appointment, without the need of lab stage.[11] This is one of the advantages of the present adhesive maintainer compared with the traditional and most used band and loop space maintainer for posterior unilateral loss.[4] In addition to the time-saving, because it is done in a single step, there is also material saving. Alginate impressions are usually made to construct a working dental stone model, to serve as a basis for making the device.[8] However, in this case, the stainless steel wire was folded and adjusted directly on the supporting teeth, thus eliminating material expenditure and one more clinical step.

The most common cause of failure of direct bonded space maintainers is the failure of the composite-enamel bond.[13] However, due to the fact that primary extraction happened when the radicular formation of the permanent was in Nölla's stage 7, there was an acceleration in its eruption and the maintainer only stayed for a period of three months, such failure was not observed throughout the treatment. In a study found in the literature, the mean survival length in months was 9.20.[8] Due to the time of treatment reported to have been lower than that generally observed, the failures may not have occurred. However, it is important to keep in mind that maintainers should be selected, with the expectation that the period of space maintenance will likely require replacements, repairs and perhaps even a number of different types of space maintainers until the endpoint of therapy.[13]

Parents and patient collaboration for the proposed treatment, following the instructions given at the time of the device placement, are essential for the good prognosis of the case. Another fact that may have collaborated for not to have adhesiveness failure, was that unlike the design of direct bonded space maintainers made in other studies,[8,10,11] in this case report a looping was made at the ends of the wire, where the composite resin would be added, offering greater retention. This looping by generating a rounded contour would also prevent a piercing lesion in the child mucosa if this maintainer loosened. In addition, all steps of the adhesive technique were followed carefully and using good quality materials. The different space maintainer designs, bonding systems, and resin materials used in the different studies can explain the variation of the failure rate of these maintainers between the studies.[8]

It is known that there is no strong evidence that favors a particular method of space maintenance.[13] However, in face of the premature loss of primary molars, it is necessary to plan and deliver the more appropriate space maintainer, even knowing that space maintenance starts with preserving natural teeth free of caries.[14] To determine the best maintainer for each case, it is important to perform a good diagnosis, keeping in mind the estimated time that the maintainer will be used until the eruption of the successor tooth. The integrity of the appliance also depends on the correct execution of the chosen technique and the maintenance in periodic appointments, such as those in this case that were monthly.

In this way, this case report can conclude that the direct bonded space maintainer was a good choice for the case presented, because it was able to fulfill its function until the successor tooth eruption. For providing time optimization and material savings, can be used in situations where there is a limitation of available materials, as in the public service. Also, in cases where the acceleration of the successor's eruption is expected and the time of stay in function is lower, minimizing the chance of failures to occur.

ACKNOWLEDGEMENT

This Case Report was conducted during the master's stage of Camila Silva de Amorim under the supervision of the Prof. Matheus Melo Pithon. This Case Report was partially supported by Coordenação de Aperfeiçoamento de Pessoal de Nível Superior – Brasil (CAPES) – Finance code 001

REFERENCES

1. Lopez-Gomez SA, Villalobos-Rodelo JJ, Avila-Burgos L, Casanova-Rosado JF, Vallejos-Sanchez AA, Lucas-Rincon SE, et al. Relationship between premature loss of primary teeth with oral hygiene, consumption of soft drinks, dental care, and previous caries experience. Scientific reports. 2016;6:21147.
2. Dentistry AAoP. Management of the Developing Dentition and Occlusion in Pediatric Dentistry. Pediatric dentistry. 2017;39(6):334-47.
3. Law CS. Management of premature primary tooth loss in the child patient. Journal of the California Dental Association. 2013;41(8):612-8.

4. Srivastava N, Grover J, Panthri P. Space Maintenance with an Innovative “Tube and Loop” Space Maintainer (Nikhil Appliance). International journal of clinical pediatric dentistry. 2016;9(1):86-9.
5. Lin YT, Lin WH, Lin YT. Immediate and six-month space changes after premature loss of a primary maxillary first molar. Journal of the American Dental Association (1939). 2007;138(3):362-8.
6. Qudeimat MA, Fayle SA. The longevity of space maintainers: a retrospective study. Pediatric dentistry. 1998;20(4):267-72.
7. Qudeimat MA, Sasa IS. Clinical success and longevity of band and loop compared to crown and loop space maintainers. European archives of paediatric dentistry : official journal of the European Academy of Paediatric Dentistry. 2015;16(5):391-6.
8. Tunc ES, Bayrak S, Tuloglu N, Egilmez T, Isci D. Evaluation of survival of 3 different fixed space maintainers. Pediatric dentistry. 2012;34(4):e97-102.
9. Ruellas A, Nojima, MC, Araújo, MTS, Sant’anna, EF, Freitas, AOA. Análise das dentições, manutenção e recuperação de espaço, pequenos movimentos. In: Maia L, Primo, LG. Odontologia integrada na infância. 1. São Paulo: Gen/ Santos; 2012.
10. Santos VL, Almeida MA, Mello HS, Keith O. Direct bonded space maintainers. The Journal of clinical pediatric dentistry. 1993;17(4):221-5.
11. Simsek S, Yilmaz Y, Gurbuz T. Clinical evaluation of simple fixed space maintainers bonded with flow composite resin. Journal of dentistry for children. 2004;71(2):163-8.
12. Yilmaz Y, Kocogullari ME, Belduz N. Fixed space maintainers combined with open-face stainless steel crowns. The journal of contemporary dental practice. 2006;7(2):95-103.
13. Ahmad AJ, Parekh S, Ashley PF. Methods of space maintenance for premature loss of a primary molar: a review. European archives of paediatric dentistry : official journal of the European Academy of Paediatric Dentistry. 2018;19(5):311-20.
14. Simon T, Nwabueze I, Oueis H, Stenger J. Space maintenance in the primary and mixed dentitions. The Journal of the Michigan Dental Association. 2012;94(1):38-40.

COMPLICATED CROWN FRACTURE TREATMENT AND ITS IMPACT ON QUALITY OF LIFE RELATED TO ORAL HEALTH: REPORT OF TWO CASES

Lívia Roberta Piedade **de Oliveira**[1], Tacíria Machado **Bezerra**[1], Thaís Rodrigues Campos **Soares**[1], Patrícia de Andrade **Risso**[2], Lucianne Cople **Maia**[1*]

[1]Department of Pediatric Dentistry and Orthodontics, School of Dentistry, Federal University of Rio de Janeiro, Rio de Janeiro, RJ, Brazil.
[2]Department of Dental Clinic, School of Dentistry, Federal University of Rio de Janeiro, Rio de Janeiro, Rj, Brazil.

Palavras-chave: Traumatismo. Dentes Permanentes. Fratura Coronária Complicada. Qualidade de Vida.

RESUMO

Objetivo: O objetivo do estudo foi relatar o manejo de duas fraturas complicadas de incisivos permanentes e como o tratamento destas lesões dentárias influencia a qualidade de vida relacionada à saúde bucal (QHRQoL). **Relato de caso:** No primeiro caso, foi realizada pulpectomia devido necrose pulpar e rizogênese completa. No segundo caso, a pulpotomia foi realizada, pois, a polpa apresentava vitalidade e o dente rizogênese incompleta. A colagem dos fragmentos foi realizada em ambos os casos. QHRQoL foi avaliada antes e uma semana após o tratamento. No caso 1, os escores variaram de 32 a 9 no CPQ[11-14], de 42 a 12 no P-CPQ e de 24 a 4 no FIS. No caso 2, os escores variaram de 38 a 20 no CPQ[8-10], de 94 a 28 no P-CPQ e de 39 a 10 no FIS. **Conclusão**: A colagem de fragmentos é uma solução eficiente, assim como a terapia endodôntica. Além disso, o tratamento do traumatismo dentário promoveu uma melhora na qualidade de vida das crianças e suas famílias, e podendo ser observado uma semana após o tratamento.

Keywords: Trauma. Permanent Teeth. Complicated Crown Fracture. Quality of Life.

ABSTRACT

Objective: The purpose of this study was to report on the management of two complicated crown fractures of the permanent incisors and how the treatment of these injuries influences quality of life related to oral health (QHRQoL). **Case report**: In the first case, pulpectomy was performed because of pulp necrosis and complete rhizogenesis. In the second case, pulpotomy was performed, as the pulp had vitality and the tooth had incomplete rhizogenesis. Fragment bonding was carried out in both cases. QHRQoL was assessed before and one week after treatment. In case 1, scores varied from 32 to 9 in the CPQ[11-14,] from 42 to 12 in the P-CPQ, and from 24 to 4 in the FIS. In case 2, scores varied from 38 to 20 in the CPQ[8-10], from 94 to 28 in the P-CPQ, and from 39 to 10 in the FIS. **Conclusion**: Fragment bonding is an efficient solution, as well as endodontic therapy. Furthermore, dental trauma treatment improved the quality of life of children and their families and could be observed one week after treatment.

Submitted: November 13, 2018
Modification: January 10, 2019
Accepted: January 14, 2019

***Correspondence to:**
Professor Lucianne Cople Maia
Address: Federal University of Rio de Janeiro, caixa Postal 68066,
Cidade Universitária, CCS, Rio de Janeiro, CEP: 21941971, Brazil.
Telephone Number: +55 (21) 25622098
Fax:+55 21 25622098
E-mail: rorefa@terra.com.br

INTRODUCTION

Traumatic dental injuries (TDI) in children and adolescents are a serious public health problem.[1] Falling down is the most common cause of dental trauma in this population, occurring more frequently in boys than in girls. The upper central incisors are the most affected teeth due to their position in the arch.[2,3]

Crown fractures involve enamel and dentin, which can be classified into uncomplicated fractures, when no pulp exposure occurs, and complicated fractures when exposure occurs. The treatment of fractures is mostly restorative, and may or may not require endodontic therapy. Some factors such as rhizogenesis, the duration and extent of pulp exposure, pulp vitality, and fracture extension should be taken into account in therapeutic planning.[4-7]

TDI lead to several consequences, such as aesthetic alterations, discoloration, pain, and discomfort, which can lead to children not smiling or speaking in a natural way, perhaps affecting self-concept and social relationships. These situations impact on children's quality of life and treatment can improve quality of life related to oral health (QHRQoL) scores.[8-11]

The aim of this study was to describe the clinical approach to two paediatric patients after a complicated crown fracture and to evaluate the impact of TDI treatment on the QHRQoL of the children and their families related to oral health.

CASE REPORT

In the first case, a 12-year-old boy who had suffered a dental injury was referred to a public hospital less than 30 min after the accident, but no clinical procedures were performed. The mother was instructed to keep the dental fragment in saline solution and he was prescribed anti-inflammatory medication. After 6 months, the mother brought the boy to the Dental Trauma Surveillance Centre (DTSC) of the Department of Paediatric Dentistry at Federal University of Rio de Janeiro, with complaints regarding aesthetics and a bad odour from the tooth.

During anamnesis, the mother reported that the boy had been playing soccer at school. After TDI, the patient had a history of psychological violence within the last 6 months at school, due to bullying from the other children about his smile and broken tooth. Even though he suffered bullying, he said that he was not ashamed of smiling, but he wanted to reattach the dental fragment.

The intraoral exam revealed good oral hygiene and the overjet was not increased. The permanent maxillary left central incisor presented a complicated crown fracture in the enamel and dentin (Figure 1A). The tooth did not respond to thermal sensitivity or percussion tests.

Periapical radiographic examination showed complete canal root development, closed apices, no periapical pathology, and the absence of root or alveolar bone fractures (Figure 1B).

Endodontic treatment was performed before the reattachment of the fractured fragment (Figure 1C), which was kept for 6 months in saline solution. Etching and bonding to the tooth with flow resin was performed (Figure 1D).

In the second case, an 8-year-old girl suffered a dental trauma while taking a shower. She fell down on the floor in the presence of her grandmother, who called by phone to her private dentist to ask for advice. In order to stop the bleeding around the TDI, she was instructed to drink ice water, put ice cubes in her mouth and take anti-inflammatory medication. She was requested to keep the dental fragment in saline solution. A couple of hours later, the mother was able to take the girl to her private dentist, who suggested extraction and an implant. The mother found it better to ask for a second opinion.

The mother searched for treatment at the DTSC, less than 24 h after the occurrence of the TDI, due to aesthetic complaints. The girl was very embarrassed about her smile and very afraid to lose her tooth.

During anamnesis, the mother said how worried they both were due to the possibility of losing the tooth and she looked very upset.

Increased overjet was observed in the extraoral exam and in the intraoral exam, the permanent right maxillary central incisor was clearly damaged (Figure 2A). A sensitivity test was not performed in order to not provoke pain, but it was evident that the pulp was vital (Figure 2B). The dental fragment was kept in water (Figure 2C). Clinical and radiographic examinations were performed and showed incomplete root development and no alterations around the periapical region (Figure 2D).

Pulpotomy with MTA followed by sealing with glass ionomer cement and the restorative procedures to bond the fragment were performed (Figure 2E and 2F). Recommendations regarding oral habits to avoid, eating, and oral hygiene were emphasised.

In order to evaluate the impact of TDI treatment on children's and families' lives, QHRQoL questionnaires (FIS - Familiar Impact Scale, P-CPQ - Parental/Caregiver Perceptions and CPQ - Child Perception Questionnaire)[11-16]

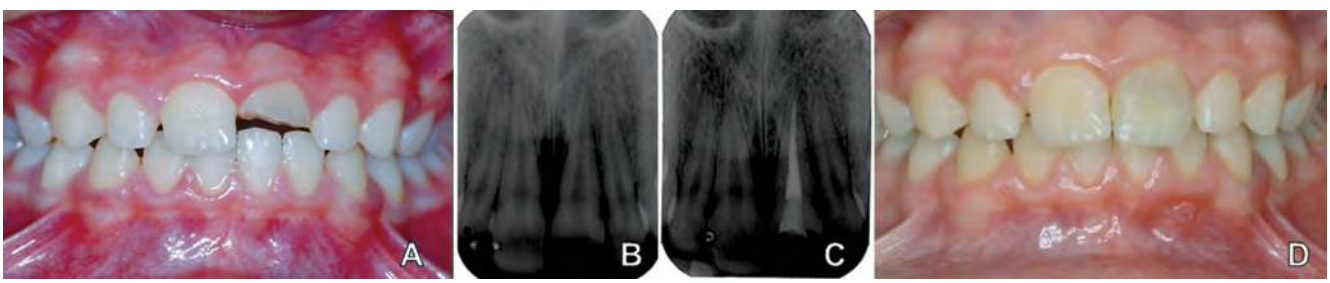

***Figure 1**: (A) Intra oral aspect of the first case; (B) Radiographic aspect before treatment; (C) Radiographic aspect after the endodontic treatment and before the reattachment of the dental fragment; (D) Final intra oral aspect of the first case.*

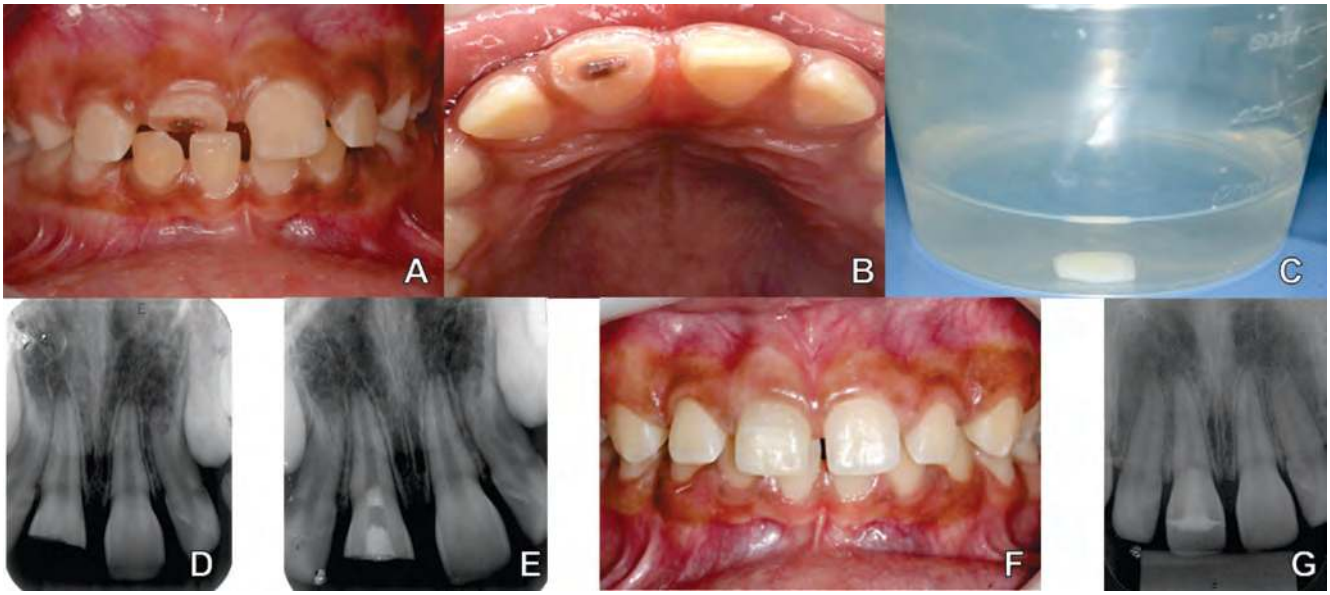

***Figure 2**: (A) Intra oral aspect of the second case; (B) Aspect of the pulp before treatment; (C) Dental fragment; (D) Initial radiographic aspect; (E) Radiographic aspect after endodontic therapy; (F) Final aspect after the reattachment of the fragment. (G) Radiographic aspect after 1-year follow-up.*

***Table 1**: Gender Differences on assessing Quality of Life before and after the treatment according to each Questionnaire issue.*

	BOY		GIRL	
CPQ	*BEFORE TREATMENT*	*AFTER TREATMENT*	*BEFORE TREATMENT*	*AFTER TREATMENT*
ORAL SYMPTOMS	*14(87.5%)*	*4(25%)*	*6(30%)*	*0 (0)*
FUNCTION LIMITATIONS	*12(75%)*	*5(31.2%)*	*7(35%)*	*8 (40%)*
EMOTIONAL WELNESS	*4 (25%)*	*0 (0)*	*12 (75%)*	*4 (25%)*
SOCIAL WELLNESS	*2(12.5%)*	*0 (0)*	*13(29.5%)*	*8 (18.2%)*
TOTAL32 (50%)	9 (14%)	38 (38%)	20 (20%)	
P-CPQ	*BEFORE TREATMENT*	*AFTER TREATMENT*	*BEFORE TREATMENT*	*AFTER TREATMENT*
ORAL SYMPTOMS	*12 (50%)*	*0 (0)*	*12 (50%)*	*0 (0)*
FUNCTION LIMITATIONS	*14 (43.7%)*	*8 (25%)*	*20 (62.5%)*	*10 (31.2%)*
EMOTIONAL WELNESS	*10 (35.7%)*	*4 (14.3%)*	*28 (100%)*	*7 (25%)*
SOCIAL WELLNESS	*6 (15%)*	*0 (0)*	*34 (85%)*	*11 (27.5%)*
TOTAL42 (33.9%)	12 (9.7%)	94 (75.8%)	28 (22.6%)	
FIS	*BEFORE TREATMENT*	*AFTER TREATMENT*	*BEFORE TREATMENT*	*AFTER TREATMENT*
PARENTAL EMOTIONS	*12(42.8%)*	*0(0)*	*24(85.7%)*	*0 (0)*
FAMILIAR CONFLICTS	*0 (0)*	*0(0)*	*0 (0)*	*0(0)*
PARENTAL/ FAMILIAR ACTIVITIES	*12(100%)*	*4(33.3%)*	*15(93.7%)*	*10(83.3%)*
TOTAL	24 (42.8%)	4 (7.1%)	39 (69.6)	10 (17.8%)

Note: % relative to total scores for each questionnaire

were administered through interviews conducted by the researcher in charge. The CPQ questionnaire was used according to the patient's age, for the first case the CPQ[11-14] and for the second case the CPQ.[8-10] A reduction of the impact on QHRQoL was clearly seen only one week after treatment (Table 1). The self-esteem of both subjects was recovered and social interactions were improved.

The girl returned for a one-year follow up; the radiographic exam showed complete root formation, confirming pulp vitality (Figure 2G). The boy did not return for evaluation.

DISCUSSION

The management of two cases of complicated crown fractures was described. The first case reports on a boy who was not able to admit that he was feeling embarrassed to smile, laugh, and show his teeth in public, but it was clear by his behaviour as related by his mother that he was having difficulty at school; in other words, the TDI impacted negatively on his QHRQoL. The girl from the second case was clearly very ashamed and refused to go to school and wanted her tooth reattached as soon as possible, showing that TDI affected her emotional state and impacted on her QHRQoL. In both cases, the restorative and endodontic treatment provided an improvement in the quality of life, observed in just one week.

These findings corroborate those of other studies, which found that TDI and its treatment highly influenced the QHRQoL of children and their families.[8,10] In contrast, other authors found that the presence of TDI in children did not have an impact on QHRQoL of children or their families.[17,18] The type of trauma evaluated in the studies, since fractures can cause more aesthetic damage than luxations, the time since the trauma occurred, the type of sequelae, and delayed care are factors that could affect these results.

In the first case, the tooth already had complete root development and remained with exposed dentinal tubules for 6 months; pulp necrosis was diagnosed and endodontic treatment was performed. These factors led us to believe that the extent of the fracture, the period of dentinal tubule exposure to the oral cavity, and root development may influence the presence of complications and determine the clinical management of dental trauma. Pulp necrosis is the most common healing complication and diagnosis is difficult in cases of trauma.[4,5] Late diagnosis of pulp necrosis after trauma can result in additional complications, such as apical periodontitis and inflammatory root resorption.

Partial pulpotomy is a good strategy for the preservation of tooth vitality; such a procedure offers superb outcomes for the treatment of complicated traumatic crown fractures.[19] This corroborates our second case, in which we performed more conservative treatment, i.e. pulpotomy, due to factors such as the young age of the patient, short duration of pulp exposure, incomplete root development, and the presence of pulp vitality. Immediate treatment involving reattachment of the fragment recovers aesthetics and is rapid and inexpensive. An improvement in QoL and its social aspect was observed by both of our patients after the reattachment of the fragments and pulp therapy. These results agree with those of Fakhruddin et al.,[20] who showed that the restoration of injured teeth improved aesthetics and social interactions, but functional deficiencies can persist as a result of periodontal or pulpal pain.

In case 1, the family took a long time to search for a definitive treatment, but in case 2, treatment was sought very quickly. Previous assistance may have influenced the search for care at DTSC, since the person in charge reported concerns regarding the radical care proposed in the second case. This difference in the length of time patients remained untreated may have influenced the impact of QoL outcomes. Because of the delay in care, the patient in the first case had pulp sequelae, which resulted in greater complaints regarding functional limitations and oral symptoms when compared to the second case.

The girl was obviously more concerned about aesthetics than the boy. We believe that girls tend to be concerned about their appearance, as the QHRQoL scores related to emotional and social wellness were very different between the boy and the girl. The aspect of reattaching the fragment to the fractured crown played an important role from the moment we started treatment with the girl, showing that she was worried about aesthetics, while the boy was afraid of the procedure itself. He turned out to be more aggressive over time when bullying played a role at school, but he claimed to not be ashamed of his smile or of showing his teeth in public. This was reflected in the results of the QHRQoL administered before treatment (oral symptoms and functional limitations), on which the boy scored higher than the girl, and also after treatment (social and emotional wellness), when the boy scored much lower than the girl.

Aesthetic recovery through reattachment of the fragment to the fractured tooth is a rapid and practical solution, particularly for permanent teeth. Endodontic treatment minimises the risk of complications in the pulp and periapical tissues, bringing greater safety to the restorative treatment. The impact on the QoL of school-aged children who have suffered dental injuries is high, but it is possible to offer these children better QoL after recovering their oral health status.

REFERENCES

1. Glendor U. Epidemiology of traumatic dental injuries - a 12-year review of the literature. Dental Traumatology 2008;24:603-11.
2. Cavalcanti AL, Bezerra PK, de Alencar CR, Moura C. Traumatic anterior dental injuries in 7- to 12-year-old Brazilian children. Dental Traumatology 2009;25:198-202
3. Soares T, Risso PA, Maia, LC. Traumatic dental injury in permanent teeth of young patients attended at the federal University of Rio de Janeiro, Brazil. Dental Traumatology 2014;30:312-6.

4. Hecova H et al. A retrospective study of 889 injured permanent teeth. Dental traumatology 2010;26:466-75.
5. Soares, TR, Luiz RR, Risso, P, Maia, LC. Healing complications of traumatized permanent teeth in pediatric patients: a longitudinal study. International Journal of Paediatric Dentistry 2014;24:380-6.
6. Andreasen JO, Andreasen FM, Andersson L. Textbook and color atlas of traumatic injuries to the teeth, 4th edn. Copenhagen: Blackwell Munksgaard; 2007.
7. Diangelis AJ, Andreasen JO, Ebeleseder KA, Kenny DJ, Trope M, Sigurdsson A, Andersson L, Bourguignon C, Flores MT, Hicks ML, Lenzi AR, Malmgren B, Moule AJ, Pohl Y, Tsukiboshi M. International Association of Dental Traumatology guidelines for the management of traumatic dental injuries: 1. Fractures and luxations of permanent teeth. Dental Traumatology 2012;28:2-12
8. Antunes LA, Andrade MR, Leão AT, Maia LC, Luiz RR. Change in the quality of life of children and adolescents younger than 14 years old after oral health interventions: a systematic review. Pediatric Dentistry 2013;35:37-42.
9. Freire-Maia FB, Auad SM, Abreu MH, Sardenberg F, Martins MT, Paiva SM, Pordeus IA, Vale MP. Oral health-related quality of life and traumatic dental injuries in young permanent incisors in Brazilian schoolchildren: a multilevel approach. PLoS One 2015;10(8):e0135369
10. Viegas CM, Scarpelli AC, Carvalho AC, Ferreira Fde M, Pordeus IA, Paiva SM. Impact of traumatic dental injury on quality of life among Brazilian preschool children and their families. Pediatric Dentistry 2012;34:300-6.
11. Barbosa TS, Tureli MC, Gaviao MB. Validity and reliability of the child perceptions questionnaires applied in Brazilian children. BMC Oral Health. 2009;9:13.
12. Goursand D, Paiva SM, Zarzar PM, Ramos-Jorge ML, Cornacchia GM, Pordeus IA, et al. Cross-cultural adaptation of the Child Perceptions Questionnaire 11-14 (CPQ11-14) for the Brazilian Portuguese language. Health Quality of Life Outcomes. 2008;64:2.
13. Jokovic A, Locker D, Stephens M, Kenny D, Tompson B, Guyatt G. Measuring parental perceptions of child oral health-related quality of life. J Public Health Dent. 2003;63:67-72.
14. Jokovic A, Locker D, Stephens M, Kenny D, Tompson B, Guyatt G. Validity and reliability of a questionnaire for measuring child oral health-related quality of life. J Dent Res. 2002;81:459-63.
15. Jokovic A, Locker D, Tompson B, Guyatt G. Questionnaire for measuring oral health-related quality of life in eight- to ten-year-old children. Pediatric Dentistry 2004;26:512-8.
16. Locker D, Jokovic A, Stephens M, Kenny D, Tompson B, Guyatt G. Family impact of child oral and oro-facial conditions. Community Dentistry and Oral Epidemiology 2002;30:438-48.
17. Siqueira MB, Firmino RT, Clementino MA, Martins CC, Granville-Garcia AF, Paiva SM. Impact of traumatic dental injury on the quality of life of Brazilian preschool children. International Journal of Environmental Research and Public Health 2013;10:6422-41.
18. Neto JJ, Gondim JO, de Carvalho FM, Giro EM. Longitudinal clinical and radiographic evaluation of severely intruded permanent incisors in a pediatric population. Dental Traumatology 2009;25:510-4.
19. McIntyre JD, Vann WF Jr. Two case reports of complicated permanent crown fractures treated with partial pulpotomies. Pediatric Dentistry 2009;31(2):117-22.
20. Fakhruddin KS, Lawrence HP, Kenny DJ, Locker D. Impact of treated and untreated dental injuries on the quality of life of Ontario school children. Dental Traumatology 2008;24(3):309-13.

Revista Científica do CRO-RJ (Rio de Janeiro Dental Journal) | Instructions to authors

The Revista Científica do CRO-RJ (Rio de Janeiro Dental Journal), a periodical published quarterly aiming at divulging and promoting scientific production and interchange of information between the Brazilian and International community in the different areas of Dentistry and other fields of Health Care. The entire content of the Revista Científica do CRO-RJ (Rio de Janeiro Dental Journal) is available on the following web site http://revcientifica.cro-rj.org.br, to which there is free access. All the articles published in the Revista Científica do CRO-RJ (Rio de Janeiro Dental Journal) have a publication license CC BY-NC-ND (http://creativecommons.org/licenses/by-nc-nd).

The Revista Científica do CRO-RJ (Rio de Janeiro Dental Journal) publishes original articles, clinical case reports, reviews, letters to the editor and editorials/comments. Researches involving animals and/or human beings must be accompanied by the Certificate of Approval of a Research Ethics Committee. All articles are published in PDF format, in American English and must be submitted in this language. An abstract in Portuguese is demanded at the time of submitting and sending the final version.

Peer Review Process

All the content published by the Revista Científica do CRO-RJ (Rio de Janeiro Dental Journal) goes through the process of review by specialists. Articles submitted for appreciation are sent to the CRO-RJ librarian, who, under the supervision of the Editors-in Chief, initially assesses them with regard to the minimum standards demanded relative to form of presentation in the Revista Científica do CRO-RJ (Rio de Janeiro Dental Journal), with a view to complying with all the guidelines required for sending original articles. Once approved at this stage, the original is submitted for appreciation by the Editorial Board, to assess the merit of the work and decide about the convenience of publishing it, with or without changes. After this, the article is sent to undergo a process of evaluation carried out in the review system, by peers selected from a register of reviewers. The reviewers are always professionals from institutions different from that of the origin of the article; they are blind to the identity of the authors and place of origin of the work. After receiving both reports, the Editorial Council evaluates them, and decides about acceptance of the article without changes, rejection, or return to the authors with the suggestions about changes. The Editorial Board is responsible for returning the article to the authors for explanations, as many times as necessary, and at any time, the Editors may decide to reject the document. Each version is always analyzed by the Editorial Board that has the power of making the final decision.

Types of Articles Published

The Revista Científica do CRO-RJ (Rio de Janeiro Dental Journal) accepts the spontaneous submission of original articles, clinical case reports, reviews, letter sot the editor and editorials/review comments, and letters to the editor.

Original articles include randomized and controlled studies; studies of diagnostic tests and triage; observational cohort, case control and cross-sectional studies; other descriptive and experimental studies, as well as those of basic research with laboratory animals. The text must have a maximum of 3.000 words, excluding tables and references; the number of references must not exceed 30. Articles that report clinical trials with therapeutic interventions must be registered in one of the Registers of Clinical Trials
listed by the World Health Organization. In the absence of a Latin American Register, the Revista do CRO-RJ (Rio de Janeiro Dental Journal) suggest that the authors use the following register www.clinicaltrials.gov, of the National Institute of Health (NIH). The Identification Number must be presented in the body of the manuscript. The submission of clinical trials must adhere to CONSORT checklist (http://www.consort-statement.org/). In cases of submission of observational studies, for preparation of the manuscript, adhesion to the STROBE guidelines is requested (https://www.strobe- statement.org/index.php?id=strobe-home).

Clinical Case Reports must not exceed 2000 words, including the abstract, brief introduction, description of the case, discussion, acknowledgments (if there are any). The figures may be organized in the form of a panel. Each panel will be considered a figure. The abstract must not exceed 250 words. Case report articles must be accompanied by the term of free and informed consent signed by the participant and/or his/her legal guardian. For preparation of the manuscript, authors must adhere to the guidelines suggested in CARE (http://www.care-statement.org).

Reviews are critical and orderly assessments of the literature relative to topics of clinical importance, with emphasis on factors such as the causes and prevention of diseases, their diagnosis, treatment and prognosis. Systematic reviews and meta-analyses are included in this category. In the body of the manuscript of the latter two types of reviews, authors must include the Registration Number of the Review protocol in PROSPERO (http://www.crd.york.ac.uk/PROSPERO/). For preparation of the manuscript, authors must follow the guidelines proposed by PRISMA (http://www.prisma-statement.org/). Authors may also submit a proposal of a review article, with a script, to the Editorial Board. If this is approved the author may develop the script and submit it for publication. Review articles must be limited to 6.000 words, excluding references and tables.

Letters to the editor must contain comments with a constructive critical content about subject matter previously published in the Revista Científica do CRO-RJ (Rio de Janeiro Dental Journal). These must be submitted directly to the Editorial Board. The maximum size is 1000 words, including a maximum of 10 bibliographic references. Whenever possible, a reply to the authors will be published together with the letter.

Editorials and comments are commissioned from authorities in specific areas. The Editorial Board may also analyze proposals of spontaneously submitted comments.

General Guidelines

The manuscript must be written using 12-point Arial font, on A4 size pages, with 1.5 line spacing, and a 3 cm margin on each side of the page, including the bibliographic references and titles/legends of tables and illustrations. The file must be presented in digital format, extension “doc” or “docx”. Each section must start on a new page, in the following order; title page, abstract in Portuguese, Abstract in English, text, acknowledgments, bibliographic references, tables (each complete table, with title and footnotes, on a separate page), figures (each complete figure, with titles and footnotes, on a separate page) and figure legends.

The following are the main guidelines about each section, according to the type of manuscript:

Title Page

The title page must contain all of the following items of information:

a) Title of the article, concise and informative, avoiding the use of superfluous terms and abbreviations; also avoid indicating the place and city where the study was conducted;

b) Abbreviated title (short title) to be stated at the top of all the pages with a maximum of 60 characters, counting the spaces;

c) The full name of each of the authors (first name and other surnames, with the last surname typed in bold-face font.

d) Department to which the authors are affiliated and/or definition of the institution or official service to which the study is tied;

e) Specific contribution of each author to the study;

f) Declaration of conflict of interest (write “nothing to declare” or a clear revelation of any interest of an economic or other nature that may cause embarrassment if it becomes known after publication of the article);

g) Name, address, telephone, fax and e-mail address of the corresponding author;

h) Source of financing or supplier of equipment and materials, if this were the case;

ABSTRACT

The abstracts (Portuguese and English) must contain a maximum of 250 words, avoiding the use of abbreviations. No words that identify the institution or city where the article was written must be put into the abstract, to facilitate blind reviewing. All the information that appears in the abstract must also appear in the article. The abstract must be structured according to the following description:

Abstract of Original Article

Introduction (optional): introduce the reader to the topic to be addressed in the article.

Aim: inform the initial hypotheses, if there are any. Define the main aim and inform only the most relevant secondary aims.

Methods: Inform the type of study design, contextual or local, the patients or participants (define the eligibility criteria, sample number, sample distribution criteria among groups, etc.), the interventions/ exposures (describe characteristics, including methods of application, variables analyzed, duration, etc.), and the criteria for measuring the outcome, including the statistical analysis.

Results: Inform the main data, confidence intervals and significance, the statistics of the findings.

Conclusions: Present only those supported by the data of the study, and that contemplate the aims, as well as their practical application with equal emphasis on the positive and negative findings that have similar scientific merits.

Abstract of Case Reports

Introduction (optional): inform the reader about the topic to be addressed.

Aim: briefly state the aims of the report.

Case Report: report the case itself.

Results: Inform the main data related to resolution of the case.

Conclusions: Present only those supported by the data of the study, and that contemplate the aims and their application.

Abstract of Reviews

Introduction (optional): briefly report the central topic of the review, and justify why it was conducted.

Aim: Inform the aim of the review, indicating whether it especially emphasizes some factor, risk, prevention, diagnosis, treatment or prognosis.

Sources of data: Describe the sources of the research, defining the databases and years researched. Briefly inform the eligibility criteria of articles and methods of extraction and evaluation of the quality of information (in cases of Systematic Reviews).

Summary of data: Inform the main results of the research, whether they are quantitative or qualitative.

Conclusions: Present the conclusions and their clinical application.

After the summary of the original articles, case reports or reviews, include three to six key-words that will be used for indexing. Use terms of Medical Subject Headings (MeSH), available in http:// www.nlm.nih.gov/mesh/ meshhome.html. When adequate descriptors are not available, it is possible to use free terms.

ABBREVIATIONS

These must be avoided, because they hamper comfortable reading of the text. When used, they must be defined when they are used for the first time. They must never appear in the title and abstracts.

TEXTS

The text of **original articles** must contain the following sections, each with its respective sub-title:

Introduction: Clear, objective, succinct, citing only references strictly related to the topic, and seeking to justify why the study was conducted. At the end of the introduction, the aims of the study must be clearly described.

Materials and Methods: Describe the population studies, sample and eligibility criteria; clearly define the variables and detail the statistical analysis; if necessary, include references about the methods used during the course of this section. Procedures, products and items of equipment used must be described in sufficient detail to allow reproduction of the study. Furthermore, they must contain details of the brand and place of manufacture. In case of studies with human beings and/or animals, it is mandatory to include a declaration that all the procedures were approved by the research ethics committee of the institution to which the authors belong. In the absence of this, approval must be obtained from another research ethics committee indicated by the National Commission of Research Ethics of the Ministry of Health.

Results: These must be presented clearly, objectively and in a logical sequence. The information contained in tables or figures must not be repeated in the text. The option to use graphs instead of tables with a large number of data depends on the authors and Editorial Board, which may suggest changes and adjustments with the purpose of making them better suited to the guidelines and specificities of the Revista de Odontologia do CRO-RJ (Rio de Janeiro Dental Journal).

Discussion: This must interpret the results and compare them with data previously described in the literature, emphasizing the new and important aspects of the study. Discuss the implications of the findings and their limitations, as well as the need for additional researches. Avoid repetition of the results and/or superimposition between results and discussion. The conclusions must be presented at the end of the discussion, and must respond to the aims of the study, by avoiding information if inferences were not supported by the findings. The authors must place equal emphasis on favorable and unfavorable findings that have similar scientific merits. Include recommendations, when these are pertinent.

The text of **case reports** must contain the following sections, each with its respective sub-title:

Introduction: Clear, objective, succinct, citing only references strictly related to the topic, and seeking to justify why the study was conducted. Describe the aims at the end of the introduction.

Case Report: must present details of the case and procedures for performing them. Describe the follow-up data and prognosis of the case, when pertinent. CRO suggests that cases without due conclusion should be avoided. Mention the Term of Free and Informed Consent.

Discussion: Discuss the diagnostic, therapeutic and technical criteria used, among other details about the case. Discuss the clinical implications of the findings and their limitations. The conclusions must be presented at the end of the discussion, and must respond to the aims of the study, by avoiding information if inferences were not supported by the findings. The authors must place equal emphasis on favorable and unfavorable findings that have similar scientific merits. Include recommendations, when these are pertinent.

The text of **review articles** must contain the following topics: - In case of **narrative reviews**, the following are suggested:

Introduction: clear and objective, in which the authors explain the importance of the review to clinical practice, in the light of dental literature. The introduction must conclude with the aims of the review.

Materials and Methods/Data Source: It is necessary to describe the methods of data selection and extraction, followed by Data Synthesis.

Data Synthesis: This data synthesis (result/discussion) must present all the pertinent information in rich detail.

Conclusion: The conclusion section must correlate the main ideas of the review with the possible clinical applications, limiting generalization to the domains of the review.

- In cases of **systematic reviews, with or without meta-analyses**, the authors must follow the PRISMA statement (http://www.prisma-statement.org/). These reviews must contain: **Introduction**: that demonstrates the pertinence of the subject and the existent controversy with respect to the topic. At the end of the introduction, the authors should raise the focal question of the review. **Materials and Methods**: must present the search strategy; eligibility criteria of the studies; risk of bias analysis of the included studies; data extraction, and when pertinent, the strategy used for quantitative data synthesis.

Result: must respond in an orderly manner to the data searched according to the methodological design with respect to the qualitative and quantitative synthesis of the primary studies included.

Discussion: must consider interpreting the results, emphasizing resolution of the controversies related to the topic, with this being directed towards answering the focal question of the review, showing whether or not there is need for further research. The limitations of the study must also be pointed out and envisage the external validity of the study (power of generalization of the data).

Conclusion: The conclusion section must correlate the main ideas of the review with the possible clinical applications.

Acknowledgments

These must be brief and objective; they should only mention the person or institutions that made a significant contribution to the study, butthat had not fulfilled the criteria of authorship.

References

The references must be formatted in the Vancouver style, also known as the Uniform Requirements style.

The bibliographic references must be numbered and ordered according to the order in which they appear in the text, in which they must be identified by the respective superscript Arabic numbers. To list the references, do not use the Word resource of end notes or footnotes.

Articles accepted for publication, but not yet published, may be cited provided that the name of the journal is indicated and that it is "in press". Unpublished observations and personal communications may not be cited as references. If it were imperative to include information of this type in the article, it must be followed by the observation "unpublished data" or "personal communication" in parentheses in the body of the article.

The titles of periodicals must be abbreviated as recommended in the Medicus Index; a list with their respective abbreviations may be obtained by means of the publication NLM "List of Serials Indexed for Online Users", available at the address http:// www.nlm.nih.gov/tsd/serials/lsiou.html.

As follows, we present some examples of the model adopted by the Revista Científica do CRO-RJ (Rio de Janeiro Dental Journal):

Articles in periodicals:

1. Up to six authors:

Vieira AR, Bayram M, Seymen F, Sencak RC, Lippert F, Modesto A. In Vitro Acid-Mediated Initial Dental Enamel Loss Is Associated with Genetic Variants Previously Linked to Caries Experience. Front Physiol. 2017 Feb 22;8:104. doi: 10.3389/fphys.2017.00104.

2. More than six authors:

da Silva Bastos Vde A, Freitas-Fernandes LB, Fidalgo TK, Martins C, Mattos CT, de Souza IP, et. al. Mother-to-child transmission of Streptococcus mutans: a systematic review and meta-analysis. J Dent. 2015 Feb;43(2):181-91. doi: 10.1016/j.jdent.2014.12.001.

3. Organization as author:

American Academy of Pediatrics. Clinical practice guideline. Diagnosis and management of childhood obstructive sleep apnea syndrome. Pediatrics 2012;130 (3):576-684.

4. Articles with electronic publication, not yet with printed publication:

Tavares Silva C, Calabrio IR, Serra-Negra JM, Fonseca- Gonçalves A, Maia LC. Knowledge of parents/guardians about nocturnal bruxism in children and adolescents. Cranio. 2016; Jun 24:1-5. [Epub ahead of print]

Books:

Andreasen JO, Andreasen FM. Textbook and color atlas of traumatic injuries to the teeth. 4ª ed. Copenhagen: Mosby. 2007.

Chapters of Books:

Pagel JF, Pegram GV. The role for the primary care physician in sleep medicine. In: Pagel JF, Pandi-Perumal SR, editors. Primary care sleep medicine. 2nd ed. New York: Springer; 2014.

Academic Studies:

BorkowskiMM. Infant sleep and feeding: a telephone survey of Hispanic Americans [dissertation]. MountPleasant(MI): Central Michigan University; 2002.

CD-ROM:

Soils. Geographica on CD ROM. [CD ROM]. Melbourne, Australia: Random House. 1999.

Homepage/website:

Integrative Medicine Center[Internet]. Houston: University of Texas, M. D. Anderson Cancer Center; c2017 [cited 2017 Mar 25]. Available from: https://www.mdanderson.org/patients- family/diagnosis-treatment/care-centers-clinics/integrative- medicine-center.html.

Ministry of Health Documents/Decrees and Laws:

1. Brazil. Decree 6.170, of July 25, 2007. States provisions about the rules relative to Transfers of resources from the Union by means of transfer agreements and contracts and makes other provisions. Diário Oficial, Brasília, 26 jul. 2007.

2. Brazil. Ministry of Health Health Care Secretary Department of Primary Care Política Nacional de Atenção Básica / Ministério da Saúde. Health Care Secretary Department of Primary Care Brasília, Ministério da Saúde, 2012. (Série E. Legislação em Saúde)

Presentation of Paper/Study?

Pierro VSS, Maia LC, Silva EM. Effect of pediatric syrups on roughness and erosion of enamel (abstract). 82nd. IADR General Session & Exhibition; 2004 Mar 10-13, Honolulu, Hawaii. J Dent Res 2004, 83 (Special Issue A): 896.

Tables

Each table must be presented on a separate page, numbered with a Arabic numeral (1, 2, 3, etc.), in the order of appearance in the text; with single spacing between lines, and contain a summarized but explanatory title. All the explanations must be presented in footnotes and not in the title, identified with superscript letters in alphabetical order. Do not underline or draw lines within the tables and do not use spaces to separate the columns. Do not use space on either side of the symbol ± or any other symbol.

Figures (photographs, drawings, graphs, etc.)

All the figures must be numbered with Arabic numerals (1, 2, 3, etc.), in order of appearance in the text. The title must be clear and objective, and must appear at the base of the Figure. All the explanations must be presented in the legends, including those about the abbreviations used. Figures reproduced from other previously published sources must indicate this condition in the legend, in addition to being accompanied by a letter of permission from the copyright holder. Photographs must not allow identification of the patient; masking the patient's eye region in the photograph may not provide sufficient protection. Should there be possibility of identification, it is mandatory to include a written term of free and informed consent to publication. Microphotographs must present internal scales and arrows in contrast with the background.

Illustrations in color are accepted for publication online, without additional cost to the authors. However, all the figures will be transformed to black and white in the printed version. If the authors consider it essential for a certain image to be in color, even in the printed version, the authors are requested to make special contact with the editors. Computer-generated images, such as graphs, must be attached in the form of files in the following formats: .jpg, .gif or .tif, with minimum resolution of 300 dpi. Graphs must preferably be presented in two dimensions. CRO will only accept

drawings, photographs or any illustrations that contain an adequate degree of resolution for the printed version of the journal.

Figure Legends

These must be presented on a separate page, duly identified with their respective numbers.

Verification List

As part of the submission process, authors are requested to indicate their agreement with the items listed as follows:

1. All the authors will sign and submit their agreement by means of a Copyright License Declaration (and end user license), and the content of their intellectual work will be their sole and exclusive responsibility.
2. The corresponding author must prepare, with the consent of the other authors, a letter of submission of the article to the Revista Científica do CRO-RJ (Rio de Janeiro Dental Journal).
3. The submission file (manuscript) must be sent as a Microsoft Word document.
4. The title page must contain all the information required, as specified in the guidelines to the authors.
5. The abstract and key words must be formatted and submitted in English and Portuguese, following the title page.
6. The entire text must be presented in double line spacing using 12-point Arial font, and using italics instead of underlining to indicate emphasis (except in e-mail addresses. All the tables, figures and legends must be numbered in the order in which they appear in the text; each of these must be placed on a separate page, after the bibliographic references at the end of the article.
7. The text must be in accordance with the demands of style and bibliography described in the publication guidelines.
8. The references must be presented in the so-called Vancouver style, and numbered consecutively in the order in which they appear in the text.
9. Information about approval of the study by a research ethics committee must be clearly presented in the text, in the Methods section, and must be sent as an attachment.
10 All the internet addresses presented in the text must be active and ready to be clicked on.
11.Documentary proof of potential Conflict of Interest must be signed by all the authors and sent as an attachment during the submission process.

Final Considerations:

Anti-Plagiarism Policy

The Revista Científica do CRO-RJ (Rio de Janeiro Dental Journal) uses a system to detect plagiarism (available at http//:www.plagium.com/pt/detectordeplagio). When submitting an article to the journal, the authors accept that the work will be digitized in the mentioned program at the time of submission, and in the case of acceptance, prior to publication.

Ethics Policy of the Publication

All submissions will be subject to the condition that the articles have not been previously published, and have also not been simultaneously submitted to another medium of disclosure. All the authors must have read and approved the content and all the authors have declared possible conflicts of interest. The article must follow the ethical principles

of the Revista Científica do CRO-RJ (Rio de Janeiro Dental Journal), and they must also comply with the international standards of research ethics in studies with human beings and animals.

Conflict of interest and financial aid

The Revista Científica do CRO-RJ (Rio de Janeiro Dental Journal) requires all authors to declare potential conflicts of interest. Any interest or relationship, financial or other type that may be perceived as having influenced the results of a study, and the objectivity of an author, is considered a potential source of conflict of interests, and must be declared. The potential sources of conflict of interest include, but are not limited to, rights arising from patent rights or ownership of shares, membership of a board of directors, membership of an advisory board or committee of a company, and receiving advice or speaking fees from a company. If the authors are not sure whether a past or present affiliation or relationship needs to be divulged in the manuscript, please contact the editorial office at http://revcientifica.cro-rj.org.br

The existence of conflict of interests does not exclude publication.

The corresponding author is responsible for ensuring that all the authors fulfill and sign the copyright license declaration and other mandatory documents at the time of submission.

Confirmation of sending the documents

After submission, the corresponding author will receive an e-mail to confirm receipt of the article. If this e-mail of confirmation is not received after 24 hours, please contact the Revista Científica do CRO-RJ (Rio de Janeiro Dental Journal) by e-mail: revistacientifica@cro-rj.org.br. The error may have been caused by some type of spam filtering in the e-mail server.

Updating the status of the article

The initial process of evaluating the article may take up to 60 days, counted from the date of its submission. Should this period have expired, you may contact the Editorial Board to verify the present status. The Revista Científica do CRO-RJ (Rio de Janeiro Dental Journal) will inform you by e-mail, once a decision has been made. One of the following possibilities will be indicated in the reply e-mail: 1. Make adjustments to suit the guidelines and Re-submit; 2. Accepted; 3. Minor adjustments required; 4. Major adjustments required; 5. Rejected. In the latter case, the article will be summarily refused and cannot be re-submitted to the journal.

Submission of Revised Articles

The revised manuscripts must be sent within 2 months after notifying the authors about the conditional acceptance (minor or major adjustments). All the revisions must be accompanied by a letter of response to the reviewers, in which each question or suggestion made by the reviewers must be answered in sequential order. The letter must a) detail the author's reply, point by point, to each of the reviewers' comments, and b) a revised manuscript, highlighting in color, exactly what has been changed in the manuscript after revision. In addition to this, any need for adjustment or correction of the manuscript is the sole responsibility of the authors.

The authors must supply an official certificate of revision of the English language in the act of submitting the revised manuscript. The authors will be fully responsible for the costs of translation/revision of the English language.

RIO DE JANEIRO DENTAL JOURNAL

REVISTA CIENTÍFICA DO CRO-RJ



www.cro-rj.org.br

www.facebook.com/crorj

www.instagram.com/crorj