RIO DE JANEIRO DENTAL JOURNAL

REVISTA CIENTÍFICA DO CRO-RJ

revcientifica.cro-rj.org.br

Editors-in-Chief
Lucianne Cople Maia
Andréa Fonseca-Gonçalves

Volume 5 - Nº3
September-December, 2020

ISSN 1518-5249
e-ISSN 2595-4733

IMAGEM FREEPIK

CRO RJ

The official journal of the
Conselho Regional de Odontologia do Rio de Janeiro

REVISTA CIENTÍFICA DO CRO-RJ (RIO DE JANEIRO DENTAL JOURNAL)

Conselho Regional de Odontologia do Rio de Janeiro
President: Altair Dantas de Andrade
Secretary: Ricardo Guimarães Fischer
Financial officer: Outair Bastazini Filho
Counselors: Felipe Melo de Araujo, Igor Bastos Barbosa, Juarez D´Avila Rocha Bastos, Leonardo Alcântara Cunha Lima, Marcelo Guerino Pereira Couto, Maria Cynesia Medeiros de Barros e Sávio Augusto Bezerra de Moraes

Editors-in-Chief/Editoras-chefes
• Lucianne Cople Maia de Faria
Professora Titular do Departamento de Odontopediatria e Ortodontia da Universidade Federal do Rio de Janeiro - maia_lc@ufrj.br
• Andréa Fonseca-Gonçalves
Professora Adjunta do Departamento de Odontopediatria e Ortodontia da Universidade Federal do Rio de Janeiro - andrea.goncalves@odonto.ufrj.br

Associate Editors / Editores Associados
Alessandra Buhler Borges (Unesp – SJC), Brazil
Alexandre Rezende Vieira (University of Pittsburgh), EUA
Anna Fuks (Hebrew University of Jerusalem), Israel
Antônio Carlos de Oliveira Ruellas (UFRJ), Brazil
Glória Fernanda Barbosa de Araújo Castro (UFRJ), Brazil
Ivo Carlos Corrêa (UFRJ), Brazil
Júnia Maria Cheib Serra-Negra (UFMG), Brazil
Laura SalignacGuimarães Primo (UFRJ), Brazil
Luiz Alberto Penna (UNIMES), Brazil
Marco Antonio Albuquerque de Senna (UFF), Brazil
Maria Augusta Portella Guedes Visconti (UFRJ), Brazil
Mauro Henrique Abreu (UFMG)
Senda Charone (UnB), Brazil
Tatiana Kelly da Silva Fidalgo (UERJ), Brazil
Walter Luiz Siqueira (University of Saskatchewan), Canada
Yuri Wanderley Cavalcanti (UFPB), Brazil

Ad Hoc Consultants
Adilis Kalina Alerxandria de França (UERJ), Brazil
Alessandra Reis Silva Loguercio (UEPG), Brazil
Alfredo Carrillo Canela (UAA), Paraguai
Aline Abrahão (UFRJ), Brazil
Ana Maria Gondim Valença (UFPB), Brazil
Andréa Neiva da Silva (UFF), Brazil
Andréa Pereira de Morais (UNIVERSO), Brazil
Andréa Vaz Braga Pintor (UFRJ), Brazil
Bianca Marques Santiago (UFPB), Brazil
Branca Heloisa Oliveira (UERJ), Brazil
Brenda Paula F. de Almeida Gomes (FOP-UNICAMP), Brazil
Camillo Anauate Netto (GBPD), Brazil
Carlos José Soares (UFU), Brazil
Casimiro Abreu Possante de Almeida (UFRJ), Brazil
Celso Silva Queiroz (UERJ), Brazil
Cinthia Pereira M. Tabchoury (FOP/UNICAMP), Brazil
Cláudia Maria Tavares da Silva (UFRJ), Brazil
Cláudia Trindade Mattos (UFF), Brazil
David Normando (UFPA), Brazil
Denise Fernandes Lopes Nascimento (UFRJ), Brazil
Eduardo Moreira da Silva (UFF), Brazil
Fabian Calixto Fraiz (UFPR), Brazil
Gisele Damiana da Silveira Pereira (UFRJ), Brazil
Issis Luque Martinez (PUC), Chile
Jonas de Almeidas Rodrigues (UFRGS), Brazil
Jônatas Caldeira Esteves (UFRJ), Brazil
José Valladares Neto (UFG), Brazil
Kátia Regina Hostilio Cervantes Dias (UFRJ), Brazil
Leopoldina de Fátima Dantas de Almeida (UFPB), Brazil
Lívia Azeredo Alves Antunes (UFF/Nova Friburgo), Brazil
Luciana Pomarico Ribeiro (UFRJ), Brazil
Maíra do Prado (FO-UVA), Brazil
Maria Cynésia Medeiros de Barros (UFRJ), Brazil
Maria Eliza Barbosa Ramos (UERJ), Brazil
Maria Elisa Janini (UFRJ), Brazil
Mariane Cardoso (UFSC), Brazil
Mario Vianna Vettore (UFMG), Brazil
Maristela Barbosa Portela (UFF), Brazil
Matheus Melo Pithon (UESB), Brazil
Matilde da Cunha Gonçalves Nojima (UFRJ), Brazil
Martinna Bertolini (University of Connecticut), USA
Michele Machado Lenzi da Silva (UERJ), Brazil
Miguel Muñoz (University of Valparaiso), Chile
Mônica Almeida Tostes (UFF), Brazil
Paula Vanessa P. Oltramari-Navarro (UNOPAR), Brazil
Paulo Nelson Filho (FORP),Brazil
Patrícia de Andrade Risso (UFRJ), Brazil
Rafael Rodrigues Lima (UFPA),Brazil
Rejane Faria Ribeiro-Rotta (UFG), Brazil
Roberta Barcelos (UFF), Brazil
RogérioLacerda Santos (UFJF) Brazil
Ronaldo Barcellos de Santana (UFF), Brazil
Ronir Ragio Luiz (IESC/UFRJ), Brazil
Samuel Jaime Elizondo Garcia (Universidad de León), México
Sandra Torres (UFRJ), Brazil
Taciana Marco Ferraz Caneppele (UNESP), Brazil
Tiago Braga Rabello (UFRJ), Brazil
Thiago Machado Ardenghi (UFSM), Brazil

Disclaimer
The Publisher, CRO-RJ and Editors cannot be held responsible for errors or any consequences arising from the use of information contained in this journal; the views and opinions expressed do not necessarily reflect those of the Publisher, CRO-RJ and Editors, neither does the publication of advertisements constitute any endorsement by the Publisher,CRO-RJ and Editors of the products advertised.

MAIL/CORRESPONDÊNCIA
All mail shoud be sent to revistacientifica@cro-rj.org.br
Toda correspondência deve ser enviada à Secretaria no endereço abaixo:
revistacientifica@cro-rj.org.br

ISSN (print): 1518-5249
e-ISSN 2595-4733

CONSELHO REGIONAL DE ODONTOLOGIA DO RIO DE JANEIRO
REVISTACIENTÍFICADOCRORJ(
RIODEJANEIRODENTALJOURNAL)
Rua Araújo Porto Alegre, 70, 5º andar, Centro, Rio de Janeiro-RJ - Cep 20030-015 • Tel. (21) 3505-7600. - Site: www.cro-rj.org.br
Graphic Design: Claudio Santana
Librarian: Vinicius da Costa Pereira
Trainee Librarian: Jefferson Igor da Silva Farias
Information Technology Intern: Moisés Limeira e Paulo Felippe
Available on: www.revcientifica.cro-rj.org.br
2018 - Conselho Regional de Odontologia do Rio de Janeiro

Revista Científica do CRO-RJ (Rio de Janeiro Dental Journal)

Volume 5, Number 3

Summary
Contents

Editorial

Imagens do diagnóstico e conclusão do tratamento: uma reflexão necessária
Andreia Cristina Breda de Souza ---------- 1

Review

Molar-incisor malformation: a narrative review
Thamiles Gonzalez Rodrigues Passos, Patrícia Nivoloni Tannure, José Carlos Pettorossi Imparato, Andréa Vaz Braga Pintor --- 2

Original Article

Impact of untreated dental caries and malocclusion in brazilian adolescents on the quality of life of their families
Letícia Pereira Martins, Jéssica Madeira Bittencourt, Lawrey Guimaraes Miguel, Miriam Pimenta Vale, Saul Martins Paiva, Cristiane Baccin Bendo ---------- 13

Evaluation of dental school student's satisfaction regarding their own smile esthetics and facial profile
Caroline Figueiredo Cardoso, Caroline Pelagio Maués Casagrande, Felipe de Assis Ribeiro Carvalho, Rhita Cristina Cunha Almeida ---------- 22

Relationship between depression, alcohol and/or tobacco abuse of those responsible and children's oral health
Flávia Martins de Souza da Silva, Kriss Mélani Sanga Gárate, Glória Fernanda Barbosa de Araújo Castro ---------- 28

Avaliação das características superficiais dos instrumentos reciproc, reciproc blue e xp-endo shaper
Fernanda Kac Szmajser, Gabriela Hernandez Costa, Letícia do Vale Campos Simão, Carolina Oliveira de Lima, Renata Antoun Simão, Celso Neiva Campos, Maíra Prado ---------- 35

Case Report

Oral manifestations and craniofacial characteristics of hutchinson-gilford Progeria syndrome: a case report
Caroline Gomes Bertoncelli, Andréa Reis Wendt, Paulo Ricardo Gomes Fernandes dos Santos, Luciana Reichert da Silva Assunção, José Vitor Nogara Borges de Menezes1, Fabian Calixto Fraiz ---------- 42

Reabilitação estética e funcional em paciente com cárie na primeira infância: relato de caso
Isabella Sichieri Germano Alves, Carla Oliveira Favretto, Liliana Carolina Baéz-Quintero, Laura Imbriani Bento, Natália Maria Castorino de Oliveira, Cristiane Duque, Marcelle Danelon ---------- 48

Dental radiographic anatomy analysis for identification of a carbonized body: case report
Millena Gonçalves de Souza Gomes, Vanessa Moreira Andrade, Annie Seabra de Medeiros, Andreia Cristina Breda de Souza, Maria Augusta Visconti ---------- 54

Alagille syndrome: facial characteristics, rare oral manifestations, and management of the case
Camila Nassur, Adílis Alexandria, Sabrina Loren de Almeida Salazar, Luciana Pomarico, Glória Fernanda Barbosa de Araújo Castro ---------- 61

Replantation of avulsed tooth: a step-by-step report
Michelle Jenné Allegretto, Larissa Soares Lima da Silva, Jéssica Muniz Loureiro, Lucas Alves Jural, Marcela Baraúna Magno, Patricia de Andrade Risso, Lucianne Cople Maia ---------- 66

IMAGENS DO DIAGNÓSTICO E CONCLUSÃO DO TRATAMENTO: UMA REFLEXÃO NECESSÁRIA

Na atualidade, por inúmeras razões como o surgimento das redes sociais, a evolução da sociedade, as modificações no perfil do paciente, a alteração na percepção de necessidade dos tratamentos odontológicos por parte dos pacientes, a competição por espaço no mercado de trabalho, dentre outras, percebe-se um aumento mais que significativo da propaganda e publicidade em odontologia.

A Odontologia é uma profissão que se exerce em benefício da saúde do ser humano[1] e há sempre preocupação por parte daqueles que a exercem de destacar essa característica fundamental, afastando-a dos serviços comumente oferecidos nas relações de consumo. No entanto, percebe-se que esse frenético aumento de exposição dos trabalhos odontológicos vem nos aproximando cada vez mais das relações de consumo convencionais.[2]Não há dúvidas que uma boa estratégia de marketing eleva a probabilidade de alcançar os objetivos em comunicação de saúde[3] e pode aumentar a procura dos pacientes por um determinado profissional ou procedimento. No entanto, cabe destacar que na quase totalidade das relações há bônus e ônus. O bônus se traduz no aumento da demanda de tratamentos odontológicos, enquanto o ônus se reflete no novo olhar da sociedade para a classe odontológica, assemelhando-nos ao comércio em geral.

Apesar da resolução do CFO 196/2019[4] permitir a divulgação de imagens, feitas pelo próprio profissional, do diagnóstico e conclusão do tratamento, a Lei 5.081 de 26 de agosto de 1966[5], que regulamenta o exercício da Odontologia em todo território nacional, na alínea A, do Art. 7º, veda ao Cirurgião Dentista (CD)a exposição de trabalhos odontológicos com o objetivo de granjear clientela. Sim, a referida norma é antiga, mas está em vigor. O que acarreta a necessidade da classe odontológica se mobilizar para modificação do texto legal, de forma a acompanhar os avanços da sociedade. Da forma como está, há quebra do respeito ao ordenamento jurídico nacional, uma vez que, considerando a pirâmide de Kelsen, uma resolução não pode contrariar um texto de lei ordinária.[6]

As estratégias de marketing, propaganda e publicidade, são utilizadas para fidelizar clientes, criar demanda para um produto ou serviço ou melhorar a imagem de uma empresa ou de um profissional. Em Odontologia, o que se percebe é que os recursos de imagens são utilizados com finalidade de publicidade e marketing, ou seja, criar demanda e consequentemente conquistar clientela. Sendo assim, é importante ponderar sobre o reflexo da contrariedade anteriormente citada sobre a categoria.

É certo que da relação existente entre o CD e o paciente surge uma obrigação contratual, que pode ser de meio ou de resultado. Muitos profissionais da Odontologia entendem que essa obrigação é de meio, considerando os aspectos biológicos que revestem as terapêuticas odontológicas, assim como a imperiosa e necessária colaboração do paciente com os tratamentos, além dos diferentes níveis de acesso à saúde oral.[7]

No entanto, para o Direito, percebe-se que a obrigação do CD tem sido, em regra, de resultado.[8]Nota-se que o crescimento desenfreado da publicidade de tratamentos odontológicos que apresentam as imagens do início do tratamento e da conclusão do mesmo vem contribuindo de modo avassalador para esse entendimento.[9]

Cabe ao CD se responsabilizar por exercer a odontologia dentro dos princípios científicos, técnicos e éticos que a regem, além de considerar os recursos disponíveis para o tratamento do paciente.[2]

É importante refletir que o emprego das imagens, como ferramenta de marketing, busca transmitir ideologias e seduzir o público-alvo.[10] Em especial as fotografias do diagnóstico e conclusão do tratamento. Ainda que permitidas pela resolução 196/2019 do CFO, estas geram uma expectativa de resultado nos pacientes.[8]Nesse sentido, citando a advogada Ana Cristina Von Jess que ensina "...Toda vez que uma das partes tem uma expectativa inicial não alcançada, há a frustração." Assim, a preocupação aumenta, pois quando frustrados, os pacientes buscam os mecanismos judiciais visando a reparação e o ressarcimento. Alguns CDs mais cuidadosos procuram acrescentar um texto explicativo em suas postagens, com o intuito de esclarecer dentre outras coisas que as imagens são ilustrativas, buscando se afastar da garantia de sucesso no tratamento. No entanto, talvez e muito provavelmente isso não seja suficiente para diminuir ou eliminar as expectativas do paciente. O objetivo aqui não está em saber se as pessoas lembram mais do que ouvem, do que leem ou do que veem. Porém, é inquestionável que uma imagem diz algo por si mesma[11], como dizem, vale mais que mil palavras. Resta saber quem tem maior poder de convencimento: o texto ou o belo recurso visual empregado pelo CD.

REFERÊNCIAS

1. Conselho Federal de Odontologia. Código de Ética Odontológica. Resolução no. 118 de 11 de maio de 2012. Rio de Janeiro: CFO; 2012 [Access in: 2019 Mar 9]. Availablefrom: <http://www.cfo.org.br. Acesso em 09 de março de 2019. [Links]

2. Garbin, Cléa Adas Saliba; Garbin, Artênio José Isper; Rovida, Tânia Adas Saliba; Saliba, Marcos Tadeu Adas; Dossi, Ana Paula. A responsabilidade profissional do cirurgião-dentista segundo a opinião de advogados Rev. odontol. UNESP (Online) ; 38(2)mar.-abr. 2009.

3.Elrod JK, Fortenberry JL Jr. Integrated marketing communications: a strategicpriority in healthand medicine. BMC Health Serv Res. 2020 Sep 15;20(Suppl 1):825. doi: 10.1186/s12913-020-05606-7.

4. Conselho Federal de Odontologia. Resolução Nº 196 de 29 de janeiro de 2019. Rio de Janeiro: CFO; 2019 [Access in: 2019 Mar 9]. Availablefrom: http://www.cfo.org.br. [Links]

5. Brasil. Lei n. 5.081, de 24 de agosto de 1966. Regula o exercício da Odontologia. 1966 [Access in: 2019 Mar 9]. Available from: http://www.planalto.gov.br/ccivil_03/leis/L5081.htm [Links]

6. Gonçalves, Alex Silva, & Quirino, RegioHermilton Ribeiro. (2018). A Norma Hipotética Fundamental de Hans Kelsen e a Regra de Reconhecimento de Herbert Hart: semelhanças e diferenças entre os critérios de validade do Sistema Jurídico. Sequência (Florianópolis), (78), 91-118. https://doi.org/10.5007/2177-7055.2018v39n78p91

7.Oliveira, Rogério Nogueira; Fernandes, Mário Marques. Responsabilidade civil do Cirurgião-Dentista: a doutrina em processos e o contraponto odontológico. Rev. Assoc. Paul. Cir. Dent. vol.69 no.2 Sao Paulo Abr./Jun. 2015

8. Lyra, Maria da Conceição Almeida da Rocha; Pereira, Mariana Mourão de Azevedo Flores; Musse, Jamilly de Oliveira. A obrigação de resultado nas ações de responsabilidade civil do cirurgião-dentista no Brasil, em 2017. Rev. Bras. Odontol. Leg. RBOL ; 6(3): 47-58, set-dez 2019.

9. Simplício Alexandre Henrique de Melo. Social media andDentistry: ethicaland legal aspects. Dental Press J. Orthod. [Internet]. 2019 Dec [cited 2021 Apr 04] ; 24(6): 80-89. Availablefrom: http://www.scielo.br/scielo.php?script=sci_arttext&pid=S2176-94512019000600080&lng=en. Epub Jan 24, 2020. https://doi.org/10.1590/2177-6709.24.6.080-089.sar.

10. Santos, Mauricio Antonio. A linguagem da fotografia na propaganda. Monografia. Crato. Universidade Regional do Cariri. 2010

11. Sgarbi, Paulo. Uma imagem vale mais do que mil palavras? A página da educação. N.º 174 Ano 17, Janeiro 2008.

Andreia Cristina Breda de Souza

Serviço de Odontologia Forense, Instituto de Medicina Legal Afrânio Peixoto, Rio de Janeiro, Rio de janeiro, Brasil.

Professora de Odontologia Legal, Departamento de Odontologia Social e Preventiva, Faculdade de Odontologia, Universidade Federal do Rio de Janeiro, Rio de Janeiro, Rio de Janeiro, Brasil.

MOLAR-INCISOR MALFORMATION: A NARRATIVE REVIEW

Thamiles Gonzalez Rodrigues **Passos**[1], Patrícia Nivoloni **Tannure**[2,3], José Carlos Pettorossi **Imparato**[3], Andréa Vaz Braga **Pintor**[3,4*]

[1]Student in Pediatric Dentistry, School of Dentistry, São Leopoldo Mandic, Rio de Janeiro, RJ, Brazil.
[2]School of Dentistry, Universidade Veiga de Almeida, Rio de Janeiro, Rio de Janeiro, Brazil.
[3]School of Dentistry, São Leopoldo Mandic, Rio de Janeiro, Rio de Janeiro, Brazil.
[4]Department of Pediatric Dentistry and Orthodontics, Universidade Federal do Rio de Janeiro, Rio de Janeiro, Brazil.

Palavras-chave: Malformação Molar-Incisivo. Malformação radicular Molar-Incisivo. Malformação Radicular. Desenvolvimento Radicular. Raízes Dentárias. Anormalidades

RESUMO

Introdução: "Malformação molar-incisivo" (MIM) ou "Malformação radicular molar-incisivo" é uma anomalia dental recém-reportada de etiologia desconhecida, possivelmente associada a complicações sistêmicas, que afeta o desenvolvimento de raízes dos primeiros molares permanentes e esmalte dentário de incisivos centrais. **Objetivo**: Realizar uma revisão da literatura sobre "Malformação molar incisivo", também conhecida como "Malformação raiz-molar incisivo", discutindo seus aspectos clínicos, radiográficos/tomográficos, diagnóstico diferencial e possibilidades de tratamento. Fonte dos dados: Busca eletrônica foi realizada na base MEDLINE, em março de 2021, sem limite quanto ao ano de publicação. Os termos pesquisados foram "molar-incisor malformation", "molar-root incisor malformation", "root malformation", "root development", "tooth roots", "abnormalities". **Síntese dos dados**: Quinze artigos, na maioria série de casos, foram incluídos. Em geral, a história médica revelou complicações clínicas durante a gestação e/ou primeiros anos de vida. As características clínicas incluíram defeitos de esmalte dentário na região cervical de incisivos e mobilidade acentuada de molares e incisivos permanentes. Radiograficamente, observou-se a presença de câmaras pulpares parcialmente obliteradas, raízes de molares e incisivos permanentes curtas, finas e incompletas. Microscopicamente, reportou-se a ocorrência de camada de dentina hipercalcificada, em forma de lente, no interior da câmara pulpar, ao nível da junção cemento-esmalte, denominada de "diafragma cervical mineralizado". **Conclusão**: A "Malformação molar-incisivo" é uma anomalia caracterizada por alterações do desenvolvimento radicular, da câmara pulpar e do esmalte em molares e incisivos permanentes. O diagnóstico diferencial inclui Displasia dentinária tipo I e Odontodisplasia regional. Históricos médico e familiar são essenciais para o diagnóstico final, e o tratamento, o qual apesar de não ter protocolo estabelecido requer abordagem multidisciplinar e tratamentos convencionais como exodontia, endodontia, ortodontia e implantes dentários.

Keywords: Molar-incisor malformation. Molar-root Incisor Malformation. Root Malformation. Root Development. Tooth Roots. Abnormalities.

ABSTRACT

Introduction: "Molar-incisor malformation" (MIM) or "Molar root-incisor malformation" is a recently reported dental anomaly of unknown etiology, possibly associated with systemic complications, which affects the development of first permanent molar roots and dental enamel of central incisors. Objective: To conduct a literature review on "Molar-incisor malformation", also known as "Molar root-incisor malformation", discussing its clinical, radiographic/tomographic and microscopic aspects; differential diagnosis and treatment possibilities. **Sources of data**: Electronic search was performed on the MEDLINE database in March 2021, without limit regarding the year of publication. The terms used were "molar-incisor malformation", "molar-root incisor malformation", "root malformation", "root development", "tooth roots", "abnormalities". **Synthesis of data**: Fifteen articles, most of them case series, were included. In general, medical history revealed clinical complications during pregnancy and / or the first years of life. Clinical features included tooth enamel defects in the cervical region of incisors and marked mobility of permanent molars and incisors. Radiographically, partially obliterated pulp chambers, short, thin and incomplete roots of first permanent molars and incisors, were observed. Microscopically, the occurrence of a hypercalcified dentin layer, in the form of a lens, inside the pulp chamber, at the level of the cementum-enamel junction, called "mineralized cervical diaphragm", was reported. **Conclusion**: "Molar-incisor malformation" is an anomaly characterized by changes in root development, pulp chamber and enamel in permanent molars and incisors. The differential diagnosis includes Dentin Dysplasia type I and Regional Odontodysplasia. Medical and family histories are essential for the final diagnosis, and treatment, which despite not having an established protocol, requires a multidisciplinary approach and conventional treatments such as tooth extraction, endodontics, orthodontics, and dental implants.

Submitted: April 05, 2021
Modification: August 16, 2021
Accepted: September 02, 2021

***Correspondence to:**
Andréa Vaz Braga Pintor,
Address: Rua Sorocaba, 316, Botafogo, Rio de Janeiro, RJ, Brazil. CEP: 22271-110
Telephone number:
E-mail: andrea_pintor@hotmail.com

INTRODUCTION

Dental development is a complex process that involves strict molecular control regulated by signals that are transmitted between the epithelium and the neural crest derived from the mesenchyme[1]. The discontinuation of this process can lead to abnormal tooth development, due to complex interactions between genetic, epigenetic and environmental factors, which can manifest as changes in number, shape, changes in the mineralized matrix of the tooth.[2,3]

"Molar-incisor malformation" (MIM), also known as "Molar root-incisor malformation" (MRIM), is a newly reported type of dental anomaly with malformation of the roots of first permanent molars[4] and characteristic enamel defect in the central incisors crown. The condition is mainly represented by deviations in the root development of the first permanent molars. The roots are usually very thin and malformed and, many times, nonexistent, although the crown of the affected teeth present clinically typical morphologies. In addition, MIM can affect deciduous second molars.[3,5,6]

This anomaly may cause clinical impairments such as tooth impaction, tooth loss, loss of space, spontaneous pain and poor aesthetic of the incisors.[7] It is assumed that the etiology of a tooth with MIM differs from other hereditary and environmental dental anomalies previously described. Although similar to dentin dysplasia (DD) type I, which, is hereditary and may affect the both dentitions partially or completely, MIM affects first permanent molars. Moreover, the medical history of patients with MIM reveals health problems, including neurological disorders, such as myelomeningocele and meningitis, and systemic conditions, such as kidney disease, premature birth and low birth weight or in the first 2 years of life in most cases.[5,6]

The aim of this study was to conduct a literature review on "Molar-incisor malformation", also known as "Molar root-incisor malformation", discussing its clinical, radiographic/tomographic and microscopic aspects, differential diagnosis and treatment possibilities.

MATERIALS AND METHODS

Data source and eligibility criteria

An electronic search was conducted on the MEDLINE database (via PubMed) in March 2021, without limit regarding the year of publication, using the terms "molar-incisor malformation", "molar-root incisor malformation", "root malformation", "root development", "tooth roots", "abnormalities". Clinical studies that reported clinical, radiographic/tomographic and/or microscopic aspects, differential diagnosis and/or treatment approaches of MIM, were included. Conversely, clinical studies that were not related to MIM or were about other root abnormalities, were excluded. In addition, review studies and conference abstracts were also excluded.

Data extraction

The data regarding the country, type of study; sample size; age of participants; reporting of brain injuries; premature birth; occurrence of infections at prenatal or first year periods; clinical and radiographic oral manifestations; microscopic aspects and treatments, were extracted.

RESULTS

A total of fifteen articles, most of them case series, published in English, in their full version, with relevance to the topic studied were included in this review. Briefly, the reported medical histories revealed clinical complications during pregnancy and / or the first years of life. Clinical features included tooth enamel defects in the cervical region of incisors and marked mobility of permanent molars and incisors. Radiographically, partially obliterated pulp chambers, short, thin and incomplete roots of first permanent molars and incisors. The occurrence of a hypercalcified dentin layer, in the form of a lens, inside the pulp chamber, at the level of the cementum-enamel junction, called "mineralized cervical diaphragm" was reported as a microscopic characteristic.

Synthesis of data

The main characteristics regarding country, sample size, age of participants, medical history (concerning the occurrence of brain injuries, premature birth, infections or other complications), and oral manifestations (clinical, radiographic/tomographic) of MIM reported in the case reports and series included, were described in Table 1. Reported possible etiology, microscopic characteristics, differential diagnosis, and treatments were presented descriptively.

Table 1: *Main characteristics of the included studies.*

Reference and study location	Type of study	Sample size	Age of participants	Medical history				Oral manifestations	
				Brain injuries	Premature birth	Infections	Others	Clinical	Radiographic/ tomographic
Lee *et al.*, 2014[7] South Korea	Case series	2	4 and 13 years old	Yes	Yes	No	No	Impaction, early exfoliation, loss of space, spontaneous pain, periodontal abscess, defective aesthetics, mobility of the first molars and permanent central incisors	Permanent first molars and deciduous second molars with thin and short roots
Witt *et al.*, 2014[8] Switzerland	Case series	2	8 and 10,5 years old	No	Yes	Yes	No	Normal-looking clinical crowns	Radiographic: dysplastic roots in the first four permanent molars.Micro-CT: CMD (cervical-mineralized diaphragm) at the level of cemento-enamel junction was found in the analysis of the extracted molars. Intermingled in the calcified matrix, soft tissue canals networks were observed. The buccal roots of the maxillary molars were narrow or elementary. In the mandibular molars the roots were shorts.

Table 1: *Main characteristics of the included studies.*

Reference and study location	Type of study	Sample size	Age of participants	Medical history				Oral manifestations	
				Brain injuries	Premature birth	Infections	Others	Clinical	Radiographic/ tomographic
Lee *et al*., 2015[9] South Korea	Case report	1	6 years old	Yes	Yes	No	Yes	Normal-looking clinical crowns and severe mobility in the permanent and primary molars affected by MIM	Radiographic: first permanent molars with short and thin roots. Micro-CT: a calcified matrix did not entirely obliterate the canal roots of the upper right permanent first molar. A radiopacity in the lower right permanent molar was found between the enamel and dentin.
McCreedy *et al*., 2015[10] USA	Case series	2	8 and 9 years old	No	Yes	No	Yes	Cervical constriction and enamel defect on the upper permanent incisor and mobility	First permanent molars with atrophied pulp chambers and short and narrow roots
Wright *et al*., 2016[11] USA/South Korea	Case series	30	Not reported	No	No	Yes	Yes	Permanent incisors with cervical constriction	First permanent molars with thin and dysplastic roots
Yue an d Kim *et al*., 2016[12] South Korea	Case report	1	13 years old	No	No	Yes	No	Gingival hidradenitis suppurativa	First permanent molars with thin roots and small atrophied pulp chambers

Table 1: *Main characteristics of the included studies.*

Reference and study location	Type of study	Sample size	Age of participants	Medical history				Oral manifestations	
				Brain injuries	Premature birth	Infections	Others	Clinical	Radiographic/ tomographic
Brusevold *et al*., 2017[5] Norway	Case series	6	8 – 12 years old	Yes	Yes	No	Yes	Cervical constriction on the upper central incisor	Radiographic: first permanent molars with hypoplastic roots, limited pulp chambers.Micro-CT: a lower left first permanent molar was observed. Although the dentin and enamel were normal, the pulp chamber only connected with one canal and was partially obliterated. A denser layer of dentin was found and correlated with a cervical enamel constriction.
Choi *et al*., 2017[6] South Korea	Case series	3	6 -9 years old	No	No	Yes	Yes	Gingival abscess, defect in the cervical region of the upper central incisor	Radiographic: First permanent molars with underdeveloped roots, bone resorption

Table 1: *Main characteristics of the included studies.*

Reference and study location	Type of study	Sample size	Age of participants	Medical history				Oral manifestations	
				Brain injuries	Premature birth	Infections	Others	Clinical	Radiographic/ tomographic
Kim *et al*., 2019[16] South Korea	Case series	38	3 – 23 years old	Yes	Yes	Yes	Yes	Wedge-shaped defect in permanent incisors or canines in the cervical portion of the crown and mobility	Affected molars with underdeveloped, short and slender roots. Micro-CT: revealed CMD in the cemento-enamel junction in a lower permanent first molar. Also, primitive roots were observed. However, in a second observed tooth, CMD was at the middle section of the crown of an upper permanent first molar, instead at the level of the cemento-enamel junction. A fissure was observed in the cervical region, on the external face of the crown, at the CMD region. Dysplastic and malformed roots were also described.
Neo *et al*., 2019[14] UK	Case report	1	12 years old	No	No	No	Yes	Normal-looking clinical crowns	Extensive root resorption or under development of the roots was observed, little root structure. Pulpal spaces were thin and crescent-shaped.
Pavlic *et al*., 2019[15] Slovenia	Case report	1	12,5 years old	No	No	No	Yes	Hypoplastic cervical third of the upper permanent incisors	First permanent molars with atrophied pulp chambers and short and narrow roots

Table 1: Main characteristics of the included studies.

Reference and study location	Type of study	Sample size	Age of participants	Medical history				Oral manifestations	
				Brain injuries	Premature birth	Infections	Others	Clinical	Radiographic/ tomographic
Vargo *et al*., 2019[16] USA	Case series	8	3-19 years	Yes	Yes	Yes	Yes	Incisors with wedge-shaped enamel defect in the cervical one-third but also unremarkable crowns, defects on the crown of permanent mandibular canines	Malformed, short maxillary central incisor roots, root malformation of the permanent molars
Vieira *et al*., 2020[17] Brazil	Case report	1	8 years old	No	No	No	Yes	Fluorosis stain and hypoplasia on teeth 11 and 31 and mobility in the upper and lower permanent incisors	First permanent molars with short roots and open apices, incomplete root formation of the incisors
Kim *et al*., 2020[18] South Korea	Case series	2	6 and 7 years old	Yes	Yes	No	No	Mobility of the lower left second primary molar	Radiographic: Unerupted permanent central incisors exhibited a cervical notch of the crown, root malformations and almost rootless of second primary molars and first permanent molars with dysplastic roots.Micro-CT: analysis of an extracted lower first permanent molar revealed CMD at the cemento-enamel junction, also a narrow cervical region with small and thin roots.
Park *et al*., 2020[19] South Korea	Case series	2	10 and 11 years old	Yes	Yes	Yes	Yes	Abscess, periapical abscess and normal-looking clinical crown	Abnormal furcation position, shorten middle of tooth, constricted pulp cavities, elongated and shorted roots

Etiology

The etiology of MIM remains undetermined, however, some studies indicated that MIM is caused by environmental factors and is related to medical history, such as the use of drugs and diseases related to the central nervous system.[6,7,9] Most patients had health problems such as myelomeningocele in the first two years of life,[6,11] premature delivery,[6-9,13,16,18,19] meningitis,[7,11,13,16] convulsion,[5,7,13] perinatal asphyxia,[9,10,13,16,19] cerebral hemorrhage,[5,9,13,18] Staphylococcus infection,[8,12] autoimmune lymphoproliferative[15], and abortion attempts during pregnancy.[17]

Microscopic characteristics

Analysis of histological sections revealed narrow pulp chamber, in which the dentin layer on the floor had a normal appearance, while cervical to the this tissue an altered dentin layer was observed, with irregular and globular aspects. The layer of hypercalcified dentin seemed to prevent the connection of the pulp chamber with the root canals.[5] Similarly, amorphous dentin and altered pulp chamber in the middle portion of the crown, despite the normal dentin and pulp in the upper section, were observed.[7] Although root fractures were not observed, abnormal dentin, cementum and pulp tissue were observed, in addition to inflammatory cells in a region of abnormal root dentin fissure.[7] In another study, normal and amorphous dentin were observed on the upper section of the pulp floor, while osteodentin-like and hyperactive cells similar to pulp were disclosed on the middle and on the lower sections of the pulp floor, as well as the presence of an amorphous tissue similar to cementum-cells.[9] A study reported narrow pulp chambers between the roof and the floor, which were considered as dysplastic areas with irregular contours.[11] The pulp chambers presented with several pulp inclusions that resembled disorganized dentin. In the upper portion of the pulp chamber, normal dentin that extended to the dentin-enamel junction was observed. The roots presented abnormal morphology.[11] In addition, some studies reported the occurrence of a densely calcified plate, "cervical-mineralized diaphragm (CMD) that was located cervical to the pulp chamber and approached the edge of the enamel.[8,15] According to Witt (2014), the CMD was formed by densely calcified globules, having a diameter of approximately 2-3 mm, alternating with a moderately mineralized matrix, which was passed through a dense network of soft tissue channels.[8] Close to the CMD, an amorphous tissue like sclerotic dentin was disclosed, as well as cells like chondrocytes in the portion where the dentin appeared thinner. In the cervical section, instead of the pulp and furcation, cellular cement and a small amount of periodontal ligament were also observed. In the root canals, normal pulp tissue was found, although blocked by mineralized structures that looked like pulp stones[15]. Moreover, it was observed the occurrence of pulp cavity floor composed of dentin coated with a pre-dentin layer and cells equivalent to odontoblasts, while partially developed root segments were covered by acellular cementum.[8] Regarding the dentinal tubules, it was observed that those changed their course in the coronal direction and ran almost horizontally along the edge of the CMD towards the pulp cavity.[8]

Differential diagnosis

The final diagnosis of MIM can only be confirmed by excluding other conditions with similar clinical and radiographic characteristics: Dentin Dysplasia type I and Regional Odontodysplasia. Dentin Dysplasia type I (DD type I) is an anomaly in which the enamel and coronary dentin are clinically normal and well-developed, but the root dentin is disorganized leading to shortening of the root. Unlike MIM, this condition is hereditary and is also called "rootless teeth".[20,21] Dentinal disorganization can happen at different stages of tooth development, which can vary from one patient to another and from tooth to tooth in the same patient. The most affected were deciduous teeth and, in permanent teeth, it depends on the proportion of dentin between organized and disorganized dentin.[20] Dentin Dysplasia type I can affect the entire dentition, on the other hand, MIM is a disease localized to specific teeth.[18] In addition, periapical radiolucencies are frequently observed in non-carious teeth with DD type I even when they exhibit pulp chambers and root canals almost completely obliterated.[14] Regional odontodysplasia is a non-hereditary condition in which the development of enamel and dentin were affected, therefore, is also referred to as "ghost teeth". Most cases were idiopathic, but others seem to be related to syndromes, growth abnormalities, neural disorders and vascular malformations.[20] Although MIM teeth does not present any of these characteristics, radiographically, in cases of regional odontodysplasia is possible to observe the thin layers of enamel and dentin, large pulp chambers and various adjacent teeth being affected.[18] However, this condition can resemble MIM when it presents smaller roots, open apexes and show pulp calcifications.[20]

Treatment

Patients with MIM must be constantly monitored by the dental team for the correct diagnosis and elaboration of a comprehensive conservative treatment plan, considering the patient's signs and symptoms in order to avoid pain and early tooth loss.[5,7] Teeth with MIM should be extracted only when necessary or to avoid more painful treatments and

further complications.[5] Endodontic treatment can also be considered in cases of apical abscesses in teeth affected by MIM, however the treatment has a high degree of difficulty, as there is the "cervical mineralized diaphragm" (CMD), several accessory channels and absence of periodontal support.[3,13,19] The participation of an orthodontist in MIM cases is extremely important, since orthodontic treatments and even implant installation can be considered after tooth loss and, even so that the professional advises the best time to perform the extraction of the affected tooth.[7,13]

DISCUSSION

The "Molar-incisor malformation" (MIM) is a dental anomaly recently described in the literature, with few published articles, most of which were case series[5-8,10,11,13,16,18,19] and case reports,[9,12,14,15,17] with small sample sizes. MIM has been observed and reported in several countries such as Brazil, South Korea, Slovenia, United Kingdom, United States, Norway, Switzerland, although the prevalence of the anomaly has not yet been determined.

MIM is characterized by a failure in the development of the root of first permanent molars, despite the crowns of these teeth present normal aspect, contour and superficial resistance. Major complaints such as spontaneous pain; mobility; swelling; edema; inflammation; pulp necrosis; periapical abscess sinus tract in the gums; loss of space; unusual root development; dental caries without a history of pain; difficulty in endodontic treatment due to uncontrolled bleeding and calcified root canals; and –possible dentinal alterations– have been reported.[6-11,13,19,15,17] Otherwise, some patients had no clinical signs and symptoms and discovered the anomaly in routine consultations and through panoramic radiographs.[10,13] The roots were usually underdeveloped, thin and malformed, and may even be absent. The pulp chamber is abnormal, narrow in the coronary portion. Commonly, all first permanent molars are affected, mainly the lower ones.[5,11,15] The permanent incisors, when affected, exhibit a constriction in the crown in the cervical region, in the shape of a wedge and morphological changes in the pulp chamber and in the root. In some cases, the roots of the second deciduous molars were also affected, presenting deformities similar to those of permanent first molars.[5,11,12,17,18]

The panoramic radiographs of patients with MIM showed first upper and lower permanent molars roots with abnormal morphology.[5-7,10] These roots were characterized as underdeveloped, short, narrow, and divergent. In some cases, pulp obliteration, open apexes, visible alveolar bone loss in the furcation region and even absent roots were also observed. Due to a marked reduction in height, the coronary pulp chambers were partially obliterated, hypercalcified and with evident constriction in the form of narrow slits.[5-8] In the upper central incisors, constrictions were noted in the cervical third of the crown. The roots of these teeth were described as having a normal aspect, in most cases, however, they were also reported with incomplete root formation.[5,17] The roots of the permanent central incisors, when affected, showed open and wide root apexes, and altered ratio between the sizes of the crown and the root.[17]

Bruseovld *et al*. (2017)[5], Choi *et al*. (2017)[6], and Kim *et al*. (2020)[18] observed first permanent lower molars extracted through Microcomputed tomography (Micro-CT) and noticed the pulp partially obliterated, and the pulp chamber hardly connecting with root canals.[5] A layer of hypercalcified dentin, that was denser, was found in the cervical third for the pulp chamber, close to a layer of dentin with normal density. Interestingly, this hypercalcified denser layer represented an association with constriction of the cervical enamel.[5] Likewise, the analysis by Choi *et al*. (2017)[6] and Kim *et al*. (2020)[18], revealed a mineralized plaque in the cervical region inside the pulp chamber, extending to the cemento-enamel junction. The root canals did not seem to have differentiated correctly into fully formed canals and, in addition, the non-development of the roots was also observed. The mineralized plaque was also observed at the average crown height, inside the pulp chamber. Dysplastic roots were intertwined, generating irregular channel morphology. In addition, the presence of calcified materials was found in the pulp cavity. The external shape of the crown was also affected, with a crack in the enamel in the region of the plaque and irregular protrusions in the cervical.[6] Witt *et al*. (2014)[8] and Luder *et al*. (2015)[4], also observed through Micro-CT an ectopic mineralized plate, in the form of a lens at the level of the cemento-enamel junction, which was called "cervical mineralized diaphragm" (CMD). Therefore, this condition came to be called "root malformation associated with a cervical mineralized diaphragm" (RM-CMD). The mineralized plate involved densely calcified globules, sometimes agglutinated, linked to a moderately mineralized collagen matrix, as well as a network of soft tissue channels including large blood vessels and connective tissue similar to the periodontal ligament. According to Witt *et al*. (2014)[8], the plates extended until close to the enamel margin, however, in other areas, they allowed a certain space for fixing the roots.

The etiology remains uncertain.[6,17] However, genetic and epigenetic factors cannot be totally discarded, studies indicated that this condition is caused by different environmental factors that would be associated with the abnormal formation of the tooth root.[7,8,15] Past medical history, including drugs,[7] infection,[11,12] diseases related to the central nervous system,[5-7,11] premature birth,[3,8,11,20] asthma,[18,10,14] especially in the first two years of life, were suggested as possible causes.[8,9,13]

Meningitis is an injury to the central nervous system, characterized as inflammation of the subarachnoid space and can be caused by viral or bacterial infection. If the origin of meningitis is bacterial, treatment with antibiotics should be started immediately.[7] In addition, according to Kim *et al*. (2019), in South Korea, the use of antibiotics to treat premature babies is standard procedure. On the other hand, despite the patient enjoying a good general health during the first three years of life, there was a report of problematic pregnancy, which may suggest the association of environmental factors root malformation of molars and coronary cervical constrictions in the incisors.[17]

The age range of patients diagnosed with MIM was between 3 and 23 years.[5-12,14-19] Even reporting 30 cases of MIM, Wright *et al*. (2016), did not mention the average age of patients who participated in the study. Adequate diagnosis must be made based on clinical and radiographic examination, relating the patient's medical history, mainly during the neonatal period.[13] The difficulties in diagnosing MIM cases were due to the few studies published in the literature to date and, mainly, the unknown etiology of this condition.

Due to the few studies and types of studies, there is still no evidence regarding the best treatment for this anomaly. Meanwhile, patients with MIM are strong candidates for strict monitoring by the dental team, in order to promote a favorable prognosis, especially for children and adolescents.[5,13] Conventional treatments include apicectomy and endodontic treatment.[9] On the other hand, many cases benefit from the extraction of the tooth affected by MIM, followed by orthodontic treatment, allowing healthy second permanent molars to occupy the space.[5,10,13] Dental implants, as long as there is preservation of space and alveolar bone, can be also be considered after tooth loss.[5,10,13]

Endodontic treatment is a challenge as a result of the "cervical mineralized diaphragm" (CMD) located in the pulp chamber, the various accessory channels and the absence of periodontal support.[13,19] Despite this, less than half of the patients lost one or more teeth affected by MIM during the follow-up period.[13] Corroborating the study by Yue *et al*. (2016)[12], in which endodontic treatment was performed on the first left permanent molar diagnosed with MIM, that after six months of follow up, was asymptomatic and with normal healing of the periapical tissues and with normal depth at probing, Park *et al*. (2020) conducted endodontic treatments in two patients and both cases were filled with continuous technique with Endoseal MTA (Maruchi, Wonju, Korea). In addition, the two cases had an exact perforation point and for the correction, Endocem MTA (Marucho, Wonju, Korea) was used. The execution of endodontic treatment on teeth with MIM and its prognosis depends directly on the accessibility of the root canals, since these are often filled with pulp stones.[19] On the other hand, interceptive orthodontic treatment during the permanent dentition was successfully conducted on the patient with MIM, that allowed the interception of deleterious habits and improved overbite and overjet.[17] Kim *et al*. (2020)[18], in one of the cases, not only used a lingual arch to prevent premature loss of the lower second primary molar, but also to maintain and stabilize the first permanent molar until the second permanent molar was capable to restore the place of the affected first permanent molar.

Thus, we observed that there are still very few reports and research in the literature on the "Molar-Incisor Malformation", which impairs the correct diagnosis and treatment, as well as a good prognosis in these cases. Therefore, further studies are necessary for this condition to be, in fact, fully understood.

CONCLUSION

The Molar-incisor malformation (MIM) is an unusual and newly discovered dental anomaly characterized by changes in root development, pulp chamber and enamel in permanent molars and incisors. The differential diagnosis includes Dentin Dysplasia type I and Regional Odontodysplasia. Even with unknown etiology, the diagnosis requires additional information about the patient's medical history in the first two years of life and clinical and radiographic examinations. Treatment is challenging due to the lack of a protocol to date. For this reason, research and studies on the subject are extremely important to contribute to knowledge regarding its etiology and therapeutic possibilities such as tooth extraction, endodontics, orthodontics and implant installation. In addition, interdisciplinary treatment is essential for the correct diagnosis and preparation of a treatment plan to preserve the affected tooth in the mouth for as long as possible.

REFERENCES

1. Huang X-F, Chai Y. Molecular regulatory mechanism of tooth root development. Int J Oral Sci. 2012 Dec;4(4):177–81.
2. Bei M. Molecular genetics of tooth development. Current Opinion in Genetics & Development. 2009 Oct;19(5):504–10.
3. Cobourne MT, Sharpe PT. Diseases of the tooth: the genetic and molecular basis of inherited anomalies affecting the dentition: Diseases of the tooth. WIREs Dev Biol. 2013 Mar;2(2):183–212.
4. Luder HU. Malformations of the tooth root in humans. Front Physiol [Internet]. 2015 Oct 27 [cited 2020 Nov 3];6. Available from: http://journal.frontiersin.org/Article/10.3389/fphys.2015.00307/abstract

5. Brusevold IJ, Bie TMG, Baumgartner CS, Das R, Espelid I. Molar incisor malformation in six cases: description and diagnostic protocol. Oral Surgery, Oral Medicine, Oral Pathology and Oral Radiology. 2017 Jul;124(1):52–61.

6.Choi S, Lee J, Song J. Molar-Incisor Malformation: Three Cases of a Newly Identified Dental Anomaly. THE JOURNAL OF THE KOREAN ACADEMY OF PEDTATRIC DENTISTRY. 2017 Aug 31;44(3):370–7.

7.Lee H-S, Kim S-H, Kim S-O, Lee J-H, Choi H-J, Jung H-S, et al. A new type of dental anomaly: molar-incisor malformation (MIM). Oral Surgery, Oral Medicine, Oral Pathology and Oral Radiology. 2014 Jul;118(1):101-109.e3.

8.Witt CVA, Hirt T, Rutz G, Luder HU. Root malformation associated with a cervical mineralized diaphragm – a distinct form of tooth abnormality? Oral Surgery, Oral Medicine, Oral Pathology and Oral Radiology. 2014 Apr;117(4):e311–9.

9. Lee H-S, Kim S-H, Kim S-O, Choi B-J, Cho S-W, Park W, et al. Microscopic analysis of molar–incisor malformation. Oral Surgery, Oral Medicine, Oral Pathology and Oral Radiology. 2015 May;119(5):544–52.

10. McCreedy C,Robbins H, Newell A, Mallya SM. Molar-incisor Malformation: Two Cases of a Newly Described Dental Anomaly. J Dent Child 2016;83(1):33-7.

11. Wright JT, Curran A, Kim K-J, Yang Y-M, Nam S-H, Shin TJ, et al. Molar root-incisor malformation: considerations of diverse developmental and etiologic factors. Oral Surgery, Oral Medicine, Oral Pathology and Oral Radiology. 2016 Feb;121(2):164–72.

12.Yue W, Kim E. Nonsurgical Endodontic Management of a Molar-Incisor Malformation-affected Mandibular First Molar: A Case Report. Journal of Endodontics. 2016 Apr;42(4):664–8.

13.Kim J-E, Hong J-K, Yi W-J, Heo M-S, Lee S-S, Choi S-C, et al. Clinico-radiologic features of molar-incisor malformation in a case series of 38 patients: A retrospective observational study. Medicine. 2019 Oct;98(40):e17356.

14. Neo H-LL, Watt EN, Acharya P. Molar-incisor malformation: A case report and clinical considerations. J Orthod. 2019 Dec;46(4):343–8.

15. Pavliè A, Vrecl M, Jan J, Bizjak M, Nemec A. Case report of a molar-root incisor malformation in a patient with an autoimmune lymphoproliferative syndrome. BMC Oral Health. 2019 Dec;19(1):49.

16.Vargo RJ, Reddy R, Da Costa WB, Mugayar LRF, Islam MN, Potluri A. Molarincisor malformation: Eight new cases and a review of the literature. Int J Paediatr Dent. 2020 Mar;30(2):216–24.

17.Vieira FGF, Pintor AVB, Abrahão AC, Ruellas ACO, Visconti MA, Primo LG. Differential diagnosis, three-dimensional imaging aspects and interceptive orthodontic management of molar–incisor malformation. Int J Case Rep Images. 2020;11:1.

18.Kim MJ, Song J-S, Kim Y-J, Kim J-W, Jang K-T, Hyun H-K. Clinical Considerations for Dental Management of Children with Molar-Root Incisor Malformations. Journal of Clinical Pediatric Dentistry. 2020 Jan 1;44(1):55–9.

19.Park S, Byun S, Kim J, Yang B, Oh S. Treatment of Molar Incisor Malformation and the short term follow-up: Case reports. European Journal of Paediatric Dentistry. 2020;21(3):238–42.

20.Neville BW, editor. Oral and maxillofacial pathology. 3. ed. St. Louis, Mo: Saunders/Elsevier; 2009. 968 p.

21. Pintor A, Alexandria A, Marques A, Abrahao A, Guedes F, Primo L. Histological and Ultrastructure Analysis of Dentin Dysplasia Type I in Primary Teeth: A Case Report. Ultrastructural Pathology. 2015 Jul 4;39(4):281–5.

IMPACT OF UNTREATED DENTAL CARIES AND MALOCCLUSION IN BRAZILIAN ADOLESCENTS ON THE QUALITY OF LIFE OF THEIR FAMILIES

Letícia Pereira **Martins**[1], Jéssica Madeira **Bittencourt**[1]*, Lawrey Guimaraes **Miguel**[1], Miriam Pimenta **Vale**[1], Saul Martins **Paiva**[1], Cristiane Baccin **Bendo**[1]

[1]Department of Oral Health of Children and Adolescents, Faculty of Dentistry, Universidade Federal de Minas Gerais, Belo Horizonte, Brazil.

Palavras-chave: Cárie Dentária. Má oclusão. Qualidade de Vida. Adolescente.

RESUMO

Objetivo: O objetivo do presente estudo foi avaliar o impacto da cárie dentária e da má oclusão em adolescentes brasileiros na qualidade de vida relacionada à saúde bucal (QVRSB) de suas famílias. **Métodos**: Foi realizado um estudo transversal representativo com 1168 adolescentes de Belo Horizonte, Minas Gerais, Brasil, e suas famílias. Os pais/responsáveis responderam à versão brasileira da *Family Impact Scale* (B-FIS) para avaliar o impacto das condições bucais na QVRSB das famílias. A má oclusão foi diagnosticada pelo Índice de Estética Dental e a cárie dentária pelo índice CPOD. Três examinadores calibrados realizaram exames clínicos. Sexo, idade e vulnerabilidade social dos adolescentes foram coletadas como variáveis de confusão. A análise dos dados foi realizada por meio de análise de regressão de Poisson bivariada e multivariada com variância robusta (p<0,05). Resultados: Resultados ajustados por sexo, idade e vulnerabilidade social demonstraram que famílias de adolescentes com cárie dentária não tratada tiveram 29% mais impacto na Atividade Parental/Familiar (IC95% = 1,11-1,50), 28% nas Emoções Parentais (IC95% = 1,09-1,51) e 34% em Conflito Familiar (IC 95% = 1,09-1,65) do que aqueles sem cárie. Quando ajustada para sexo e idade, a má oclusão foi associada ao Encargo Financeiro (RP = 1,39; IC95% = 1,01-1,65); entretanto, perdeu significância quando a vulnerabilidade social foi incluída no modelo multivariado (RP = 1,27; IC95% = 0,99-1,64). **Conclusão**: A cárie dentária não tratada em adolescentes exerceu impacto negativo na QVRSB de suas famílias. A vulnerabilidade social influenciou a ausência de impacto da má oclusão na QVRSB das famílias.

Keywords: Dental Caries, Malocclusion, Quality of life, Adolescent

ABSTRACT

Objective: The aim of the present study was to evaluate the impact of dental caries and malocclusion in Brazilian adolescents on the oral health-related quality of life (OHRQoL) of their families. **Methods**: A representative cross-sectional study was conducted with 1168 adolescents from Belo Horizonte, Minas Gerais, Brazil, and their families. Parents/caregivers answered the Brazilian version of the Family Impact Scale (B-FIS) to assess the impact of oral conditions on the OHRQoL of the families. Malocclusion was diagnosed using the Dental Aesthetic Index. Dental caries was diagnosed using the DMFT index. Three examiners who had undergone training and calibration exercises performed the clinical examinations. Sex, age and social vulnerability of the adolescents were considered confounding variables. Data analysis was performed using bivariate and multivariate Poisson regression analysis with robust variance (p<0.05). **Results**: The analysis adjusted by sex, age and social vulnerability demonstrated that families of adolescents with untreated dental caries had 29% more impact on Parental/Family Activity (95% CI: 1.11-1.50), 28% on Parental Emotions (95% CI: 1.09-1.51) and 34% on Family Conflict (95% CI: 1.09-1.65) than those without caries. When adjusted for sex and age, malocclusion was associated with Financial Burden (PR=1.39; 95%CI=1.01-1.65), but this variable lost its significance when social vulnerability was included in the multivariate model (PR=1.27; 95% CI: 0.99-1.64). **Conclusion**: Untreated dental caries in adolescents exerted a negative impact on the OHRQoL of their families. Social vulnerability exerted an influence on the impact of malocclusion on the OHRQoL of the families.

Submitted: April 1, 2020
Modification: June 14, 2021
Accepted: June 18, 2021

***Correspondence to:**
Jéssica Madeira Bittencourt
Address: Av. Antônio Carlos 6627, Belo Horizonte, Minas Gerais, Brazil. Zip code: 31270-901. - Telephone number: +55 (31) 3409 2470; Fax: (31) 3409 2472
E-mail: jessbitten@yahoo.com.br

INTRODUCTION

Understanding the perceptions of individuals with regards to their health and quality of life (QoL) is essential to understanding the extent to which oral problems affect their daily lives.[1] Adolescence is characterized by rapid physical and psychological development and appearance is important in this stage of life.[2] The evaluation of oral health-related quality of life (OHRQoL) is essential to understanding how the main oral conditions that affect individuals in this age group impact their daily lives and the lives of their families. The emotional and social well-being of adolescents as well as physical and financial aspects of their oral problems can affect family well-being.[3]

Studies have shown that dental caries and malocclusion affect the OHRQoL of adolescents.[4,5] Untreated dental caries on permanent teeth affects 2.4 billion people worldwide[6] and results in pain, difficulties chewing and speaking, sleep disorders and psychological problems, implying a negative impact on OHRQoL.[7] The prevalence of malocclusion in adolescents ranges from 17.3 to 31.3% throughout the world[8-10] and the impact on dental esthetics plays an important role in the psychological well-being of adolescents in terms of self-esteem, acceptance and social interactions. Therefore, the psychosocial effect of malocclusion on dental esthetics can lead to a reduction in OHRQoL.[8]

Families play a central role in adolescent health, healthcare concerns, needs and interventions.[3] As parents are the main decision makers regarding their children's health, their perceptions exert considerable influence on treatment choices.[11] Adolescents affected by oral problems often turn to their families for assistance with treatment and the relief of symptoms.[1,12] Thus, families can be indirectly affected by the oral problems of their children[3] and it is important to assess how such problems in adolescents affect familial OHRQoL.

However, few studies in the literature have addressed the impact of these oral problems in adolescents on the OHRQoL of their families[1,3,13] and no representative studies were found assessing the association between malocclusion in adolescents and family OHRQoL. Two previous representative studies assessed the impact of dental caries in adolescents on the OHRQoL of their families,[14,15] but neither study was conducted in Brazil.

Therefore, the aim of the present study was to evaluate the impact of dental caries and malocclusion in adolescents on the OHRQoL of their families in a representative sample from Brazil. The hypothesis was that dental caries and malocclusion in adolescents impact the OHRQoL of their families.

MATERIALS AND METHODS

Study design and eligibility criteria

A population-based, cross-sectional study was conducted following the recommendations of the Strengthening the Reporting of Observational Studies in Epidemiology (STROBE) statement.[16] The study was conducted in Belo Horizoante, Minas Gerais, Brazil. Belo Horizonte has a population of 2,375,151 residents and is divided into nine administrative districts.[17] The Human Development Index (HDI) is 0.810, placing the city in twentieth place in the HDI ranking among Brazilian municipalities.[17]

The study was conducted with adolescents aged 11 to 14 years randomly selected from public and private schools in Belo Horizonte. In 2017, 99.2% of individuals aged 6 to 14 years were enrolled in the Brazilian educational system.[18] Therefore, a representative sample of schoolchildren in this age group enables the results to be extrapolated to children and adolescents. Adolescents absent on the days scheduled for the clinical examinations and those with down syndrome and autism spectrum disorders were excluded.

Sampling strategy

The present study offers unprecedented statistical analyses of a database used in previously published studies[1,5,10]. Specifically, the impact of dental caries and malocclusion in adolescents on the OHRQoL of their families has not previously been reported using this database and is the focus of the current set of analyses.

As the data had already been collected, the power of the sample was calculated. A 95% confidence interval and the comparison of means of the total score on the Family Impact Scale (FIS) between adolescents with and without dental caries were used. The power was determined to be 92.45%.

To ensure the representativeness to the sample, one public and one private school were selected at random from each of the nine administrative districts of Belo Horizonte. A classroom was randomly selected from each school. The parents/guardians of the selected adolescents received a letter explaining the study and requesting their authorization for the participation of the adolescents by signing the statement of informed consent. The adolescents also agreed to participate by signing a statement of informed consent. This study received approval from the Human Research Ethics Committee of the Federal University of Minas Gerais (Ethics Committee approval number: 110/08) and was conducted in accordance with the Declaration of Helsinki.

Dependent variable

The Brazilian version of the Family Impact Scale (B-FIS) was used, which has been validated for use in the Brazilian culture.[19] This instrument is part of the Child Oral Health Quality of Life Questionnaires (COHQoL) and its aim is to measure the impact of the oral health status of children/adolescents on their family's OHRQoL according to the view of parents/guardians.[19] The B-FIS consists of 14 items distributed among four domains: Parental/Family Activity, Parental Emotions, Family Conflict and Financial Burden. Each item addresses the frequency of events in the previous three months. The following are the scored response options: "Never" = 0; "Once/twice" = 1; "Sometimes" = 2; "Often" = 3; and "Every day/almost every day" = 4. The total B-FIS score is the sum of all item scores. Scores can also be computed for each of the four domains. Higher scores denote a greater negative impact of the child's/adolescent's oral problems on the family's OHRQoL.[19]

Independent variables of interest

Malocclusion

Malocclusion was measured using the Dental Aesthetic Index (DAI), which was calculated using a regression equation: (missing visible teeth x 6) + (crowding) + (spacing) + (diastema x 3) + (largest anterior maxillary irregularity) + (largest anterior mandibular irregularity) + (anterior maxillary overjet x 2) + (anterior mandibular overjet x 4) + (vertical anterior open bite x 4) + (anteroposterior molar relation x 3) + 13. The DAI value is the sum resulting from this equation, which is used to classify the need for treatment and the severity of malocclusion. DAI ≤ 25 defines an occlusion with no abnormalities or mild malocclusion and no need or mild need for treatment; DAI 26 to 30 defines definite malocclusion for which treatment is elective; DAI 31 to 35 defines severe malocclusion for which treatment is highly desirable; and DAI ≥ 36 defines very severe or disabling malocclusion for which treatment is fundamental.[20] In this study, malocclusion was dichotomized as absent/mild (DAI ≤ 25) or present (DAI > 25).

Dental caries

Dental caries was measured using the Decayed, Missing and Filled Teeth (DMFT) index, which is recommended by the World Health Organization (WHO) to measure and compare dental caries experience in populations of different countries.[21] For statistical purposes, only the D component was considered in the present study and was dichotomized as absence of untreated caries (D component = 0) or presence of untreated caries (D component ≥1).

Confounding independent variables

Some socioeconomic characteristics were collected due to the potential interference in the association between malocclusion/dental caries and family OHRQoL. The confounding variables were social vulnerability, type of school in which the adolescent was enrolled (public or private), age and sex of the adolescent.

The Social Vulnerability Index (SVI), developed by the city of Belo Horizonte, was used to measure vulnerability to social exclusion and was considered a socioeconomic indicator, as it enables the determination of the social reality of the city with the aim of providing efficient management based on the development of each community. The 81 planning units of the municipality were analyzed according to five dimensions: Environmental – access to housing and basic infrastructure; Cultural – access to schooling; Economic – access to income and work; Legal – access to legal assistance; and Survival Security – access to health, food security and social security.[22] The SVI is divided into five different classes ranging from Class I, which comprises the most socially vulnerable families, to Class V, which comprises the least socially vulnerable families.[22] In the present study, the SVI was dichotomized as high social vulnerability (Classes I and II) or low social vulnerability (Classes III, IV and V).

Training and calibration exercises

Three dentists underwent training and calibration exercises prior to performing the clinical examinations. The training exercises were first performed, followed by clinical calibration based on the criteria proposed by the DAI (malocclusion) and WHO (dental caries). Training (discussions on theory) involved the use of plaster models for the DAI and photographs for dental caries. The training and calibration exercises were conducted by an expert in the field (gold standard). For the clinical calibration, 44 adolescents who were not part of the main study were examined by each of the three dentists separately to determine inter-examiner agreement. After one month, 10 adolescents were re-examined to calculate intra-examiner agreement. Mean kappa values were 0.84 for inter-examiner agreement and 0.90 for intra-examiner agreement.

Pilot study

To test the methods (clinical examination and administration of questionnaires) and prepare the examiners, a pilot study was conducted with a sample of 66 adolescents who did not participate in the main study.

Data collection

The adolescents were examined at school in a predetermined order during class hours. The examiners used appropriate personal protective equipment and artificial lighting (Petzl Zoom head lamp, Petzl America, Clearfield, UT, USA). The clinical examinations were performed with the aid of disposable mouth mirrors (PRISMA®, São Paulo, SP, Brazil) and millimeter probes (WHO-621 Trindade, Campo Mourão, PA, Brazil).

The B-FIS was self-administered by the parents/guardians to measure the impact of untreated dental caries and malocclusion in the adolescents on family OHRQoL. The adolescents delivered the B-FIS to their parents/guardians, who completed the questionnaire at home and sent it back to the research team at the school.

Data analysis

Statistical analysis was performed using the Statistical Package for the Social Sciences (SPSS, version 22.0, IBM Corp., Armonk, NY, USA). The data were analyzed using descriptive statistics (frequency, mean and standard deviation), Spearman's correlation coefficients as well as bivariate and multivariate Poisson regression analyses with robust variance. The multivariate analysis was performed to determine the impact of malocclusion and untreated dental caries in adolescents on family OHRQoL adjusted by socioeconomic and clinical characteristics. In addition, the model fit through the deviance test was observed. The level of significance was set at 5% (p<0.05).

RESULTS

The sample of this study comprised 1,168 adolescents and their parents/caregivers. This sample is representative of 11-to-14-year-old adolescents who live in the city of Belo Horizonte, Brazil. Girls accounted for the majority of the sample (59.8%) and mean age was 12.37 years (±1.11). Most of the adolescents lived in regions of low social vulnerability (60.0%). The prevalence of untreated dental caries and malocclusion was 29.1% and 30.9%, respectively (Table 1).

The results of the bivariate Poisson regression analysis revealed statistically significant associations between untreated dental caries and the Parental/Family Activity (p<0.001), Parental Emotions (p=0.002) and Family Conflict (p=0.004) domains as well as with B-FIS total score (p<0.001). Malocclusion was only associated with the total B-FIS score (p = 0.036). High social vulnerability was also significantly associated with the Parental/Family Activity, Parental Emotions and Family Conflict domains (p<0.001, p=0.003 and p=0.015, respectively) and with B-FIS total score (p<0.001). Adolescent's age was associated with the Financial Burden domain (p=0.042) (Table 2).

Thus, untreated dental caries and malocclusion were incorporated together into the multivariate Poisson regression (Table 3). Model 1 was further adjusted by age; Model 2 was adjusted by age and sex; and Model 3 was adjusted by age, sex and SVI. In all models, the presence of untreated dental caries was significantly associated with the Parental/Family Activity, Parental Emotions and Family Conflict domains as well as the B-FIS total score. Malocclusion was significantly associated with the Financial Burden domain and B-FIS total score only in Models 1 and 2. However, these associations lost their significance (p > 0.05) when SVI was included in the adjustment (Model 3).

***Table1**: Categorization of sample.*

Variables	N (%)
Sex	
Male	470 (40.2%)
Female	698 (59.8%)
Age[1]	12.37 (1.112)
SVI	
High Vulnerability	467 (40.0%)
Low Vulnerability	701 (60.0%)
Untreated dental caries	
Present	340 (29.1%)
Absent	828 (70.9%)
Malocclusion	
Present	361 (30.9%)
Absent/mild	807 (69.1%)

Note: SVI = social vulnerability index. [1] mean (standard deviation).

***Table 2**: Descriptive and bivariate analyses of associations between independent variables and B-FIS domains/total score.*

	Parental/Family Activity		Parental Emotions		Family Conflict		Financial Burden		Total Score	
	Mean (SD)	**PR (95%CI)**	**Mean (SD)**	**PR (95%CI)**	**Mean (SD)**	**PR (95%CI)**	**Mean (SD)**	**PR (95%CI)**	**Mean (SD)**	**PR (95%CI)**
Sex										
Male	2.38(2.999)	1.02 (0.88-1.18)	1.84(2.516)	0.94(0.81-1.12)	1.33(2.276)	1.06(0.86-1.29)	0.43(0.830)	1.10(0.87-1.40)	5.98(7.058)	1.01(0.88-1.16)
Female	2.34(3.051)	1.00	1.94(2.780)	1.00	1.27(2.173)	1.00	0.39(0.840)	1.00	5.93(7.381)	1.00
Age	0.013[1]	1.03 (0.97-1.10)	-0.004	1.01(0.94-1.08)	0.018	1.02(0.94-1.11)	0.065*	1.11(1.00-1.23)*	0.011	1.03(0.97-1.09)
SVI										
High	2.82(3.311)	1.38(1.19-1.60)***	2.19(2.857)	1.03(1.09-1.51)**	1.49(2.339)	1.28(1.05-1.55)*	0.45(0.893)	1.20(0.95-1.53)	6.94(7.916)	1.31(1.14-1.51)***
Low	2.05 (2.785)	1.00	1.71(2.532)	1.00	1.16(2.119)	1.00	0.37(0.795)	1.00	5.29(6.694)	1.00
Malocclusion										
Present	2.60(3.075)	1.16(0.99-1.35)	2.10(2.713)	1.16(0.98-1.37)	1.43(2.283)	1.16(0.95-1.43)	0.48(0.922)	1.28(1.00-1.64)	6.61(7.405)	1.17(1.01.1.35)*
Absent/mild	2.25(3.003)	1.00	1.81(2.656)	1.00	1.23(2.181)	1.00	0.37(0.793)	1.00	5.66(7.164)	1.00
Untreated dental Caries										
Present	2.82(3.268)	1.30(1.12-1.52)***	2.26(2.775)	1.30(1.10-1.53)**	1.59(2.498)	1.35(1.10-1.66)**	0.45(0.876)	1.18(0.92-1.52)	7.12(7.765)	1.130(1.13-1.51)***
Absent	2.17(2.906)	1.00	1.75(2.621)	1.00	1.17(2.076)	1.00	0.38(0.818)	1.00	5.47(6.975)	1.00

*Note: Poisson regression; [1] Spearman correlation coefficient; * p <0.05; ** p <0.01; *** p <0.001. SD = standard deviation; PR = prevalence ratio; CI = confidence interval; SVI = social vulnerability index.*

***Table 3**: Multivariate models of associations between untreated dental caries/malocclusion and B-FIS domains/total score.*

	Parental/Family Activity Adjusted PR (95% CI)	Parental Emotions Adjusted PR (95% CI)	Family Conflict Adjusted PR (95% CI)	Financial Burden Adjusted PR (95% CI)	Total Score Adjusted PR(95% CI)
Model 1 **Untreated dental Caries**					
Present	1.30 (1.12-1.52)***	1.30 (1.10-1.53)**	1.35 (1.10-1.66)**	1.18 (0.92-1.52)	1.30 (1.13-1.51)***
Absent	1.00	1.00	1.00	1.00	1.00
Malocclusion					
Present	1.16 (1.00-1.35)	1.17 (0.99-1.38)	1.17 (0.95-1.43)	1.29 (1.01-1.65)*	1.17 (1.02-1.36)*
Absent/mild	1.00	1.00	1.00	1.00	1.00
Model 2 **Untreated dental Caries**					
Present	1.31 (1.12-1.52)***	1.30 (1.10-1.53)**	1.36 (1.10-1.67)**	1.19 (0.92-1.52)	1.31 (1.13-1.51)***
Absent	1.00	1.00	1.00	1.00	1.00
Malocclusion					
Present	1.001.16 (1.00-1.35)	1.001.17 (0.99-1.38)	1.17 (0.95-1.43)	11.39 (1.01-1.65)*	1.001.17 (1.02-1.35)*
Absent/mild	1.00	1.00	1.00	1.00	1.00
Model 3 **Untreated dental Caries**					
Present	1.29 (1.11-1.50)***	1.28 (1.09-1.51)**	1.34 (1.09-1.65)**	1.18 (0.92-1.52)	1.29 (1.12-1.49)*
Absent	1.00	1.00	1.00	1.00	1.00
Malocclusion					
Present	1.001.14 (0.98-1.33)	1.001.15 (0.97-1.36)	1.001.15 (0.93-1.41)	11.27(0.99-1.64)	1.001.15 (1.00-1.33)
Absent/mild	1.00	1.00	1.00	1.00	1.00

*Note: Multivariate Poisson regression adjusted for age, sex, SVI; PR = prevalence ratio; CI = confidence interval. Model 1 adjusted for age; Model 2 adjusted for age and sex; Model 3 adjusted for age, sex and SVI. Note: * p<0.05; ** p<0.01; *** p<0.001; Deviance test Model #1 (3.79), Model #2 (3.79) and Model #3 (3.74).*

DISCUSSION

In the present study, untreated dental caries in adolescents exerted a negative impact on the OHRQoL of their families, which is in agreement with data reported in previous studies[3]. However, it is important to note that these studies employed other methods, such as the use of a convenience sample and a younger age group[3,23] or a sample of adolescents with sickle cell disease[13] and were not performed in Brazil.[14,15] Thus, studies with representative samples are needed and the present investigation fills this gap in the literature with a representative sample of adolescents aged 11 to 14 years enrolled to public and private schools in a large Brazilian city.

One of the possible explanations for the impact of dental caries on the OHRQoL of families may be due to the fact that parents/guardians often feel guilty about their children's oral problems.[23] Moreover, children may require more attention from their parents to relieve the discomfort stemming from untreated dental caries, which can affect parental emotions.[24] Dental caries can also result in parents missing days of work because they have to stay home to take care of their children or take them to a dental appointment. Parents may have difficulties carrying out daily family activities, resulting in expenditures of time and money in order to access dental care.[23] However, no association was found between untreated dental caries and the Financial Burden domain in the present study.

Another important aspect of the present study was the finding that the fully adjusted model demonstrated that malocclusion did not exert an impact on the OHRQoL of the family. As malocclusion does not involve pain symptoms, it may not be perceived by families as an oral problem. On the other hand, the literature points out that malocclusion negatively impacts the OHRQoL of adolescents, especially with regards to emotional and social aspects.[5] One may therefore conclude that malocclusion in adolescents is related to the perception of beauty, since it can affect dental esthetics, which is of considerable importance to social acceptance, especially in the school environment.[2] The family, however, may not perceive that physical appearance plays such an important role in the construction of an adolescent's personal identity. This suggests that adolescents do not share their feelings with their families, such as embarrassment or concern about what other people think about their oral condition.

However, it is interesting to note that malocclusion in adolescents impacted the Financial Burden domain and total B-FIS score when adjusted only for sex and age (Models #1 and #2). When adding SVI to the model (Model #3), these associations lost their significance. The SVI is a local socioeconomic index that enables measuring the vulnerability of the population in a specific way considering five dimensions. In other words, it is a measure of social exclusion. As free orthodontic treatment is offered in Brazil in a very limited way and families with high social vulnerability have virtually no access to this treatment through private services because they cannot afford the cost[25]. Moreover, studies have shown an association between a better socioeconomic status of the family and greater demand for orthodontic treatment[25] as well as an association between a worse socioeconomic status and greater need for orthodontic appliances.[26]

There are several reasons for measuring family impact, especially the central role families play in the health of adolescents due to the relationship of dependence between child and caregiver, with the caregiver being responsible for decisions regarding treatment.[11] To date, however, few studies have addressed this issue in the age group analyzed in the present investigation.[1,12,14,15] The first study evaluated both dental caries and malocclusion, but these variables were not incorporated into a multivariate model, since the main objective was to assess the impact of dental trauma in adolescents on the OHRQoL of their families.[1] The second analyzed the impact of malocclusion on family OHRQoL in a sample selected by convenience.[12] The last two studies determined the impact of dental caries on family OHRQoL in a probabilistic sample but were not performed in Brazil.[14,15] Thus, the present study makes an important contribution to the literature, as studies using multivariate models are important for controlling for confounding factors. Moreover, this is a population-based study conducted at public and private schools, which enables the data to be extrapolated to the entire population of schoolchildren and even adolescents in Belo Horizonte, as nearly all (99.2%) adolescents in the city are part of the Brazilian educational system.[18]

It is necessary for more comprehensive future research to be carried out with a longitudinal design to obtain an understanding of how this impact influences the OHRQoL of the families of adolescents over time. The present study has a cross-sectional design, which does not enable the establishment of causal relations between dental caries or malocclusion and the impact on family OHRQoL. However, the sample was large and representative of adolescents in the city of Belo Horizonte and, therefore, we can extrapolate the data to the entire population. It is possible that there is a memory bias, due to the use of FIS, a questionnaire that addresses the frequency of events in the previous three months. Thus, the respondent may not have remembered a specific item. Moreover, the results underscore the importance of developing public policies aimed at oral health,

such as measures to prevent the occurrence of dental caries as well as reduce risk factors for caries and malocclusion. To improve the OHRQoL of families, it is essential to invest in public policies aimed at reducing social inequalities by expanding access to health, education, housing and work.[27] It is also important for dentists to understand how affected individuals face oral problems, with a focus on patient-centered outcomes. Thus, dentists should inform patients regarding the diagnosis, explain the problem, provide treatment options and offer a prognosis while enabling them to participate in decisions regarding their treatment.[28]

CONCLUSION

In conclusion, this study demonstrated that untreated dental caries in adolescents exerted a greater negative impact on the OHRQoL of the families. Parental/Family Activity, Parental Emotions and Family Conflict were the most affected domains. Regarding malocclusion, its negative impact on the OHRQoL of families is influenced by social vulnerability.

ACKNOWLEDGMENTS

This study was supported by the Coordination for the Advancement of Higher Education Personnel (CAPES), the National Council for Scientific and Technological Development (CNPq) the Research Support Foundation of the State of Minas Gerais (FAPEMIG), the Dean's Office of Research at the Federal University of Minas Gerais (*Pró-reitoria de Pesquisa da Universidade Federal de Minas Gerais*) (PRPq / UFMG), Brazil. The authors declare that there are no potential conflicts of interest.

REFERENCES

1. Bendo CB, Paiva SM, Abreu MH, Figueiredo LD, Vale MP. Impact of traumatic dental injuries among adolescents on family's quality of life: a population-based study. Int J Paediatr Dent. 2014 Sep 24(5):387–96. doi: 10.1111/ipd.12083.
2. Gatto RCJ, Garbin AJÍ, Corrente JE, Garbin CAS. The relationship between oral health-related quality of life, the need for orthodontic treatment and bullying, among Brazilian teenagers. Dental Press J Orthod. 2019 May 20;24(2):73-80. doi: 10.1590/2177-6709.24.2.073-080.oar.
3. Locker D, Jokovic A, Stephens M, Kenny D, Tompson B, Guyatt G. Family impact of child oral and oro-facial conditions. Community Dent Oral Epidemiol. 2002 Dec 30(6):438-48. doi:10.1034/j.1600-0528.2002.00015.x.
4. Aimée NR, Van Wijk AJ, Maltz M, Varjão MM, Mestrinho HD, Carvalho JC. Dental caries, fluorosis, oral health determinants, and quality of life in adolescents. Clin Oral Investig. 2017 Jun 21(5):1811-20. doi: 10.1007/s00784-016-1964-3.
5. Bittencourt JM, Martins LP, Bendo CB, Vale MP, Paiva SM. Negative effect of malocclusion on the emotional and social well-being of Brazilian adolescents: a population-based study. Eur J Orthod. 2017 Nov 39(6):628-33. doi: 10.1093/ejo/cjx020.
6. Kassebaum NJ, Bernabe E, Dahiya M, Bhandari B, Murray CJ, Marcenes W. Global burden of untreated caries: a systematic review and metaregression. J Dent Res. 2015 May 94(5):650-8. doi: 10.1177/0022034515573272.
7. Faria PC, Gonçalves SP, Paiva SM, Junior PAM, Vieria-Andrade RG, Marques LS, et al. Dental caries, but not malocclusion or developmental defects, negatively impacts preschoolers' quality of life. Int J Paediatr Dent. 2016 May 26(3):211–9. doi: 10.1111/ipd.12190.
8. Araki M, Yasuda Y, Ogawa T, Tumurkhuu T, Ganburged G, Bazar A, et al. Associations between Malocclusion and Oral Health-Related Quality of Life among Mongolian Adolescents. Int J Environ Res Public Health. 2017 Aug 10;14(8). doi: 10.3390/ijerph14080902.
9. Nagalakshmi S, James S, Rahila C, Balachandar K, Satish R. Assessment of malocclusion severity and orthodontic treatment needs in 12-15-year-old school children of Namakkal District, Tamil Nadu, using Dental Aesthetic Index. J Indian Soc Pedod Prev Dent. 2017 Jul-Sep 35(3):188-92. doi: 10.4103/JISPPD.JISPPD_280_16.
10. Martins LP, Bittencourt JM, Bendo CB, Vale MP, Paiva SM. Malocclusion and social vulnerability: a representative study with adolescents from Belo Horizonte, Brazil. Cien Saude Colet. 2019 Feb 24(2):393-400. doi: 10.1590/1413-81232018242.33082016.
11. Salama F, Alwohaibi A, Alabdullatif A, Alnasser A, Hafiz Z. Knowledge, behaviours and beliefs of parents regarding the oral health of their children. Eur J Paediatr Dent. 2020 Jun 21(2):103-109. doi: 10.23804/ejpd.2020.21.02.03.
12. LG, Melgaço CA, Abreu MH, Lages EMB, Paiva SM. Effect of malocclusion among adolescents on family quality of life. Eur Arch Paediatr Dent. 2015 Aug 16(4):357-63. doi: 10.1007/s40368-014-0172-6.
13. Fernandes ML, Kawachi I, Corrêa-Faria P, Paiva SM, Pordeus IA. The impact of the oral condition of children with sickle cell disease on family quality of life. Braz Oral Res. 2016 Feb 30(1):1-8. doi: 10.1590/1807-3107BOR-2016.vol30.0021.
14. Onoriobe U, Rozier RG, Cantrell J, King RS. Effects of enamel fluorosis and dental caries on quality of life. J Dent Res. 2014 Oct 93(10):972-79. doi: 10.1177/0022034514548705.
15. Abed R, Bernabe E, Sabbah W. Family Impacts of Severe Dental Caries among Children in the United Kingdom. Int J Environ Res Public Health. 2019 Jan 17(1):109. doi: 10.3390/ijerph17010109.
16. Malta M, Cardoso LO, Bastos FI, Magnanini MM, Silva CM. STROBE initiative: guidelines on reporting observational studies. Rev Saude Publica. 2010 Jun 44(3):559-65. doi: 10.1590/s0034-89102010000300021.
17. Instituto Brasieliro de Geografia e Estatistica (IBGE), Board of Directors Research, Population Coordination and Social Indicators. Estimative of the resident population with date of reference, Rio de Janeiro 2018.
18. Instituto Brasieliro de Geografia e Estatistica (IBGE), Education 2017. Ongoing PNAD. IBGE - Directorate of Research, Coordination of Work and Income, Rio de Janeiro, 2018.
19. Goursand D, Paiva SM, Zarzar PM, Pordeus IA, Allison PJ. Family Impact Scale (FIS): psychometric properties of the Brazilian Portuguese language version. Eur J Paediatr Dent. 2009 Sep 10(3):141–6.
20. Cons NC, Jenny J, Kohout FJ, Freer TJ, Eismann D. Perceptions of occlusal conditions in Austrália, the German Democratic Republic and the United States of America. Int Dent J. 1983 Jun 33(2):200-6.
21. World Health Organization (WHO). Oral Health Surveys - Basic Methods. 5th edn. Geneva: World Health Organization. 2013.
22. Nahas MI, Ribeiro C, Esteves O, Moscovitch S, Martins VL. The map of social exclusion in Belo Horizonte: Methodology of building an urban management tool. Cad Cienc Soc. 2000 7:75–88.

23. Abanto J, Paiva SM, Raggio DP, Celiberti P, Aldrigui JM, Bonecker M. The impact of dental caries and trauma in children on family quality of life. Community Dent Oral Epidemiol. 2012 Aug 40(4):323–31. doi: 10.1111/j.1600-0528.2012.00672.x.
24. Firmino RT, Gomes MC, Vieira-Andrade RG, Martins CC, Paiva SM, Granville-Garcia AF. Case-control study examining the impact of oral health problems on the quality of life of the families of preschoolers. Braz Oral Res. 2016 Nov 30(1):e121. doi: 10.1590/1807-3107BOR-2016.vol30.0121.
25. Laniado N, Oliva S, Matthews GJ. Children's orthodontic utilization in the United States: Socioeconomic and surveillance considerations. Am J Orthod Dentofacial Orthop. 2017 Nov 152(5):672-8. doi: 10.1016/j.ajodo.2017.03.027.
26. Badran SA, Sabrah AH, Hadidi SA, Al-Khateeb S. Effect of socioeconomic status on normative and perceived orthodontic treatment need. Angle Orthod. 2014 Jul 84(4):588-93. doi: 10.2319/062913-482.1.
27. Baker SR, Foster Page L, Thomson WM, Broomhead T, Bekes K, Benson PE, Aguilar-Diaz F, Do L, Hirsch C, Marshman Z, McGrath C, Mohamed A, Robinson PG, Traebert J, Turton B, Gibson BJ. Structural Determinants and Children's Oral Health: A Cross-National Study. J Dent Res. 2018 Sep 97(10):1129-1136. doi: 10.1177/0022034518767401.
28. Ismail A, Razak IA, Ab-Murat N. The impact of anticipatory guidance on early childhood caries: a quasi-experimental study. BMC Oral Health. 2018 July 18:126. doi: 10.1186/s12903-018-0589-0.

EVALUATION OF DENTAL SCHOOL STUDENT'S SATISFACTION REGARDING THEIR OWN SMILE ESTHETICS AND FACIAL PROFILE

Caroline Figueiredo **Cardoso**[1], Caroline Pelagio Maués **Casagrande**[1], Felipe de Assis Ribeiro **Carvalho**[1*], Rhita Cristina Cunha **Almeida**[1]

[1]Departament of Orthodontics, Universidade do Estado do Rio de Janeiro, Rio de Janeiro, Rio de Janeiro, Brazil.

Palavras-chave: Face. Sorriso. Estética Facial. Perfil Facial. Ortodontia.

RESUMO

Introdução: A estética facial apresenta grande importância na vida dos indivíduos. Entretanto, nem sempre o considerado estético pelo ortodontista corresponde com a opinião do paciente, visto que a estética é subjetiva. Assim, objetivou-se avaliar a percepção de graduandos da faculdade de Odontologia, em relação ao próprio sorriso e perfil facial, analisando se haveria diferença nesta percepção em relação ao período que cursariam e à medida que os conhecimentos são adquiridos. **Materiais e Métodos**: Desenvolveu-se este estudo observacional transversal, no qual distribuiu-se um questionário para todos os alunos do curso de Odontologia da Universidade do Estado do Rio de Janeiro. O questionário continha perguntas sobre o período cursado, idade, sexo, naturalidade, história prévia de tratamento ortodôntico, satisfação com o sorriso, índice de Necessidade de Tratamento Ortodôntico (IOTN) para ser comparado com o sorriso, além de escala para comparação do perfil facial. O teste do qui-quadrado foi aplicado no *software* SPSS 13.0 e todas as análises foram realizadas com 95% de confiança ($p \leq 0,05$). **Resultados**: Foram preenchidos 166 dos 253 questionários distribuídos. Destes, 103 alunos relataram tratamento ortodôntico prévio. O grau de satisfação com o próprio sorriso foi alto, sendo de 78% no primeiro ano de faculdade, 63% no segundo, 87% no terceiro e 72% no quarto ano. Houve preferência pelo perfil levemente convexo para ambos os gêneros. Foi observado que 62% da amostra já havia feito tratamento ortodôntico, sendo a maioria da etnia branca. O teste qui-quadrado encontrou diferença estatisticamente significativa na etnia dos estudantes que receberam tratamento ortodôntico prévio ($p=0,008$). **Conclusão**: Não houve diferença na percepção estética do próprio sorriso e perfil em relação ao período cursado, sendo o grau de satisfação com o próprio sorriso bastante alto.

Keywords: Face. Smiling. Facial Aesthetics. Facial Profile. Orthodontics.

ABSTRACT

Introduction: Facial aesthetics is especially important in a person's life. However, what is considered aesthetic by the orthodontist does not always correspond with the patient's opinion, since aesthetics is very subjective. Thus, the aim of this study is to evaluate the perception of dental graduate students in relation to their own smile and facial profile, analyzing if there would be any difference between this self-evaluation associated with the year students are attending in dental school and the technical knowledge progressively acquired. **Materials and methods:** A transverse observational study was performed, in which a questionnaire was applied to all dentistry students at the State University of Rio de Janeiro. The questionnaire inquired about: student's current semester, age, gender, nationality, and previous history of orthodontic treatment. It also contained a Likert scale of satisfaction about their smile, the aesthetic component of the Index of Orthodontic Treatment Need (IOTN) for students to compare with their smile, and a scale for facial profile comparison. The chi-squared test was applied using the SPSS 13.0 software and all analyzes were performed with 95% confidence ($p \leq 0.05$). **Results:** A total of 253 questionnaires were distributed and 166 were filled out. Among those, 103 people reported having had orthodontic treatment before. The level of satisfaction with their own smile was high, reaching 78% in the first year of the course, 63% in the second, 87% in the third, and 72% in the fourth year. There was a preference for a slightly convex profile for both genders. It is observed that 62% of the sample reported having been submitted to orthodontic treatment before and the percentage of white students who had received previous orthodontic treatment was substantially higher than other ethnicities. The qui-square test found a significant statistical difference in ethnicity among students that had received previous orthodontic treatment ($p=0.008$). **Conclusion:** There was no difference in the aesthetic perception of the smile and profile in relation to the year attended by dental school students, with the level of satisfaction with their own smile being high.

Submitted: October 6, 2020
Modification: June 04, 2021
Accepted: June 12, 2021

***Correspondence to:**
Felipe de Assis Ribeiro Carvalho
Adress: Boulevard 28 de Setembro, 157, Vila Isabel, Rio de Janeiro, RJ
Zip code: 20551-030
Telephone number : +55 (21) 9 9924-5162
E-mail: carvalhofar@gmail.com

INTRODUCTION

Although orthodontists seek both functional and aesthetic improvement during treatments, the patient's decision to undertake orthodontic treatment is based primarily on aesthetic considerations. Being so, the evaluation and understanding of the factors that influence their decision should be considered in addition to a clinical evaluation.[1]

Many factors can influence the perception of aesthetics. This implies that the ideals of beauty are always changing in different populations.[2] The demand for orthodontic treatment is much more related to psychological and social factors than somatic ones.[3] In multiple places, such as Scandinavia, The Netherlands and the United Kingdom, the social impact of malocclusions has become a matter of public health. Thus, efforts have been made to provide orthodontic treatment to the population in order to fend off negative impacts caused by malocclusions.[3]

Facial profile is also related to psychosocial factors; it is observed that people with balanced facial features are supposedly happier and more successful.[4] Adults and children with attractive faces are perceived favorably and treated in a more positive way than less attractive ones.[4]

Orthodontic treatment plays an important role in facial aesthetics due to the influence that anterior teeth have on the lips position and, consequently, the facial profile.[2] However, orthodontists' assessments do not always correspond to patients' expectations and/or opinions, since aesthetics is not absolute or objective, but rather extremely subjective.[5]

The vast majority of the classification systems take into account only the mean measures of a population, to the detriment of the measurements of each individual. In addition, it is known that the most accepted standard may vary according to different ethnicities and cultures, and that orthodontic treatments must consider the individual aspects of the evaluated patient. [4]

The related literature contains a great number of studies regarding the preference of lay people[3,6,7] yet there is lack of information concerning the analytical point of view of dental surgeons.[3]

Thus, the objective of this study is to evaluate the self-perception Dentistry students have of their smile and facial profile, analyzing the hypothesis that students' personal preferences would change during the graduation course because of the specific knowledge acquired throughout their studies.

MATERIAL AND METHODS

This study has been submitted and approved by the Research Ethics Committee of the Pedro Ernesto University Hospital (Protocol approval 2.756.436) and all participants have signed an informed consent form.

The study form consisted of a transverse observational study, in which a self-administered questionnaire (Figure 1) was applied to all dentistry students at the State University of Rio de Janeiro in the year of 2019. All graduate students enrolled in Dentistry school, with no exception or exclusion criteria, were invited to participate.



QUESTIONNAIRE

Date: __/__/____

Name: _____

Student's current semester of the course: _____

Place of birth: _____ Age:_____ Gender: (F) (M)

How long have you been living in Rio de Janeiro? _____

1) Are you currently undergoing orthodontic treatment? (YES) (NO)

1.1) If affirmative, for how long has the treatment been in progress? _____

1.2) Did the orthodontic treatment begin before or after entering Dental School? _____

2) Have you previously been submitted to orthodontic treatment? (YES) (NO)

2.1) If affirmative, for how long? _____

2.2) Did the orthodontic treatment begin before or after entering Dental School? _____

2.3) Was the result of the orthodontic treatment satisfactory? (YES) (NO)

3) According to the following scale, how do you feel about your smile? Mark with an "x" the corresponding picture.

(Left to right: very dissatisfied, dissatisfied, neutral, satisfied and very satisfied)

4) In figure 1 there are 10 pictures of different occlusions, ranging from the most esthetic to the least esthetic one. Which of the pictures would you consider the most similar to the esthetics of your smile? Write the corresponding number in the provided space. ( )

5) According to the facial profiles represented in this questionnaire, which one appears to be similar to your facial profile? Answer analyzing only the picture that refers to your biological gender. Write the corresponding letter in the provided space. ( )

6) Also analyzing the facial profile pictures, which facial profile do you consider the most esthetic for each gender? Write the corresponding letter in the provided space.
F ( ) M ( )

***Figure 1**: Questionnaire used in the present study, including the Likert scale, the photographs of the esthetic component of the IOTN index and the female and male facial profile scales.*

The questionnaire inquired about students' current semester, age, gender, nationality and previous background of orthodontic treatments.

A Likert scale [6] ranging from very satisfied, satisfied, neutral, dissatisfied to very dissatisfied. (Figure 1) was used in order to analyze students' satisfaction with their own smile. The questionnaire also included photographs used in the aesthetic component of the Index of Orthodontic Treatment Need (IOTN).[8]

As described in the mentioned index, these photographs are numbered in a scale from 1 to 10 (in which 1 corresponds to the best dental appearance and 10 to the worst one), and the purpose of this scale is that the interviewee can identify which of them they would fit into, regardless of the teeth's color and shape (Figure 1).

Moreover, two facial profile scales were used – male and female[3] (Figure 1), being up to interviewees to select the one that most resembled theirs, as well as which profile they considered the most aesthetic for each gender.

The sample size calculation was based on the paper of Oliveira *et al.* (2013)[4] and was performed using a 95% confidence level, as well as a 5% margin of error, resulting in 153 questionnaires.

The qui-square test was used to analyze if there was any change in students' self-evaluation according to the semester they were attending or according to students' ethnic. Also, the correlation between students' ethnic and the access to orthodontic treatment was made so that an analysis about eventual differences between students could be verified. The descriptive statistics of the data, frequency tables and qui-square test were carried out using the Statistical Package for Social Sciences 13.0 *software* (SPSS Inc., Chicago, Illinois, USA). All analyzes were performed with 95% confidence and $p \leq 0.05$.

RESULTS

From the total of 253 questionnaires distributed, 166 were filled out, more than the minimum sample size required by the sample size calculation. The other students did not agree to participate. The questions that eventually were found with no answer were specified as missing data.

The distribution of students that answered the questionnaire according to their semester can be seen in Table 1. It is noticeable that first semester students comprised the largest parcel of the responses. This is because this class has 60 students, while others have around 25 to 30.

***Table 1**: Distribution of students that answered the questionnaire by semester.*

Semester	1st	2nd	3rd	4th	5th	6th	7th	8th
Total	60	27	26	30	26	29	28	27
Answered	42	19	13	23	11	21	19	18

It was found that 74.5% of respondents were female and 25.5% male. 103 of the respondents had already undergone orthodontic treatment (98 did so before the beginning of Dental school and 5 after it).

The chi-squared test did not find any statistically significant difference between students' smile satisfaction and the year they were attending in dental school (p=0.4), or regarding students' ethnicity (p=0.8). Nevertheless, it revealed a significant statistical difference in ethnicity among students that had received previous orthodontic treatment (p=0.008), as it can be seen in Table 2.

***Table 2**: Comparison between students' ethnicity and orthodontic treatment access.*

		Ethnicity				
		White	**Black**	**Brown**	**Indígenous**	**Total**
Previous orthodontic treament	**Yes**	64	8	17	1	90
	No	18	12	9	0	39
Total		82	20	26	1	129

Note: The Pearson's chi-square value obtained was 11.738 a with degree of freedom 3 and Asymptotic Significance (bilateral) of 0.008.

Students' satisfaction regarding their own smile was high, showing that 28.5% claimed to be very satisfied and 47.9% stated to be satisfied (Table 3). This high satisfaction rate was observed in all semesters of dental school, without any noteworthy differences on this aspect. The level of satisfaction with their own smile was 78% in the first year of dental school, 63% in the second, 87% in the third, and 72% in the fourth.

***Table 3**: Student satisfaction with their own smile according to the Likert scale.*

Satisfaction	Frequency (n)	Valid Percentage
Dissatisfied	9	5.5%
Neutral	30	18.2%
Satisfied	79	47.9%
Very Satisfied	47	28.5%
Total	165	100%
Error	1	0.6%

When comparing their smile with the IOTN index, about half the respondents (50.9%) felt represented by the most aesthetic smile, followed by a 27.3% of who selected the second most aesthetic one. From the cumulative percentage, it was observed that 90% of interviewees identified themselves with the 3 most aesthetic occlusions (Table 4).

***Table 4**: Student's self-evaluation according to the IOTN index.*

AC IOTN	Frequency (n)	Valid Percentage
1	84	50.9%
2	45	27.3%
3	19	11.5%
4	6	3.6%
5	4	2.4%
6	3	1.8%
7	3	1.8%
8	1	0.6%
Total	165	100%
Error	1	0.6%

The participants were almost unanimous (91% for female and 89.6% for male) in the preference for the slightly convex profile for both genders (Table 5). Eighteen students left this question with no answer. The results did not show major discrepancies between students' facial profile self-perception and the profile they elected as the most aesthetic. One hundred and thirty participants self-identified with the convex profile B (79.3%); 17 with C (10.4%), 8 with H (4.9%), 7 with A (4.3%), and 2 with F (1.2%).

***Table 5**: Preference for facial profiles according to gender.*

Profile	Gender fem (n)	Gender fem (%)	Gender male (n)	Gender male (%)
A	1	0.7%	12	8.3%
B	135	91.2%	129	89.6%
C	7	4.7%	3	2.1%
H	5	3.4%	0	0.0%
Total	148	100%	144	100%
Error	18	10.8%	22	13.3%

DISCUSSION

Performing aesthetic procedures is not a simple task, as it demands not only technical knowledge, but also adequate interpretation of patients' wishes.[9] One of the main goals for adults when seeking orthodontic treatment is aesthetic improvement.[10] However, the satisfaction level and aesthetic parameters may vary between patients and orthodontists.[10] The present study observed a high demand for orthodontic treatment among Dentistry student's prior to the beginning of the course. Such fact demonstrates the smile's importance for undergraduates of this academic field,

but also may indicate that orthodontic treatment can influence career choice. Students' satisfaction with their own smile was high in all semesters of dental school, with no noteworthy differences on this aspect, not even after having the orthodontic discipline in the sixth period of dental school.

The face scale on the Likert Scale was used because it is a universal method for survey collection, easily understood, enabling participants to respond in a degree of agreement. Moreover, the responses are easily quantified and subjective for computation in mathematical analysis. Likert surveys are also quick, efficient, and inexpensive methods for data collection. They have high versatility and can be sent out through mail, over the internet, or given in person.[11]

Considering that the ethnicity of more than 60% of this study sample was white, it could be observed that the number of white people who received previous orthodontic treatment exceeds other ethnicities. These findings are corroborated by a systematic review of Brazilian data, which confirms that, among university students, the percentage of white people who received orthodontic treatment outnumbers other ethnical groups.[10]

The aesthetic component of the IOTN index was employed in this questionnaire to determine which of the 10 photographs (that illustrate a scale of occlusion aesthetics) was the best fit for each individual. It was noted that in the process of filling out the questionnaire, some of the participants found it difficult to understand the scale's goal, trying to find a picture that matched their own occlusion. This information raises suspicion regarding the accuracy of studies that used the IOTN, most of all when administered to lay people. Curiously, the study of Lu Yin *et al*. (2014)[12] registered a substantial dissonance between the opinions of orthodontists and lay people regarding the aesthetic component of the IOTN[13], which makes possible the idea that interviewees misinterpreted the index.

The slightly convex profile chosen by participants of the current study differs from the results reached by Lu Yin *et al*. (2014)[12], since the straight profile was elected the most aesthetic by Chinese respondents. Furthermore, this same study analyzed how Chinese young adults perceived their own facial profiles (taking into consideration soft tissues, as well as dental aesthetics) and compared to the opinion of orthodontists about these same young people. According to the results, the assessment made by the professionals was closer to the answers of male lay people than female ones.

The present study, however, deviates from those findings, unveiling a nearly unanimous preference of the public for the slightly convex profile for both genders, the same as in the analysis performed by Viegas *et al*. (2016)[6].

There is controversy in the literature when it comes to the use of photographs or silhouettes in facial profile analysis. Some authors defend that employing photographs may lead to confusion and reduce the decision's objectivity, since other physical characteristics could affect the process of decision making.[6] Other authors support that silhouettes make the analysis by participants more difficult and that photographs simulate the features meant to be evaluated in a more realistic manner.[12]

Previously to the application of this study questionnaire, it was done a pilot test using a greater number of facial profiles. However, the participants of the pilot test reported having doubts about which profile to choose, arguing that the differences between them were too subtle. So, it was tried another pilot test with the profile silhouettes that were used in this study, which did not cause any other doubt.

As a weakness of this research, it is essential to acknowledge that a real analysis of students' face and occlusion by an orthodontist was not conducted, which would have provided a comparison with the collected data.However, this would entail a longer interview and would probably affect the sample size, which was a positive point of this study. A sample of 166 students is extremely relevant, considering the total number of students at the university (253), and no other work in the literature was found with this expressive sample size.

Further studies should be carried out with other undergraduate courses and even with Dentistry courses in other states so that the results could be compared.

CONCLUSION

It could be concluded from this study data that there is a high demand for orthodontic treatment among dental school students even before starting the course; Students reported high satisfaction with their smile aesthetics and profile and that it didn't change as they progressively acquired specific knowledge in the field; The percentage of white students who had received previous orthodontic treatment was substantially higher than other ethnicities. The slightly convex profile was considered the most aesthetic for both men and women.

REFERENCES

1. Flores-Mir C, Silva E, Barriga MI, Lagravere MO, Major PW. Lay person's perception of smile aesthetics in dental and facial views. J Orthod. 2004;31(3):204–9. doi: 10.1179/146531204225022416.
2. Peck H, Peck S. A concept of facial esthetics. Angle Orthod. 1970;40(4):284–317. doi: 10.1043/0003-3219(1970)040<0284:ACOFE>2.0.CO;2.

3. Cala L, Spalj S, Slaj M, Lapter MV, Slaj M. Facial profile preferences: Differences in the perception of children with and without orthodontic history. Am J Orthod Dentofac Orthop. 2010;138(4):442–50. doi: 10.1016/j.ajodo.2008.10.024.
4. Khosravanifard B, Rakhshan V, Raeesi E. Factors influencing attractiveness of soft tissue profile. Oral Surg Oral Med Oral Pathol Oral Radiol. 2013;115(1):29–37. doi: 10.1016/j.oooo.2012.03.021.
5. Mori, AT. Expectativas com relação aos resultados estéticos dos tratamentos odontológicos [dissertação]. São Paulo: Universidade de São Paulo, Faculdade de Odontologia; 2003. doi: 10.11606/D.23.2003.tde-04112003-093231.
6. Viegas MM, Mariano Pereira P, Proença L. Avaliação da perceção estética do perfil facial em diferentes painéis de observadores. Rev Port Estomatol Med Dent e Cir Maxilofac. 2016;57(4):252–7. doi: 10.1016/j.rpemd.2016.09.002.
7. Correia LP, Morado Pinho M, Manso MC. Motivação, perceção do impacto e grau de satisfação com o tratamento ortodôntico. Rev Port Estomatol Med Dent e Cir Maxilofac. 2016;57(4):247–51. doi:10.1016/j.rpemd.2016.08.001.
8. De Oliveira MDV, Da Silveira BL, Mattos CT, Marquezan M. Facial profile esthetic preferences: Perception in two Brazilian states. Dental Press J Orthod. Julie 2015;20(3):88–95. doi: 10.1590/2176-9451.20.3.088-095.oar.
9. Bernabé E, Flores-Mir C. Normative and self-perceived orthodontic treatment need of a Peruvian university population. Head Face Med. 2006;2:22. doi: 10.1186/1746-160X-2-22.
10. Pachêco-Pereira C, Pereira J, … BD-AJ of, 2015 U. Factors associated with patient and parent satisfaction after orthodontic treatment: a systematic review. Elsevier. 2015;148(4):652–9. doi:10.1016/j.ajodo.2015.04.039.
11. Likert R. A technique for the measurement of attitudes. Arch Psychol. 1932.
12. Yin L, Jiang M, Chen W, Smales RJ, Wang Q, Tang L. Differences in facial profile and dental esthetic perceptions between young adults and orthodontists. Am J Orthod Dentofac Orthop. 2014;145(6):750–6. doi: 10.1016/j.ajodo.2014.01.021.
13. Kok Y V., Mageson P, Harradine NWT, Sprod AJ. Comparing a quality of life measure and the aesthetic component of the index of orthodontic treatment need (IOTN) in assessing orthodontic treatment need and concern. J Orthod. Desember 2004;31(4):312–8. doi: 10.1179/146531204225020625.

RELATIONSHIP BETWEEN DEPRESSION, ALCOHOL AND /OR TOBACCO ABUSE OF THOSE RESPONSIBLE AND CHILDREN'S ORAL HEALTH

Flávia Martins de Souza da **Silva**[1], Kriss Mélani Sanga **Gárate**[1], Gloria Fernanda Barbosa de Araújo **Castro**[1*]

[1]Department of Pediatric Dentistry and Orthodontics, School of Dentistry, Universidade Federal do Rio de Janeiro, Rio de Janeiro, RJ, Brazil.

Palavras-chave: Saúde Bucal. Depressão. Alcoolismo. Tabagismo.

RESUMO

Objetivo: Investigar a influência da depressão parental e do uso de cigarro e álcool pelos pelos pais/cuidadores na saúde bucal de crianças de 5 a 11 anos de ambos os sexos. **Métodos**: Um estudo do tipo transversal foi conduzido com 85 crianças e seus respectivos cuidadores. Para detectar a presença de depressão, duas versões do PHQ (Pacient Health Questionnaire) foram aplicadas: o PHQ-2, contendo duas perguntas com opção de resposta afirmativa ou negativa e o segundo, PHQ-9. Para o uso de álcool foi aplicado o AUDIT (Alcohol Use Disorders Identification Test) para avaliação do risco de dependência e abuso de álcool; e o Fagerstrom para dependência de nicotina. As crianças foram submetidas a exames orais para avaliação do controle de biofilme, sangramento gengival e presença de cárie (índices CPO-D e ceo-d). Para verificar a associação entre as diferentes variáveis, foram utilizados os testes Qui-quadrado e Exato de Fisher. **Resultados**: Somente 10,6% dos responsáveis faziam uso de tabaco e 24,7% dos mesmos apresentavam sintomas de depressão. Em relação ao consumo de álcool, 10,6% apresentavam consumo de risco ou dependência. Verificou-se associação entre sangramento gengival nas crianças e o risco de dependência de álcool dos responsáveis (p=0,038). **Conclusão**: Concluiu-se que há uma associação positiva entre o risco de dependência de álcool dos responsáveis e a presença de sangramento gengival no paciente e que a depressão, o uso de álcool e de tabaco pelos cuidadores não influência na experiência de cárie das crianças.

Keywords: Oral Health. Depression. Alcoholism. Tobacco.

ABSTRACT

Objective : To investigate the influence of parental depression and smoking and alcohol use by parents/caregivers use on oral health in children aged 5-11 years of both sexes. **Methods**: A cross-sectional study was conducted involving 85 children and their parents/caregivers. Adult respondents completed three questionnaires to assess depression and alcohol and tobacco use: two versions of the PHQ (Patient Health Questionnaire; PHQ-2 and PHQ-9), AUDIT (Alcohol Use Disorders Identification Test) for risk assessment of alcohol dependence and abuse, and the Fagerström Test for Nicotine Dependence (FTND). The PHQ-2 contained two questions requiring an affirmative or negative answer. Children underwent oral examinations to evaluate biofilm control, gingival bleeding and caries index, specifically DMFT index. Relationships among variables were evaluated using chi-squared tests and Fisher's exact test. **Results**: Only 10.6% of parents and caregivers consumed tobacco and 24,7% of parents or caregivers manifested depressive symptoms. Regarding alcohol consumption, 10.6% of caregivers presented risky consumption or dependence. A positive association was found between children's gingival bleeding and their caregivers' risk of alcohol dependence (p=0.038). **Conclusion**: A positive association between caregivers' risk of alcohol dependence and the presence of gingival bleeding in children was found. Caregivers' depression and alcohol and tobacco use did not influence children's caries.

Submitted: July 19, 2020
Modification: August 18, 2021
Accepted: August 27, 2021

***Correspondence to:**
Dra. Gloria Fernanda Barbosa de Araújo Castro.
Rua professor Rodolpho Paulo Rocco, 325, Cidade Universitária, Rio de Janeiro, RJ, Brazil
Zip Code: 21941-971
Phone Number: +55 (21) 9 9640-6390
Fax: +55 (21) 3939-2771
E-mail: gfbacastro@yahoo.com.br

INTRODUCTION

Dental caries is deemed a complex, polymicrobial disease. It can also be considered as a dysbiosis. Dental caries lesions are only observed when there is an imbalance in the environment that favors the acidification of the dental biofilm. Caries occur as a result of the metabolism of dietary carbohydratesw by living microorganisms.[1]

In the last national sampling performed in 2010, Brazil presented a DMF-T (Decayed, Missing, Filled Teeth) caries rate of 2.1 in children aged 12 years. This number is 25% lower than the one reported in 2003 (DMF-T caries rate of 2.78). However, the index of decayed primary teeth did not decrease substantially and the number of untreated teeth remained high (80%).[2]

Worldwide, caries is still one of the most common chronic diseases among children[3] and its cause has been mainly attributed to factors such as poor oral hygiene and a high-sugar diet. Nonetheless, secondary factors, such as level of education, parents' occupations and socioeconomic level, are recognized as important determinants of children's health.[4] In this context, the family plays a major role in developing healthy habits in their children, for instance, teaching about proper oral health. The adult directly responsible for the child should teach about oral hygiene.

The most common psychiatric disorders are mood disorders. These include depression, bipolar disorders, anxiety disorders and chemical dependencies, most notably alcoholism.[5] Several factors may explain psychiatric disorders, such as genetics or biochemical issues, as well as a person's lifestyle.[5] According to Vidal *et al*. (2013)[6], mental disorders are more prevalent in females, individuals with little education or low income, smokers, and women who suffered violence. Some evidence suggests that mothers' ability to care for their children is negatively impacted when their mental health is affected.[7] Research shows that mothers with depressive symptoms offer less effective emotional support and provide limited assistance with their child's education, regardless of age group.[7,8]

Only a few known studies[9-12] examine the influence of parents' psychosocial problems on the oral health of their children. Thus, to increase understanding of this topic, the main purpose of the present study is to identify possible relationships between parents' or caregivers' depression, smoking, and alcohol use and the oral health of children.

MATERIALS AND METHODS

This study was approved by the Research Ethics Committee of the Federal University of Rio de Janeiro, Rio de Janeiro, Brazil, by the CAAE number 68963517.8.0000.5257 and the ethics approval number 2.328.197. Before starting this study, informed consent was obtained from parents and a formal agreement from children/adolescents.

This research can be considered a pilot study, as no other research directly relates parents' or caregivers' psychiatric disorders and alcohol and tobacco consumption to the oral health of children without disabilities.

An observational cross-sectional study was conducted with a non-probabilistic sample, selected by convenience including all those who attended an appointment during one semester and agreed to participated. The final sample consisted of 85 children and adolescents aged 5-11 years of both sexes and their primary caregivers. Participants were patients at the Pediatric Dentistry Clinic in the Department of Pediatric Dentistry and Orthodontics at the Faculty of Dentistry of the Federal University of Rio de Janeiro, Brazil. Children went to the clinic accompanied by their parents or legal guardians in the period between March and August 2019. Children with negative behavior towards the clinical examination, children wearing orthodontic appliances, and guardians who did not agree to participate were excluded from this study.

Dependent variables were children's oral biofilm, gingival condition and dental caries. Predictors were adults' depression and use of alcohol/tobacco.

Instruments and Data Collection

PHASE I: Assessment of parental/caregiver depression and alcohol/tobacco use

To assess the presence of depression symptoms, parents/caregivers completed the PHQ (Patient Health Questionnaire) in its two versions (PHQ-2 and PHQ-9)[9-11] in face-to-face interviews. First, the PHQ-2 was used as a screening test for all parents. Subsequentially, those who answered "yes" to at least one question completed the PHQ-9 questionnaire. The PHQ-9 contains 9 items. Each item is scored from 0 to 3, resulting in a maximum score of 27. A score from 0 to 9 indicates the absence of depression, a score of 10 to 14 is considered mild depression, a score from 15 to 19 indicates moderate depression, and scores from 20 to 27 indicate severe depression. The two questionnaires were validated for the Brazilian population.[13-15]

Afterwards, all parents/caregivers completed the Brazilian version of the Alcohol Use Identification Test (AUDIT)[16] to assess alcohol consumption and risk of dependency. The questionnaire included 10 questions concerning the previous 12 months. Possible scores range from 0 to 40. Scores from 0 to 7 indicate low risk or moderate consumption, scores from 8 to 15 indicate risky consumption, and scores from 16 to 19 indicate harmful use or high consumption. Scores of 20 or more indicate a likely dependency.

Lastly, parents/caregivers completed the Fagerström Test for Addiction of Nicotine (FTND)[17,18] to detect dependence on this substance. The FTND has a six-item scale and produces scores ranging from 0 to 10. The score of nicotine addiction is divided into five levels: very low (0-2 points); low (3-4 points); moderate (5 points); high (6-7 points); and very high (8-10 points).

PHASE II: Children's clinical examination

Before the intra-oral clinical examination, a calibration procedure was undertaken in 10 patients (who were not included in the study population) by a single examiner previously trained and calibrated. The intra-examiner kappa concordance test was performed for the clinical parameters of biofilm index, gingival condition, and caries index, revealing values ≥ 0.75.

To evaluate their oral condition, all patients were examined using a mirror, explorer, gauze and periodontal probe under artificial light after previous prophylaxis. The criteria described below were used for the biofilm, gingival condition and caries index.

The quality and quantity of biofilm visible on the surfaces of the teeth were evaluated according to the biofilm index proposed by Ribeiro *et al*.[19] Biofilm was classified as thin when it could only be identified after drying the dental surface. Thick biofilm was firmly adhered to the dental surface and was easily identified upon visual examination. To classify the biofilm's resistance to removal, a single side scrub movement (from distal to mesial or vice versa) was performed with gauze. Children who scored 0 were considered to have an excellent biofilm control, while index scores of 1 and 2 were considered satisfactory and indicated a thin and easily removed biofilm (immature). Scores of 3, 4 and 5 represented poor mechanical control and indicated the presence of a thick and firmly adhered (mature) biofilm.

To assess the gingival condition, the bleeding index proposed by Aimano and Bay (1975)[20] was adopted. The periodontal probe was gently inserted in the gingival sulcus, covering the buccal and the palatal surfaces. In the case of spontaneous bleeding or bleeding after the probing, the score was 1. In the case of lack of bleeding, the score was 0.

Statistical analysis

The index recommended by the World Health Organization (WHO, 1997)[3], from which one can infer DMF-T for a permanent dentition and dmf-t for a primary dentition, was used in the dental examination to evaluate children's experience of dental caries. The data were organized and analyzed using the Statistical Package for the Social Sciences (SPSS for Windows, version 20.0; IBM Corp., Armonk, NY). A descriptive and univariate statistical analysis was performed to characterize the sample using the chi-squared test for nominal variables and the Student *t*-test for quantitative variables. A 95% confidence interval was used for the chi-squared test and Fisher's exact test. Significance level was set at $p<0.05$.

RESULTS

The sample included 85 pairs of legal guardians and child patients. The average age of patients was 8 years ± 3.07, with a minimum age of 5 and a maximum of 11; 60% of patients were male and 40% were female. Children's main caregivers were their parents (83.5%). The average age of caregivers was 42 years ± 11.22, with a minimum age of 31 and a maximum of 53. The majority of parents and caregivers (65.9%) had completed high school (Table 1).

Regarding the presence of depression, 24.7% of parents or caregivers manifested depressive symptoms. Mild levels of depression (15.3%) were most frequent. With regard to alcohol consumption, the majority (89.4%) had low risk or abstinence, while 10.6% presented risky consumption or dependence. Only 10.6% of parents and caregivers consumed tobacco. The majority (5.9%) consumed a very low amount of tobacco (Table 2).

The results of the bivariate analysis (Table 3) showed that gingival bleeding was higher in children whose parents or caregivers consumed alcohol (p=0.038). No statistically significant association was found between depression or tobacco consumption and children's oral health.

Table 1: Sample distribution, according to sociodemographic characteristics.

Children and adolescents (n = 85)		
Variables	**N**	**%**
Gender		
Female	34	40.0
Male	51	60.0
Age, (in years)		
≤ 8	40	47.1
> 8	45	52.9
Caretakers (n = 85)		
Age, (in years)		
≤ 42	51	60.0
> 42	34	40.0
Type of legal guardians		
Parents	71	83.5
Others	14	16.5
Educational level		
Illiterate	1	1.2
Primary education	20	23.5
Secondary education	56	65.9
Higher education	8	9.4

Table 2: Sample distribution (n = 85), according to psychological characteristics and substance use (alcohol and/or tobacco).

Depression		
Variables analyzed	**N**	**%**
Yes	21	24.7
Mild	13	15.3
Moderate	4	4.7
Severe	4	4.7
No	64	75.3
Alcohol consumption		
Low-risk or no-risk	76	89.4
Risky consumption or dependency	9	10.6
Tobacco consumption		
Yes	9	10.6
Very low	5	5.9
Low	2	2.4
High	2	2.4
No	76	89.4

Table 3: Association between depression, risky alcohol and tobacco use and the children's oral health (85 patients)

		Biofilm control %(n)		*p*-value*	Gingival bleeding* % (n)		*p*-value*	dmf-t	*p*-value**	DMFT	*p*-value**	Caries experience% (n)		*p*-value*	DMFT=0		*p*-value*
		Excellent/ satisfactory	Poor		Yes	No		Average (DP)		Average (DP)		Yes	No		Yes	No	
Depression	**Yes (n =21)**	76.2(16)	23.8(5)	0.50	2.8(5)	76.2(16)	0.50	2.85 (1.90)	0.22	0.75(1,33)	0.97	71.4(15)	50(19)	0.11	70(14)	73.5(25)	0.78
	No (n =64)	82.8(53)	17.2(11)		17.2(11)	82.8(53)		1.86(2.74)		0.74(1.40)		28.6(6)	50(19)		30(6)	23.5(9)	
Alcohol consumption	**Low-risk or norisk**	82.9(63)	17.1(13)	0.23	15.8(12)	84.2(64)	0.03	2.04(2.63)	0.81	0.72(1.38)	0.73	51(26)	66.7(6)	0.31	69.6(32)	66.7(6)	0.57
	Risky consumption or dependency (n=9)	66.7(6)	33.3(3)		44.4(4)	55.6(5)		2.29(2.62)		0.89(1.45)		49(25)	33.3(3)		30.4(14)	33.3(3)	
Tobacco consumption	**Yes (n=9)**	77.8(7)	22.2(2)	0.78	33.3(3)	66.7(6)	0.23	2.0(2.00)	0.94	0.89 (1.76)	0.73	66.7(6)	33.3(3)	0.41	77.8(7)	22.2(2)	0.49
	No (n=76)	81.6(62)	18.4(14)		17.1(13)	82.9(63)		2.07(2.69)		0.72(1.33)	56.3(43)		43.4(33)		70.6(48)	29.4(20)	

*Note: *Qui-square or Fisher test; ** Student t-test.*

DISCUSSION

Caries is still one of the most common chronic diseases among children,[3] and its cause has been mainly attributed to factors such as poor oral hygiene and a high- sugar diet. However, no other study has considered psychiatric disorders such as depression and substance use (tobacco and/or alcohol) in caregivers as possible contributing factors to children's poor oral health.

Recent studies have found a correlation between depression in mothers and caries in children without disabilities.[10,21] In this study, we did not observe a significant association between depression in caregivers and caries in patients. This may be because previous studies took place in the field, while our sample was comprised of regular patients of the pediatric dental clinic, who received specialized dental care according to their individual needs. Although this study found no statistical relationship, unlike the most recent studies, our results were equivalent to those found in a previous study conducted with special children[11] at the same institution. This suggests that the location of the research may influence the results.

This study found a significant positive association between alcohol consumption by legal caregivers and gingival bleeding rate in children. This association needs a careful interpretation because the study sample was small, and other systemic factors, such as oral hygiene habits, may have influenced the results; therefore, this result could be spurious. However, Gesser *et al*.[22] associated gingival bleeding with socioeconomic variables, such as place of residence and parents' educational level. In spite of the difference between the samples of Gesser *et al*.[22] and this one, participants answered the same questions in the initial questionnaire. Further, it was observed that legal caregivers who presented a risk of alcohol dependence lived mostly in high-risk areas, with one exception, and the majority had some secondary education, though may not have completed it. These factors could explain the high level of gingival bleeding in the children of these caregivers.

Leroy *et al*.[12] found a positive association between parents who smoked and caries experience in preschool children. These children were under 5 years of age and only had deciduous teeth. This result is not compatible with the one found in this study, since we did not observe a significant association between the tobacco use by caregivers and caries disease in patients. In the study of Garate *et al*.[11], conducted at the same institution with special patients, a positive association was found between use of tobacco by legal guardians and caries in children's primary teeth. In the present study, the age range was greater than the one used by Leroy *et al*.[12] study and the majority of the patients already had some or nearly all of their permanent teeth, which might also explain the difference in the results. The deciduous teeth have a thinner glaze that is less mineralized, and are thus more susceptible to caries disease.[23]

One limitation of this study is the small sample size. Additionally, radiographs were not taken. Therefore, proximal caries was probably not identified. In order to be considered as caries, the teeth should have been cavitated to eliminate active white spots. A further limitation was that biomarkers were not used to confirm the diagnosis of caregivers based on the questionnaires. The use of questionnaires can result in classification errors, in this case because respondents may have been ashamed of admitting their depression or use of alcohol and tobacco. Additionally, these data cannot be extrapolated to all children. These results should also be considered preliminary because the children represent a biased sample (obtained from the Dental School) and a convenience selection of volunteers. These limitations highlight the need to undertake longitudinal studies using larger samples to further evaluate the current data.

The results of this preliminary study suggests that it is important to recognize these changes in those caregivers and that in some way the child's oral health can be harmed by this. So, the management of the patient should include welcoming and direct guidance to parents who have similar conditions. Also, that epidemiological studies should be encouraged to verify the real association between these changes and their influence on children's oral health.

CONCLUSION

From the results of this study, the following conclusions were drawn:

1. There is a positive association between caregivers' alcohol consumption and gingival bleeding in children.

2. Depression and the consumption of alcohol and tobacco by caregivers does not influence children's caries experience.

REFERENCES

1. Cruz LR, D'Hyppolito IM, Barja-Fidalgo F, de Oliveira BH. "Cárie é transmissível?". Rev. Bras. Odontol. Rio de Janeiro. 2017. doi: 10.18363/rbo.v74n1.p.68

2. Brasil. Ministério da saúde. Coordenação Nacional de Saúde Bucal. Projeto SB Brasil 2010: condições de saúde bucal da população brasileira. Brasilia: Ministerio da saúde; 2011.

3. Organization WH. World Health Organization Oral Health Surveys–Basic Methods. Geneva: World Health Organization; 1997.

4. Moura MS, Santos-Pinto LAM, Giro EMA, Cordeiro RCL. Cárie dentária relacionada ao nível socioeconômico em escolares de Araraquara. Rev. Odontol UNESP. 1996; 25(l):97-07.

5. Neto MRL, Elkis H. Psiquiatria Básica. 2. ed. Porto Alegre: Artmed; 2007.

6. Vidal CEL, Yanez BFP, Chaves CVS, Yanez CFP, Michalaromichs IA, & Sousa LA. Transtornos mentais comuns e uso de psicofármacos em mulheres. Caderno de Saúde Coletiva. 2013; 21(4):457-464.
7. Dang AT, Ho M, Kroenke K, Grupp-Phelan J. Maternal somatic symptoms psychosocial correlates and subequent pediatric emergency deparment use. Pediatr Emerg Care. 2013; 29(2):170-4. doi: 10.1097/PEC.0b013e3182809a10.
8. Wu V, East P, Delker E, Blanco E, Caballero G, Delva J, et al. Associations Among Mothers' Depression, Emotional and LearningMaterial Supportt Their Child, and Children's Cognitive Functioning: A 16Year Longitudinal Study. ChildDevelopment. 2017; 1-17. doi: 10.1111/cdev.13071.
9. Jabbarifar SE, Ahmady N, Sahafian SAR, Samei F, Soheillipour S. Association of parental stress and early childhood caries. Dental research journal. 2006 ;6(2):65.
10. dos Santos Pinto G, de Ávila Quevedo L, Correa MB, Azevedo MS, Goettems ML, Pinheiro RT, et al. Maternal depression increases childhood dental caries: a cohort study in Brazil. Caries research. 2017; 51(1):17-25.
11. Garate KMSG, de Cotrim J, Alves BMA, Castro GFB. Influence of Depression and Use of Alcohol and / or Tobacco by Parents in the Oral Health of Children with Disabilities. Pesquisa Brasileira em Odontopediatria e Clínica Integrada. 2021. doi : 10.1590/pboci.2021.024
12. Leroy R, Hoppenbrouwers K, Jara A, Declerck D. Parental smoking behaviorand caries experience in preschool children. Community Dent Oral Epidemiol. 2008; 36(3):249-57.
13. Spitzer RL, Kroenke K, Williams JB, Group PHQPCS. Validation and utility of a self-report version of PRIME-MD: the PHQ primary care study. Jama. 1999; 282(18):1737-44.
14. de Lima Osório F, Vilela Mendes A, Crippa JA, Loureiro SR. Study of the Discriminative Validity of the PHQ9 and PHQ2 in a Sample of Brazilian Women in the Context of Primary Health Care. Perspectives in psychiatric care. 2009; 45(3):216-27.
15. Santos IS, Tavares BF, Munhoz TN, Almeida LSPd, Silva NTBd, Tams BD, et al. Sensitivity and specificity of the Patient Health Questionnaire-9 (PHQ-9) among adults from the general population. Cadernos de Saúde Pública. 2013; 29(8):1533-43.
16. Babor TF, Higgins-Biddle JC, Saunders JB, Monteiro MG, Organization WH. AUDIT: the alcohol use disorders identification test. Guidelines for use in primary health care. 2th ed. 2001.
17. Meneses-Gaya ICd, Zuardi AW, Loureiro SR, Crippa JAdS. Psychometric properties of the Fagerström test for nicotine dependence. Jornal Brasileiro de Pneumologia. 2009; 35(1):73-82.
18. Carmo JTd, Pueyo AA. A adaptação ao português do Fagerström test for nicotine dependence (FTND) para avaliar a dependência e tolerância à nicotina em fumantes brasileiros. Rev Bras Med. 2002; 59(1/2):73-80.
19. Ribeiro AA, Portela M, Souza, IP. Relation between biofilm, caries activity and gingivitis in HIV+ children. Pesqui Odontol Bras. 2002;16(2):144-50.
20. Ainamo J, Bay I. Problems and proposals for recording gingivitis and plaque. International dental journal. 1975; 25(4):229-35.
21. Seow W, Clifford H, Battistutta D, Morawska A, Holcombe T. Case-control study of early childhood caries in Australia. Caries research. 2009; 43(1):25-35.
22. Gesser HC, Peres MA, Marcenes W. Condições gengivais e periodontais associadas a fatores socioeconômicos. Rev Saude Publica. 2001; 35(3):289-293.
23. De Menezes Oliveira MAH, Torres CP, GomesSilva JM, Chinelatti MA, De Menezes FCH, PalmaDibb RG, et al. Microstructure and mineral composition of dental enamel of permanent and deciduous teeth. Microscopy research and technique. 2010; 73(5):572-7.
24. Ljubešiæ M. Parents of children with disabilities and parenting support. UNICEF-a za Hrvatsku. 2013.
25. Lima MCPS, Lobo INR, Leite KVM, Muniz GRL, Steinhauser HC, Maia PRM. Oral health status of children admitted to the Children's Municipal Hospital of Imperatriz-Maranhão. Rev Bras Odontol [Internet]. 2016; 73(1):24-29. Available from: http://www.revista.aborj.org.br/index.php/rbo/article/view/607/477.

AVALIAÇÃO DAS CARACTERÍSTICAS SUPERFICIAIS DOS INSTRUMENTOS RECIPROC, RECIPROC BLUE E XP-ENDO SHAPER

Fernanda Kac **Szmajser**[1], Gabriela Hernandez **Costa**[1], Letícia do Vale Campos **Simão**[1], Carolina Oliveira de **Lima**[2], Renata Antoun **Simão**[3], Celso Neiva **Campos**[4], Maíra **Prado**[1*]

[1]Faculdade de Odontologia, Universidade Veiga de Almeida, Rio de Janeiro, Rio de Janeiro, Brasil.
[2]Faculdade de Odontologia, Universidade do Estado do Rio de Janeiro, Rio de Janeiro, Rio de Janeiro, Brasil.
[3]Departamento de Odontologia, Universidade Federal do Rio de Janeiro, Rio de Janeiro, Rio de Janeiro, Brasil.
[4]Departamento de Odontologia, Universidade Federal de Juiz de Fora, Juiz de Fora, Minas Gerais, Brasil.

Palavras-chave: Instrumentos Odontológicos. Microscopia Eletrônica de Varredura. Superfície.

RESUMO

Introdução: o controle da qualidade no processo de fabricação dos instrumentos endodônticos é importante uma vez que defeitos e falhas superficiais podem comprometer o preparo dos canais. **Objetivo**: avaliar a presença de defeitos e falhas do processo de fabricação na superfície de instrumentos Reciproc (R25), Reciproc Blue (RB25) e XP-endo shaper (XP), por meio de microscopia eletrônica de varredura (MEV). **Materiais e Métodos**: Ao total, foram avaliados 60 instrumentos de níquel titânio, sendo 20 por grupo: R25, RB25 e XP, em três regiões: 0mm (ponta do instrumento), 4mm e 7mm da ponta, no MEV, com aumento de 100x. As imagens foram avaliadas quanto ao número de falhas de fabricação (bordo irregular, ranhura, microcavidade e rebarba) e por um sistema de escores de 1 a 4, sendo 1, nenhuma área com defeito e 4, mais de cinco áreas com defeitos na superfície. Os dados foram submetidos à análise estatística utilizando o teste de Dunn (p<0,05). **Resultados**: Sobre a análise por regiões, foram identificadas diferenças significativas em grande parte dos instrumentos. Comparando os diferentes instrumentos, não foi observada diferença significativa para microcavidade (p=0,76), bordo irregular (p=0,98) e rebarba (p=0,40). O instrumento R25 mostrou maior número de ranhuras em comparação aos demais (p=0,0000*). RB25 mostrou maiores valores de escores que os instrumentos R25 (p= 0,0002) e XP (p=0,01). **Conclusão**: Todos os instrumentos avaliados apresentaram defeitos/falhas superficiais do processo de fabricação.

Keywords: Dental Instruments. Scanning Electron Microscopy. Surface.

ABSTRACT

Introduction: The quality control of endodontic instruments is extremely important since defects and failures on their surface, during their manufacturing process, can compromise the preparation of root canal. **Objective**: this study evaluated the presence of defects and failures in the manufacturing process on the surface of Reciproc (R25), Reciproc Blue (RB25) and XP endo-shaper (XP) instruments by means of scanning electron microscopy (SEM). **Materials and Methods**: In total, sixty nickel titanium instruments (n=20): R25, RB25 and XP were evaluated in the scanning electron microscope in three regions: 0mm (tip of the instrument), 4mm and 7mm of the tip, with a magnification of 100x. The images were evaluated in relation to the number of manufacturing faults (irregular border, groove, microcavity and burr) and by a system of scores, from 1 to 4, where 1 is no defective area and 4, more than five areas with defects on the surface. The data were submitted to statistical analysis using Kruskal-Wallis and Mann-Whitney tests (p<0.05). **Results**: Regarding the analysis by regions, significant differences were identified in most of the instruments. Comparing the different instruments, no significant difference was observed for microcavity (p=0.76), irregular border (p=0.98) and burr (p=0.40). The R25 instrument showed a greater number of grooves compared to the others (p=0.0000*). RB25 showed higher scores than the R25 (p=0.0002) and XP (p=0.01) instruments. **Conclusion**: All evaluated instruments showed defects/failures in the manufacturing process.

Submitted: October 6, 2020
Modification: June 04, 2021
Accepted: June 12, 2021

***Correspondence to:**
Maíra do Prado
Address: Praça da Bandeira, 149, Rio de Janeiro – RJ, Brazil. Zip code 20270-150
Telephone number: +55 (21) 97104-1717
E-mail: mairapr@hotmail.com

INTRODUÇÃO

O controle da qualidade dos instrumentos endodônticos é de extrema importância uma vez que durante o processo de fabricação podem ocorrer defeitos e falhas superficiais, que podem comprometer a qualidade da instrumentação dos canais e com isso, o sucesso do tratamento endodôntico a longo prazo.[1-3] Visto que não é possível observar estes defeitos e falhas a olho nu, o cirurgião-dentista, ao adquirir estes instrumentos, confia na qualidade indicada pelo fabricante. Entretanto, os instrumentos de níquel titânio (NiTi), de modo geral, são produzidos por usinagem, apresentando grande flexibilidade e propriedade de memória de forma da liga, o que pode resultar em uma superfície irregular, tensionada, plasticamente deformada ou contaminada.[1-3]

A complexa anatomia e morfologia do sistema de canais radiculares (SCR), como paredes irregulares, de diferentes formatos, e curvaturas, podem influenciar no sucesso do tratamento. Dessa forma, novos instrumentos vêm sendo desenvolvidos para suprir esta demanda, a fim de diminuir a chance de falhas durante a intervenção endodôntica.[4-5]

Tratando-se dos recentes avanços na Endodontia, ressalta-se o surgimento do instrumento Reciproc que opera em movimento recíproco ou reciprocante. Este instrumento apresenta uma maior resistência à fadiga cíclica e maior flexibilidade quando comparado aos instrumentos de NiTi operados em movimento contínuo.[6-8] Somado a isso, também merecem destaque os instrumentos Reciproc Blue, a nova geração de instrumentos Reciproc, que apresenta maior flexibilidade e menor risco de fratura do que o instrumento Reciproc, devido ao tratamento térmico da liga, que permite um melhor acesso a canais curvos.[9] Ainda, em relação a modificações no design e na liga, foram desenvolvidos os instrumentos XP-endo shaper, que alteram de forma em temperatura de 35^{0}C ou mais, possibilitando, de acordo com o fabricante, maior flexibilidade e preparo de áreas de difícil acesso no canal.[10-11]

A partir destes avanços, os instrumentos têm sido amplamente estudados e empregados na rotina odontológica.[12-13] Um estudo anterior verificou que todos os instrumentos analisados apresentaram defeitos, porém os instrumentos Reciproc demonstraram menor quantidade de defeitos e deformações ao serem comparados com o instrumento reciprocante WaveOne®[13]. No entanto, até o momento, não foi localizado na literatura, nenhum estudo que avaliou a superfície dos instrumentos XP - endo shaper.

Diante da importância em manter a qualidade dos instrumentos endodônticos durante o seu processo de fabricação e com o surgimento de novos instrumentos no mercado, o objetivo deste estudo foi avaliar a presença de defeitos e falhas do processo de fabricação na superfície dos instrumentos Reciproc (R25), Reciproc Blue (RB25) e XP-endo shaper, por meio da microscopia eletrônica de varredura.

MATERIAIS E MÉTODOS

Preparo das amostras

Ao total foram avaliados 60 instrumentos de NiTi novos, sendo 20 instrumentos por grupo: Reciproc R25 (diâmetro na ponta de 0,25 mm e conicidade .08) (VDW, Munique, Alemanha), Reciproc Blue RB25 (diâmetro na ponta de 0,25 mm e conicidade .08) (VDW, Munique, Alemanha), e XP - endo Shaper (diâmetro na ponta de 0,30 mm e conicidade .04) (FKG Dentaire, La Chaux-de-Fonds, Suiça).

Inicialmente, os instrumentos foram removidos das caixas, com o auxílio de uma pinça clínica limpa e estéril, e lavados em ultrassom por 10 minutos para a remoção de sujidades. Em seguida, foram removidos da água, com o auxílio da pinça clínica, secos com jatos de ar e fixados em base metálica.[14]

Avaliação, processamento e análise dos dados

Os instrumentos foram examinados no microscópio eletrônico de varredura (MEV) (JSM 5800LV, Jeol, Tóquio, Japão) em três regiões: 0mm (ponta do instrumento), 4mm da ponta e 7mm da ponta, com aumento de 100x.Terminada a captura das imagens, estas foram importadas para o programa Power Point (Microsoft Corporation).

As análises foram realizadas por dois avaliadores, alunos de graduação em Odontologia do último período, cegados. Para calibração dos avaliadores, 20 imagens com diferentes tipos de defeitos foram analisadas em conjunto. Após a calibração, todas as imagens foram avaliadas. O teste Kappa foi utilizado para análise interexaminadores, demonstrando boa concordância entre os mesmos com valor de 0,97. Em caso de discordância, as imagens foram reavaliadas a fim de obter um consenso entre os examinadores.

As imagens foram avaliadas em relação ao número de falhas de fabricação: bordo irregular, ranhura, microcavidade e rebarba. Ainda, utilizou-se um sistema de escores nas diferentes imagens avaliadas: 1 – instrumento sem nenhuma área de defeito na superfície examinada; 2 - instrumento com cerca de uma a três áreas com defeitos na superfície examinada; 3 - instrumento com cerca de quatro a cinco áreas com defeitos na superfície examinada; 4 -

instrumento com mais de cinco áreas com defeitos na superfície examinada[14].

Análise estatística

Os dados foram submetidos à análise estatística utilizando-se o teste de Kappa, para análise interexaminadores. Para comparação entre os diferentes instrumentos e nas diferentes regiões dos instrumentos foram utilizados os testes de Kruskal-Wallis e Dunn, com nível de significância de 5%.

RESULTADOS

Todos os sistemas avaliados apresentaram defeito ou falha no seu processo de fabricação (Figuras 1 a 3). Os dados de microcavidades, bordo irregular, ranhura e rebarba estão descritos na Tabela 1, em cada região avaliada (0, e 4 e 7mm da ponta).

Com relação à microcavidade, no instrumento R25, as regiões de 4 e 7mm aquém da ponta do instrumento apresentaram maior número de defeitos quando comparadas a região 0mm (ponta do instrumento) (p=0,02). Nos instrumentos RB25 (p=0,94) e XP-endo Shaper (p=0,64) não houve diferença estatisticamente significativa em relação às regiões avaliadas. Além disso, não houve diferença em relação ao número de microcavidades entre os instrumentos avaliados (p=0,76).

Tratando-se de bordo irregular, no instrumento R25, na região 7mm, houve maior presença de bordos irregulares quando comparado a região 0mm (p=0,03), sem diferenças em relação a região 4mm (p=0,20). No instrumento RB25, não foram identificadas diferenças entre as regiões do instrumento (p=0,35). No entanto, no instrumento XP, a região 0mm (ponta do instrumento) apresentou maior número de defeitos do que as regiões 4mm (p=0,02) e 7mm (p=0,03). Com relação aos diferentes instrumentos, não houve diferença em relação ao número de bordo irregular em relação ao total (p=0,98). No entanto, o instrumento XP demonstrou maior número de bordos irregulares quando comparado ao R25, na região 7mm (p=0,03).

No que concerne a presença de ranhura, não houve diferença entre os instrumentos, em relação as regiões avaliadas. Entretanto, ao se comparar os diferentes instrumentos, R25 demonstrou maiores valores de ranhura em comparação aos demais (p=0,0000*).

No que diz respeito a rebarba, no instrumento R25 não foram identificadas diferenças com relação as regiões avaliadas (p=0,51). No RB25, a região 0mm demonstrou menor número de defeitos quando comparada as demais (p=0,013). Já nos instrumentos XP, a região 7mm apresentou menor número de rebarbas do que as regiões 0mm (p=0,02) e 4mm (p=0,0004). No total, não houve diferença entre os instrumentos avaliados em relação ao número de rebarbas (p=0,40).

Quanto à análise por escores, em todos os instrumentos avaliados, não houve diferença estatística com relação às regiões avaliadas. Comparando os diferentes instrumentos, RB25 mostrou maiores valores em detrimento ao instrumento R25 (p=0,0002) e XP (p=0,01) (Tabela 2).

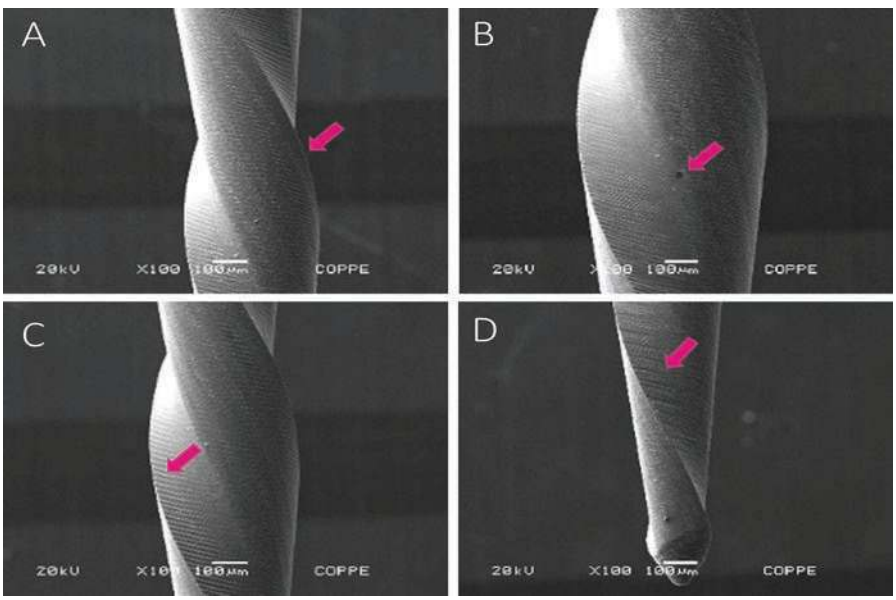

Figura 1: Fotomicrografias ilustrando bordo irregular A), microcavidade B), ranhura C) e rebarba D) no instrumento Reciproc - (seta rosa).

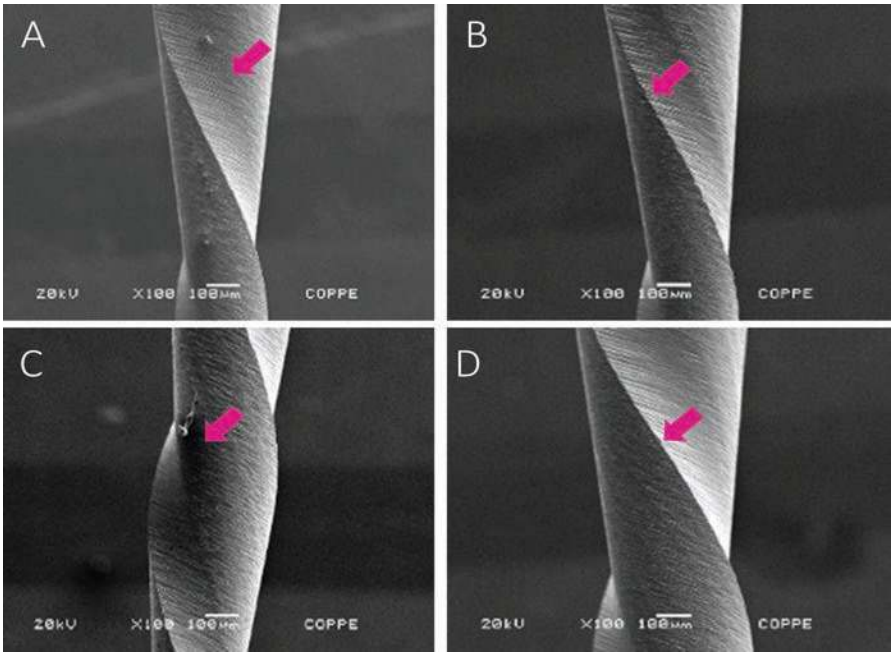

Figura 2: *Fotomicrografias ilustrando bordo irregular A), microcavidade B), ranhura C) e rebarba D) no instrumento Reciproc Blue - (seta rosa).*



Figura 3: *Fotomicrografias ilustrando bordo irregular A), microcavidade B), ranhura C) e rebarba D) no instrumento XP endo shaper - (seta rosa).*

***Tabela 1**: Análise da presença de microcavidade, bordo irregular, ranhura e rebarba do processo de* fabricação nas diferentes regiões dos instrumentos.

Defeito/Região do instrumento	R25	RB25	XP - endo shaper
Microcavidade			
0 mm	3/0/5Aa	5/3/5Aa	5/0/5Aa
4 mm	5/0/5Ba	5/2/5Aa	5/0/5Aa
7 mm	5/1/5Ba	5/1/5Aa	5/0/5Aa
Total	5/0/5a	5/0/5a	5/0/5a
Bordo irregular			
0 mm	0/0/4Aa	1/0/5Aa	1/0/5Ba
4 mm	0/0/5ABa	0/0/5Aa	0/0/3Aa
7 mm	1/0/5Bb	0/0/3Ab	0/0/2Aa
Total	1/0/5a	0/0/5a	1/0/5a
Ranhura			
0 mm	1/1/2Ab	1/1/2Aab	1/1/2Aa
4 mm	1,5/1/2Ab	1/1/2Aa	1/1/2Aa
7 mm	1,5/1/2Ab	1/1/1Aa	1/1/1Aa
Total	1/1/2b (54,5*)	1/1/2a (40,9*)	1/1/2a (36,5*)
Rebarba			
0 mm	1/0/2Aa	1/0/2Aa	1/0/3Ba
4 mm	1/0/5Ab	1/0/2Bab	2/0/4Ba
7 mm	1/1/2Ab	1/0/2Ba	0/0/2Aa
Total	1/0/5a	1/0/2a	1/0/4a

Note: Letras minúsculas diferentes indicam diferenças entre os grupos (no mesmo tipo de defeito); letras maiúsculas indicam diferenças significativas entre as regiões avaliadas dos instrumentos (0, 4 e 7mm) (Teste de Dunn, p<0,05). Med- mediana; min- mínimo; máx- máximo; (*) valor do ranking médio.

Tabela 2: *Variação dos escores dos defeitos do processo de fabricação dos diferentes instrumentos.*

Região do instrumento	R25	RB25	XP-endo shaper
0 mm	4/2/4Aab	4/4/4Ab	4/2/4Aa
4 mm	4/2/4Aa	4/4/4Aa	4/2/4Ab
7 mm	4/2/4Aa	4/4/4Ab	4/2/4Aa
Total	4/2/4a	4/2/4a	4/2/4a

Note: Letras minúsculas diferentes indicam diferenças entre os grupos; letras maiúsculas indicam diferenças significativas entre as áreas dos instrumentos (Teste de Dunn, p<0,05). Med- mediana; min- mínimo; máx- máximo.

DISCUSSÃO

Os instrumentos endodônticos vêm sendo continuamente aperfeiçoados em relação à qualidade da usinagem e no polimento eletroquímico, a fim de minimizar falhas e irregularidades nas lâminas de corte.[14] Tais defeitos, na presença de fadiga, podem agir como zonas de concentração de tensão e desencadear a fratura do instrumento, podendo comprometer a instrumentação dos canais e com isso, o sucesso do tratamento. Torna-se evidente, portanto, a necessidade de garantir a qualidade desses instrumentos no momento de sua fabricação.[1,14] Apesar disso, a presença de falhas e defeitos na parte ativa dos instrumentos, antes mesmo de sua utilização, ainda é recorrente.[14]

No presente estudo, foram avaliados isoladamente, na parte ativa do instrumento, diferentes tipos de defeitos: microcavidade, bordo irregular, rebarba e ranhura. Com

relação a análise por regiões, o presente estudo verificou diferenças significativas nos instrumentos, principalmente no R25. No entanto, Arantes *et al*.[12] avaliaram diversos instrumentos (Twisted File, BioR[1]Ce, Mtwo, and EndoWave) e não observaram diferença estatisticamente significantiva entre as partes ativas analisadas. Esta distinção nos resultados possivelmente ocorreu pelos diferentes instrumentos avaliados em cada estudo.

Os instrumentos examinados apresentaram índices semelhantes para microcavidade, bordo irregular e rebarba. Com relação a ranhuras, o instrumento Reciproc mostrou um número maior quando comparado aos instrumentos Reciproc Blue e XP-endo shaper, o que pode ser justificado pelo diferentes tratamentos térmicos empregados nos instrumentos Reciproc Blue, no qual há a formação de uma camada de óxido na cor azul na superfície do instrumento, que o caracteriza, e XP-endo Shaper, que é produzido pela liga MaxWire®, que é responsável pela alteração de formato do instrumento quando em contato com a temperatura coroporal.[15] Embora tais ranhuras estejam presentes, estas podem não ser significativas para a fratura dos instrumentos. No estudo de Caballero-Flores *et al*.[16], o índice de fratura do sistema Reciproc, ao serem instrumentados 1.226 canais radiculares, foi de 0,93%, sendo considerado um valor extremamente baixo.

No segundo momento deste estudo, os defeitos foram classificados em um sistema de escores, no qual foi contabilizada a soma de todas as falhas de fabricação. Nesta pesquisa, o instrumento Reciproc Blue evidenciou mais de cinco áreas com defeitos na superfície examinada, apresentando um maior valor ao ser comparado com os demais instrumentos. Contudo, segundo o estudo de Keskin *et al*.[17], no qual os instrumentos avaliados foram operados até ocorrer sua fratura, o instrumento Reciproc Blue apresentou uma maior resistência à fadiga cíclica do que o instrumento Reciproc (p<0,05), mostrando que o processo de fratura não pode ser associado a um fator isolado, mas sim a uma combinação de fatores. Além disso, de acordo com Silva *et al*.[18], o instrumento Reciproc Blue mostrou necessidade de um maior ângulo de rotação para fratura, mas um torque menor para falha do que o sistema Reciproc.

Embora tais defeitos estejam presentes, quando utilizados uma única vez, como preconizado pelo fabricante, o risco de fratura dos instrumentos é baixo.[16,19] No entanto, o uso repetido dos mesmos pode acarretar a fratura. Nesse sentido, Karamifar *et al*.[20] avaliaram as alterações superficiais de instrumentos após o uso único e múltiplos usos no preparo do canal radicular, e verificaram que a partir do segundo uso, o instrumento XP-endo shaper mostrou microtrincas que se propagaram e levaram à fratura do instrumento no quarto uso. Ainda, observou-se que o movimento reciprocante não demonstrou resultados superiores ao movimento de rotação contínua em relação aos defeitos na superfície do instrumento.

A literatura mostra que os instrumentos avaliados no presente estudo apresentam uma habilidade semelhante na formatação dos canais radiculares.[19,21] Assim cabe ao profissional a escolha do instrumento, baseada não apenas neste, mas em diferentes fatores, entre eles o acabamento superficial. Neste contexto, é essencial que o cirurgião-dentista atente para a possibilidade de fratura do instrumento utilizado, assim como os motivos para o seu acometimento. Embora este estudo apresente resultados relevantes para o risco de fratura e desempenho quanto ao preparo químico mecânico, também é prudente que haja uma análise de tais instrumentos após o preparo dos canais radiculares. Apesar das melhorias dos instrumentos durante os últimos anos, como modificações no design e no tratamento das ligas metálicas, defeitos e falhas no processo de fabricação ainda são uma realidade que exige atenção.

CONCLUSÃO

Todos os instrumentos avaliados mostraram defeitos e/ou falhas no processo de fabricação.

AGRADECIMENTOS

À Fundação de Amparo a Pesquisa do Estado do Rio de Janeiro (Faperj E-26/202.784/2019) pelo apoio financeiro.

REFERÊNCIAS

1. Anderson ME, Price JW, Parashos P. Fracture resistance of electropolished rotary nickel-titanium endodontic instruments. J Endod. 2007 Oct;33(10):1212-1216. doi: 10.1016/j.joen.2007.07.007.

2. McGuigan MB, Louca C, Duncan HF. Endodontic instrument fracture: causes and prevention. Braz Dent J. 2013 Apr;214(7):341-348. doi: 10.1038/sj.bdj.2013.324.

3. Siqueira JF; Lopes HP. Endodontia Biologia & Técnica. In: Lopes HP, Elias CN, Siqueira JF, Vieira MVB. Instrumentos Endodônticos. 4ª ed. Rio de Janeiro: Guanabara Koogan, 2015: 517-519,522,533.

4. de Almeida AP, Souza MA, Miyagaki DC, Dal Bello Y, Cecchin D, Farina AP. Comparative evaluation of calcium hypochlorite and sodium hypochlorite associated with passive ultrasonic irrigation on antimicrobial activity of a root canal system infected with Enterococcus faecalis: an in vitro study. J Endod. 2014 Dec;40(12):1953-1957. doi: 10.1016/j.joen.2014.08.025.

5. de Siqueira Zuolo A, Zuolo ML, da Silveira Bueno CE, Chu R, Cunha RS. Evaluation of the Efficacy of TRUShape and Reciproc File Systems in the Removal of Root Filling Material: An Ex Vivo Micro-Computed Tomographic Study. J Endod. 2016 Feb;42(2):315-319. doi: 10.1016/j.joen.2015.11.005.

6. Vilas-Boas RC, Alcalde MP, Guimarães BM, Ordinola-Zapata R, Bueno CR, Duarte MA. RECIPROC: Comparativo entre a cinemática reciprocante e rotatória em canais curvos. Rev. Odontol. Bras. Central 2013;22(63):1981-3708. https://doi.org/10.36065/robrac.v22i63.835.
7. VDW. <http://www.vdw-dental.com/en/,2019 />. Página consultada em: 10 de março de 2019.
8. De-Deus G, Silva EJ, Vieira VT, Belladonna FG, Elias CN, Plotino G, Grande NM. Blue Thermomechanical Treatment Optimizes Fatigue Resistance and Flexibility of the Reciproc Files. J Endod. 2017 Mar;43(3):462-466. doi: 10.1016/j.joen.2016.10.039.
9. Topçuo□lu HS, Topçuo□lu G. Cyclic Fatigue Resistance of Reciproc Blue and Reciproc Files in an S-shaped Canal. J Endod. 2017 Oct;43(10):1679-1682. doi: 10.1016/j.joen.2017.04.009.
10. Azim AA, Piasecki L, da Silva NUX, Cruz ATG, Azim KA. XP Shaper, A Novel Adaptive Core Rotary Instrument: Micro-computed Tomographic Analysis of Its Shaping Abilities. J Endod. 2017 Sep;43(9):1532-1538. doi: 10.1016/j.joen.2017.04.022.
11. De-Deus G, Belladonna FG, Simões-Carvalho M, Cavalcante DM, Ramalho CNMJ, Souza EM, Lopes RT, Silva EJNL. Shaping efficiency as a function of time of a new heat-treated instrument. Int Endod J. 2019 Mar;52(3):337-342. doi: 10.1111/iej.13000.
12. Arantes WB, da Silva CM, Lage-Marques JL, Habitante S, da Rosa LCL, de Medeiros JMF. SEM Analysis of Defects and Wear on Ni–Ti Rotary Instruments. Scanning. Jul-Aug 2014;36(4):411-8. doi: 10.1002/sca.21134.
13. Hanan AR, Meireles DA, Sponchiado Júnior EC, Hanan S, Kuga MC, Bonetti Filho I. Surface characteristics of reciprocating instruments before and after use—a SEM analysis. Braz Dent J. 2015 Mar-Apr;26(2):121-7. https://doi.org/10.1590/0103-6440201300208.
14. Pires MVMP. Avaliação do desempenho e alteração de superfície das limas Wave One e One Shape no decorrer do número de usos. [tese]. Universidade de São Paulo, 2014. doi: 10.11606/D.23.2015.tde-17062015-124846
15. FKG. Disponível em: <http://www.fkg.ch/>. Acesso em: 25/04/2021.
16. Caballero-Flores H, Nabeshima CK, Machado MEL. Fracture incidence of instruments from a single-file reciprocating system by students in an endodontic graduate programme: a cross-sectional retrospective study. Int Endod J. 2019 Jan;52(1):13-18. doi: 10.1111/iej.12982.
17. Keskin C, Inan U, Demiral M, Kele_□A. Cyclic Fatigue Resistance of Reciproc Blue, Reciproc, and WaveOne Gold Reciprocating Instruments. J Endod. 2017 Aug;43(8):1360-1363. doi: 10.1016/j.joen.2017.03.036.
18. Silva EJNL, Hecksher F, Antunes HDS, De-Deus G, Elias CN, Vieira VTL. Torsional Fatigue Resistance of Blue-treated Reciprocating Instruments. J Endod. 2018 Jun;44(6):1038-1041. doi: 10.1016/j.joen.2018.03.005.
19. Kabil E, Kati□M, Ani□I, Bago I. Micro-computed evaluation of canal transportation and centering ability of 5 rotary and reciprocating systems with different metallurgical properties and surface treatments in curved root canals. J Endod. 2021 Mar;47(3):477-484. doi: 10.1016/j.joen.2020.11.003.
20. Karamifar K, Samavi S, Saghiri MA. Topographic changes in NiTi rotary instruments after the clinical use. Aust Endod J. 2020 Dec;46(3):315-322. doi: 10.1111/aej.12427.
21. Pérez Morales MLN, González Sánchez JA, Olivieri JG, Elmsmari F, Salmon P, Jaramillo DE, Duran-Sindreu F. Micro-computed tomographic assessment and comparative study of the shaping ability in six NiTi files- an in vitro study. J Endod. 2021 Feb 4:S0099-2399(21)00070-4. doi: 10.1016/j.joen.2020.12.021.

ORAL MANIFESTATIONS AND CRANIOFACIAL CHARACTERISTICS OF HUTCHINSON-GILFORD PROGERIA SYNDROME: A CASE REPORT

Caroline Gomes **Bertoncelli**[1], Andréa Reis **Wendt**[1], Paulo Ricardo Gomes Fernandes dos **Santos**[1], Luciana Reichert da Silva **Assunção**[1], José Vitor Nogara Borges de **Menezes**[1], Fabian Calixto **Fraiz**[1*]

[1]Departament of Stomatology, Universidade Federal do Paraná, Curitiba, Paraná, Brazil.

Palavras-chave: Progéria. Síndrome de Hutchinson-Guilford. Manifestações Bucais. Criança. Relatos de Casos.

RESUMO

Introdução: A Progéria ou Síndrome de Hutchinson-Guilford (HGPS) é uma doença genética rara com um fenótipo característico de envelhecimento precoce em crianças pequenas, causado por uma mutação no gene LMNA e conseqüente acúmulo de progerina na célula. **Objetivo**: Descrever as manifestações orais da Síndrome de Hutchinson-Guilford. **Relato do Caso**: Este é um relato de caso de uma paciente de seis anos com Síndrome de Hutchinson-Guilford. O exame físico revelou atrofia da pele, lipodistrofia, rarefação dos cabelos, vasos sangüíneos proeminentes no couro cabeludo, desproporção craniofacial, cianose perioral e aumento das articulações dos joelhos. O exame intraoral revelou abertura bucal limitada, dentição mista com anatomia dentária normal e apinhamento ântero-inferior. A sequência e a cronologia de erupção estavam alteradas. O plano de tratamento incluiu profilaxia profissional, aplicação tópica de flúor, bem como orientação de higiene bucal e aconselhamento dietético. O acompanhamento do desenvolvimento da dentição e a intervenção odontológica precoce e oportuna colaboraram com a manutenção da saúde bucal da criança. **Conclusão**: Intervenções clínicas e educacionais precoces podem ajudar os pacientes com HGPS a manter um estado de saúde bucal adequado e melhorar sua qualidade de vida.

Keywords: Hutchinson–Gilford Progeria Syndrome. Progeria. Oral Manifestations. Child. Case Reports.

ABSTRACT

Introduction: Hutchinson-Guilford progeria syndrome (HGPS) is a rare genetic disease with a characteristic phenotype of premature aging in young children caused by a mutation in the LMNA gene and consequent accumulation of progerin in the cell. **Aim:** Describe oral manifestations of Hutchinson-Guilford progeria syndrome. **Case Report:** This is a case report of a six-year-old female patient with Hutchinson-Guilford Progeria syndrome. The physical examination revealed skin atrophy, lipodystrophy, hair rarefaction, prominent blood vessels of the scalp, craniofacial disproportion, perioral cyanosis and enlarged knee joints. The intraoral exam revealed limited mouth opening, mixed dentition with normal tooth anatomy and anteroinferior crowding. The eruption sequence and chronology were abnormal. The treatment plan included professional prophylaxis, the topical application of fluoride as well as both oral hygiene and dietary counselling. Monitoring the development of dentition and an early and timely dental intervention contributed to the maintenance of child's oral health**.** **Conclusion:** Early clinical and educational interventions can help patients with HGPS maintain adequate oral health status and improve their quality of life.

Submitted: May 18, 2020
Modification: July 26, 2021
Accepted: August 05, 2021

***Correspondence to:**
Fabian Calixto Fraiz
Departament of Stomatology
Universidade Federal do Paraná
Address: Avenida Lothário Meissner, 632.
Curitiba – PR, Brazil. Zip code: 80210-170
Telephone number: +55 (41) 3360-4021

INTRODUCTION

The first cases of Hutchinson-Guilford Progeria syndrome (HGPS; also known as progeria) were described by Jonathan Hutchinson in 1886 and independently by Hastings Guilford ten years later, giving rise to the name of the syndrome.[1,2] There are currently 30 progeroid syndromes described.[3] Classic HGPS (OMIM: #176670) is a rare sporadic autosomal dominant genetic disease[4-8] with a characteristic phenotype of premature aging in young children caused by a mutation in the LMNA gene and consequent accumulation of progerin in the cell.[6,7,9,10] The accumulation of this protein due to the repetition of cellular cycles causes toxicity, diminishing the life expectancy of the cell and causing premature tissue aging.[8]

According to a report from the Progeria Research Foundation published on March 31, 2019, 157 patients were diagnosed with this syndrome worldwide.[11] The mean life expectancy of affected individuals is 14 years of age and death generally occurs due to heart problems.[3,4]

Affected children are born with a stable health status and begin to present signs of the disease at about six to 12 months of age.[12,13]The most frequent manifestations are alopecia, hypotrichosis, lipodystrophy, exophthalmia, skin atrophy, thin nose, prominent blood vessels, stiff enlarged joints and short stature.[12,14,15] Mental development is not affected.[14] Few studies have offered a good description of the orofacial manifestations. The most common manifestations are: perioral cyanosis, craniofacial disproportion micrognathia, maxillary sinus atrophy, facial atrophy, delayed tooth eruption, tooth agenesis, dental malformations, dental crowding, narrow pulp chamber and frequent caries.[13,14]

Due to the low prevalence byof the syndrome, the Progeria Research Foundation has led an effort to unite all cases.[11] However, studies addressing oral problems in individuals with HGPS describe a considerable variety of characteristics, which hinders the identification of a pattern. Therefore, the aim of the present study was to contribute to the recognition of orofacial manifestations in this rare syndrome.

CASE REPORT

This case report describes oral manifestations in a six-year-old female patient with HGPS. The patient medical history revealed the parents were young at conception (mother: 21 years; father: 23 years) and the pregnancy occurred without complications. In the first year of the child's life, the occurrence of hair loss, prominent blood vessels on the scalp, low body weight and growth deficit led to the first suspicion of HGPS, which was confirmed when the child was two years of age through a genetic evaluation performed by the Progeria Research Foundation.[11] The patient was included in the foundation's study protocol of farnesyltransferase. At five years of age, the patient exhibited neuroatrophy of the knees, was sent for physical therapy and began taking imipramine (25 mg).

At six years and nine months of age, the patient began taking lonafarnib (SCH663366) (75 mg) provided by the foundation and exhibited skin atrophy, lipodystrophy, hair rarefaction, prominent blood vessels of the scalp, craniofacial disproportion, perioral cyanosis and enlarged knee joints. Electrocardiogram and echocardiogram results revealed normal findings. Concomitant to the use of lonafarnib, the patient made use of retinol with cholecalciferol and acetylsalicylic acid.

The patient began to visit the pediatric dental service of the *Universidade Federal do Paraná* in the city of Curitiba, Brazil, at the age of six years and nine months. At the time, the patient weighed 10.7 kg and was 98 centimeters in height (Figure 1A). Her diet was not considered cariogenic (little snacking between meals and low intake of sweets). She made regular use of a fluoridated toothpaste (1100 ppm F), but had difficulty using dental floss.

The intraoral exam revealed limited mouth opening, a mixed dentition with normal tooth anatomy and anteroinferior crowding (Figure 1B and 1C). The teeth were sound, but marginal gingivitis related to dental biofilm was found. The eruption sequence and chronology were not consistent with her age (six years); teeth 75 and 85 were still absent from the oral cavity. The panoramic radiograph revealed atrophy of the maxillary sinuses, small condyles, the formation of the germs of all permanent teeth, impacted teeth 75 and 85 and a lack of space for the proper eruption of teeth 31, 32 and 42 (Figure 1D).

The treatment plan included professional prophylaxis, the topical application of fluoride as well as both oral hygiene and dietary counselling. At the follow-up appointment when the child was eight years of age the mother reported that the use of dental floss was more frequent and an improvement in gingival health status was observed after oral hygiene counselling (Figure 2A and 2B). The panoramic radiograph showed an irregular root resorption pattern, although root development of the permanent successors was considered normal. The teeth 52, with delayed root resorption, and 54, with extensive resorption and considerable mobility, (Figure 2C) were extracted. The clinical examination revealed a developmental defect of enamel in teeth 11 (enamel hypoplasia) and 21 (demarcated opacity) (Figure 2A).

At nine years of age, the oral hygiene pattern had

worsened, with localized marginal gingivitis (Figure 3A). The other findings were the ectopic eruption of teeth 31 and 32 (Figure 3B), considerable mobility of teeth 63 and 64, the 24 erupting in vestibular direction (Figure 3C), and the presence of teeth 16 and 26 in the oral cavity. Non-cavitated caries were found on teeth 44 and 12 (Figure 3D). Panoramic radiography revealed an absence of space for proper eruption of all teeth (Figure 3E)

All teeth were normal in size, but with a lack of space for proper eruption. The cephalometric analysis revealed deficient jaw growth (SNA:78°; SNB:67°) with greater mandibular deficiency (ANB:11°). A tendency toward vertical growth (SNGoGN:54°) with a short face (AFAI:85 mm) was found (Table 1 and Figure 4).

***Table 1**: Cephalometric analysis of present case of Hutchinson-Guilford Progeria syndrome.*

SNA	78°
SNB	67°
ANB	11°
Co-A	110 mm
Co-Gn	118 mm
Mx-Md difference	8 mm
SNGoGN	54°
SNGN	65°
SNPo	35°
AFAI	85 mm
Naso-labial angle	112°

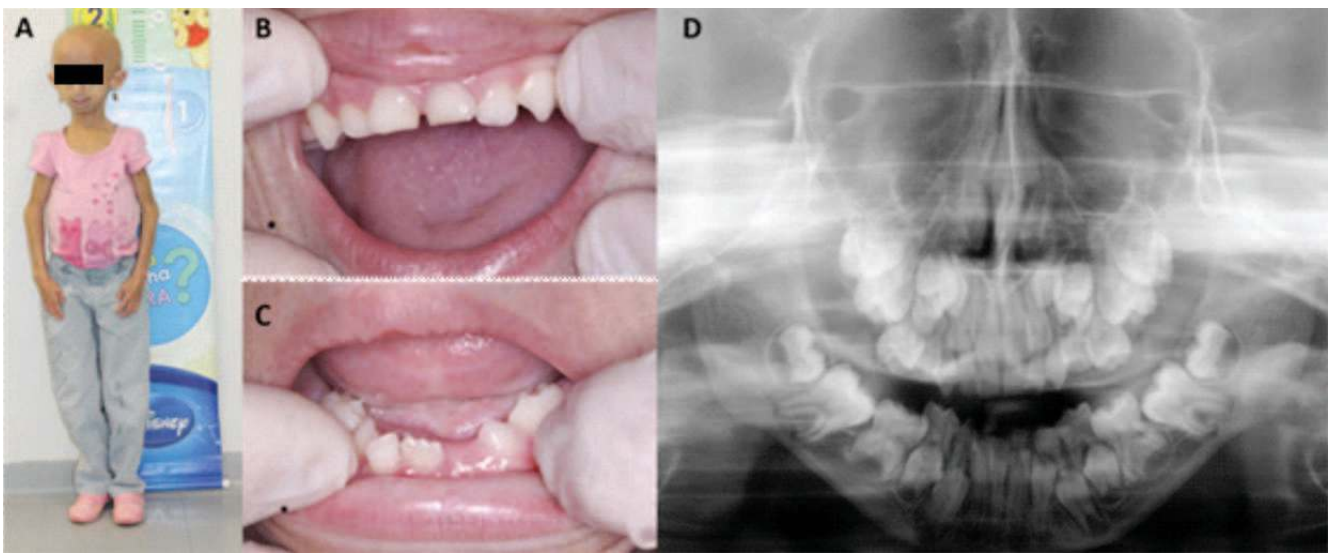

***Figure 1**: A) Aged clinical appearance and short stature at 6 years of age. B) Limited mouth opening. C) Dental crowding in anteroinferior region. D) Initial panoramic radiograph.*

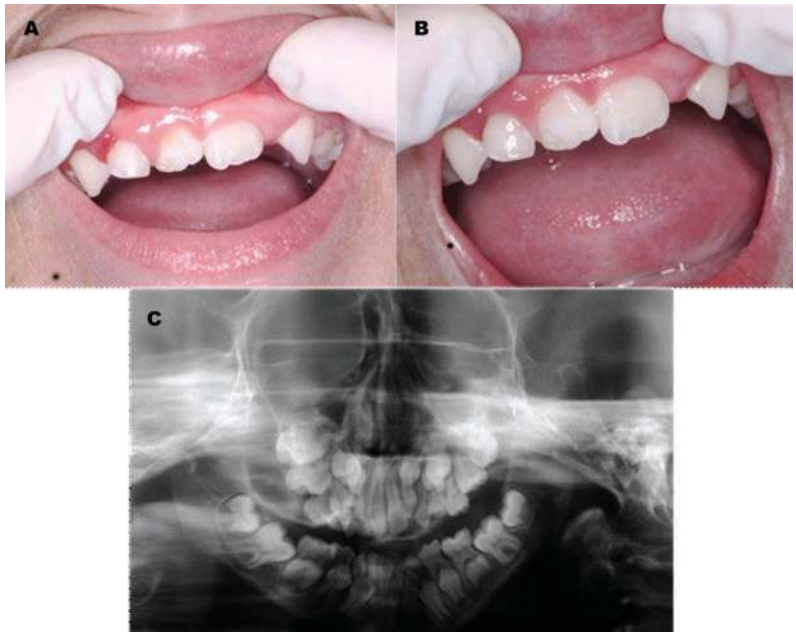

***Figure 2**: A) Intraoral examination at 8 years of age. B) Clinical evolution after oral hygiene counselling. C) New panoramic radiograph after 2 years, confirming presence of all germs of permanent successors.*

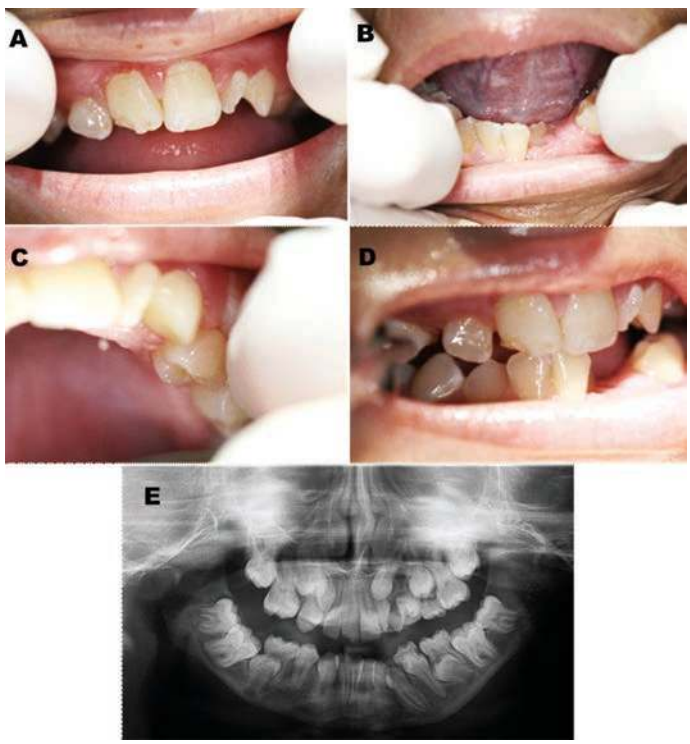

***Figure 3**. A) Marginal gingivitis on incisors. B) Absence of space for eruption of teeth 31 and 32. C) Tooth 24 erupting in vestibular direction. D) Active white spots on teeth 12 and 44. E) Absence of space for proper eruption of all teeth.*

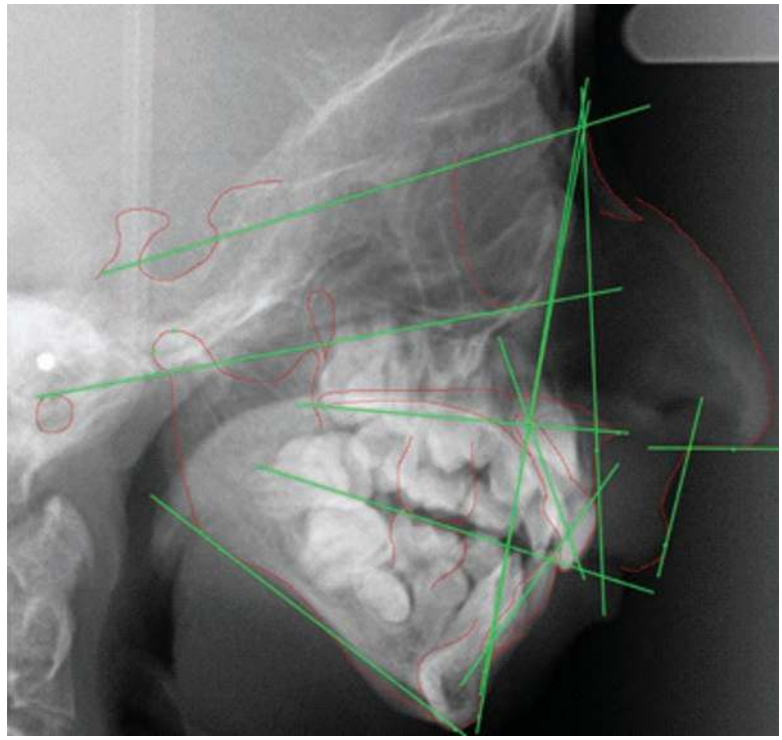

***Figure 4**: Cephalometric tracing indicating abnormally small vertical and sagittal dimensions.*

DISCUSSION

The considerable variation in oral findings associated with HGPS described in the literature is likely due to the low prevalence of this syndrome.[10,13,16] Moreover, the increase in life expectancy of affected individuals leads to new clinical situations determined by the lifecycle itself. The most relevant oral manifestations can be considered the result of incompatibility determined by deficient jaw growth and the normal morphological/anatomical development of the teeth.[17] This may lead to the need for extraction of some teeth.[18]

In the present case, the cephalometric analysis revealed micrognathia in both jaws, leading to a lack of space for the adequate eruption of the permanent teeth, which were normal in terms of both shape and size.

On the sagittal plane, the ANB angle was slightly increased (11°); the anterior height of the face (AFAI:85 mm) and the length of both the maxilla and mandible (Co-A:110 mm; Co-GN:118 mm) were abnormally small. As reported in other cases, a tendency toward vertical growth (SNGoGN: 54°) and an increase in the nasolabial angle (112°) due to deficient maxillary growth were also found.[19] Other authors also report discrepancies between normal tooth size in a face with atrophic growth.[17,20] In 2002, Batstone[18] reported a case in which the surgical removal of the permanent mandibular first molars and primary maxillary second molars was necessary due to recurring pericoronaritis.

According to Domingo,[20] hypodontia is another common condition in individuals with HGPS. The author reported a greater frequency of absent second premolars in comparison to the general population, which is in agreement with clinical findings of agenesis described in the literature.[10,17,19] Although hypodontia is a common condition in individuals with HGPS, especially the absence of second premolars,[10,17,19] this was not found in the present case.

Delays in the eruption chronology are also commonly reported in individuals with HGPS.[18,19] In the present case, the primary mandibular second molars had not yet erupted at six years of age, probably due to the mandibular growth deficiency.

The literature suggests that individuals with HGPS have a high incidence of dental caries and gingivitis.[13-17,19] In the present case, gingivitis was associated with a greater presence of biofilm and lower toothbrushing frequency at home. It was possible to maintain oral health throughout the entire follow-up period through simple preventive measures. This suggests that the increased prevalence of caries and gingivitis is more related to traditional etiological factors rather than oral characteristics inherent to the syndrome.

CONCLUSION

In conclusion, children with Hutchinson-Gilford Progeria Syndrome who receive preventive care and educational actions for the control of dental biofilm, access to fluoride and dietary control have the same chances of successfully avoiding the development of dental caries and gingivitis as children without this syndrome. However, dentists should be aware of the altered eruption pattern, dental crowding as well as the discrepancy between deficient orofacial development and normal tooth size and shape. These aspects may require an adequate, timely intervention to minimize the consequences of the lack of space in the oral cavity. Early clinical and educational interventions can help individuals with HGPS maintain an adequate oral health status, improving their quality of life.

REFERENCES

1. Hutchinson J. Congenital absence of hair and mammary glands with atrophic condition of the skin and its appendages. *Trans Med Chir Soc*. 1886;69:473-477.

2. Gilford H, Hutchinson J. On a Condition of Mixed Premature and Immature Development. *J R Soc Med*. 1896;MCT-80(1):17-45. Doi: 10.1177/095952879708000105.

3. Passarelli PC, Pasquantonio G, Manicone PF, et al. Orofacial signs and dental abnormalities in patients with Mulvihill-Smith syndrome. *Med (United States)*. 2018;97(18). doi: 10.1097/MD.0000000000010656.

4. Gordon LB, Shappell H, Massaro J, et al. Association of lonafarnib treatment vs no treatment with mortality rate in patients with Hutchinson-Gilford progeria syndrome. *JAMA - J Am Med Assoc*. 2018;319(16):1687-1695. doi: 10.1001/jama.2018.3264.

5. Kreienkamp R, Gonzalo S. Metabolic Dysfunction in Hutchinson-Gilford Progeria Syndrome. Cells. 2020 Feb 8;9(2):395. doi: 10.3390/cells9020395.

6. Ahmed MS, Ikram S, Bibi N, Mir A. Hutchinson–Gilford Progeria Syndrome: A Premature Aging Disease. Mol Neurobiol. 2018 May;55(5):4417-27. doi: 10.1007/s12035-017-0610-7.

7. QI YC, XIE XH. Hutchinson-Gilford Progeria Syndrome and its Relevance to Cardiovascular Diseases and Normal Aging. *Biomed Environ Sci*. 2013;26(5):382-389. doi: 10.3967/0895-3988.2013.05.007.

8. Hussain I, Patni N, Ueda M, et al. A novel generalized lipodystrophy-associated progeroid syndrome due to recurrent heterozygous LMNA p.T10I mutation. *J Clin Endocrinol Metab*. 2018;103(3):1005-1014. doi: 10.1210/jc.2017-02078.

9. Choi H, Kim TH, Jeong JK, Strandgren C, Eriksson M, Cho ES. Expression of the Hutchinson-Gilford Progeria Mutation Leads to Aberrant Dentin Formation. *Sci Rep*. 2018;8(1):15368. doi:.10.1038/s41598-018-33764-6.

10. Reichert C, Gölz L, Götz W, Wolf M, Deschner J, Jäger A, et al. Dental and craniofacial characteristics in a patient with Hutchinson–Gilford progeria syndrome. J Orofac Orthop. 2014 Jul;75(4):251-63. doi: 10.1007/s00056-014-0216-x.

11. Progeria Research Foudation [Internet]. Available from: https://www.progeriaresearch.org.

12. Hennekam RCM. Hutchinson-Gilford progeria syndrome: review of the phenotype *Am J Med Genet A*. 2006;140(23):2603-24. doi: 10.1002/ajmg.a.31346.

13. Nogueira AS, Nogueira CBP, Medeiros R, Beliláqua AC, Santos PSS, Rubira-Bullen IRF, et al. Hutchinson-Gilford Progeria Syndrome (HGPS): relevant aspects of a rare syndrome diagnosed in a Brazilian child. J Oral Diag. 2016;1(1):91-98. doi: 10.5935/2525-5711.20160009.

14. Alves DB, Silva JM, Menezes TO, Cavaleira RS, Tuji FM, Lopes MA, et al. Clinical and radiographic features of Hutchinson-Gilford progeria syndrome: A case report. World J Clin Cases. 2014 Mar 16;2(3):67-71. doi: 10.12998/wjcc.v2.i3.67.

15. Panigrahi RG, Panigrahi A, Vijayakumar P, Choudhury P, Bhuyan SK, Bhuyan R, et al. Hutchinson-Gilford Progeria Syndrome: A Rare Genetic Disorder. Case Rep Dent. 2013;2013:631378. doi: 10.1155/2013/631378.

16. Bassir SH, Chase I, Paster BJ, Gordon LB, Kleinman ME, Kieran MW, et al. Microbiome at sites of gingival recession in children with Hutchinson–Gilford progeria syndrome. J Periodontol. 2018 Jun;89(6):635-44. doi: 10.1002/JPER.17-0351.

17. Maloney WJ. Hutchinson-gilford progeria syndrome: Its presentation in F. Scott fitzgerald's short story' the curious case of benjamin button; And its oral manifestations. J Dent Res. 2009 Oct;88(10):873-876. doi: 10.1177/0022034509348765.

18. Batstone MD, Macleod AWG. Oral and maxillofacial surgical considerations for a case of Hutchinson-Gilford progeria. Int J Paediatr Dent. 2002 Nov;12(6):429-32. doi: 10.1046/j.1365-263x.2002.00401.x.

19. Hasty MF, Vann WF. Progeria in a pediatric dental patient: literature review and case report. Pediatr Dent. 1988 Dec;10(4):314-9.

20. Domingo DL, Trujillo MI, Council SE, et al. Hutchinson-Gilford progeria syndrome: Oral and craniofacial phenotypes. *Oral Dis*. 2009;15(3):187-195. doi: 10.1111/j.1601-0825.2009.01521.x.

REABILITAÇÃO ESTÉTICA E FUNCIONAL EM PACIENTE COM CÁRIE NA PRIMEIRA INFÂNCIA: RELATO DE CASO

Isabella Sichieri Germano **Alves**[1], Carla Oliveira **Favretto**[2], Liliana Carolina **Baéz-Quintero**[3], Laura Imbriani **Bento**[1], Natália Maria Castorino de **Oliveira**[3], Cristiane **Duque**[1], Marcelle **Danelon**[3*]

[1]Departamento de Odontologia, Universidade de Ribeirão Preto, Ribeirão Preto, São Paulo, Brasil.
[2]Departamento de Odontopediatria, Faculdade Morgana Potrich, Mineiros, Goiás, Brasil.
[3]Departamento de Odontologia Preventiva e Restauradora, Faculdade de Odontologia, Universidade Estadual Paulista, Araçatuba, SP, Brasil.

Palavras-chave: Cárie Dentária. Reabilitação Bucal. Odontopediatria.

RESUMO

Introdução: Cárie na Primeira Infância (CPI) é o termo utilizado para descrever a cárie dentária em crianças menores de 6 anos de idade. **Objetivo**: Relatar o tratamento reabilitador estético e funcional de uma criança com CPI. **Relato do caso**: Paciente do sexo masculino, 5 anos de idade, compareceu à clínica de Odontopediatria da Faculdade de Odontologia de Araçatuba (FOA/UNESP), acompanhado pela mãe, que relatou como queixa principal dor e presença de cárie. Ao exame clínico intrabucal, constatou-se na arcada superior lesões de cárie em todos os dentes, exceto nos dentes 55, já restaurado, e dente 65, hígido. Na arcada inferior, lesões de cárie foram observadas nos dentes 74 e 84. Após diagnóstico clínico e radiográfico, optou-se por realizar a confecção de coroa de aço para os dentes 74 e 84, exodontia dos dentes 51, 52, 61 e 64, instalação de aparelho mantenedor de espaço funcional removível e restaurações dos demais dentes afetados com compósito resinoso. **Conclusão**: Foi possível recuperar as funções estéticas, fonéticas e mastigatórias do paciente, colaborando para a melhora da autoestima da criança, o que gerou satisfação dos familiares. A educação em saúde bucal realizada com a criança e os responsáveis foi essencial para o sucesso do tratamento e a manutenção da saúde bucal.

Keywords: Dental Caries. Oral Rehabilitation. Pediatric Dentistry.

ABSTRACT

Introduction: Early Childhood Caries (ECC) is the term used to describe dental caries in children under 6 years of age. **Objective**: Report the aesthetic and functional rehabilitation treatment of a child with ECC. **Case report**: A 5-year-old male patient was attended at the to the Pediatric Dentistry Clinic of the Araçatuba Dental School (FOA/UNESP), accompanied by his mother, who reported pain and dental caries as the main complaint. On intraoral clinical examination, caries lesions were found in all upper teeth, except for tooth 55, already restored, and tooth 65, healthy. In the lower arch, caries lesions were observed in teeth 74 and 84. After clinical and radiographic diagnosis, it was decided for the manufacture of steel crown for teeth 74 and 84, extraction of teeth 51, 52, 61 and 64, installation of removable functional space maintenance device and restorations of the other affected teeth with composite resin. **Conclusion**: In view of the treatment performed, it was possible to recover the aesthetic, phonetic and masticatory functions, contributing to the improvement of the child's self-esteem as well as satisfaction of family members. Oral health education carried out with the child and his parents was essential for the success of the treatment and the maintenance of oral health.

Submitted: February 25, 2021
Modification: Juny 19, 2021
Accepted: July 05, 2021

***Correspondence to:**
Marcelle Danelon
Address: Rua José Bonifácio, 1193, Centro, Araçatuba – SP, Brazil.
Zip code 16015-050.
Telephone number: +55 (18) 3636-3235
E-mail: marcelledanelon@hotmail.com

INTRODUÇÃO

A cárie é uma doença crônica de caráter multifatorial. Fatores como a má higiene bucal, hábitos alimentares inadequados, alterações na composição da saliva e colonização microbiana influenciam o metabolismo das bactérias sobre os dentes, acelerando o processo de desmineralização da superfície dentária.[1] A cárie na primeira infância (CPI) é definida como a presença de uma ou mais superfícies cariadas (cavitada ou não cavitada), perdidas ou restauradas (devido à cárie) em qualquer dente decíduo de uma criança com menos de seis anos de idade, sendo considerada um problema de saúde pública.[2] Na evolução da doença e dos aspectos clínicos observam-se lesões de mancha branca próximas à margem gengival dos incisivos superiores, evoluindo para cavitação, posteriormente atingindo os molares superiores e inferiores decíduos.[3] Os incisivos superiores e molares superiores são os mais susceptíveis a lesões de cárie e os incisivos inferiores são menos susceptíveis devido à proteção salivar secretada pela glândula sublingual.[4]

O tratamento para a CPI dependerá do estágio das lesões, da idade e do comportamento da criança durante o tratamento odontológico, além da colaboração dos pais. Inicialmente, o tratamento é feito eliminando gradualmente os maus hábitos, como ingestão de líquidos e alimentos açucarados. Feito isto, lesões em estágio inicial receberão o tratamento conservador, utilizando a aplicação tópica de flúor, associado a uma higiene adequada com dentifrícios fluoretados. Em casos mais graves é feito o tratamento restaurador com cimento de ionômero de vidro, compósitos resinosos, coroas de resina, coroas de acetato e coroas de aço.[5] Em casos extremos é feito o tratamento endodôntico ou exodontia quando há destruição coronária extensa que impossibilite tratamentos restauradores.

A perda precoce dos dentes decíduos poderá acarretar problemas na mastigação, deglutição, fonética e estética, instalação de hábitos deletérios, como a interposição lingual ou posição inadequada da língua, perda de espaço, desequilíbrio oclusal e dificuldades na fala.[6] Nesses casos, pode ser feita a instalação de aparelhos mantenedores de espaço e próteses removíveis que têm como principal função manter espaços no arco dentário para a correta erupção dos dentes permanentes, prevenir ou corrigir hábitos deletérios, melhorar a função, fonação e o aspecto psicológico da criança e dos pais.[7] Além destes, as coroas de aço têm recebido grande destaque na preservação da estrutura dentária de molares decíduos.[8] O objetivo do presente estudo foi relatar o tratamento reabilitador estético e funcional de uma criança, com cárie na primeira infância, assim como orientar ao odontopediatra as múltiplas opções do tratamento reabilitador infantil.

RELATO DO CASO

Paciente do sexo masculino, 5 anos de idade, compareceu à clínica de Odontopediatria da Faculdade de Odontologia de Araçatuba (FOA/UNESP), acompanhado pela mãe, relatando dor na região dos dentes 51, 52, 61 e 64. Durante a anamnese, a mãe relatou que a criança fazia consumo de doces várias vezes ao dia, e que a higienização era precária, embora utilizasse dentifrício com 1100 ppm de flúor. Ainda, mencionou que a criança tinha dificuldade no relacionamento social com os colegas por apresentar dentes "estragados" (Figura 1A-F). Em relação à saúde geral, não foi relatada nenhuma alteração sistêmica. Diante da exposição dos fatos o profissional conversou com o paciente e a responsável, motivando-os quanto à importância de adotar medidas iniciais interceptativas para garantir o sucesso do tratamento. Ao exame clínico intrabucal e radiográfico observou-se extensa destruição coronária, além de lesão e reabsorção periapical, devido à presença de lesão cariosa nos dentes 51, 52, 61 e raiz residual do dente 64 (Figura 1A-H), além da ausência do dente 62. Verificou-se também lesões de mancha branca ativas nos dentes 71 e 81 e lesões cavitadas ativas nos dentes 53, 63, 72, 74, 82 e 84. Apenas os dentes 55 (já restaurado), 65 e 75 estavam livres de cárie (hígidos). Após diagnóstico clínico e radiográfico optou-se em realizar a confecção de coroa de aço para os dentes 74 e 84, exodontia dos dentes 51, 52, 61 e 64, instalação de aparelho mantenedor de espaço funcional removível na arcada superior, substituindo os dentes extraídos, e restaurações dos dentes afetados com compósito resinoso. O plano de tratamento proposto incluiu também aplicação tópica de flúor, motivação, medidas de instrução de higiene oral e dieta em todas as sessões. Essas sessões eram realizadas a cada sete dias.

Inicialmente procedeu-se com a restauração dos dentes 53 e 63. Para isto, após remoção de tecido cariado com curetas de dentina, foi feito isolamento relativo com rolete de algodão. A seguir, realizou-se condicionamento ácido (ácido fosfórico, 37%, Biodinâmica®) por 15 segundos (Figura 2A). Os dentes foram lavados e na sequência aplicou-se o sistema adesivo (Adper Single Bond 2, 3M®) (Figura 2B). Após fotopolimerização, iniciou-se a inserção do compósito resinoso (Resina Filtek Z350 XT, cor A2, 3M®) (Figura 2C). A Figura 2D mostra o aspecto clínico final dos dentes 53 e 63 após restauração. Para os demais dentes com lesões cavitadas (72 e 82) institui-se como tratamento restauração com cimento de ionômero de vidro, e para aqueles com lesões de mancha branca ativa (71 e 81) aplicação tópica de verniz fluoretado.

Para a exodontia dos dentes 51, 52, 61 e raiz residual

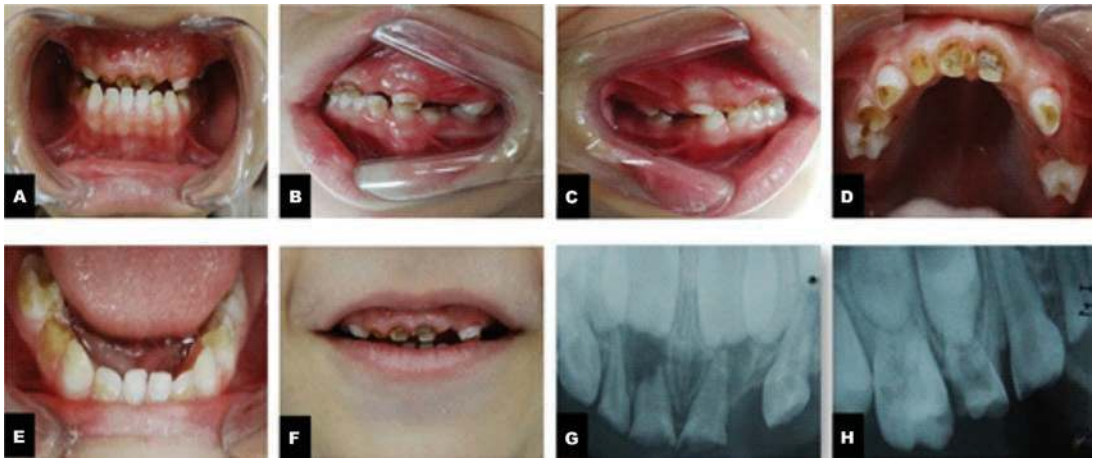

Figura 1: *A) Aspecto clínico inicial – vista frontal. B) Aspecto clínico inicial – vista lateral esquerda. C) Aspecto clínico inicial – vista lateral direita. D) Aspecto clínico inicial – vista oclusal superior. E) Aspecto clínico inicial – vista oclusal inferior. F) Aspecto clínico inicial – vista frontal-posição de repouso. G) Aspecto radiográfico inicial-região anterior superior. H) Aspecto radiográfico inicial-região posterior superior.*

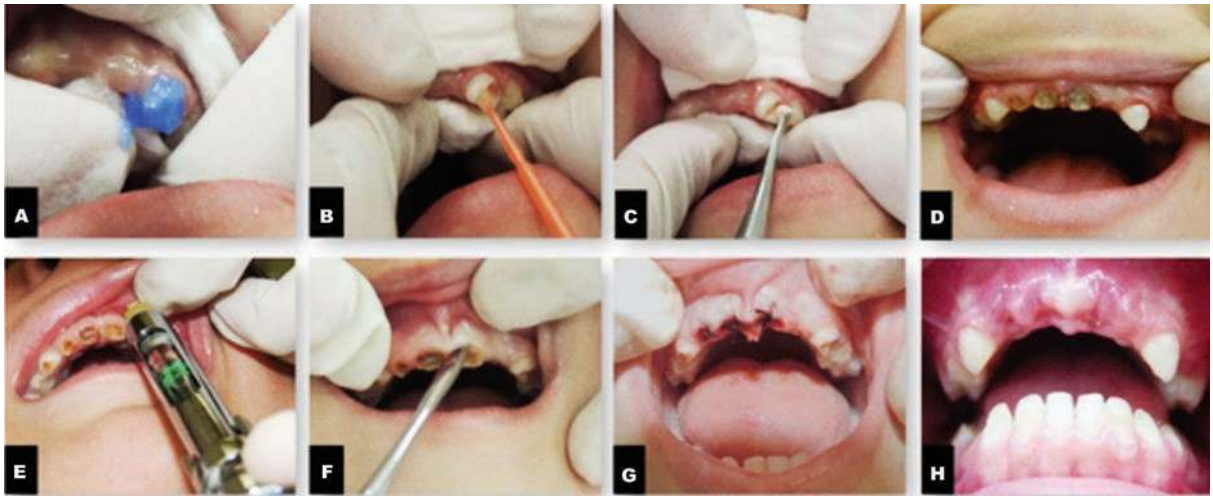

Figura 2: *A) Condicionamento ácido. B) Aplicação de sistema adesivo. C) Inserção de compósito resinoso. C) Aspecto clínico final após restauração dos dentes 53 e 63. D) Anestesia terminal infiltrativa (Mepivacaína a 3%). E) Sindesmotomia. F) Aspecto clínico final após sutura. G) Aspecto clínico final após 7 dias da exodontia.*

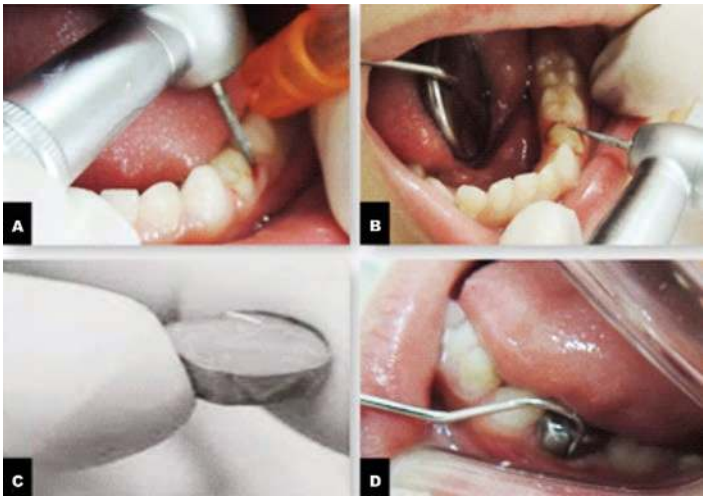

Figura 3: *(A e B) Preparo dentário para recebimento de cora de aço. C) Inserção de cimento de ionômero de vidro na coroa de aço. D) Cimentação e adaptação da coroa de aço.*



Figura 4: *A) Aspecto clínico final após restauração com compósito resinoso e coroas de aço-vista lateral direita. B) Aspecto clínico final após restauração com compósito resinoso e coroas de aço-vista lateral esquerda. C) Aspecto clínico final após restauração com compósito resinoso e coroas de aço-vista frontal. D) Aspecto clínico final – vista oclusal superior com mantenedor de espaço funcional removível. E) e F) Aspecto clínico final – vista frontal com mantenedor de espaço funcional removível.*

do dente 64, inicialmente realizou-se anestesia tópica com Benzotop® por 3 minutos, seguida de anestesia terminal infiltrativa dos nervos alveolar superior anterior e médio com Mepivacaína a 3% (Figura 2E). A seguir procedeu-se com a sindesmotomia utilizando hollemback 3s (Duflex®) (Figura 2F) e avulsão com fórceps infantil, seguida da sutura do alvéolo com fio de seda 4.0 (Figura 2G). Após 7 dias, paciente retornou à clínica para a remoção da sutura (Figura 2H).

Os dentes 74 e 84 foram preparados (Figura 3A-B) utilizando-se uma ponta diamantada cônica 3203 (KG Sorensen®), a qual promoveu uma redução oclusal, além de um desgaste proximal de aproximadamente 1mm, terminando abaixo da margem gengival, para evitar formação de degrau ou saliências próximos à gengiva, o que poderia dificultar a adaptação da coroa. Com o uso de um compasso de ponta seca, o tamanho da coroa de aço (3M®) a ser utilizada foi selecionado baseando-se no comprimento mesio-distal dos remanescentes dentários (74 e 84). Previamente a etapa de prova da coroa de aço, o paciente foi instruído a morder, verificando possíveis contatos em relação cêntrica. Após o preparo e ajuste na coroa de aço, foi colocado cimento de ionômero de vidro para cimentação (GC Fuji Plus C®) no interior da mesma, (Figura 3C). A coroa foi colocada sobre os dentes previamente preparados (Figura 4d), tomando-se o cuidado de remover os excessos após correta adaptação. A Figura 4A-F mostra o aspecto clínico final após reabilitação oral com compósito resinoso, mantenedor de espaço funcional removível (com dentes de estoque na região do 51, 52, 61 e 64) e coroas de aço. Após a reabilitação oral, a criança retornou mensalmente para avaliação do risco e atividade de cárie, acompanhamento dos procedimentos reabilitadores, bem como para instrução de higiene oral e dieta.

DISCUSSÃO

Considerando a idade do paciente (5 anos), o número de dentes afetados e a gravidade das lesões foi dado o diagnóstico de CPI. Entre as principais complicações e consequências desta patologia encontram-se alterações nas funções mastigatória, fonética e estética, no desenvolvimento dos maxilares, perda de espaço por exodontias prematuras e impacto negativo na qualidade de vida da criança.[2] Neste caso clínico, a fim de evitar estas complicações se instaurou um plano de tratamento que incluiu adequação do meio bucal (restaurações com compósito resinoso e exodontias) e reabilitação da função e da estética (coroas de aço e mantenedor de espaço funcional), tratamentos de eleição em crianças com CPI.[9-12]

Para o tratamento da CPI se podem realizar diferentes tipos de intervenção que dependerão da progressão da enfermidade e do comportamento da criança. Podem ser incluídas desde abordagens não invasivas, como o uso de diamino fluoreto de prata, verniz fluoretado e dentifrício fluoretado; até abordagens mais invasivas usando compósito resinoso, amálgama, cimento de ionômero de vidro ou coroas de aço. A longevidade desses materiais restauradores é variável; para as restaurações em amálgama pode ser de até 58%, compósitos resinosos 62% e cimento de ionômero de vidro convencionais de 33%.[13] Outra abordagem no tratamento da cárie dentária em crianças é o tratamento

restaurador atraumático, que está baseado na remoção de tecido cariado fazendo somente uso de instrumentos manuais, sendo o cimento de ionômero de vidro o material restaurador de preferência.[10] No presente caso clínico foi usada a abordagem preconizada pela Academia Americana de Odontopediatria,[2] na qual a remoção da cárie é realizada com instrumentos manuais e a restauração posterior com um material adesivo. Esta técnica é usada para o controle da cárie em crianças com múltiplas lesões de cárie.[14]

Os materiais mais comumente usados na restauração de lesões cariosas cavitadas são os compósitos resinosos e o cimento de ionômero de vidro (CIV); a escolha dependerá das necessidades do paciente, propriedades mecânicas e objetivo do tratamento. Neste caso, optou-se por usar compósito resinoso na reabilitação dos dentes 53 e 63 devido ao melhor polimento, lisura e estética favorável.[12]

Nos dentes 74 e 84 foram colocadas coroas de aço, tratamento que tem mostrado êxito em crianças com alto risco de cárie, uma vez que apresentam menor taxa de perda (5,4%) quando comparadas a dentes tratados com compósitos resinosos (21,4%).[8,15] As coroas de aço apresentam boa estabilidade e retenção e são indicadas para reabilitações de primeiros e segundos molares, e para crianças com lesões de cárie extensas e com alto risco de desenvolvimento de novas lesões.[8]

Para obter resultados favoráveis nos tratamentos realizados, as coroas de aço devem ter uma adequada adaptação marginal que permita preservar a saúde periodontal e uma oclusão funcional. No presente caso, as seleções das coroas de aço foram feitas previamente ao preparo dos dentes, sendo o espaço mésio-distal medido com compasso de ponta seca, com o intuito de delimitar com precisão o tamanho da coroa. A seguir, protegeu-se as regiões proximais dos dentes com tira de aço para que cuidadosamente fosse realizada a eliminação das áreas retentivas dos dentes e rebaixamento proximal e oclusal de 1,0 mm. Após procedeu-se com o recorte da porção cervical da cora para impedir a ocorrência de isquemia na área de recebimento da coroa. Durante todo o período que compreendeu desde o ajuste das coroas até a fase de cimentação, a criança apresentou-se com um comportamento bastante colaborador.

Na reabilitação dos dentes anteriores foi usado um mantedor de espaço funcional removível com a finalidade de devolver a estética e a autoestima da criança, além de ajudar a manter as funções fonética e mastigatória do paciente.[16] Outra opção de reabilitação na região anterior é a confecção de pinos intrarradiculares e a restauração coronária com compósito resinoso, no entanto precisa-se avaliar algumas condições clínicas para seu uso, como integridade da porção radicular, grau de rizólise do dente, rizogênese do sucessor permanente, presença de reabsorção patológica e lúmen do canal radicular.[17] Neste caso não foi possível colocar pinos intrarradiculares nos dentes 51, 52 e 61 uma vez que apresentavam lesões periapicais extensas impossibilitando o tratamento endodôntico, e pouca estrutura dentária remanescente na qual se pudesse aderir a posterior restauração. Após a exodontia dos dentes, a sutura foi realizada com o intuito de coaptar as bordas da ferida cirúrgica, uma vez que os dentes permanentes sucessores encontravam-se no estágio 6 de Nolla, sem formação radicular. Destaca-se que para o presente caso, o anestésico local de escolha foi a Mepivacaína, a qual possui propriedade vasodilatadora branda fornecendo uma duração mais longa da anestesia do que, a maioria dos outros anestésicos locais quando a droga é administrada sem vasoconstritor.[18]

O principal fator de risco para a CPI é a exposição a açúcares na dieta. Todavia, outros fatores como hábitos de higiene oral, estado de saúde, educação dos pais, entorno social, cultural e econômico, acesso a programas de fluoretação e serviços de atenção precisam ser avaliados.[19] Para controlar estes fatores, realiza-se a educação em saúde bucal com motivação aos pais e a criança a fim de evitar o surgimento de novas lesões de cárie, mudar hábitos de higiene oral, e favorecer o estabelecimento de uma dentição permanente saudável no futuro. A mudança dos hábitos de higiene oral e de alimentação deve ser o principal objetivo do tratamento da CPI, pois favorecerá não só a diminuição do risco de novas lesões, mas também a modificação do estilo de vida das famílias.

Entre as limitações do caso clínico está o uso de um mantenedor de espaço removível, pois sua eficácia na manutenção do espaço do primeiro pré-molar superior esquerdo dependerá do tempo de uso e aceitação da criança. Também ao incluir a região anterior é necessário monitorar a irrupção dos dentes permanentes para ajustá-lo gradativamente. Por ser considerado um paciente com alto risco de cárie, é importante monitorar os hábitos de higiene oral e realizar aplicação profissional de flúor periodicamente.

A prevenção e tratamento da CPI continua sendo um desafio para a Odontologia. Na literatura, são descritas várias técnicas e materiais restauradores que podem ser usados, no entanto sua escolha dependerá das condições clínicas de cada paciente. A descrição deste caso clínico refere-se ao tratamento de uma criança com diferentes estágios de desenvolvimento da doença e pode servir como guia para dentistas e/ou odontopediatras na reabilitação de casos semelhantes.

CONCLUSÃO

Concluiu-se que houve uma recuperação das funções estéticas, fonéticas e mastigatórias do paciente; colaborando para a melhora da autoestima da criança e gerando satisfação dos familiares. O trabalho de educação em saúde bucal com a criança e os responsáveis foi essencial para o sucesso do tratamento e a manutenção da saúde bucal.

REFERÊNCIAS

1. Veena RL, Nagarathna C. Correlation of streptococcus mutans and streptococcus sobrinus colonization with and without caries experience in preschool children. Indian J Dent Res. 2020 Feb;31(1):73-79. doi: 10.4103/ijdr.IJDR_432_18.

2. American Academy of Pediatric Dentistry. Policy on Early Childhood Caries (ECC): Classifications, Consequences, and Preventive Strategies. AAPD. 2019-2020;40(6):60-62.

3. Pitts NB, Baez RJ, Diaz-Guillory C, Donly KJ, Alberto Feldens C, McGrath C, et al. Early Childhood Caries: IAPD Bangkok Declaration. Int J Paediatr Dent. 2019 May 17;29(3):384 386. doi: 10.1111/ipd.12490.

4. Alazmah A. Early childhood caries: a review. J Contemp Dent Pract. 2017 Aug 1;18(8):732-737. doiI: 10.5005/jp-journals-10024-2116.

5. Pineda IC, Osorio SRG, Franzin LCS. Cárie precoce da primeira infância e reabilitação em odontopediatria. Rev Uningá Review. 2014 Jul-Set;19(3):51-55.

6. Kalia G, Tandon S, Bhupali NR, Rathore A, Marthur R, Rathore K. Speech evaluation in children with missing anterior teeth and after prosthetic rehabilitation with fixed functional space maintainer. J Indian Soc Pedod Prev Dent. 2018 Oct-Dec;36(4):391-395. doi: 10.4103/JISPPD.JISPPD_221_18.

7. Cui T, Xu Q, Wu Y, Yang X, Li T, Sun H. Longitudinal Follow-up Survey of Effects of Oral Comprehensive Healthcare Measures on Early Childhood Caries. Oral Health Prev Dent. 2020;18(2):197-203. doi: 10.3290/j.ohpd.a43347.

8. Seale NS, Randall R. The Use of Stainless-Steel Crowns: A Systematic Literature Review. Pediatr Dent. 2015 Mar-Apr;37(2):145-160.

9. Grund K, Goddon I, Schüler IM, Lehmann T, Heinrich W. Clinical consequences of untreated dental caries in German 5- and 8-year-olds. BMC Oral Health. 2015 Nov 4;15:140. doi: 10.1186/s12903-015-0121-8.

10. Seow WK. Early Childhood Caries. The Pediatric Clinics of North America. 2018 Oct;65(5):941-954. doi: 10.1016/j.pcl.2018.05.004.

11. Colak H, Dülgergil CT, Dalli M, Hamidi MM. Early childhood caries update: A review of causes, diagnoses, and treatments. J Nat Sci Biol Med. 2013 Jan;4(1):29-38. doi: 10.4103/0976-9668.107257.

12. Khare V, Nayak PA, Khandelwal V, Nayak UA. Fixed functional space maintainer: novel aesthetic approach for missing maxillary primary anterior teeth. BMJ Case Rep. 2013 Jun 3. doi: 10.1136/bcr-2013-009585.

13. Duangthip D, Chen KJ, Gao SS, Man LEC, Hung CC. Managing Early Childhood Caries with Atraumatic Restorative Treatment and Topical Silver and Fluoride Agents. Int J Environ Res Public Health. 2017 Oct 10;14(10):1204. doi: 10.3390/ijerph14101204.

14. Dorri M, Martinez-Zapata MJ, Walsh T, Marinho VCC, Sheiham A, Zaror C. Atraumatic restorative treatment versus conventional restorative treatment for managing dental caries. Cochrane Database of Systematic Reviews. 2017 Dec 28;12(12). doi: 10.1002/14651858.CD008072.pub2.

15. Gholman RR, Kassar WM, Meligy OAE. Dental Rehabilitation of a Child with Ectodermal Dysplasia: A Case Report. Int J Clin Pediatr Dent. 2019 Jul-Aug;12(4):362-365. doi: 10.5005/jp-journals-10005-1651.

16. Kalia G, Tandon S, Bhupali NR, Rathore A, Mathur R, Rathore K. Speech evaluation in children with missing anterior teeth and after prosthetic rehabilitation with fixed functional space maintainer. J Indian Soc Pedod Prev Dent. 2018 Oct-Dec;36(4):391-395. doi: 10.4103/JISPPD.JISPPD_221_18.

17. Verma L, Passi S. Glass fibre-reinforced composite post and core used in decayed primary anterior teeth: a case report. Case Rep Dent. 2011;2011:864254. doi: 10.1155/2011/864254.

18. Klingberg G, Ridell K, Brogårdh-Roth S, Vall M, Berlin H. Local analgesia in paediatric dentistry: a systematic review of techniques and pharmacologic agents. Eur Arch Paediatr Dent. 2017 Oct;18(5):323:329. Epub 2017 Sep 14. doi: 10.1007/s40368-017-0302-z.

19. Phantumvanit P, Makino Y, Ogawa H, Rugg-Gunn A, Moynihan P, Petersen PE, et al. WHO Global Consultation on Public Health Intervention against Early Childhood Caries. Community Dent Oral Epidemiol. 2018 Jun;46(3):280-287. doi: 10.1111/cdoe.12362.

DENTAL RADIOGRAPHIC ANATOMY ANALYSIS FOR IDENTIFICATION OF A CARBONIZED BODY: CASE REPORT

Millena Gonçalves de Souza **Gomes**[1*], Vanessa Moreira **Andrade**[2], Annie Seabra de **Medeiros**[2], Andreia Cristina Breda de **Souza**[2,3], Maria Augusta **Visconti**[1]

[1]Department of Oral Pathology and Diagnosis, Dental School of the Universidade Federal do Rio de Janeiro, Rio de Janeiro, Rio de Janeiro, Brazil.
[2]Forensic Odontology Service, Instituto de Medicina Legal Afrânio Peixoto, Rio de Janeiro, Rio de janeiro, Brazil.
[3]Department of Social and Preventive Dentistry, Dental School of the Universidade Federal do Rio de Janeiro, Rio de Janeiro, Rio de Janeiro, Brazil.

Palavras-chave: Identificação de Vítimas. Odontologia Legal. Cadáver. Radiografia.

RESUMO

Introdução: Os exames de imagem odontológicos fornecem um importante auxílio para os odontolegistas em casos de identificação cadavérica. Porém, em alguns casos, tal auxílio se torna essencial, como nos casos em que todas as coroas dentárias se encontram hígidas e quando ocorre perda da estrutura coronária, podendo ser devido à ação térmica. **Objetivo**: Relatar um caso em que odontolegistas identificaram um cadáver através de comparações radiográficas. **Relato do caso**: Em 2018, um cadáver carbonizado no interior de um veículo incinerado foi encaminhado para exame visando sua identificação. A análise comparativa utilizou diferentes tipos de exames bidimensionais: uma radiografia panorâmica *antemortem* e radiografias periapicais *postmortem*. Houve total concordância da anatomia dentária radiográfica, destacando-se a angulação das raízes, morfologia dos condutos radiculares, regiões de furca, ápices radiculares, forma das câmaras pulpares e regiões do trabeculado alveolar relativos a ambas as arcadas, além de uma cavidade localizada na face oclusal do primeiro molar inferior direito. **Conclusão**: A compatibilidade da anatomia dentária observada através das radiografias foi primordial para um resultado positivo do processo de identificação odontológica.

Keywords: Victims Identification. Forensic Dentistry. Cadaver. Radiography.

ABSTRACT

Introduction: Dentistry imaging is responsible for providing paramount support for forensic odontologists in cases of cadaveric identification. Nevertheless, in some cases, this assistance becomes essential, as in cases in which all the crowns have proven to be in perfect health standards, and when the dentist is able to identify loss of crown structural integrity, which can occur due to intense thermal action. **Objective**: To report a case in which forensic odontologists identified a cadaver through radiographic comparisons. **Case report**: In 2018, a carbonized bodyfound inside an incinerated vehicle was referred to an examination aiming its identification. The comparative analysis used different types of bidimensional images: *antemortem* panoramic radiograph and *postmortem* periapical radiographs. There was a total agreement of the dental radiographic anatomy, with emphasis on the root angulation, morphology of root canals, furcation regions, root apexes, the shape of pulp chambers and regions of alveolar trabecular related to both arches, as well as a cavity located in the occlusal surface of the lower right first molar. **Conclusion**: The compatibility of dental anatomy analyzed through the radiographs was fundamental for a positive result of the dentistry identification process.

Submitted: March 12, 2020
Modification: July 18, 2021
Accepted: July 30, 2021

***Correspondence to:**
Millena Gonçalves de Souza Gomes
Address: Rua Coronel Eurico de Souza Gomes Filho, número 515, apartamento 301. Rio de Janeiro – Rio de Janeiro, Brazil. Zip Code: 22620-320
Telephone number: +55 (21) 9 8788-0191.
E-mail: sgomesmillena@gmail.com

INTRODUCTION

One of the objectives of forensic dentistry is the determination of human identity through the comparison and compatibility of *antemortem* (AM) and *postmortem* (PM)[1-4] records, by utilizing all documentation present in the patient dental documentation, including examinations related to dental treatments.[5] Therefore, dental identification is based on verifying the particularities of dental nature between the dental records relating to examination and/or treatments conducted whilst the patient was alive, and those particularities observed in the cadaver.[6-11]

In accordance with the INTERPOL guide for Disaster Victim Identification[12], dental analysis is considered a primary method of identification, being a reliable method to confirm the identity, together with friction ridge analysis and DNA analysis. The analysis of the dental arches by the forensic dentists fills the biological demands for an identification method to be considered valid (individuality, perpetuation and immutability), as well as the technical demands (practicability and classifiable).[13]

The *postmortem* radiographical exam was introduced into the forensic dentistry routine in 1898[14], ever since studies have been conducted showing and reiterating the importance of forensic dentists conducting intraoral radiographs. These must cover all dental support locations, including the edentulous areas, to achieve knowledge on unerupted teeth, extracted roots and anatomical structures.[5,6,9-11,16-19]

The specific techniques to be applied in each individual case will depend crucially on the quality and types of *antemortem* radiographs available to the forensic dentists.[15,16]

The objective of the present article was to report a case of human identification, beginning with the confrontation of the dental characteristics observed in an *antemortem* panoramic radiograph and those verified in *postmortem* periapical radiographs, laying the foundation of the essential aspects that involve the process of dental identification, as well as, highlighting its advantages and limitations.

CASE REPORT

In August 2018, a carbonized corpse was found inside an incinerated vehicle, the body was then referred to the Legal Medical Institute Afrânio Peixoto in Rio de Janeiro – Brazil so that its cause of death could be determined, and a human identification examination could be conducted. On external examination, despite the severe carbonization, it was possible to state that the deceased was an adult male. Due to the intense carbonization, it was not possible to determine the cause of death with the necroscopic exam identifying that the upper and lower airways did not present any sign of soot.

The family members of a missing adult male went to the Forensic Dentistry Sector of the Legal Medical Institution, bringing the *antemortem* dental documentation, seeking a comparative analysis with the aforementioned corpse (Figure 1). The *antemortem* documentation was composed by panoramic radiography and five digitalized photos, both dated February 2017, being three intraoral photos (smiling, right lateral and left lateral - all conducted with teeth in occlusion) and two extraoral photos (smiling with teeth in occlusion and right lateral profile with pursed lips). The *antemortem* dental documentation also contained a declaration from the dentist hired by the man, dated August 2018, informing the beginning of the orthodontic treatment in February 2017, with the installation of a fixed orthodontic appliance in both arches, a dental cleaning and made the mentioned photos. In addition, the declaration also reported the patient return in April 2017 for installation of orthodontic bands, and after this date, the dentist had no more contact with the patient.

When analyzing the dental records provided by the family, it was possible to identify in the panoramic radiograph (Figure 2) the clinical situations described in Table 1 and the root configuration of the teeth that presented healthy roots in Table 2.

The team of forensic dentists on duty conducted ten periapical radiographs of the corpse using parallelism technique with positioners with a conventional device of periapical radiography. The jaws were placed on the sector's bench protected with a plastic film. Five images were of the maxilla (Figure 3) and five of the mandible (Figure 4), then overlaps and comparisons were made with the PowerPoint program between the *antemortem* panoramic radiograph and the *postmortem* periapical radiographs.

The clinical situations present in Table 3 were possible to be observed in the *postmortem* periapical radiographs.

Regarding the anatomical dental and alveolar characteristics, it was noted a total and complete agreement between the *antemortem* and *postmortem* images, highlighting the location, contour, and extension of the cavity on the occlusal face of tooth 46 (Figure 5), the root angulation, root canal morphology, furcation regions and root apexes (Figure 6), the shape of pulp chambers (Figure 7), and regions of alveolar trabecular (Figure 8) related to both arches.

Given the above, specific correspondences were verified between all the characteristics in the cadaveric examination with those obtained from the *antemortem* documentation, furthermore, no incompatibility or inconsistency was verified when the data was confronted. The results of this investigation allowed the dentists to conclude the identification as positive.

According to the American Board of Forensic Odontology guidelines,[20] the results of this investigation allowed the dentists to conclude the identification as positive, in other words, the *antemortem* and *postmortem* data match in sufficient detail to establish that they are from the same individual, with no unexplained discrepancy.

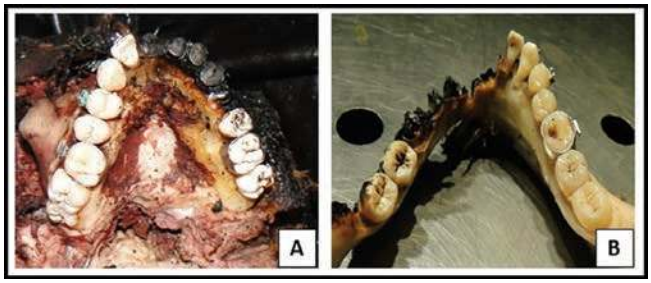

***Figure 1**: Top view photographs of the charred corpse. A) Maxilla; B) Mandible.*



***Figure 2**:* Antemortem *panoramic radiograph provided by the family.*

***Table 1**: Dental configuration extracted from* antemortem *panoramic radiography of upper and lower teeth.*

Upper teeth	Note	Lower teeth	Note
18	Infraocclusion	38	H
17	H	37	H
16	H	36	H
15	H	35	H
14	H	34	H + BR
13	H	33	H + BR
12	H	32	H + BR
11	Caries (IM)	31	H + BR
21	MR (IM)	41	H
22	H	42	H + BR
23	H	43	H + BR
24	H	44	H + BR
25	H	45	H
26	H	46	Caries (O)
27	H	47	H
28	Infraocclusion	48	H

Note: H: Healthy; BR: Orthodontic bracket; MR: Mimetic restoration; IM: Incisal mesium; O:Occlusal.

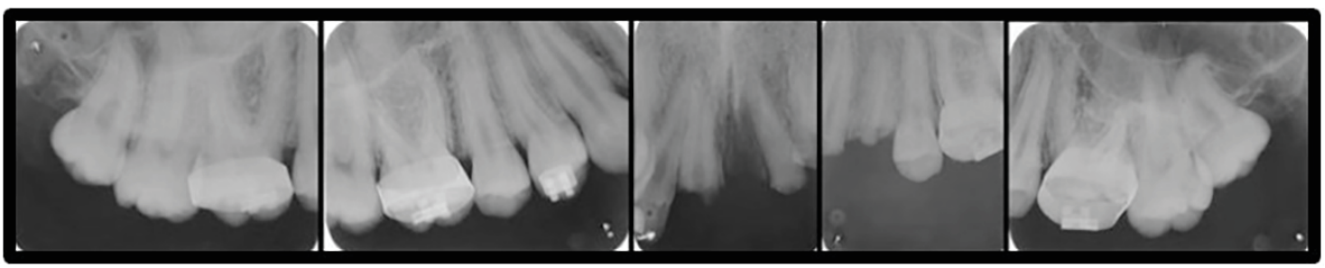

***Figure 3**: Postmortem periapical radiographs of the maxilla.*

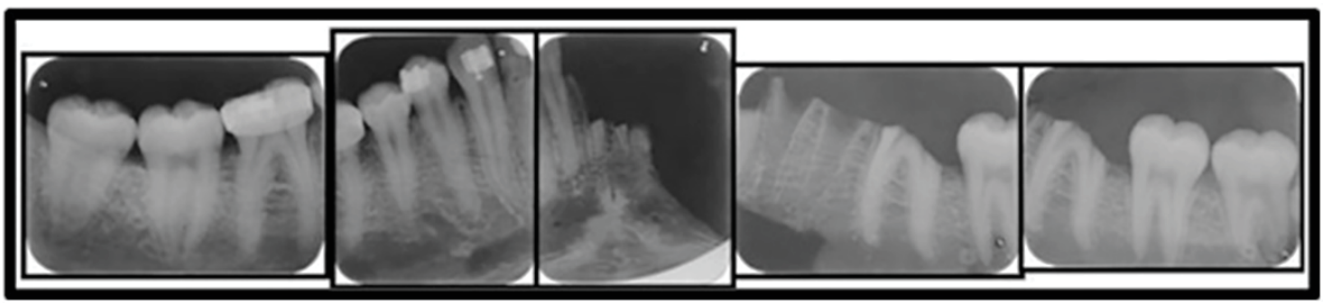

Figure 4: *Postmortem periapical radiographs of the mandible*

***Table 2**: Root configuration of teeth with intact roots.*

Tooth	Root configuration
18	Fusion roots and distal tilt
17	Pulp narrowing and parallel and straight roots
16	Pulp narrowing and converging roots
14	Distal curvatures in the cervical third of its roots
12	Mesial curvatures in the middle and apical third of its roots
11	Distal curvatures of the apical thirds of its roots
21	Distal curvatures of the apical thirds of its roots
22	Mesial curvatures in the middle and apical third of its roots
24	Distal curvatures in the cervical third of its roots
26	Pulp narrowing and divergent roots
27	Pulp narrowing and parallel and straight roots
28	Fusion roots with distal inclination and root laceration
38	Converging roots and open apical end
37	Wide Pulp chamber and parallel and straight roots with pulp narrowing, mesial pulp horn higher than the distal
36	Relatively parallel roots, with apex slightly curved to distal
45	Mesial curvatures in the middle third of its roots
46	Pulp narrowing and relatively parallel roots
47	Wide Pulp chamber and converging roots
48	Fusion roots and exposed apical end

***Table 3**: Odontogram filled out from* postmortem *periapical radiographs.*

Upper teeth	Note	Lower teeth	Note
18	H	38	H
17	H	37	H
16	H + B + BR	36	TAF
15	H	35	PMA
14	H + BR	34	PMA
13	H	33	TAF
12	H	32	BSM
11	TAF	31	RR
21	TAF	41	RR
22	TAF	42	H + BR
23	TAF	43	H + BR
24	TAF	44	H + BR
25	H	45	H
26	H + B + BR	46	H + B + BR
27	H	47	H
28	H	48	H

Note: H: Healthy; B: Orthodontic band; BR: Orthodontic bracket; TAF: Thermal action fracture; PMA: postmortem *avulsion; BSM: Bone segment missing due to thermal action; RR: Root remnant due to thermal action.*

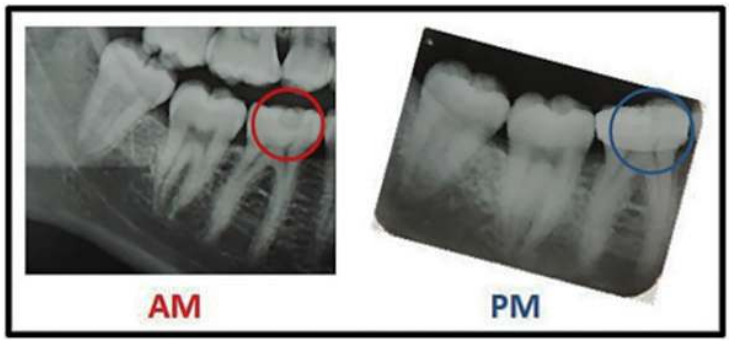

***Figure 5**: Comparison of the shape of the cavity in the tooth crown 46. AM: antemortem; PM: post mortem.*

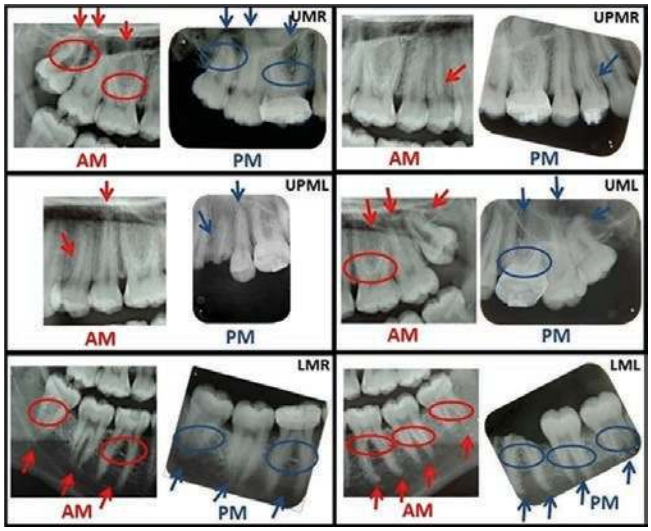

***Figure 6**: Comparison of the angulation of the roots, root canal, furcation regions and root apexes. UMR: região molar superior do lado direito; AM: antemortem; PM: post mortem; UPMR: região pré-molar superior do lado direito; UPML: região pré-molar superior do lado esquerdo; UML: região molar superior do lado esquerdo; LMR: região molar inferior do lado direito; LML: região molar inferior do lado esquerdo.*

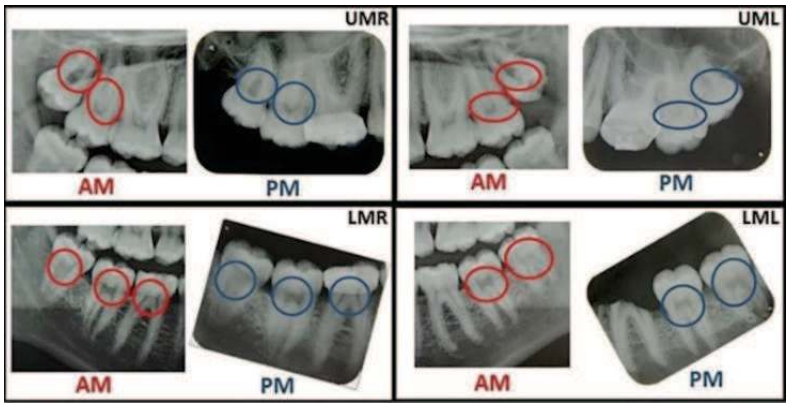

***Figure 7**: Comparison of the shape of the pulp chambers. UMR: região molar superior do lado direito; AM: antemortem; PM: post mortem; UML: região molar superior do lado esquerdo; LMR: região molar inferior do lado direito; LML: região molar inferior do lado esquerdo.*

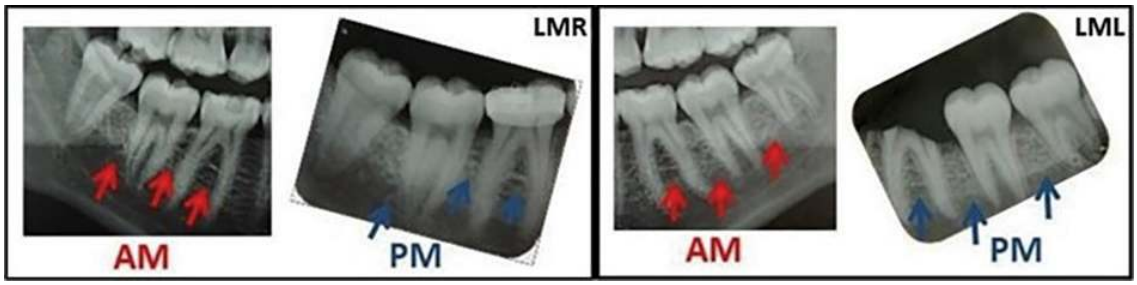

***Figure 8**: Comparison of regions of the alveolar trabeculate. AM: antemortem; PM: post mortem; LMR: região molar inferior do lado direito; LML: região molar inferior do lado esquerdo.*

DISCUSSION

The carbonization condition of the corpse prevented the use of the most employed primary method of identification, the dactyloscopy or friction ridge analysis, due to dehydration on the regions of the digital, being impossible its analysis. With this, in carbonized cadavers the dental analysis is the preferred method of identification, having seen the teeth and restorative materials resistance in relation to the termal act.[4,5,17,19]

Combination of morphological, pathological, and therapeutic dental characteristics is employed to distinguish individuals, where the cumulative effects of these particularities, when positive, increases the practical importance for the result of identification.[6,14,18,21,22]

The comparison of the aforementioned dental characteristics, when recorded in written form in *antemortem* documents, might contain errors and a lack of details,[12] while comparing them based on *antemortem* radiographs provides objective and reliable data. Thus, as in this case report, several studies have cited positive comparisons between *antemortem* and *postmortem* dental radiographs, either by comparing the images in parallel or by overlapping.[4,5,7-9,11,15,17,19,21,22]

According to Scoralick *et al.*[19], considering the reality of forensic activity in Brazil, the comparison between radiographs is beneficial, as it is a low-cost and effective method.

In the present report, the comparative analysis was based on radiographic exams with distinct characteristics and objectives, with panoramic radiography being the source of *antemortem* information that allowed the adequate extraction of data of the forensic dentistry confrontation.

Characteristics such as tooth positioning, root, pulp and crown shape are unique for each individual,[19] and it is notorious that dental roots preserve morphological information for longer periods when compared to crowns,[11,16] highlighting the importance of radicular radiographic analysis for cases of cadaveric dental identification.

Attributable to the high temperature to which the cadaver was exposed, it resulted in the loss of teeth, either due to fracture at the cervical level, reduction to the root remnant, *postmortem* avulsion, or absence of a bone segment with the specific tooth, making human identification extremely difficult. However, the analysis of the root angulation and root apices of the teeth present, as well as the analysis of the bone trabeculate and the furcation region of the molars were indispensable to the establishment of the identification once the incinerated corpse did not possess all its intact teeth in the arch on account of the carbonization.

In addition to the thermal action, which can hinder dental identification due to loss of tooth structure, another challenge for forensic dentists is the expansion and popularization of prophylactic dental treatments, responsible for significantly diminishing the incidence of caries, making the process of dental identification burdensome,[21,23] as there is a consequent reduction in the need for restorative interventions. Therefore, dental identification is more laborious and must be done through morphological identifiers as was done in the present case report, being different from that presented in other articles[5,7,11,17-19] which compared *antemortem* and *postmortem* dental interventions. The difficulty in the identification process was highlighted by Forrest[16] who cited that in the absence of restorations or evidence of other dental treatment, anatomical features, including dental morphology, sinuses, and bone morphology, can be used, nevertheless, the level of work demanded is increased as it becomes a more straining process.[16]

Another point that can be highlighted is the fact that the *antemortem* documentation dated February 2017 and the cadaveric exam was performed in August 2018, having a time gap of more than a year. However, the compared characteristics for identification as the root angulation, morphology of root canals and shape of pulp chambers do not change as time went on. In a different manner, in the analysis of restorative treatments, a time gap can difficult

the identification process, due to the new dental treatments that could be conducted in this time interval.

In the present case, the predominance of healthy teeth and the quality and compatibility of the anatomical aspects present on the radiographs led the experts to the conclusion of identification as positive. As a limitation, it was not possible to compare the mandibular canal and maxillary sinus anatomy due to periapical radiographs do not cover these regions.

CONCLUSION

In summary, this report demonstrated that aspects of the dental and alveolar root anatomical structure observed through *postmortem* radiographs were essential for the dental identification process, allowing an objective comparison with *antemortem* radiographs. In addition, different types of *antemortem* and *postmortem* dental images can be used for cadaveric identification through radiographic comparison.

Acknowledgments

The authors would like to thank the director of the Legal Medical Institute Afrânio Peixoto for allowing the disclosure of this case.

REFERENCES

1. Brown KA. Procedures for the collection of dental records for person identification. J Forensic Odontostomatol. 2007; 25(2):63-4.

2. Chiam SL, Page M, Higgins D, Taylor J. Validity of forensic odontology identification by comparison of conventional dental radiographs: a scoping review. Science & Justice. 2019;59: 93-101. doi: 10.1016/j.scijus.2018.08.008.

3. Manica S. A new website to aid the interpretation of antemortem dental records: www.internationaldentalcharts.org. J Forensic Odontostomatol. 2014; 32(2):1-7.

4. Musse JO, Marques JAM, Vilas Boas CDF, Sousa SRV, Oliveira RN. Importância pericial das radiografias panorâmicas e da análise odontológica para identificação humana: relato de caso. Rev Odontol UNESP. 2011;40(2): 108-111.

5. Caputo IGC, Reis JN, Silveira TCP, Guimarães MA, Silva RHA. Identification of a charred corpse through dental records. RSBO. 2011;8(3):345-51.

6. Angelakopoulos N, Franco A, Willems G, Fieuws S, Thevissen P. Clinically Detectable Dental Identifiers Observed in Intra-oral Photographs and Extra-oral Radiographs, Validated for Human Identification Purposes. J Forensic Sci. 2017;62(4):900-6. doi: 10.1111/1556-4029.13310.

7. Blakaj F, Bicaj T, Bicaj B. Dental Identification of a Decomposed Body. Med Arh. 2010;64(2):125-6.

8. Blau S, Hill A, Briggs CA, Cordner SM. Missing Persons-Missing Data: The Need to Collect Antemortem Dental Records of Missing Persons. J Forensic Sci. 2006;51(2):286-9. doi: 10.1111/j.1556-4029.2006.00051.x.

9. Campobasso CP, Dell'Erba AS, Belviso M, Di Vella G. Craniofacial Identification by Comparison of Antemortem and Postmortem Radiographs Two Case Reports Dealing with Burnt Bodies. Am J Forensic Med Pathol. 2007;28(2):182-6. doi: 10.1097/PAF.0b013e31806195cb.

10. Chen H, Jain AK. Dental Biometrics: Alignment and Matching of Dental Radiographs. IEEE Trans Pattern Anal Mach Intell. 2005;27(8):1319-26.

11. Silva RF, Franco A, Mendes SDSC, Picole FF, Nunes FG, Estrela C. Identifying murder victims with endodontic radiographs. J Forensic Dent Sci. 2016;8(3):167-70. doi:10.4103/0975-1475.195112

12. INTERPOL [Internet]. Disaster Victim Identification Guide [version 2018]. Available from: https://www.interpol.int/How-we-work/Forensics/Disaster-Victim-Identification-DVI

13. Vanrell, JP. Odontologia Legal e Antropologia Forense. 3ª ed. Editora Guanabra Koogan S.A. 2019.

14. Manigandan T, Sumathy C, Elumalai M, Sathasivasubramanian S, Kannan A. Forensic radiology in dentistry. J Pharm Bioallied Sci. 2015;7(1):S260-4. Doi: 10.4103/0975-7406.155944.

15. Emiliano GBG, Marinho FS, Oliveira RN. Potential contribution of periapical radiographic film image processing for forensic identification. RGO. 2016;64(4):484-9. doi: 10.1590/1981-86372016000300000193215.

16. Forrest AS. Collection and recording of radiological information for forensic purposes. Aust Dent J. 2012;57(1):24-32. doi: 10.1111/j.1834-7819.2011. 01658.x.

17. Hinchliffe J. Forensic odontology, part 1. Dental identification. Br Dent J. 2011;210(5):219-24. doi: 10.1038/sj.bdj.2011.146.

18. Nicopoulou-Karayianni K, Mitsea AG, Horner K. Dental Diagnostic Radiology in the Forensic Sciences: Two Case Presentations. J Forensic Odontostomatol. 2007;25(1):12-6.

19. Scoralick RA, Barbieri AA, Moraes ZM, Júnior LF, Júnior ED, Naressi CM. Identificação humana por meio do estudo de imagens radiográficas odontológicas: relato de caso. Rev Odontol UNESP. 2013;42(1):67-71.

20. American Board of Forensic Odontology (ABFO) [Internet]. Body Identification Information & Guidelines [revised 2017]. Available from: http://abfo.org/wp-content/uploads/2012/08/ABFO-Body-ID-Information-Guidelines-Feb-2017.pdf

21. Carvalho SPM, Silva RHA, Lopes-Junior C, Peres AS. A utilização de imagens na identificação humana em odontologia legal. Radiol Bras. 2009;42(2):125-30. doi: 10.1590/S0100-39842009000200012.

22. Johansen RJ, Bowers M. Positive Dental Identification Using Tooth Anatomy and Digital Superimposition. J Forensic Sci. 2013;58(2):534-6. doi: 10.1111/1556-4029.12040.

23. Gruber J, Kameyama MM. O papel da radiologia em odontologia legal. Pesqui Odontol Bras. 2001;15(3): 263-8.

ALAGILLE SYNDROME: FACIAL CHARACTERISTICS, RARE ORAL MANIFESTATIONS, AND MANAGEMENT OF THE CASE

Camila **Nassur**[1], Adílis **Alexandria**[1,2*], Sabrina Loren de Almeida **Salazar**[1], Luciana **Pomarico**[1], Gloria Fernanda Barbosa de Araújo **Castro**[1]

[1] Department of Pediatric Denstry and Orthodontics, Universidade Federal do Rio de Janeiro, Rio de Janeiro, Rio de Janeiro, Brazil.
[2] Department of Preventive and Community Dentistry, Universidade do Estado do Rio de Janeiro, Rio de Janeiro, Rio de Janeiro, Brazil.

Palavras-chave: Síndrome de Alagille. Hiperplasia Gengival. Fibroma Ossificante Periférico.

RESUMO

Introdução: A síndrome de Alagille (AGS) é uma doença autossômica dominante com expressividade variável que podem afetar o fígado, coração, rins, vasos sanguíneos, olhos, rosto e esqueleto. **Objetivo**: Descrever um caso de um paciente pediátrico com síndrome de Alagille. **Relato do caso**: A história familiar era negativa até mesmo para as manifestações mais leves de AGS. Clinicamente, o paciente apresentava face triangular, hipertelorismo, filtro curto e face média plana. O exame intraoral revelou ausência dos incisivos laterais superiores permanentes, hipoplasia de esmalte e aspecto esverdeado em alguns dentes, hiperplasia gengival, retenção de dois incisivos inferiores decíduos, presença de um dente supranumerário, e um nódulo de tecido mole pediculado na face lingual do primeiro molar inferior permanente esquerdo. **Resultados**: O tratamento odontológico exigiu a extração dos dentes decíduos retidos e do dente supranumerário, biópsia excisional e exame histopatológico da lesão além da aplicação de fluoreto tópico. Também foi realizada instrução dietética e de higiene oral. **Conclusão**: Atualmente, o paciente faz visitas de acompanhamento frequentes para monitorar o desenvolvimento dentário.

Keywords: Alagille Syndrome. Gingival Fibromatosis. Ossifying Fibroma.

ABSTRACT

Introduction: Alagille syndrome (AGS) is an autosomal dominant disease with variable expressiveness that can affect the liver, heart, kidneys, blood vessels, eyes, face and skeleton. **Objective**: To describe a case of a pediatric patient with Alagille syndrome. **Case report**: The family history was negative for even the mildest manifestations of AGS. Clinically, the patient had a triangular face, hypertelorism, short philtrum and flat midface. Intraoral examination revealed the absence of the permanent upper lateral incisors, enamel hypoplasia and a greenish color in some teeth, gingival hyperplasia, retention of two primary lower incisors, presence of a supernumerary tooth, and a pediculated nodule of soft tissue on the lingual aspect of the left permanent mandibular first molar. **Results**: The dental treatment required the extraction of the retained primary teeth and the supernumerary tooth, excisional biopsy and histopathological examination of the lesion were performed and also application of topical fluoride. Also dietary and oral hygiene instructions were given. **Conclusion**: Currently, the patient makes frequent follow-up visits to monitor the dental development.

Submitted: February 23, 2020
Modification: July 26, 2021
Accepted: August 05, 2021

***Correspondence to**:
Adílis Kalina Alexandria
Address: Departamento de Odontologia Preventiva e Comunitária, Faculdade de Odontologia, 2º andar, Pavilhão Mario Franco Barroso, Universidade do Estado do Rio de Janeiro. Rio de Janeiro - RJ, Brazil.
E-mail: adilis.alexandria@gmail.com.br

INTRODUCTION

Alagille Syndrome (AGS), also known as arteriohepatic dysplasia, is an autosomal dominant developmental disorder.[1] AGS was first reported by Alagille *et al.*[2] and is characterized by paucity of intrahepatic bile ducts, in association with five main clinical abnormalities: low birth weight, growth retardation, vertebral anomalies, cardiovascular and hepatic complications.[1,3,4]

The severity of the disorder can vary within the same family, with symptoms ranging from so mild that they go unnoticed to severe heart and/or liver disease requiring transplantation. The symptoms are usually observed in the first 2 years of life. Some patients can die before the age of five due to the cardiovascular and hepatic complications.[3,4]

Facial and oral findings are important considerations in the management and planning of dental treatment for patients with AGS. The aim of this article is to present a case of Alagille Syndrome in a pediatric patient, describing the facial and rare dental abnormalities.

CASE REPORT

A 13-year-old female, leucoderma, and diagnosed with the Alagille Syndrome was referred by her pediatric doctor to the Pediatric Dentistry Department of a public university in Rio de Janeiro, Brazil, for a dental appointment.

The medical history revealed that she was jaundiced at birth and 4 months after she underwent laparotomy, intraoperative cholangiogram and a liver biopsy. The result of the biopsy revealed paucity of the interlobular bile ducts. An echocardiogram also showed the presence of peripheral pulmonary artery stenosis. The patient also presented hepatosplenomegaly but without ascites and edema. Further evaluation demonstrated pulmonary artery stenosis, bilateral posterior embryotoxon, and vertebral abnormalities. A diagnosis of AGS was made. The family history was negative for even the mildest manifestations of AGS. When she was 5 years old, she underwent an orthotopic liver transplantation. She has been placed on cyclosporine, prednisolone and multivitamins.

Extraoral examination revealed a triangular face, consisting of a prominent forehead, deep-set eyes, hypertelorism, long, straight nose with flattened tip, short philtrum, flat midface and a triangular chin (Figure 1A).

Intraoral examination revealed the absence of the permanent upper lateral incisors, presence of enamel hypoplasia and a greenish color in some teeth, with the stain varying in degree and extension. The teeth showed a thin line of green pigmentation in the cervical third (Figure 1B and 1C). Gingival hyperplasia was also observed at the anterior teeth. Further examination revealed a localized pedunculated nodule (2 x 1,5 cm) on the lingual aspect of the left permanent mandibular first molar (Figure 1C). Good oral hygiene was reported, no caries were found, but an anterior cross bite was observed. Other oral manifestations such as prolonged retention of two primary lower incisors and the presence of one supernumerary tooth in the same region were also observed.

The radiography examination confirmed the agenesis of the upper lateral incisors, presence of the retained primary incisors and the supernumerary tooth (Figure 2).

The proposed treatment included the extraction of the retained primary teeth and the supernumerary tooth, as well as a fluoride application (varnish) on the teeth with hypoplasia. Also dietary and oral hygiene instructions were given to the parents. Excisional biopsy and histopathological examination of the lesion were performed. The differential diagnosis was established with pyogenic granuloma, traumatic fibroma, and peripheral giant cell granuloma. The family was informed about the likely benign nature of the lesion. Histopathological analysis revealed a peripheral ossifying fibroma. Follow-up visits were scheduled to allow the continuous monitoring of dental development. The patient was referred for orthodontic treatment.



***Figure 1**: A) Extraoral clinical photograph: triangular face, prominent forehead, deep-set eyes, hypertelorism, long, straight nose with flattened tip, short philtrum, flat midface and a triangular chin; B) Intrabucal clinical photograph: Gingival enlargements firm, pale red, and resilient, with a lobulated surface and C) Intrabucal clinical photograph: Pedunculated nodule on the lingual aspect of the left permanent mandibular first molar.*

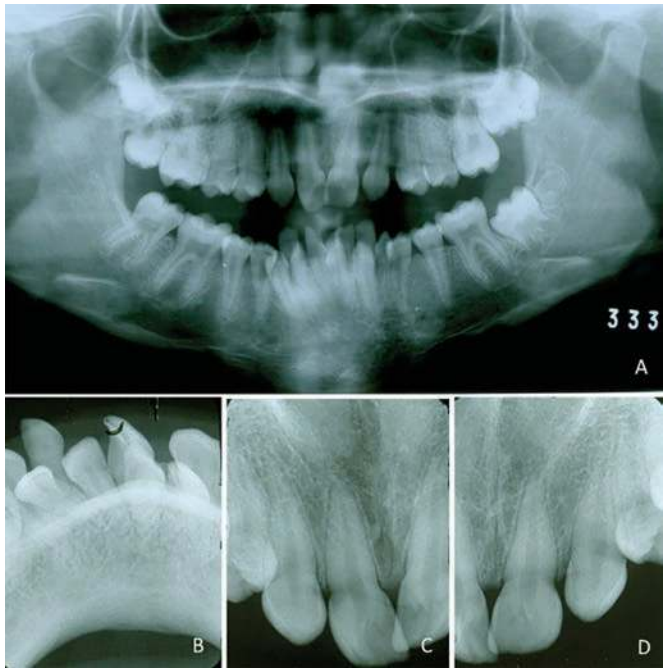

***Figure 2**: A) Panoramic radiograph, B) Periapical radiographs showing presence of retained primary incisors and a supernumerary tooth, and periapical radiographs confirmed the agenesis of the upper right C) and left D) lateral incisors.*

DISCUSSION

Alagille Syndrome is inherited in an autosomal dominant manner and genetic studies have revealed that mutations in the Jagged 1 (JAG1) gene, encoding a ligand for the Notch receptor, are responsible for this syndrome.[1,5]

Subjects commonly present chronic cholestasis, cardiac, skeletal abnormalities, ocular abnormalities, and characteristic facial features[3]. Patients with AGS present the characteristic facial features that include a prominent forehead, hypertelorism with deep-set eyes, pointed chin, or a straight nose with a bulbous tip.[4,5] These findings coincide with our case report. Also, the oral findings reported teeth with a grayish intrinsic discoloration with focal areas of white and yellow patches and enamel hypoplasia, gingival inflammation, talon cusps, oral xanthomas and severe hypodontia.[4-7]

The presence of the prolonged retention of primary incisors, a supernumerary tooth and absence of the permanent upper lateral incisors had not been previously described in the literature in AGS patients. Ho *et al*.[8] reported the case of a three-year-old patient with severe hypodontia in primary dentition. Chatterjee and Mason[6] report alterations in teeth form, but no number abnormality. Clinical problems associated with prolonged retention of deciduous teeth have also included the possibility of malocclusion, a shift in the normal midline of the patient's dentition, difficulty in maintaining dental hygiene and crowding.

The intrinsic pigmentation and enamel hypoplasia presented in this case are probably associated to hyperbilirubinemia, which must have occurred during enamel and dentin formation, resulting in dental pigmentation, due to accumulation of intrinsic staining by bilirubin oxidation.[9] The diagnosis of bilirubin pigmentation is usually based on a clinical history of jaundice combined with green tooth discoloration and less often enamel hypoplasia.[7]

Patients who have undergone organ transplant surgery are at increased risk for serious infection and require lifelong immunosuppressive therapy.[10,11] The side effects of these drugs include an increased susceptibility to infections.[11] Organ transplant recipients may be taking one or more medications that affect dental treatment. It is very important that dentists are aware of the side effects of these medications, which range from xerostomia and gingival hyperplasia to orthostatic hypotension and hyperglycemia. Cyclosporine A has been the primary tool used to prevent rejection of organ transplants and its clinical use is often complicated due to adverse effects including nephrotoxicity, hepatotoxicity, neurotoxicity, hypertension and gingival overgrowth.[12,13] The gingival fibrous hyperplasia associated with cyclosporine A therapy are described in this case, the patient took the cyclosporine for 9 years.

Some immunosuppressive agents can interact with other commonly prescribed drugs, so, the decision to premedicate for invasive dental procedures and selection of the appropriate regimen should be made upon in

consultation with the patient's physician.[11] In this case, according to her doctor, it was necessary to use medicine before the dental procedures.

It is important to make a basic therapeutic approach to reduce the risk for recurrence of gingival overgrowth; it is essential to improve oral hygiene and the execution of procedures to control periodontal disease. If the patient uses drugs that induce the gingival growth, it is important to evaluate the possibility of replacing them with other medications.[11] In more critical cases, surgical removal must be performed to reestablish the anatomy and physiology of the gingival tissue with better control of the dental biofilm.

Peripheral ossifying fibroma (POF) is a lesion of the gingival tissues[14] representing up to 2% of all oral lesions that are biopsied.[15] Garcia *et al*. (2013)[15] underline the non-neoplastic nature of the POF. It is a condition of the inflammatory reaction associated with mineralization and derived from the periodontal ligament cells. The etiology and pathogenesis of POF remains unknown, but it has been observed in conditions associated with known genetic mutations, such as the nevoid basal cell carcinoma syndrome, multiple endocrine neoplasia type II, neurofibromatosis and the Gardner syndrome.[16]

The lesions of POF are most often found in the gingival, located anteriorly to the molars and on the maxilla.[17] In this study, the lesion was exophytic and pedunculated and was located beside the molars on the mandible. There is an association between Alagille Syndrome and multiple central giant cell granulomas of the mandible.[1,3-5] However, there is no evidence to support the association between Alagille Syndrome and FOP.

CONCLUSION

This case describes an uncommon oral manifestation and some important aspects concerning diagnosis and avoidance of complications associated with AGS. The diagnosis can be difficult in a family without AGS classical features, being a challenge to clinical treatment decisions. Confirming the need for the dentist to keep a specific approach to patients suffering from systemic diseases. Early professional advice and treatment, as well as periodical follow-ups, can improve the quality of the lives of these patients.

REFERENCES

1. Turnpenny PD, Ellard S. Alagille syndrome: pathogenesis, diagnosis and management. Eur J Hum Genet. 2012; 20: 251-257. doi: 10.1038/ejhg.2011.181.

2. Alagille D, Odièvre M, Gautier M, Dommergues JP. Hepatic ductular hypoplasia associated with characteristic facies, vertebral malformations, retarded physical, mental, and sexual development, and cardiac murmur. J Pediatr. 1975; 86:63-71. doi: 10.1016/s0022-3476(75)80706-2.

3. Rapp JB, Bellah RD, Maya C, Pawel BR, Anupindi SA. Giant hepatic regenerative nodules in Alagille syndrome. Pediatr Radiol. 2017; 47(2):197-204. doi: 10.1007/s00247-016-3728-2.

4. Jesina D. Alagille Syndrome: An Overview. Neonatal Netw. 2017; 36(6):343-347. doi: 10.1891/0730-0832.36.6.343. doi: 10.1891/0730-0832.36.6.343.

5. Benabed Y, Chaillou E, Denis MC, Simard G, Reynier P, Homedan C. Alagille syndrome: a case report. Ann Biol Clin. 2018; 76(6):675-680. doi: 10.1684/abc.2018.1399.

6. Chatterjee M, Mason C. Talon Cusps Presenting in a Child with Alagille's Syndrome – A Case Report. J Clin Pediatr Dent. 2007; 32: 61-64. doi: 10.17796/jcpd.32.1.c041035j626wj573.

7. Lamba G, Nagpal DI, Korishettar R. Green Pigmentation of Teeth Caused by Neonatal Cholestatic Jaundice and Sepsis: A Case Report. Int J Clin Pediatr Dent. 2019;12(6):566-568. doi: 10.5005/jp-journals-10005-1696.

8. Ho NC, Lacbawan F, Francomano CA, Ho V. Severe hypodontia and oral xanthomas in Alagille syndrome. Am J Med Genet.2000; 93:250-2. doi: 10.1002/1096-8628(20000731)93:3<250::aid-ajmg18>3.0.co;2-a.

9. Rakauskaite A, Juodzbalys G, Pauza DH, Cicciù M. Green pigmentation in human teeth. A stereomicroscopic study. J Clin Pediatr Dent. 2014; 38(4):355-61. doi: 10.17796/jcpd.38.4.057t211602x447j8.

10. Helenius-Hietala J, Meurman JH, Höckerstedt K, Lindqvist C, Isoniemi H. Effect of the aetiology and severity of liver disease on oral health and dental treatment prior to transplantation. Transpl Int. 2012; 25(2):158-65. doi: 10.1111/j.1432-2277.2011.01381.x.

11. Hogan J, Pietrement C, Sellier-Leclerc AL, Louillet F, Salomon R, Macher MA, Berard E, Couchoud C. Infection-related hospitalizations after kidney transplantation in children: incidence, risk factors, and cost. Pediatr Nephrol. 2017; 32(12):2331-41. doi: 10.1007/s00467-017-3737-x.

12. Gandhi M, Rai E, Shirley A, Suda NK. Massive gingival bleed: a rare manifestation of cyclosporine toxicity. BMJ Case Rep. 2020; 13(12):e236828. doi: 10.1136/bcr-2020-236828.

13. Paul LC. Overview of side effects of immunosuppressive therapy. Transplant Proc. 2001; 33: 2089-2091. doi: 10.1016/s0041-1345(01)01959-5.

14. Carrera GI, Berini AL, Escoda CG. Clinicopathological features of peripheral ossifying fibroma in a series of 41 patients. Br J Oral Maxillofac Surg. 2019; 57(10):1081-1085. doi: 10.1016/j.bjoms.2019.09.020.

15. Garcia BG, Caldeira PC, Johann ACBJ, de Sousa SCOM, Caliari MV, Carmo MAV, et al. Cellular proliferation markers in peripheral and central fibromas: a comparative study. J Appl Oral Sci. 2013; 21:106-111. doi: 10.1590/1678-7757201302116

16. de Marcos JG, Rodriguez SA, Rodrigo JC, Poblet E. Peripheral

ossifying fibroma: a clinical and immunohistochemical study of four cases. J Oral Sci. 2010; 52: 95-99. doi: 10.2334/josnusd.52.95.

17. Lázare H, Peteiro A, Pérez Sayáns M, Gándara-Vila P, Caneiro J, García-García A, Antón I, Gándara-Rey JM, Suárez-Peñaranda JM. Clinicopathological features of peripheral ossifying fibroma in a series of 41 patients. Br J Oral Maxillofac Surg. 2019;57(10):1081-85. doi: 10.1016/j.bjoms.2019.09.020.

REPLANTATION OF AVULSED TOOTH: A STEP-BY-STEP REPORT

Michelle Jenné **Allegretto**[1], Larissa Soares Lima da **Silva**[1], Jéssica Muniz **Loureiro**[1], Lucas Alves **Jural**[2], Marcela Baraúna **Magno**[1,3], Patricia de Andrade **Risso**[3], Lucianne Cople **Maia**[1*]

[1]Department of Pediatric Dentistry and Orthodontics, School of Dentistry, Universidade Federal do Rio de Janeiro, Rio de Janeiro, Brazil.
[2]Ungraduated student, School of Dentistry, Universidade Federal do Rio de Janeiro, Rio de Janeiro, Brazil.
[3] Department of Dental Clinic, School of Dentistry, Universidade Federal do Rio de Janeiro, Rio de Janeiro, Brazil

Palavras-chave: Avulsão Dentária. Injuria Dental. Relatos de Caso.

RESUMO

Introdução: A avulsão é uma injuria grave que causa sérios danos aos tecidos de suporte do doente e é caracterizada pelo completo deslocamento do elemento dentário de dentro do alvéolo. O reimplante é, na maioria das situações, o tratamento de escolha para o dente permanente avulsionado e uma conduta correta é necessária para um bom prognostico nestes casos. Estudos prévios mostram que o conhecimento de dentistas sobre o manejo de um dente que sofreu avulsão é deficiente e destacam a importância da educação continuada, com a intenção de aumentar o nível de conhecimento de dentistas clínicos frente a urgências envolvendo dentes avulsionados. **Objetivo**: este relato tem como objetivo apresentar uma sequência clínica passo-a-passo envolvendo o reimplante de um dente permanente maduro que sofreu avulsão, seguindo o guia CARE. **Relato do caso**: O dente 21, armazenado em leite, foi reimplantado 2 horas após a avulsão e estabilizado com contenção flexível. As etapas clínicas foram realizadas conforme as recomendações da Associação Internacional de Traumatismos Dentários. O tratamento endodôntico foi iniciado cinco dias após o reimplante, com trocas periódicas de medicação intracanal. Atualmente o paciente encontra-se em acompanhamento, sem sinais ou sintomas negativos relacionados a avulsão. **Conclusão**: O reimplante dental após avulsão deve ser realizado após minucioso diagnóstico e condições de armazenamento do dente, com protocolo clínico embasado nas evidências científicas das associações de traumatismos dentoalveolares.

Keywords: Tooth avulsion. Tooth Injuries. Case Reports.

ABSTRACT

Introduction: Avulsion is a serious injury that causes damage to dental and supportive tissues, and is characterized by complete displacement of a tooth from its socket. In most situations, replantation is the treatment of choice for permanent tooth avulsion, and appropriate management is critical for a good prognosis in these cases. Previous studies have shown that the level of knowledge of dentists regarding the management of an avulsed tooth is deficient and have underscored the importance of continuing dental education to further the knowledge of general dentists in the urgency management of permanent avulsed teeth. **Objective**: This report aims to present a step-by-step clinical sequence involving the reimplantation of a mature permanent tooth that suffered avulsion, following the CARE guide. **Case report**: Tooth 21, stored in milk, was reimplanted 2 hours after avulsion and stabilized with flexible containment. The clinical steps were carried out according to the recommendations of the International Association of Dental Traumatology. Endodontic treatment was started five days after reimplantation, with periodic changes of intracanal medication. The patient is currently under follow-up, with no negative signs or symptoms related to avulsion. **Conclusion**: Dental reimplantation after avulsion should be performed after a thorough systemic and oral diagnosis and tooth storage conditions, with a clinical protocol based on scientific evidence of associations of dentoalveolar trauma.

Submitted: July, 2020
Modification: August 19, 2021
Accepted: February 4, 2021

***Correspondence to:**
Dr. Lucianne Cople Maia
Address: Rua Rodolpho Paulo Rocco, 325 - Cidade Universitária, Rio de Janeiro - RJ, Brazil - CEP: 21941-913.
Telephone/Fax: +55 21 3938-2098
E-mail: rorefa@terra.com.br

INTRODUCTION

Traumatic dental injuries in primary and permanent dentitions commonly occur in children and adolescents,[1] and can range from a simple concussion to substantial damage involving structures surrounding the tooth.[2,3] Avulsion can be defined as the complete detachment of the tooth from its socket, and is the most complicated and serious type of all permanent dental injuries. Its prevalence can range from 0.7% to 31.9%, with the highest incidence occurring in the maxillary central incisor.[4,5]

In most situations, replantation is the treatment of choice for the avulsion of a permanent tooth. The immediate and most appropriate management of an avulsed tooth occurs at the accident site, together with other first-aid procedures, and the dentist's knowledge regarding tooth replantation is critical for a good prognosis in these cases. Any and every attempt must be made to preserve a tooth, whether rhizogenesis is incomplete or complete.[2] The prognosis of permanent teeth with incomplete rhizogenesis is more or less favorable depending on how well the pulp can be repaired, and on continued root development. However, in regard to the replantation of teeth with complete rhizogenesis, even in the case of those with a less favorable late prognosis, the fundamental concern is to maintain the needed contour, width and height of the alveolar bone, and to restore the function and aesthetics of the tooth, even should the procedures represent but a temporary solution in anticipation of a more definitive future treatment.[2]

Many studies have shown that there is an urgent need to improve the knowledge of both general dentists and dental professions in general for treating urgency cases of tooth avulsion and overall traumatic dental injuries.[8,9] Bearing this in mind, the present study aims to give step-by-step directions for replanting an avulsed mature permanent tooth, according to the International Association of Dental Traumatology (IADT)[2] and CARE guideline.[10]

CASE REPORT

General concerns when receiving the patient

Some overall concerns involved in receiving a patient with dental avulsion call for asking the patient questions that must be answered before treatment can be decided on. Knowing where, how and when the trauma occurred, and also the storage medium of the avulsed tooth until its destination are of fundamental importance. Other related information of vital importance to treatment and prognosis include neurological symptoms, presence of systemic diseases, allergies, and having healthcare coverage for tetanus vaccine application.

Clinical Examination and Diagnosis

A thirteen-year-old adolescent was referred from a public oral health center to the Dental Trauma Surveillance and Monitoring Center - Department of Pediatric Dentistry Universidade Federal do Rio de Janeiro (DTSMC-UFRJ), Brazil, with an avulsed right maxillary permanent central incisor (#11) suffered two hours prior to admission. The traumatic injury occurred at school during recreational sports, and the tooth fell to the ground. There were no episodes of loss of consciousness or vomiting after the trauma. The adolescent's teacher placed the avulsed tooth in a container with milk (Figure 1A), and took the child and tooth to a public oral health center, which immediately referred the patient to the DTSMC-UFRJ.

During anamnesis, the mother reported that the adolescent had no general health problems or allergies that could contraindicate tooth replantation. In addition, healthcare coverage for tetanus vaccine application was confirmed. Extraoral examinations revealed no skin injuries. During intraoral clinical examination, the left permanent maxillary central incisor[11] and the right permanent lateral maxillary incisor (#12) presented with slight mobility, with bleeding from the gingival crevice, but without displacement, and were diagnosed as having subluxation (Figure 1B). Radiographic examinations showed the complete displacement of tooth #11 and a completely empty socket (Figure 1 C). No suggestive abnormalities could be seen in teeth #21 or #12. The alveolus was evaluated, and no alveolar fracture was detected.

Replantation procedure

The topical and local anesthesia administered consisted of 20% benzocaine and 2% lidocaine with epinephrine 1:100.000 (Alphacaine – DFL) (for a total average of one and a half tubes, 2.7 ml) (Figure 2 A and B).

First, the tooth was removed from the milk-filled storage container, and the crown and root surface were irrigated clean with a jet of saline. This step enabled diagnosis of a closed root canal apex, and an uncomplicated crown fracture in the avulsed tooth.

Then, the tooth was manipulated from the crown, and slowly replanted with slight digital pressure. No force was used (Figure 2 C).

A flexible splint was installed involving the maxillary canines and incisors, as follows (Figure 2 D,E,F,G):

1.Acid etching (Scotchbond Etchant - 3M ESPE) and

application of an adhesive system (Scotchbond multi-purpose - 3M ESPE), following the manufacturer's recommendations;

2.A thin layer of composite resin (Z250 3M ESPE) was placed over all the teeth to be splinted and polymerized;

3. A nylon thread was positioned over the thin layer of composite resin, and another layer of composite resin was placed over the thread to hold it in place, after which the resin was polymerized. As this procedure was being performed tooth by tooth, the replanted tooth (#11) was held in place with digital pressure. The splint was kept away from the gingiva to avoid gingival inflammation (Figure 2G). Occlusal contact was checked.

The dosing schedule was 500mg amoxicillin every 8 hours, for 7 days, and chlorhexidine (0.12%) mouth rinse twice a day for 1 week, as local antimicrobial therapy.

The patient was instructed, in the presence of the caregiver, to avoid engaging in contact sports, to eat a soft diet, and to brush with a soft-bristled brush. Furthermore, both were advised of the importance of complying with required follow-up visits. It is believed that homecare helps in the healing process following an injury, in compliance with the sequential treatment regimen, and also aids in possible future outcomes. The splint was removed 30 days after replantation.

Endodontic Therapy and Restorative Procedure

Endodontic therapy was initiated five days after tooth replantation. The root canal was prepared chemically and mechanically with irrigation using 2.5% sodium hypochlorite. Calcium hydroxide mixed with saline solution was introduced as an intracanal medicament, and the access cavity was sealed with temporary restoration material. The calcium hydroxide solution was refreshed periodically, every 15 days, during 45 days. At each intracanal medicament change during clinical visits, the temporary restoration material was removed, the root canal was cleaned with saline solution, and irrigated with 2.5% sodium hypochlorite, a fresh calcium hydroxide paste was prepared, and the root canal was filled with the medication (Figure 3B).

Root canal obturation was performed when the clinical symptoms of mobility, sensitivity to percussion and swelling of surrounding tissues had ceased, and radiographic sings of external resorption had stopped (Figure 3). In the present case, the tooth was filled 50 days after replantation.

The access cavity and crown fracture restoration was performed using the incremental technique with freehand sculpting and composite resin (A2B and A2E – Z350 – 3M ESPE) after acid etching (Scotchbond multi-purpose - 3M ESPE), and also using conditioning with an adhesive system (Prime&Bond 2.1 - Dentsply) (Figure 3F).

Follow-up

After five days, onset of the external inflammatory root resorption could be observed in the apical third of the root (Figure 3A). This resorption stopped after the root canal medication was refreshed, and did not progress during 3 months of follow-up after replantation (Figure 3B, C, D and Figure 4B). At this time, the restoration was satisfactory both functionally and esthetically (Figure 4A). The patient is scheduled to be monitored periodically at the University's DTSMC-UFRJ dental trauma center for five years.



***Figure 1**: A) tooth storage medium (milk); B) frontal view during clinical and C) radiographic examinations.*

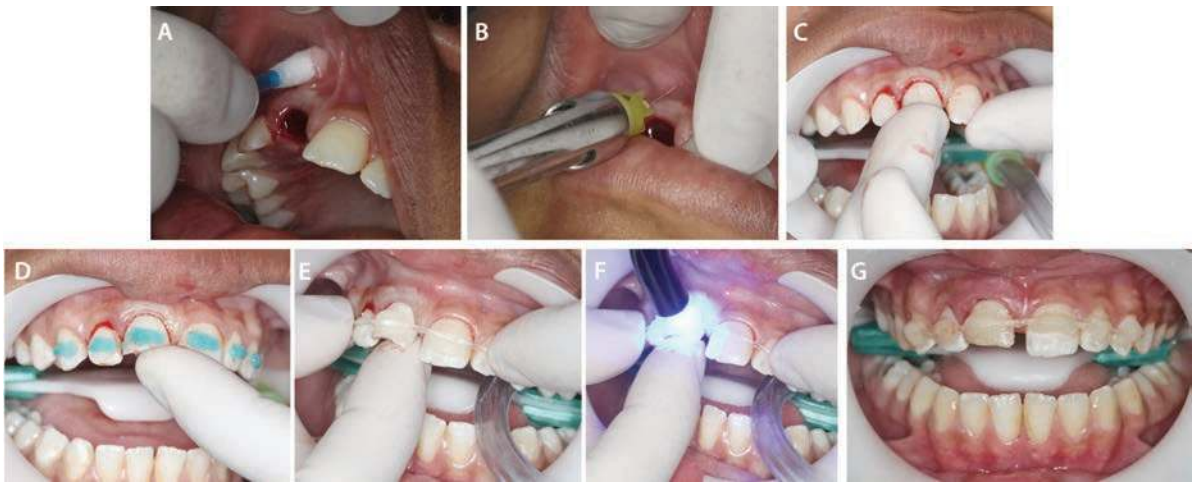

***Figure 2**: Replantation steps: Topical A) and local B) anesthesia; replantation of the tooth in the socket C); etching acid D); nylon thread was positioned after application of adhesive system and adaptation of composite resin, E); resin polymerization F); and final semi-rigid splint image G).*



***Figure 3**: Endodontic and restorative steps: periapical radiograph taken 5 days after replantation A); periapical radiograph taken 30 days after replantation (with calcium hydroxide in root canal) B) periapical radiographic 1 month after replantation C); periapical radiographic 2 months after replantation D); image after splint removal and before restoration E); and after composite resin restoration F).*



***Figure 4**: Clinical A) and radiographic B) views after 3 months of replantation.*

DISCUSSION

Previous studies have highlighted the importance of continuing dental education to further the knowledge of general dentists in the urgency management of avulsed permanent teeth.[8,9,12] The present manuscript made a step-by-step report of the immediate procedures to deal with an avulsed tooth indicated for replantation, following IADT recommendations.

Extraoral time and storage medium influence tooth avulsion treatment choice. Fifteen minutes is the ideal extraoral time for replantation.[2] The authors of this manuscript opted to replant the tooth, despite two hours of extraoral time, because it was stored in a physiological medium. Milk and herbal medicines have been reported as good alternatives to Hank's balanced salt solution.[11] It is worthwhile remembering that the main objective in cases of late replantation is to maintain the contour, width and height of the alveolar bone temporarily for future treatment.[2] In addition, there are also individual situations when replantation is not indicated, like periodontal disease and severe medical conditions.[2] The patient of the present case did not present any condition that would contraindicate tooth replantation.

A flexible splint has been found to promote periodontal healing of the reimplanted tooth better, because it allows slight tooth movement.[13] Thus, it was indicated in the present case, and installed to immobilize the reimplanted tooth, by fixing it to the tooth with composite resin. This splint can be made with steel wire up to 0.016 inches (0.4 mm) in diameter, or with a fishing line (0.13 - 0.25mm - nylon wire).[2]

Controlling the infection during periodontal healing after replantation is fundamental, because of the risk of inflammation during long-term healing periods, considering that inflammation creates an environment favorable to root resorption.[14] For this reason, the IADT recommends systemic antibiotic therapy associated to endodontic treatment for patients undergoing replantation procedures.[2] The endodontic treatment requires closing the apex ideally as of two weeks after replantation, to prevent infection of the periodontal ligament through the root canal.[2] In the present case, amoxicillin was prescribed, and the endodontic treatment was initiated 5 days before replantation.

Calcium hydroxide has been considered the gold standard of intracanal medication, because of its strong alkalizing effects, stemming from the generation of hydroxyl ions, which ensure antibacterial power with broad-spectrum activity.[15] Hydroxyl ions can diffuse through root dentine and penetrate deeper into the biofilm,[16] thus reducing the viable bacteria in half.[17] Calcium hydroxide was used as an intracanal medication for up to one month, with two changes in the medication solution, in the present study. Used together with systemic antibiotic therapy, this medication was found to be effective in stopping external root resorption, diagnosed 5 days after replantation.

Comparing the updates in the guidelines presented by IADT, some changes could be observed, like endodontic treatment in cases of avulsion of mature permanent teeth. This treatment used to be recommended between 7 and 10 days after replantation in 2012, whereas the period indicated currently is up to two weeks after replantation. In addition, although an antibiotic prescription is still questioned, systemic antibiotics are still prescribed to reduce possible inflammatory root resorption, and prevent periodontal infection. Amoxicillin and penicillin are indicated as the medications of first-choice.[2]

There are many outcomes associated with tooth avulsion, including pain and excessive mobility, as well as inflammatory, infection-related or ankyloses-related replacement root resorption, and even tooth loss resulting from contraindication of replantation, or sequels. Periodic clinical and radiographic monitoring is important for all types of traumatic dental injuries, to diagnose and treat any of these outcomes, as quickly as possible. Additionally, it is important to underscore that clinicians must evaluate the avulsed tooth as well as its adjacent neighbors and antagonists at each return visit, since other teeth may have also suffered secondary trauma.[2]

CONCLUSION

In this case report, the authors describe the IADT recommendations for tooth replantation. These procedures should be made known to general dentists to improve their knowledge regarding avulsed teeth, and ensure correct procedural behavior in their immediate handling of an avulsion in the event of urgencies.

REFERENCES

1. Azami-Aghdash S, Ebadifard Azar F, Pournaghi Azar F, Rezapour A, Moradi-Joo M, Moosavi A, et al. Prevalence, etiology, and types of dental trauma in children and adolescents: Systematic review and meta-analysis. Med J Islam Repub Iran. 2015;29: 234.
2. Fouad AF, Abbott PV, Tsilingaridis G, Cohenca N, Lauridsen E, Bourguignon C, O'Connell A, Flores MT, Day PF, Hicks L, Andreasen JO, Cehreli ZC, Harlamb S, Kahler B, Oginni A, Semper M, Levin L. International Association of Dental Traumatology guidelines for the management of traumatic dental injuries: 2. Avulsion of permanent teeth. Dent Traumatol. 2020 Aug;36(4):331-342. .
3. Diangelis AJ, Andreasen JO, Ebeleseder KA, Kenny DJ, Trope M, Sigurdsson A, et al. Guidelines for the management of traumatic dental injuries: 1. Fractures and luxations of permanent teeth. Pediatr Dent. 2017;39: 401-11.

4. Stewart C, Kinirons M, Delaney P. Clinical audit of children with permanent tooth injuries treated at a dental hospital in ireland. Eur Arch Paediatr Dent. 2011;12: 41-5.
5. Eslamipour F, Iranmanesh P, Borzabadi-Farahani A. Cross-sectional study of dental trauma and associated factors among 9- to 14-year-old schoolchildren in isfahan, iran. Oral Health Prev Dent. 2016;14: 451-7.
6. Soares AJ, Souza GA, Pereira AC, Vargas-Neto J, Zaia AA, Silva EJ. Frequency of root resorption following trauma to permanent teeth. J Oral Sci. 2015;57: 73-8.
7. Stewart SM, Mackie IC. Establishment and evaluation of a trauma clinic based in a primary care setting. Int J Paediatr Dent. 2004;14: 409-16.
8. Al-Shamiri HM, AlShalawi FE, AlJumah TM, AlHarthi MM, AlAli EM, AlHarthi HM. Knowledge, attitude and practice of hepatitis b virus infection among dental students and interns in saudi arabia. J Clin Exp Dent. 2018;10: e54-e60.
9. Cohenca N, Forrest JL, Rotstein I. Knowledge of oral health professionals of treatment of avulsed teeth. Dent Traumatol. 2006;22: 296-301.
10. Gagnier JJ, Kienle G, Altman DG, Moher D, Sox H, Riley D. The care guidelines: Consensus-based clinical case report guideline development. Journal of Clinical Epidemiology. 2014;67: 46-51.
11. Fagundes NCF, Bittencourt LO, Magno MB, Marques MM, Maia LC, Lima RR. Efficacy of hank's balanced salt solution compared to other solutions in the preservation of the periodontal ligament. A systematic review and meta-analysis. PLoS One. 2018;13: e0200467.
12. Menezes MC, Carvalho RG, Accorsi-Mendonca T, De-Deus G, Moreira EJ, Silva EJ. Knowledge of dentists on the management of tooth avulsion injuries in rio de janeiro, brazil. Oral Health Prev Dent. 2015;13: 457-60.
13. Veras SRA, Bem JSP, de Almeida ECB, Lins C. Dental splints: Types and time of immobilization post tooth avulsion. J Istanb Univ Fac Dent. 2017;51: S69-S75.
14. Consolaro A. The four mechanisms of dental resorption initiation. Dental Press J Orthod. 2013;18: 7-9.
15. Siqueira JF, Jr., Lopes HP. Mechanisms of antimicrobial activity of calcium hydroxide: A critical review. Int Endod J. 1999;32: 361-9.
16. Lin S, Tsesis I, Zukerman O, Weiss EI, Fuss Z. Effect of electrophoretically activated calcium hydroxide on bacterial viability in dentinal tubules—in vitro. Dent Traumatol. 2005;21: 42-5.
17. Chai WL, Hamimah H, Cheng SC, Sallam AA, Abdullah M. Susceptibility of enterococcus faecalis biofilm to antibiotics and calcium hydroxide. J Oral Sci. 2007;49: 161-6.

Revista Científica do CRO-RJ (Rio de Janeiro Dental Journal) | Instructions to authors

The Revista Científica do CRO-RJ (Rio de Janeiro Dental Journal), a periodical published quarterly aiming at divulging and promoting scientific production and interchange of information between the Brazilian and International community in the different areas of Dentistry and other fields of Health Care. The entire content of the Revista Científica do CRO-RJ (Rio de Janeiro Dental Journal) is available on the following web site http://revcientifica.cro-rj.org.br, to which there is free access. All the articles published in the Revista Científica do CRO-RJ (Rio de Janeiro Dental Journal) have a publication license CC BY-NC-ND (http://creativecommons.org/licenses/by-nc-nd).

The Revista Científica do CRO-RJ (Rio de Janeiro Dental Journal) publishes original articles, clinical case reports, protocols, reviews, letters to the editor and editorials/comments. Researches involving animals and/or human beings must be accompanied by the Certificate of Approval of a Research Ethics Committee. All articles are published in PDF format, in American English and must be submitted in this language. An abstract in Portuguese is demanded at the time of submitting and sending the final version.

Peer Review Process

All the content published by the Revista Científica do CRO-RJ (Rio de Janeiro Dental Journal) goes through the process of review by specialists. Articles submitted for appreciation are sent to the CRO-RJ librarian, who, under the supervision of the Editors-in Chief, initially assesses them with regard to the minimum standards demanded relative to form of presentation in the Revista Científica do CRO-RJ (Rio de Janeiro Dental Journal), with a view to complying with all the guidelines required for sending original articles. Once approved at this stage, the original is submitted for appreciation by the Editorial Board, to assess the merit of the work and decide about the convenience of publishing it, with or without changes. After this, the article is sent to undergo a process of evaluation carried out in the review system, by peers selected from a register of reviewers. The reviewers are always professionals from institutions different from that of the origin of the article; they are blind to the identity of the authors and place of origin of the work. After receiving both reports, the Editorial Council evaluates them, and decides about acceptance of the article without changes, rejection, or return to the authors with the suggestions about changes. The Editorial Board is responsible for returning the article to the authors for explanations, as many times as necessary, and at any time, the Editors may decide to reject the document. Each version is always analyzed by the Editorial Board that has the power of making the final decision.

Types of Articles Published

The Revista Científica do CRO-RJ (Rio de Janeiro Dental Journal) accepts the spontaneous submission of original articles, clinical case reports, protocols, reviews, letter sot the editor and editorials/review comments, and letters to the editor.

Original articles include randomized and controlled studies; studies of diagnostic tests and triage; observational cohort, case control and cross-sectional studies; other descriptive and experimental studies, as well as those of basic research with laboratory animals. The text must have a maximum of 3.000 words, excluding tables and references; the number of references must not exceed 30. Articles that report clinical trials with therapeutic interventions must be registered in one of the Registers of Clinical Trials

listed by the World Health Organization. In the absence of a Latin American Register, the Revista do CRO-RJ (Rio de Janeiro Dental Journal) suggest that the authors use the following register www.clinicaltrials.gov, of the National Institute of Health (NIH). The Identification Number must be presented in the body of the manuscript. The submission of clinical trials must adhere to CONSORT checklist (http://www.consort-statement.org/). In cases of submission of observational studies, for preparation of the manuscript, adhesion to the STROBE guidelines is requested (https://www.strobe- statement.org/index.php?id=strobe-home).

Clinical Case Reports must not exceed 2000 words, including the abstract, brief introduction, description of the case, discussion, acknowledgments (if there are any). The figures may be organized in the form of a panel. Each panel will be considered a figure. The abstract must not exceed 250 words. Case report articles must be accompanied by the term of free and informed consent signed by the participant and/or his/her legal guardian. For preparation of the manuscript, authors must adhere to the guidelines suggested in CARE (http://www.care-statement.org).

Protocols aim to guide clinical practices in the different specialties of dentistry. Description: Structured Summary (150 words); introduction; step-by-step presentation of the adopted protocol with textual description and images/figures/tables; discussion, conclusions and references.

Reviews are critical and orderly assessments of the literature relative to topics of clinical importance, with emphasis on factors such as the causes and prevention of diseases, their diagnosis, treatment and prognosis. Systematic reviews and meta-analyses are included in this category. In the body of the manuscript of the latter two types of reviews, authors must include the Registration Number of the Review protocol in PROSPERO (http://www.crd.york.ac.uk/PROSPERO/). For preparation of the manuscript, authors must follow the guidelines proposed by PRISMA (http://www.prisma-statement.org/). Authors may also submit a proposal of a review article, with a script, to the Editorial Board. If this is approved the author may develop the script and submit it for publication. Review articles must be limited to 6.000 words, excluding references and tables.

Letters to the editor must contain comments with a constructive critical content about subject matter previously published in the Revista Científica do CRO-RJ (Rio de Janeiro Dental Journal). These must be submitted directly to the Editorial Board. The maximum size is 1000 words, including a maximum of 10 bibliographic references. Whenever possible, a reply to the authors will be published together with the letter.

Editorials and comments are commissioned from authorities in specific areas. The Editorial Board may also analyze proposals of spontaneously submitted comments.

General Guidelines

The manuscript must be written using 12-point Arial font, on A4 size pages, with 1.5 line spacing, and a 3 cm margin on each side of the page, including the bibliographic references and titles/legends of tables and illustrations. The file must be presented in digital format, extension “doc” or “docx”. Each section must start on a new page, in the following order; title page, abstract in Portuguese, Abstract in English, text, acknowledgments, bibliographic references, tables (each complete table, with title and footnotes, on a separate page), figures (each complete figure, with titles and footnotes, on a separate page) and figure legends.

The following are the main guidelines about each section, according to the type of manuscript:

Title Page

The title page must contain all of the following items of information:

a) Title of the article, concise and informative, avoiding the use of superfluous terms and abbreviations; also avoid indicating the place and city where the study was conducted;

b) Abbreviated title (short title) to be stated at the top of all the pages with a maximum of 60 characters, counting the spaces;

c) The full name of each of the authors (first name and other surnames, with the last surname typed in bold-face font.

d) Department to which the authors are affiliated and/or definition of the institution or official service to which the study is tied;

e) Specific contribution of each author to the study;

f) Declaration of conflict of interest (write “nothing to declare” or a clear revelation of any interest of an economic or other nature that may cause embarrassment if it becomes known after publication of the article);

g) Name, address, telephone, fax and e-mail address of the corresponding author;

h) Source of financing or supplier of equipment and materials, if this were the case;

ABSTRACT

The abstracts (Portuguese and English) must contain a maximum of 250 words, avoiding the use of abbreviations. No words that identify the institution or city where the article was written must be put into the abstract, to facilitate blind reviewing. All the information that appears in the abstract must also appear in the article. The abstract must be structured according to the following description:

Abstract of Original Article

Introduction (optional): introduce the reader to the topic to be addressed in the article.

Aim: inform the initial hypotheses, if there are any. Define the main aim and inform only the most relevant secondary aims.

Methods: Inform the type of study design, contextual or local, the patients or participants (define the eligibility criteria, sample number, sample distribution criteria among groups, etc.), the interventions/exposures (describe characteristics, including methods of application, variables analyzed, duration, etc.), and the criteria for measuring the outcome, including the statistical analysis.

Results: Inform the main data, confidence intervals and significance, the statistics of the findings.

Conclusions: Present only those supported by the data of the study, and that contemplate the aims, as well as their practical application with equal emphasis on the positive and negative findings that have similar scientific merits.

Abstract of Case Reports

Introduction (optional): inform the reader about the topic to be addressed.

Aim: briefly state the aims of the report.

Case Report: report the case itself.

Results: Inform the main data related to resolution of the case.

Conclusions: Present only those supported by the data of the study, and that contemplate the aims and their application.

Abstract of Reviews

Introduction (optional): briefly report the central topic of the review, and justify why it was conducted.

Aim: Inform the aim of the review, indicating whether it especially emphasizes some factor, risk, prevention, diagnosis, treatment or prognosis.

Sources of data: Describe the sources of the research, defining the databases and years researched. Briefly inform the eligibility criteria of articles and methods of extraction and evaluation of the quality of information (in cases of Systematic Reviews).

Summary of data: Inform the main results of the research, whether they are quantitative or qualitative.

Conclusions: Present the conclusions and their clinical application.

After the summary of the original articles, case reports or reviews, include three to six key-words that will be used for indexing. Use terms of Medical Subject Headings (MeSH), available in http://www.nlm.nih.gov/mesh/ meshhome.html. When adequate descriptors are not available, it is possible to use free terms.

Abstract of Protocols

Inform the reader about the topic to be addressed and state the aim of the protocol.

ABBREVIATIONS

These must be avoided, because they hamper comfortable reading of the text. When used, they must be defined when they are used for the first time. They must never appear in the title and abstracts.

TEXTS

The text of **original articles** must contain the following sections, each with its respective sub-title:

Introduction: Clear, objective, succinct, citing only references strictly related to the topic, and seeking to justify why the study was conducted. At the end of the introduction, the aims of the study must be clearly described.

Materials and Methods: Describe the population studies, sample and eligibility criteria; clearly define the variables and detail the statistical analysis; if necessary, include references about the methods used during the course of this section. Procedures, products and items of equipment used must be described in sufficient detail to allow reproduction of the study. Furthermore, they must contain details of the brand and place of manufacture. In case of studies with human beings and/or animals, it is mandatory to include a declaration that all the procedures were approved by the research ethics committee of the institution to which the authors belong. In the absence of this, approval must be obtained from another research ethics committee indicated by the National Commission of Research Ethics of the Ministry of Health.

Results: These must be presented clearly, objectively and in a logical sequence. The information contained in tables or figures must not be repeated in the text. The option to use graphs instead of tables with a large number of data depends on the authors and Editorial Board, which may suggest changes and adjustments with the purpose of making them better suited to the guidelines and specificities of the Revista de Odontologia do CRO-RJ (Rio de Janeiro Dental Journal).

Discussion: This must interpret the results and compare them with data previously described in the literature, emphasizing the new and important aspects of the study. Discuss the implications of the findings and their limitations, as well as the need for additional researches. Avoid repetition of the results and/or superimposition between results and discussion. The conclusions must be presented at the end of the discussion, and must respond to the aims of the study, by avoiding information if inferences were not supported by the findings. The authors must place equal emphasis on favorable and unfavorable findings that have similar scientific merits. Include recommendations, when these are pertinent.

The text of **case reports** must contain the following sections, each with its respective sub-title:

Introduction: Clear, objective, succinct, citing only references strictly related to the topic, and seeking to justify why the study was conducted. Describe the aims at the end of the introduction.

Case Report: must present details of the case and procedures for performing them. Describe the follow-up data and prognosis of the case, when pertinent. CRO suggests that cases without due conclusion should be avoided. Mention the Term of Free and Informed Consent.

Discussion: Discuss the diagnostic, therapeutic and technical criteria used, among other details about the case. Discuss the clinical implications of the findings and their limitations. The conclusions must be presented at the end of the discussion, and must respond to the aims of the study, by avoiding information if inferences were not supported by the findings. The authors must place equal emphasis on favorable and unfavorable findings that have similar scientific merits. Include recommendations, when these are pertinent.

The text of **review articles** must contain the following topics: - In case of **narrative reviews**, the following are suggested:

Introduction: clear and objective, in which the authors explain the importance of the review to clinical practice, in the light of dental literature. The introduction must conclude with the aims of the review.

Materials and Methods/Data Source: It is necessary to describe the methods of data selection and extraction, followed by Data Synthesis.

Data Synthesis: This data synthesis (result/discussion) must present all the pertinent information in rich detail.

Conclusion: The conclusion section must correlate the main ideas of the review with the possible clinical applications, limiting generalization to the domains of the review.

- In cases of **systematic reviews, with or without meta-analyses**, the authors must follow the PRISMA statement (http://www.prisma-statement.org/). These reviews must contain: **Introduction**: that demonstrates the pertinence of the subject and the existent controversy with respect to the topic. At the end of the introduction, the authors should raise the focal question of the review. **Materials and Methods**: must present the search strategy; eligibility criteria of the studies; risk of bias analysis of the included studies; data extraction, and when pertinent, the strategy used for quantitative data synthesis.

Result: must respond in an orderly manner to the data searched according to the methodological design with respect to the qualitative and quantitative synthesis of the primary studies included.

Discussion: must consider interpreting the results, emphasizing resolution of the controversies related to the topic, with this being directed towards answering the focal question of the review, showing whether or not there is need for further research. The limitations of the study must also be pointed out and envisage the external validity of the study (power of generalization of the data).

Conclusion: The conclusion section must correlate the main ideas of the review with the possible clinical applications.

Acknowledgments

These must be brief and objective; they should only mention the person or institutions that made a significant contribution to the study, butthat had not fulfilled the criteria of authorship.

References

The references must be formatted in the Vancouver style, also known as the Uniform Requirements style.

The bibliographic references must be numbered and ordered according to the order in which they appear in the text, in which they must be identified by the respective superscript Arabic numbers. To list the references, do not use the Word resource of end notes or footnotes.

Articles accepted for publication, but not yet published, may be cited provided that the name of the journal is indicated and that it is "in press". Unpublished observations and personal communications may not be cited as references. If it were imperative to include information of this type in the article, it must be followed by the observation "unpublished data" or "personal communication" in parentheses in the body of the article.

The titles of periodicals must be abbreviated as recommended in the Medicus Index; a list with their respective abbreviations may be obtained by means of the publication NLM "List of Serials Indexed for Online Users", available at the address http:// www.nlm.nih.gov/tsd/serials/lsiou.html.

As follows, we present some examples of the model adopted by the Revista Científica do CRO-RJ (Rio de Janeiro Dental Journal):

Articles in periodicals:

1. Up to six authors:

Vieira AR, Bayram M, Seymen F, Sencak RC, Lippert F, Modesto A. In Vitro Acid-Mediated Initial Dental Enamel Loss Is Associated with Genetic Variants Previously Linked to Caries Experience. Front Physiol. 2017 Feb 22;8:104. doi: 10.3389/fphys.2017.00104.

2. More than six authors:

da Silva Bastos Vde A, Freitas-Fernandes LB, Fidalgo TK, Martins C, Mattos CT, de Souza IP, et. al. Mother-to-child transmission of Streptococcus mutans: a systematic review and meta-analysis. J Dent. 2015 Feb;43(2):181-91. doi: 10.1016/j.jdent.2014.12.001.

3. Organization as author:

American Academy of Pediatrics. Clinical practice guideline. Diagnosis and management of childhood obstructive sleep apnea syndrome. Pediatrics 2012;130 (3):576-684.

4. Articles with electronic publication, not yet with printed publication:

Tavares Silva C, Calabrio IR, Serra-Negra JM, Fonseca- Gonçalves A, Maia LC. Knowledge of parents/guardians about nocturnal bruxism in children and adolescents. Cranio. 2016; Jun 24:1-5. [Epub ahead of print]

Books:

Andreasen JO, Andreasen FM. Textbook and color atlas of traumatic injuries to the teeth. 4ª ed. Copenhagen: Mosby. 2007.

Chapters of Books:

Pagel JF, Pegram GV. The role for the primary care physician in sleep medicine. In: Pagel JF, Pandi-Perumal SR, editors. Primary care sleep medicine. 2nd ed. New York: Springer; 2014.

Academic Studies:

BorkowskiMM. Infant sleep and feeding: a telephone survey of Hispanic Americans [dissertation]. MountPleasant(MI): Central Michigan University; 2002.

CD-ROM:

Soils. Geographica on CD ROM. [CD ROM]. Melbourne, Australia: Random House. 1999.

Homepage/website:

Integrative Medicine Center[Internet]. Houston: University of Texas, M. D. Anderson Cancer Center; c2017 [cited 2017 Mar 25]. Available from: https://www.mdanderson.org/patients- family/diagnosis-treatment/care-centers-clinics/integrative- medicine-center.html.

Ministry of Health Documents/Decrees and Laws:

1. Brazil. Decree 6.170, of July 25, 2007. States provisions about the rules relative to Transfers of resources from the Union by means of transfer agreements and contracts and makes other provisions. Diário Oficial, Brasília, 26 jul. 2007.

2. Brazil. Ministry of Health Health Care Secretary Department of Primary Care Política Nacional de Atenção Básica / Ministério da Saúde. Health Care Secretary Department of Primary Care Brasília, Ministério da Saúde, 2012. (Série E. Legislação em Saúde)

Presentation of Paper/Study?

Pierro VSS, Maia LC, Silva EM. Effect of pediatric syrups on roughness and erosion of enamel (abstract). 82nd. IADR General Session & Exhibition; 2004 Mar 10-13, Honolulu, Hawaii. J Dent Res 2004, 83 (Special Issue A): 896.

Tables

Each table must be presented on a separate page, numbered with a Arabic numeral (1, 2, 3, etc.), in the order of appearance in the text; with single spacing between lines, and contain a summarized but explanatory title. All the explanations must be presented in footnotes and not in the title, identified with superscript letters in alphabetical order. Do not underline or draw lines within the tables and do not use spaces to separate the columns. Do not use space on either side of the symbol ± or any other symbol.

Figures (photographs, drawings, graphs, etc.)

All the figures must be numbered with Arabic numerals (1, 2, 3, etc.), in order of appearance in the text. The title must be clear and objective, and must appear at the base of the Figure. All the explanations must be presented in the legends, including those about the abbreviations used. Figures reproduced from other previously published sources must indicate this condition in the legend, in addition to being accompanied by a letter of permission from the copyright holder. Photographs must not allow identification of the patient; masking the patient's eye region in the photograph may not provide sufficient protection. Should there be possibility of identification, it is mandatory to include a written term of free and informed consent to publication. Microphotographs must present internal scales and arrows in contrast with the background.

Illustrations in color are accepted for publication online, without additional cost to the authors. However, all the figures will be transformed to black and white in the printed version. If the authors consider it essential for a certain image to be in color, even in the printed version, the authors are requested to make special contact with the editors. Computer-generated images, such as graphs, must be attached in the form of files in the following formats: .jpg, .gif or .tif, with minimum resolution of 300 dpi. Graphs must preferably be presented in two dimensions. CRO will only accept

drawings, photographs or any illustrations that contain an adequate degree of resolution for the printed version of the journal.

Figure Legends

These must be presented on a separate page, duly identified with their respective numbers.

Verification List

As part of the submission process, authors are requested to indicate their agreement with the items listed as follows:

1. All the authors will sign and submit their agreement by means of a Copyright License Declaration (and end user license), and the content of their intellectual work will be their sole and exclusive responsibility.

2. The corresponding author must prepare, with the consent of the other authors, a letter of submission of the article to the Revista Científica do CRO-RJ (Rio de Janeiro Dental Journal).

3. The submission file (manuscript) must be sent as a Microsoft Word document.

4. The title page must contain all the information required, as specified in the guidelines to the authors.

5. The abstract and key words must be formatted and submitted in English and Portuguese, following the title page.

6. The entire text must be presented in double line spacing using 12-point Arial font, and using italics instead of underlining to indicate emphasis (except in e-mail addresses. All the tables, figures and legends must be numbered in the order in which they appear in the text; each of these must be placed on a separate page, after the bibliographic references at the end of the article.

7. The text must be in accordance with the demands of style and bibliography described in the publication guidelines.

8. The references must be presented in the so-called Vancouver style, and numbered consecutively in the order in which they appear in the text.

9. Information about approval of the study by a research ethics committee must be clearly presented in the text, in the Methods section, and must be sent as an attachment.

10 All the internet addresses presented in the text must be active and ready to be clicked on.

11.Documentary proof of potential Conflict of Interest must be signed by all the authors and sent as an attachment during the submission process.

Final Considerations:

Anti-Plagiarism Policy

The Revista Científica do CRO-RJ (Rio de Janeiro Dental Journal) uses a system to detect plagiarism (available at http//:www.plagium.com/pt/detectordeplagio). When submitting an article to the journal, the authors accept that the work will be digitized in the mentioned program at the time of submission, and in the case of acceptance, prior to publication.

Ethics Policy of the Publication

All submissions will be subject to the condition that the articles have not been previously published, and have also not been simultaneously submitted to another medium of disclosure. All the authors must have read and approved the content and all the authors have declared possible conflicts of interest. The article must follow the ethical principles

of the Revista Científica do CRO-RJ (Rio de Janeiro Dental Journal), and they must also comply with the international standards of research ethics in studies with human beings and animals.

Conflict of interest and financial aid

The Revista Científica do CRO-RJ (Rio de Janeiro Dental Journal) requires all authors to declare potential conflicts of interest. Any interest or relationship, financial or other type that may be perceived as having influenced the results of a study, and the objectivity of an author, is considered a potential source of conflict of interests, and must be declared. The potential sources of conflict of interest include, but are not limited to, rights arising from patent rights or ownership of shares, membership of a board of directors, membership of an advisory board or committee of a company, and receiving advice or speaking fees from a company. If the authors are not sure whether a past or present affiliation or relationship needs to be divulged in the manuscript, please contact the editorial office at http://revcientifica.cro-rj.org.br

The existence of conflict of interests does not exclude publication.

The corresponding author is responsible for ensuring that all the authors fulfill and sign the copyright license declaration and other mandatory documents at the time of submission.

Confirmation of sending the documents

After submission, the corresponding author will receive an e-mail to confirm receipt of the article. If this e-mail of confirmation is not received after 24 hours, please contact the Revista Científica do CRO-RJ (Rio de Janeiro Dental Journal) by e-mail: revistacientifica@cro-rj.org.br. The error may have been caused by some type of spam filtering in the e-mail server.

Updating the status of the article

The initial process of evaluating the article may take up to 60 days, counted from the date of its submission. Should this period have expired, you may contact the Editorial Board to verify the present status. The Revista Científica do CRO-RJ (Rio de Janeiro Dental Journal) will inform you by e-mail, once a decision has been made. One of the following possibilities will be indicated in the reply e-mail: 1. Make adjustments to suit the guidelines and Re-submit; 2. Accepted; 3. Minor adjustments required; 4. Major adjustments required; 5. Rejected. In the latter case, the article will be summarily refused and cannot be re-submitted to the journal.

Submission of Revised Articles

The revised manuscripts must be sent within 2 months after notifying the authors about the conditional acceptance (minor or major adjustments). All the revisions must be accompanied by a letter of response to the reviewers, in which each question or suggestion made by the reviewers must be answered in sequential order. The letter must a) detail the author's reply, point by point, to each of the reviewers' comments, and b) a revised manuscript, highlighting in color, exactly what has been changed in the manuscript after revision. In addition to this, any need for adjustment or correction of the manuscript is the sole responsibility of the authors.

The authors must supply an official certificate of revision of the English language in the act of submitting the revised manuscript. The authors will be fully responsible for the costs of translation/revision of the English language.